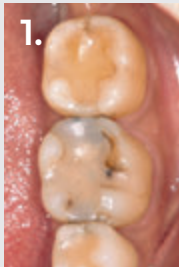


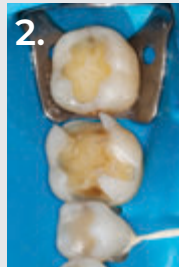


DR. RAFAEL BEOLCHI

Dr. Rafael Beolchi graduated from the University of São Paulo, Brazil, in 2000. He has maintained a private practice since 2001, working mainly in esthetic dentistry and oral rehabilitation. In 2009, he received a master's degree in Biomaterials. He lectures around the world, mainly on the advanced handling of dental materials with an easy step-by-step approach. He now lives in Portugal where he is pursuing his second master's degree.




1. Before: Failed composite restorations on both lower molars.



2. DermaDam™ rubber dam isolation after removal of the old restorations.



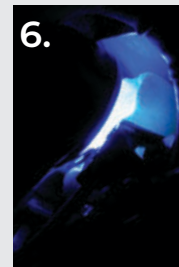
3. Trident® V3 sectional matrix system being placed, along with the anatomical wedges and rings.



4. Ultra-Etch™ etchant selectively placed on the enamel margins. Peak™ SE Primer was used as the self-etching primer on dentin and Peak™ Universal Bond adhesive was used as the bonding agent.



5. Scrubbing motion of Peak Universal Bond adhesive after Peak SE Primer application.



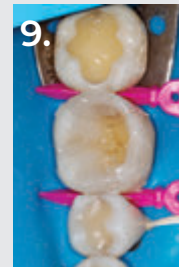
6. Peak Universal Bond adhesive being light cured by VALO™ Grand curing light.



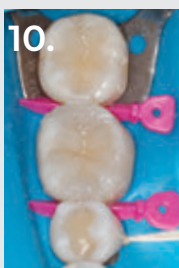7. PermaFlo™ flowable composite (A2 shade) was applied over the cavity angles and on the proximal boxes to reduce stress during polymerization and to ensure a total and complete seal of the restoration margins, respectively. It also helps in avoiding air bubbles.



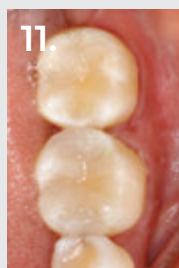
8. After curing PermaFlo flowable composite, Transcend™ composite Universal Body shade was used to create the missing mesial and distal walls.



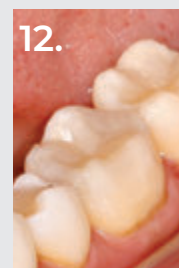
9. Transcend composite Universal Body shade applied over the lingual side of the first lower molar, already sculpted and light cured.



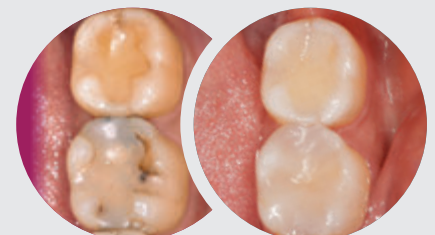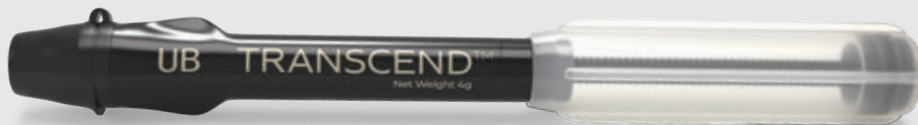10. Both restorations finalized. Note the integration of the single Universal Body shade used with the surrounding tooth structure.



11. Final aspect of the restorations after occlusal adjustments and polishing. Note how the composite blends with the surrounding tooth structures and gives an esthetic and natural appearance on the proximal boxes without the use of any blocker shades.



12. Buccal view of the finalized restorations. Note the integration of the Transcend composite Universal Body shade and tooth structure on the buccal wall of the first lower molar.



Before

10 Months After Restoration