

Keeping financially afloat during residency

By Dean Monti

Resident lives are saturated with books, charts, and a considerable amount of studying. With boards and the rest of their careers looming ahead, there is obviously a lot of associated stress. One area of education that's generally not covered in residency programs, however, is debt. Directions recently reached out to residents about this topic, and received plenty of feedback regarding their concerns, fears, advice, and more.

One resident we talked to, Jeffrey Kushner, DO — a PGY-3 at Saint Joseph Mercy Health System in Ann Arbor, Michigan — has been augmenting his studies with a strong interest in investment and personal finance. He has researched and read extensively on a variety of financial topics that dermatology residents face early in their careers, and has discovered some universal principals that all dermatology residents should be aware of. He has subsequently lectured and given presentations to his fellow residents on finance and investment topics. He has no conflict of interest — which is often a concern for those seeking advice. He just hopes to provide helpful, unbiased information as a fellow peer to any resident with limited knowledge about debt and personal finance.

For this issue of Directions — after soliciting feedback from residents — we encapsulated some of the most prevalent concerns and included them here, with responses from Dr. Kushner.

DIR: Residents indicated to us that debt is a pervasive issue throughout residency.

Dr. Kushner: Debt is a highly complicated issue. It affects many different aspects of resident life both personally and professionally. The majority of physicians, however, do not receive the proper training on how to manage debt in a timely and effective manner. Since it is hardly ever discussed in dermatology training, residents



don't realize that they're lacking the skills or knowledge to handle their debt until it becomes a reality.

For most of us, having a growing mountain of debt is an anxiety-provoking issue, but it can lead some to take an "out of sight, out of mind" approach. This is undoubtedly a surefire way to create an even bigger problem from an already unfortunate situation. For those who try to tackle it head on, some of the most common fears include: Will I ever be able to pay the debt off? Where and how do I start? How will this affect my decisions about where to practice, when to start a family, and when to ultimately retire?

Today, the increasing medical school tuition and looming threat of decreasing reimbursements are clouding our financial future, and it's only going to get worse. Compounding the problem even further is our "late" capacity to earn money in life. We usually don't start making a significant salary until our early- to mid-thirties, putting us "behind the eight ball" compared to our friends in engineering or business. Furthermore, a recent JAAD article from April

2016 discussed the staggering additional expense of simply applying to dermatology residency!

Fortunately, not everything is doom and gloom. We as dermatologists are still well-compensated compared to our colleagues in other specialties, so the ability to overcome debt and carve out a strong financial future is certainly possible.

See **FINANCIALLY AFLOAT** on p. 3

Inside *this* issue

- 1 Keeping financially afloat in residency

- 4-5 Boards' Fodders: Neonatal Ichthyosis & Neonatal Infectious Dermatoses

- 6 Race for the Case

- 8 Message from the Chair

ZEIN OBAGI MD™

— SKIN HEALTH SCIENCE —

“Embracing Change is the Key to Skincare Success”

- The past decade has seen unprecedented changes in professional skincare. Increasing demand. Better results. And distribution that left the control of the physician.
- That’s why I founded ZO®. We have advanced skincare protocols based on my philosophy of skin health. And our zero-tolerance of product diversion keeps physicians in control.
- Over 7,000 physicians have already made the change. Experience the ZO® Difference.



DR. ZEIN OBAGI
Dermatologist and
ZO Medical Director

DR. ZEIN OBAGI RESPONDS TO CHANGE

Created the Science
of Skin Health

1981

Conceived the
original Obagi
Nu-Derm®

1988

Ended relationship
with OMP

2006

Founded ZO Skin
Health, Inc.

2007

Developed new
medical products
and protocols

2012

Now Exclusively
Recommends ZO®

zoskinhealth.com | 888.893.1375

ZO SKIN HEALTH INC
— BY ZEIN OBAGI MD —

The ZO® Difference

Better Results | More Referrals | Patient Loyalty | Enhanced Revenue

ZO Skin Health, Inc. and Dr. Obagi have no business relationship with Obagi Medical Products, and Obagi Medical products does not sell or endorse using ZO products.

DIR: Many residents we talked to expressed surprise and concern when they realized their finances didn't match their lifestyle.

Dr. Kushner: Live like a resident. This is easier for some than others, but it's probably the most important factor: Do not live above your means. Once out of residency and making significant money for the first time, gradually grow into your attending salary. Or better yet, *never* fully grow into your attending salary! If you have the discipline to do this after residency graduation, you can easily wipe out all of your debt within five years, regardless of how much you have. An arbitrary but good goal is to save at least 20 percent of your gross income for savings, debt reduction, etc. For the majority of residents, debt is inevitable. The thing to avoid, if you can, is debt on top of debt. If debt is a concern, hold off whenever possible on burdening yourself with purchases and lifestyle changes that will put you any deeper in debt. Many residents want to have academic careers, or to give back to their communities with volunteer work, but student debt makes some of those ambitions unrealistic.

DIR: Some residents said that their financial situation directly impacted their career direction.

Dr. Kushner: Keep in mind your future finances. This remains a dilemma for many residents. While financial considerations did not dictate the field I ended up choosing, it encouraged me to learn as much as I could about debt, investing, and finance in general to make myself better prepared to handle the monetary aspect of medical practice. The good news is that if you live like a resident, you can take any job in any location and be successful. A strong savings rate is the most important take-away point of this article. However, achieving your financial goals is definitely impacted by your salary and earning potential. Private practice tends to pay more than academia; rural pays more than urban. Your emphasis should always be based on happiness, but if you got a late start to your medical career or have higher than average debt, you may want to consider the more lucrative position... at least initially.

DIR: Another common dilemma for residents is figuring out whether to refinance or stay in government programs.

Dr. Kushner: Consider refinancing your loans. Many of my peers believe that the 6.8 percent Stafford Loan received during medical school is our only option, and we are obligated to keep that rate. Some of you will be getting loan forgiveness through a government program which is excellent, but for the majority of dermatology residents, this isn't the case, and you should *refinance your loans!* Your offers will depend upon your salary to debt ratio, and whether you want a fixed or variable option. A common misconception is that refinancing your loans can only occur as an attending. This is a fallacy. For instance, Darien Rowayton Bank offers refinancing rates to residents. They have even established a business relationship with the AAD (for those who missed their booth in Washington D.C.). I have personally utilized them and subsequently cut my interest rate in half. And more companies are joining the mix every day. I'd encourage you to apply with multiple lenders and choose the best rate. Again, only apply if you will *not* get loan forgiveness.

DIR: Residents feel intimidated by debt because they lack the expertise that they're so used to exhibiting in their professional lives.

See **FINANCIALLY AFLOAT** on p. 7



Jeffrey Kushner, DO, is a PGY-3 at Saint Joseph Mercy Health System in Ann Arbor, Michigan.

Financial information for medical students

Many residents we spoke to cited *The White Coat Investor* (whitecoatinvestor.com), a site created and managed by James Dahle, MD, who is a financial writer and a practicing emergency physician just a few years out of residency, as a key source of financial information for medical students. Directions asked Dr. Dahle about resident debt.



What is the average debt for dermatology residents?

I've never seen it broken down by specialty, but the most reliable stats are published each year from the AAMC. It's basically a compilation of the exit survey every medical student takes when leaving med school. The average debt of those who have debt is \$183k for MDs, and closer to \$225k for DOs.



In terms of finances, what are the most common fears and concerns?

The biggest fear is whether they'll ever be able to pay off the debt. Interestingly, those who should be the most worried are usually the least worried. I'm always surprised that a large percentage of those over \$450k in debt are going into poorly paying specialties.


Many medical students today get stuck trying to figure out whether to refinance or stay in government programs, and, if so, which one to choose. It's a surprisingly complicated decision.

*Do you have a story to tell about residency or a specific item of interest? Study tips, work life balance, unique images, iconoclastic views? **We're now accepting submissions for 2017!** Email dmonti@aad.org to submit your story or get more info.*

Neonatal Ichthyosis

by Alyx Rosen, MD and Kate Oberlin, MD

Disease	Gene Defect	Clinical Presentation	Additional Manifestations	Prognosis/ Outcome
Harlequin ichthyosis	AR ABCA12	Thick membrane with deep cracks and fissures forming plate-like scales, ectropion, eclabium	Premature delivery; respiratory distress; ear deformities; fluid imbalance	Survival rate ~50%; oral retinoids may help prolong survival
Congenital ichthyosiform erythroderma (CIE)	AR TGM-1 ALOX12B ALOXE3	Generalized erythema and fine scale; collodion membrane at birth; involves flexures; nail dystrophy	Heat intolerance; scarring alopecia; rare ectropion	No improvement with age
Lamellar ichthyosis	AR TGM-1 ABCA12	Thick, brown scale involving flexural areas and trunk; eclabium, ectropion	Heat intolerance; hypernatremia	No improvement with age
Epidermolytic hyperkeratosis (EHK); Bullous CIE	AD K1/K10	Widespread blistering and erythema at birth; involves flexures, palmoplantar keratoderma	Failure to thrive; hypernatremia; recurrent infections	Evolves into verrucous hyperkeratotic plaques
Ichthyosis vulgaris	AD Filaggrin	Generalized fine, adherent scale sparing flexures	Atopic diathesis; keratosis pilaris	Improves with age
X-linked ichthyosis	XLR Steroid sulfatase	Generalized fine scale and desquamation at birth	Corneal opacities; cryptorchidism; prolonged labor	Brown "dirty" scales sparing flexures
Netherton syndrome	AR SPINK5	Trichorrhexis invaginata, ichthyosis linearis circumflexa, atopic dermatitis	Failure to thrive; infections; elevated IgE; food allergies	Pruritus; eczematous plaques
Refsum disease	AR PEX7 PHYH	Skin resembles ichthyosis vulgaris with mild scaling	Retinitis pigmentosa; cerebellar ataxia	Accumulation of phytanic acid; deafness
Sjögren-Larsson syndrome	AR FALDH	Generalized erythema and scale at birth, then dark scales on trunk	Parafoveal glistening white dots on retina	Mental retardation, seizures and spastic paralysis
Conradi-Hünemann-Happle syndrome	XLD EBP gene	Severe ichthyosiform erythroderma and scale following lines of Blaschko	Chondrodysplasia punctata; cataracts; deafness; alopecia	Follicular atrophoderma and scarring
KID syndrome	AD GJB2	Keratitis, ichthyosis, deafness, keratoderma	Photophobia; leukonychia	Increased risk of cutaneous SCC
Trichothiodystrophy (PIBIDS)	AR ERCC2 ERCC3	Photosensitivity, ichthyosis, brittle hair "tiger tail", intellectual impairment, decreased fertility, short	Sulfur deficiency in hair; diffuse alopecia	Photosensitivity decreases with age
CHILD syndrome	XLR NSDHL	Congenital hemidysplasia with ichthyosiform erythroderma, limb defects	Ipsilateral organ aplasia; stippled epiphyses	Erythema fades into hyperkeratosis



Kate Oberlin, MD, PGY-3, University of Miami, department of dermatology & cutaneous surgery



Alyx Rosen, MD, PGY-4, University of Miami, department of dermatology & cutaneous surgery

DDx "Collodion Baby": Lamellar Ichthyosis, Congenital Ichthyosiform Erythroderma (CIE), Netherton syndrome, Harlequin Ichthyosis, Self-healing collodion baby (SHCB), Trichothiodystrophy (PIBIDS), Sjögren-Larsson syndrome, Infantile Gaucher disease, Neutral lipid storage disease with ichthyosis, Hay-Wells syndrome, Conradi-Hünemann-Happle syndrome

References:

- Bolognia, Jean, Joseph Jorizzo, and Julie Schaffer. "Chapter 57." *Dermatology*. 3rd ed. Philadelphia: Elsevier Saunders, 2012. 837-870. Print.
- Cohen, Bernard. "Chapter 2." *Pediatric Dermatology*. 4th ed. Philadelphia: Elsevier Saunders, 2013. 25-39. Print.
- Schachner, Lawrence, Ronald Hansen. "Chapter 8." *Pediatric Dermatology*. 4th ed. Philadelphia: Elsevier Mosby, 2011. 567-643. Print.

Neonatal Infectious Dermatoses

by Alyx Rosen, MD, and Kate Oberlin, MD

Disease	Clinical Presentation	Extracutaneous Manifestations	Work-Up	Treatment
Syphilis	Macules or papules on palms and soles, trunk, extremities; also erosions, bullae and petechiae; mucous patches	IUGR, HSM, osteochondritis, "snuffles" or rhinitis	Maternal and neonate serology; darkfield examination	High dose penicillin G to prevent late complications
Candidiasis	Diffuse red eruption with satellite red papules and pustules on the folds and scrotum	Oral thrush, paronychia, systemic infection	Gram stain or KOH reveals pseudohyphae or budding yeast	Topical nystatin, ciclopirox, imidazoles, PO/IV if septic
Toxoplasmosis	Varies depending on timing of infection; non-specific, diffuse macules or papules, ecchymosis	Chorioretinitis, hydrocephalus, deafness, preterm birth, IUGR	Serologic testing for antigen, PCR, or antibody (IgG, IgM)	Pyrimethamine with Sulfadiazine and leucovorin
Rubella	"Blueberry muffin" macules due to extramedullary hematopoiesis	Cataracts, congenital heart disease, deafness, HSM, microcephaly	Viral cultures of pharynx, CSF, urine, conjunctiva, rubella antibody	Neuroimaging; supportive care
CMV	Generalized petechiae or purpura within 48 hours of birth, "blueberry muffin" macules	IUGR, deafness, HSM, thrombocytopenia, chorioretinitis	Viral culture, PCR, antibody testing	Ganciclovir, valganciclovir, foscarnet
Scabies	Vesicles and papules with rare burrows on the palms, soles, trunk and genitalia	Pruritus, irritability, poor feeding	Mineral oil prep demonstrating mite or eggs	Permethrin cream
HIV	Thrush, widespread seborrheic dermatitis	Bacterial and viral infections	Serology testing, PCR	Zidovudine; anti-retroviral therapy
HSV	Grouped vesicles on red base; diffuse erosions	Ocular and CNS involvement, sepsis	Viral cultures, PCR, Tzanck prep	Intravenous acyclovir
Varicella	Cicatricial dermatomal lesions with hypoplasia (congenital); generalized papules (neonatal)	Ocular and CNS abnormalities	Antibody testing, PCR, Tzanck prep	Varicella-zoster immunoglobulin; acyclovir
Impetigo neonatorum	Pustules, vesicles or bullae on an erythematous base in folds and groin; second week of life	Rarely complicated by sepsis, osteomyelitis and pneumonia	Gram stain with Gram-positive cocci in clusters and neutrophils	Dicloxacillin or cephalixin for a 10-day course
Staphylococcal Scalded Skin Syndrome (SSSS)	Scarlatiniform eruption with erythroderma in intertriginous sites; periorificial crust, +Nikolsky sign, spares mucosa	Irritability, fever, skin tenderness, rhinorrhea	Histology (frozen) with granular layer cleavage; bacterial cultures	β -lactamase-resistant antibiotics; decolonization

Abbreviations: HSM=hepatosplenomegaly; CMV=Cytomegalovirus; HSV=Herpes simplex virus; HIV=Human immunodeficiency virus; CNS=Central nervous system; IUGR=intrauterine growth restriction

DDx of "Blueberry muffin baby": CMV, varicella, zoster, rubella, toxoplasmosis, langerhans cell histiocytosis, syphilis, leukemia cutis, neuroblastoma, parvovirus, hemolytic anemia, twin-twin transfusion, myelodysplasia, rhabdomyosarcoma, neonatal lupus

References:

1. Bologna, Jean, Joseph Jorizzo, and Julie Schaffer. "Chapters 80-81." *Dermatology*. 3rd ed. Philadelphia: Elsevier Saunders, 2012. Page 1321-1366. Print.
2. Cohen, Bernard. "Chapter 2." *Pediatric Dermatology*. 4th ed. Philadelphia: Elsevier Saunders, 2013. 25-39. Print.
3. Schachner, Lawrence, Ronald Hansen. "Chapter 6." *Pediatric Dermatology*. 4th ed. Philadelphia: Elsevier Mosby, 2011. 299-373. Print.

Double the Boards' Fodders online!

In addition to this issue's Boards' Fodder, you can download two new Boards' Fodder online exclusives from www.aad.org. www.aad.org/Directions.

The latest online Boards' Fodders are Sound-alikes in Dermatology by Jeffrey Kushner, DO, and Kristen Whitney, DO; plus Tropical Dermatology: Bacterial and Viral Infections by Kristen Whitney, DO. To view, download, or print every Boards' Fodder ever published, check out the archives at www.aad.org/boardsfodder.

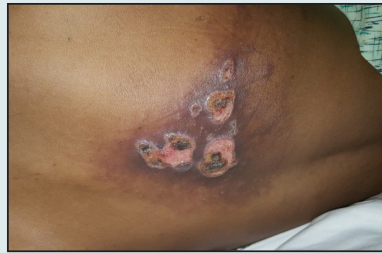
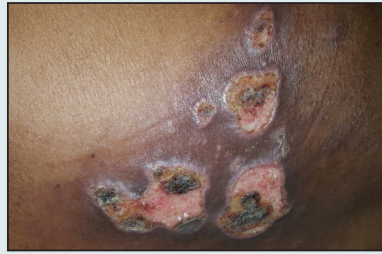
Alina Goldenberg, MD, MAS, is a resident physician, department of dermatology at University of California, San Diego.

Race for the Case: Fall 2016


By Alina Goldenberg, MD, MAS

A 32-year-old African American male presented to the ER with generalized fatigue, and over the previous three months had a 25-pound weight loss along with headaches and a rash on his back. The rash was previously diagnosed as shingles with unclear treatment and worsening progression. The physical exam revealed five non-tender, grouped and coalescing angular ulcers with central hemorrhagic and necrotic crust, and surrounding localized mottled hyperpigmentation. Size of the largest ulcer was 5cm x 5cm. His past medical history is non-contributory, and his social history is remarkable for prior incarceration. His occupation is in construction, and he temporarily resides in Arizona.



1. What is the diagnosis and 3 differentials?
2. Historical snippet: who first described the lesions?
3. What previously off-market skin test can be used for diagnosis?
4. What are the risk factors for this patient?

5. What does this condition have in common with syphilis, sarcoidosis, TB, pulmonary embolus?

Respond online with the correct answers at www.aad.org/RaceForTheCase for the opportunity to win a Starbucks gift card! If you win, we will also publish your mug (face), and if you have an interesting story to tell residents, we might share it (see our current winner profile to the right). Good luck! 

RFTC Winner Profile: Lauren Seline



Lauren Seline, MD

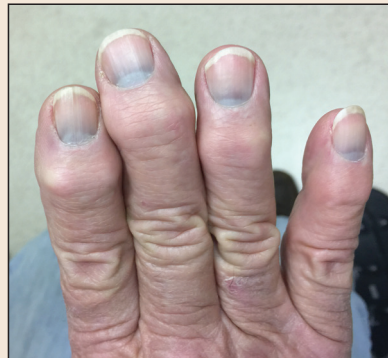Lauren Seline, MD, is a second year resident at the Medical College of Wisconsin in Milwaukee. She attended St. Olaf College in Northfield, Minnesota for undergrad — majoring in biology and chemistry before attending medical school at the Medical College of Wisconsin. Lauren also completed her intern year at Aurora St. Luke's Hospital in Milwaukee. Her hobbies include traveling, biking, running, cross country skiing, cooking/baking, and spending time with her family and friends. In addition, her husband, Darren, and she recently celebrated their second wedding anniversary! They love visiting national parks together and have been to Zion, Yellowstone, and Bryce Canyon since starting residency, and have plans to visit many more! 

Answers to Summer 2016 Race for the Case


Summer 2016 RFTC was submitted by Aman Sandhu, MD — a resident physician at Loma Linda University, dermatology.

A 70-year-old Caucasian man with a history of melanoma presented for his scheduled skin monitoring evaluation. On physical exam, he was noted to have a diffused gray-blue discoloration of his skin and nails. He has been otherwise healthy and does not take medications, with the exception of a natural immune-boosting supplement.

1. Which over-the-counter supplement is the patient likely taking? **Silver salts, consistent with a diagnosis of argyria.**
2. Which topical medication can also cause this finding? **Silver sulfadiazine (if on extensive surfaces).**
3. What is the classic histopathologic finding? **Silver granules**



in the basement membrane and around eccrine glands.


4. What type of microscopy can further support diagnosis? **Silver granules can be highlighted by dark field microscopy.**
5. What other heavy metal can cause a similar presentation if administered parenterally? **Gold, chyriasis.** 

Dr. Kushner: Learn about finance!

A great illusion that financial advisors would have you believe is that finance and investing are complicated. Thus, their business thrives when you trust them to make all your financial decisions. The truth of the matter is that basic finance is not challenging...it's certainly easier than learning genders or random Boards Fodder! The tough part is getting started. Try and read at least one financial book a year (or sections of books that are meaningful to you) or follow a specific financial blog that will get you going on the right track. Nobody cares more about your

money than you do, so it absolutely makes sense to put in the time to understand how financial decisions should be made.

While this article is not nearly enough space to fully review every aspect of debt, I highly suggest going to the website for "White Coat Investor" by visiting www.whitecoatinvestor.com (see page 3). It is the single best financial blog/website that I've found so far regarding all matters of personal finance, including updated information on student loans and refinancing.

Some final words of advice: do your own research, discuss everything with your significant other, and get several opinions from your peers before making any final decisions. 



Plan ahead for boards costs!

Aaron Secret, MD, who recently finished residency and is now a clinical instructor at the University of Utah, said: "My number one piece of advice is to plan for the boards exam. It is \$2,500, plus at least \$500 for the flight/hotel to Tampa. I tell residents to plan on \$3,000 due in winter/spring of their third year. If you save \$100/month from the start of residency, you will have enough to cover everything when it is due. It is ~\$150/month if you wait until the beginning of second year to start saving for it."

An enhanced standard letter of recommendation (SLOR) for dermatology was developed to improve the residency application process and better meet the needs of the dermatology community. A link to a PDF of the new SLOR can be accessed at www.aad.org/members/residents-fellows, under the "for medical students" tab.



HOW MUCH ARE YOU PAYING IN STUDENT LOAN INTEREST?

Learn more about the AAD's new student debt and consolidation provider

- Competitive Rates plus an additional .125% rate discount exclusive to AAD members
- Free to apply, with no commitment
- No fees or penalties
- Both federal and private loans are eligible
- \$100 per month payment during your residency and/or fellowship
- Begin a standard repayment term 6 months after ending training

Start Now!
Visit student.drbank.com/aad.




P R E F E R R E D P R O V I D E R

Apply for a variety of exclusive awards, grants, and scholarships for residents at aad.org/awards.

Message from the Chair



Faranak Kanangar, MD


This past week, I sat for the ABD Board certification exam. For this message, what better topic to discuss than the boards! This test is quite anxiety-provoking for most, although it really does not need to be. If you consistently study throughout residency, then this test is very doable. It is important to focus on learning dermatology. The boards will come and go but for the remainder of your career, you will have to be an astute dermatologist.

This test is a marathon, not a sprint, and it is important to start early in your first year. Early on in residency, I focused mainly on reading as much of the Bologna and Andrews textbooks as possible. Other textbooks include *Dermatopathology* by Dr. Elston, *Practical Dermatopathology* by Dr. Rapini, and *Hurwitz Clinical Pediatric Dermatology*. Coming up to in-service examinations and the boards, personally, I focused on boards directed studying, using the Dermatology in Review question bank, *Dermatology: Illustrated Study Guide and Comprehensive Board Review* by Sima Jain, and lectures from our faculty. For the boards, I also purchased BoardVitals; this was not absolutely necessary, but is a resource for more practice questions. I cannot emphasize koda-chromes enough. Dermatology is a visual field, and if you do not recognize the photo, you will not be able to answer the question. Utilize your dermpath rotations and become

familiarized and comfortable with the scope for the dermatopathology section of the exam.

There is a lack of study questions available to dermatology residents. Hopefully the Dermatology in Review question bank will continue to be funded. The AAD is also currently working on a platform to offer practice questions for residents, so stay tuned! Given the high anxiety associated with this exam, and the lack of available resources, some residents and programs use study resources and questions that may be in violation of the American Board of Dermatology. One of the most important pieces of advice that I will offer is: *do not do this*. To the new residents, if you are offered any such study aids, for your benefit, politely refuse. Use of these materials can result in serious repercussions from the ABD, including not being able to sit for the board examination and obtaining board certification. You have all worked very hard to get to this stage of your career, and it is just not worth it.

There are plenty of good options for study, including the more than 60 Boards Fodder charts offered through the AAD's *Directions in Residency*!

On a lighter note, I would like to conclude by congratulating everyone who just completed the board examination, and best of luck to all of you who will be taking this test next year. Happy studying! 

ZO Skin Health Inc. by Zein Obagi, MD,
proudly supports the
American Academy of Dermatology
and the *Directions in Residency* newsletter.

ZO SKIN HEALTH INC
— BY ZEIN OBAGI MD —

American Academy of Dermatology Association
P.O. Box 4014
Schaumburg, Illinois 60168-4014



Fall 2016

Residents / Fellows Committee

Faranak Kamangar, MD, <i>chair</i>	2017
Mallory Shiver, MD, <i>physician reviewer</i>	2018
Kathleen M. Casamiquela, MD	2017
Macey Renault Delcambre, MD	2017
Dana L Ellis, MD	2017
Sarah B Koch, MD	2017
Nikita Lakdawala, MD	2017
Nicole Yar-Lute Lee, MD	2017
Khang Nguyen, MD	2018
Bethanee Jean Schlosser, MD, PhD, <i>chair, Young Physicians Committee</i>	2017
Meredith Wagner, MD	2018
Eric Wilkerson, MD	2017
Xiaolong Zhou, MD	2017

Managing Ed., Special Publications: Dean Monti

Staff Editor: Danielle Piquette

Senior Graphic Designer: Theresa Oloier

Associate Director, Publishing: Katie Domanowski

Director, Creative and Publishing: Lara Lowery

AAD Staff Liaison: Cindy Kuhn,

Senior Dir., AAD Membership