

# Central Venous Catheter Placement: Modified Seldinger Technique

**Keysa Williams, DVM, ACVECC Resident  
& Andrew Linklater, DVM, DACVECC**

*Lakeshore Veterinary Specialists  
Glendale, Wisconsin*

A central venous catheter (CVC) is a large diameter catheter that can be placed in the jugular or peripheral vein. CVCs can be indicated for various procedures, including central venous pressure monitoring, blood sampling, parenteral nutrition, and IV fluid and hypertonic solution administration.<sup>4</sup> The following focuses on CVC placement using the modified Seldinger technique, a common indication in veterinary patients.

The original Seldinger technique was developed by radiologist Sven Ivar Seldinger in 1953 to allow large-bore catheter placement in peripheral arteries for angiography. Before the Seldinger technique, this procedure required a large-bore needle (through which a narrower bore catheter was threaded), restricting its use to larger arteries and making vessel puncture more difficult.<sup>1</sup>

## Original Seldinger Technique

The Seldinger technique's addition of a flexible, round-ended, metal leader (guidewire) was unique.<sup>1</sup> The sequence included needle puncture, guidewire threaded through needle, needle removed, flexible catheter threaded over guidewire, and guidewire removed.<sup>1</sup> This process enabled a catheter of the same bore as the needle to be inserted percutaneously, rather than requiring surgical exposure or a large bore needle.

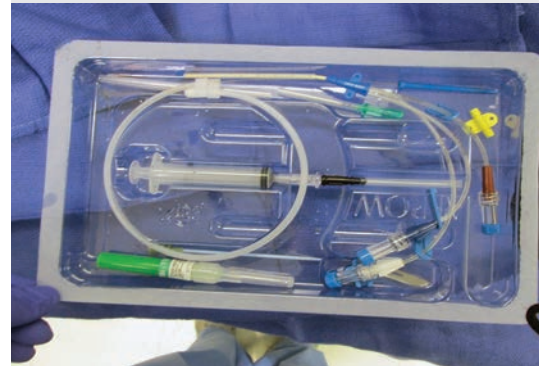The original Seldinger technique has been associated with several complications including inadvertent catheter placement into the internal thoracic vein, azygous vein, and caudal vena cava.<sup>2</sup> Perforation of vessels and/or the right atrium has also been reported.<sup>2</sup> Patency of the central venous system should not be considered sufficient evidence of adequate placement.<sup>2</sup> Radiography should always be performed to confirm appropriate placement.

## Modified Seldinger Technique

The modified Seldinger technique allows for placement of large-bore catheters in jugular veins, the pleural space, pulmonary arteries, and even hollow organs. It is also often used to place dialysis catheters. The primary modification was to use an introducer catheter (rather than a needle) to minimize entering other vessels. Other modifications have included the use of peel-away catheters and variation in stylet, catheter, and wire materials and lengths. Placement of CVCs using the modified Seldinger technique is commonly performed in veterinary patients.

## Complications & Considerations

Complications associated with CVCs include embolism, thrombosis, infection, migration or loss of the guidewire, and mechanical complications (eg, kinking, catheter



## What You Will Need

- Catheter placement kit that includes:
  - 18-gauge, 1.5-inch catheter (of appropriate size for patient)
  - Multilumen or single lumen over-the-wire catheter (of appropriate size and length for patient)
  - Guidewire
  - Vessel dilator
  - Scalpel blade (#10 or #11)
  - 6-mL syringe
  - Suture wings and suture wing clips
- Chlorhexidine 2% scrub
- Alcohol
- Sterile gloves and drapes
- Nonabsorbable suture (2-0 or 3-0 nylon)
- Bandage material
- Syringes with heparin saline flush
- Scissors, needle driver, and thumb forceps
- Clippers

continues

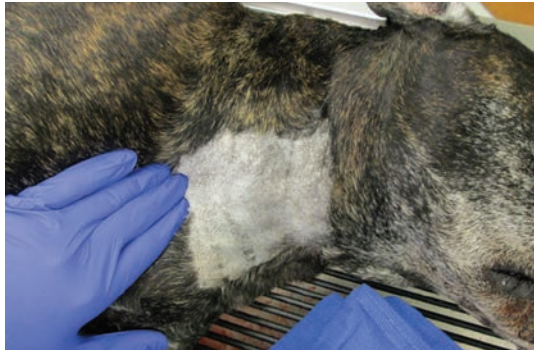fracture, catheter removal by the patient). The most common types of bacteria associated with catheter infections are *Streptococcus* spp, *Staphylococcus* spp, *Escherichia coli*, and *Enterobacter* spp.<sup>3</sup> Appropriate sterility (ie, surgical scrub, drapes, cap,

mask, gloves) must be maintained. Wearing gloves during catheter manipulation and keeping the bandage around the site clean and dry are appropriate measures to decrease risk for catheter-associated infections.

**STEP-BY-STEP ■ PLACING A CENTRAL VENOUS CATHETER USING THE MODIFIED SELDINGER TECHNIQUE**

**STEP 1**

**Author Insight**  
Appropriate sterility (surgical scrub, drapes, cap, mask, and sterile surgical gloves) must be maintained when placing a central venous catheter.

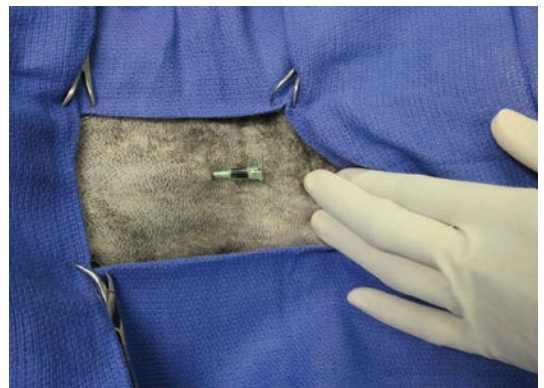
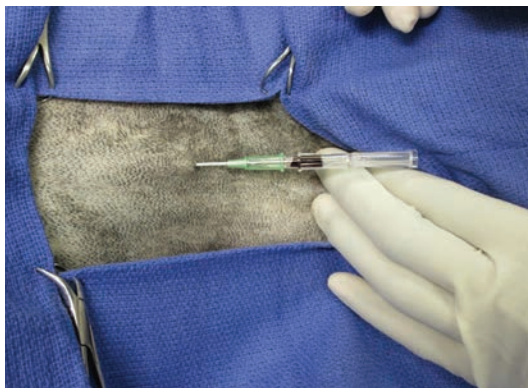

Place the patient in lateral or dorsal recumbency and identify the jugular vein. Mild to moderate sedation is often sufficient, although some patients may require general anesthesia. Appropriate monitoring is always required. Arrhythmias are possible, as the guidewire and/or catheter may be inadvertently advanced into the heart, making electrocardiogram monitoring essential. Prepare the site aseptically using surgical scrub technique with 2% chlorhexidine scrub alternating with alcohol.

Once the patient is scrubbed, secure a sterile field using either a 4-corner drape technique (with towel clamps) or a small drape. Premeasure the length for placement of the multilumen catheter. Ideal placement is between the third and fourth ribs, depending on the catheter's intended use.

**STEP 2**

**Author Insight**  
Patients with veins that are difficult to catheterize may need a facilitative (cut down) or surgical approach to the vessel.

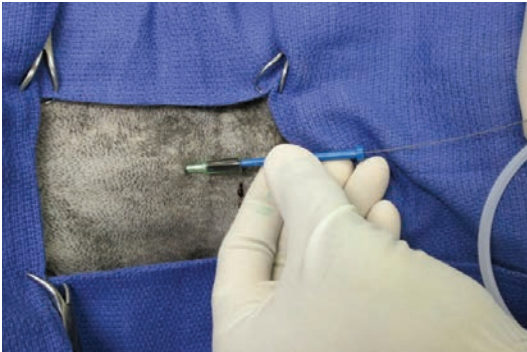


Have the assistant occlude the jugular vessel underneath the drape. Make a stab incision through the skin, and insert the catheter percutaneously, directed toward the heart, until a flash of blood is observed in the stylet. Once blood is noted, advance the catheter into the vein until the hub reaches the skin, then remove the stylet.

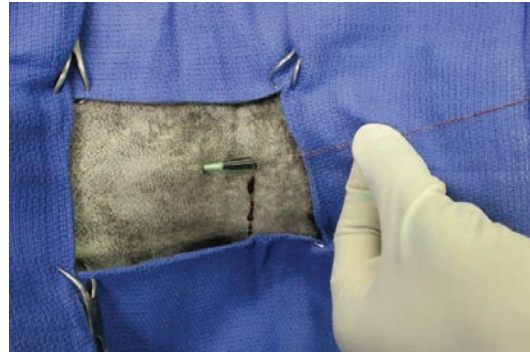
A facilitative (cut down) or surgical approach to the vessel may be needed in patients with veins that are difficult to catheterize.

CVC = central venous catheter

### STEP 3



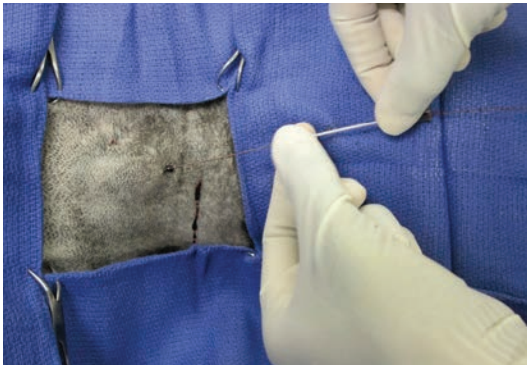Place the guidewire in the hub of the catheter and advance the wire, ensuring it is inserted deeply into the vessel and at least one catheter length outside of the body, being careful to keep the remaining guidewire in the sterile field at all times.



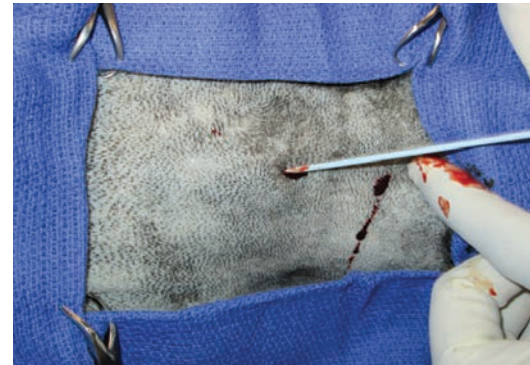
Once the guidewire has been advanced into the appropriate location, remove the guidewire cap and booster from the sterile field, but be careful not to release the grip on the guidewire.

**Author Insight**  
**Arrhythmias are possible, as the guidewire and/or catheter may be inadvertently advanced into the heart, making electrocardiogram monitoring essential.**

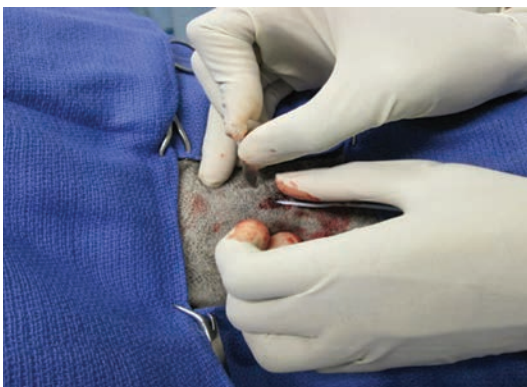### STEP 4



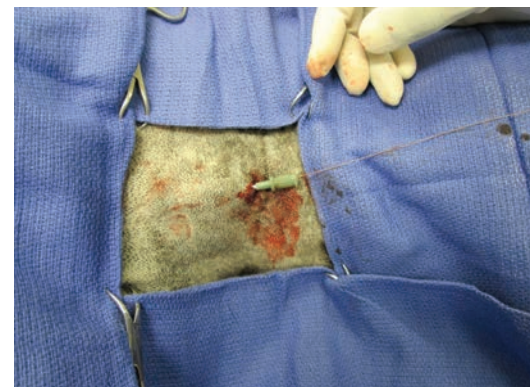
When the guidewire is in place, remove the catheter from the vessel without letting go of the wire. Use digital pressure to avoid excessive hemorrhage.



Slide the vessel dilator over the guidewire and into the vessel.



If passage of the vessel dilator through the skin is problematic, use a scalpel blade to perform a cut down.



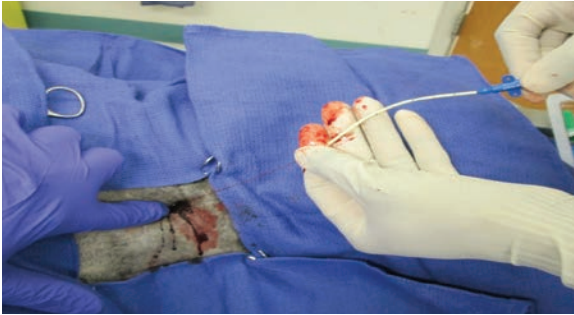Advance the vessel dilator until the hub touches the skin.

continues

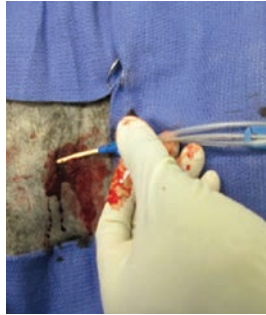
**Author Insight**

**The guidewire must be manually fed through the catheter and exit the distal port so it can be grasped before the catheter is advanced through the skin (so the guidewire is not lost into the patient's vessel).**

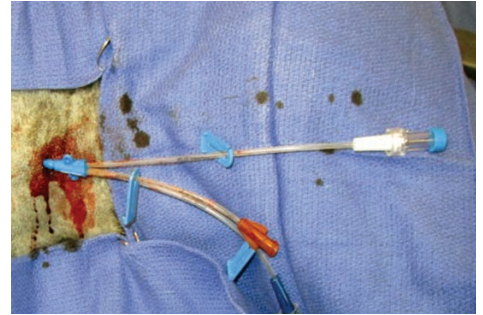
**STEP 5**



Slowly remove the vessel dilator. Because the dilator will have enlarged the opening into the vessel, hemorrhage will occur. To limit hemorrhage, an assistant—wearing sterile gloves with or without sterile gauze pads (not shown)—should apply digital pressure over the area. Once the dilator is removed, thread the multilumen catheter over the guidewire.



Remove the injection cap on the most distal port of the catheter so the guidewire can exit.

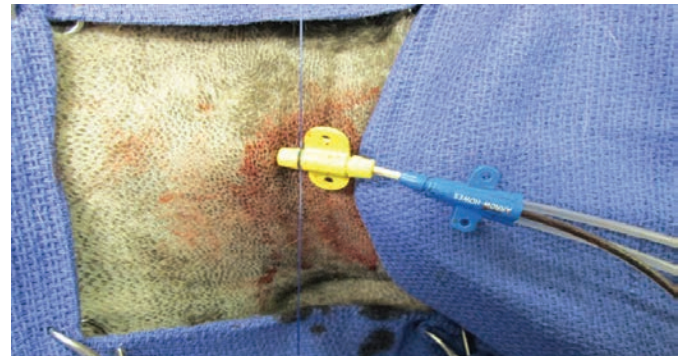
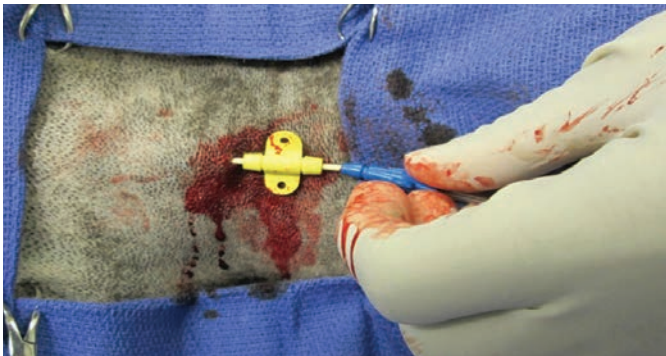
Feed the guidewire through the catheter and out the distal port, and grasp the wire to prevent it from becoming lost in the vessel before advancing catheter through the skin. Advance the catheter into a predetermined location while slowly removing the guidewire. Care must be taken not to remove the guidewire from the vessel until advancement has occurred, although it may need to be threaded through the catheter to allow advancement.

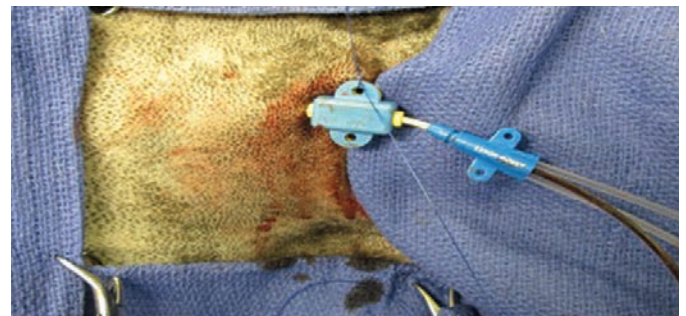
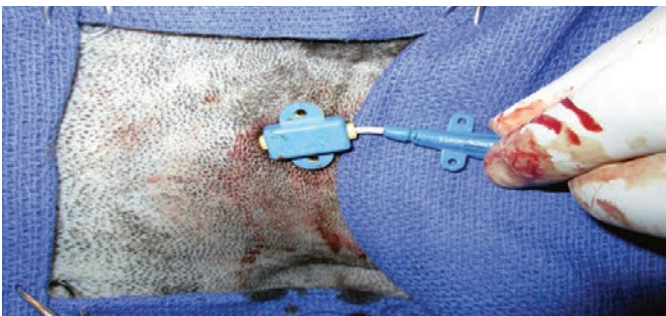**Author Insight**

**The vessel dilator enlarges the opening into the vessel, so hemorrhage will occur; digital pressure will limit blood loss and hematoma formation.**

**STEP 6**

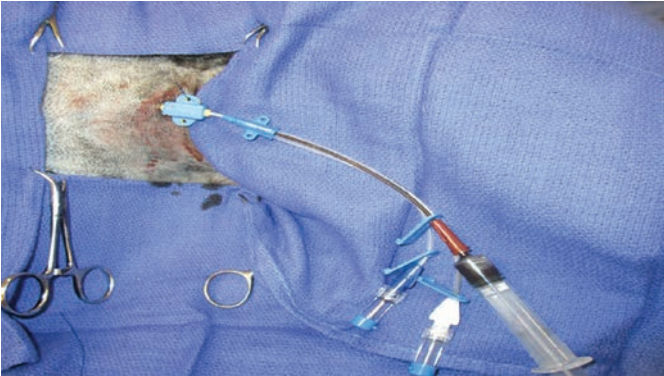


If the catheter cannot be advanced to the hub, use suture wings (blue) to prevent catheter migration. Attach the suture clip (yellow) to the exposed portion and secure it over the catheter using nonabsorbable suture.

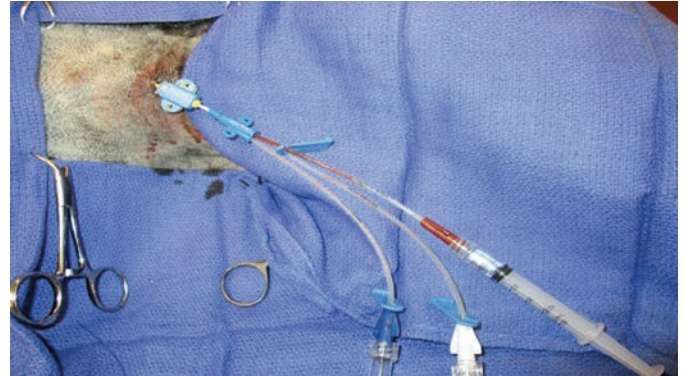


Place the suture wing over the clip and suture it to the patient's skin.

## STEP 7

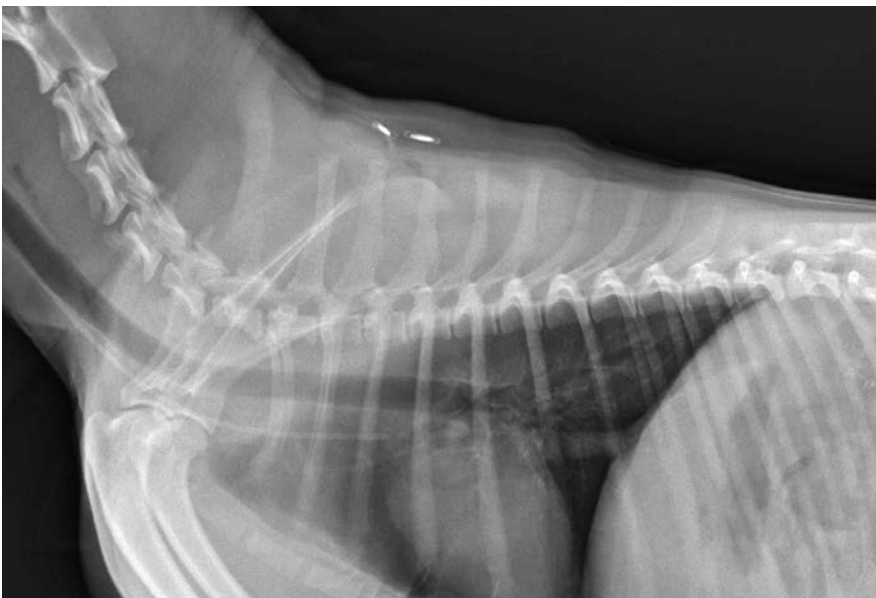


Once the sutures have been placed, aspirate the catheter from each port to remove air and ensure functionality.



Flush the catheter with heparinized saline to prevent clotting. An assistant can simultaneously flush the catheter during suturing (ie, steps 5 and 6).

## STEP 8



Acquire a radiograph to confirm the catheter is between the third and fourth rib space, cranial to the heart. Once placement is confirmed, suture the remaining suture wings to the patient to provide stability to the catheter. Place a light bandage around the neck to protect the catheter; inspect the catheter site at least once daily and any time there is patient deterioration that could be attributed to infection. Always wear sterile examination gloves when collecting samples from or manipulating the catheter.

■ cb

### Author Insight

**Placement of the tip of the catheter between the third to fourth rib space will ensure the catheter may also be used for central venous pressure measurement.**

### References

1. **The Seidinger technique: 50 years on.** Higgs ZCI, Macafee DAL, Braithwaite BD, Maxwell-Armstrong CA. *Lancet* 366:1407-1409, 2005.
2. **Radiologic interpretation of central venous catheter placement.** Gendron K, Francey T, Adami C, Geissbühler U. *Compend Contin Educ Pract Vet* 35:E4, 2013.
3. **Surveillance of infections associated with intravenous catheters in dogs and cats in an intensive care unit.** Marsh-Ng ML, Burney DP, Garcia J. *JAAHA* 43:13-20, 2007.
4. **Catheterization of the venous compartment.** Campbell MT, Macintire DK. In Burkitt Creedon JM, Davis H (eds): *Advanced Monitoring and Procedures for Small Animal Emergency and Critical Care*. Chichester, UK—Wiley-Blackwell, 2012, pp 51-68.