

CLINICAL VIEW


# CHRONIC ULCERATIVE PARADENTAL STOMATITIS OF DOGS

---

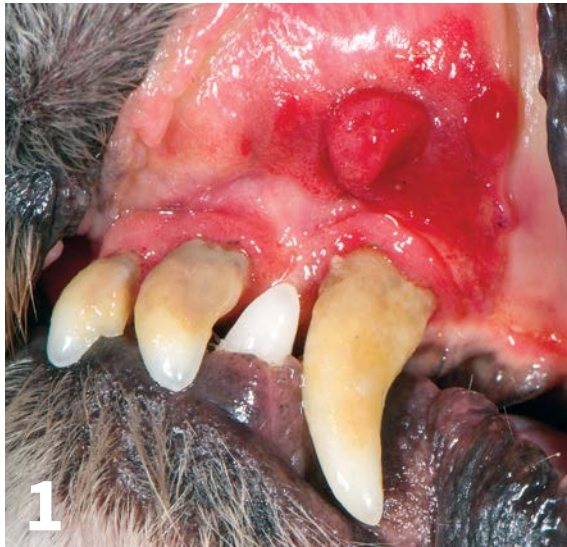**Jan Bellows, DVM, FAVD, DAVDC, DABVP**

*All Pets Dental*

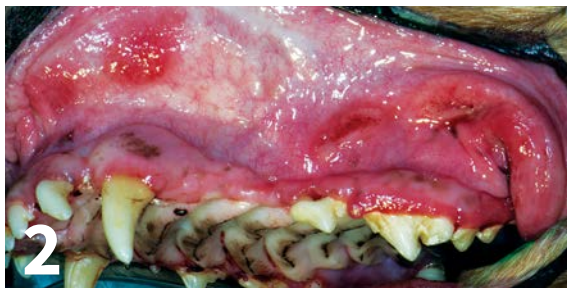
*Weston, Florida*

A close-up photograph of a dog's mouth, showing severe gingivitis and ulceration. The gingiva is highly inflamed, appearing bright red and swollen. There are significant areas of ulceration and necrosis, particularly around the teeth. The teeth themselves appear yellowish and are surrounded by a thick, dark, crusty material, likely plaque and calculus. The overall appearance is one of severe oral disease.

**C**hronic ulcerative paradental stomatitis (CUPS)—also known as ulcerative stomatitis, idiopathic stomatitis, lymphocytic plasmacytic stomatitis, and plaque-reactive stomatitis—is a painful and often debilitating disease involving mucosal areas that contact plaque and calculus in predisposed dogs.



▲ Marked labial inflammation with granuloma formation secondary to plaque mucosal contact against the left maxillary canine and third incisor.



▲ Contact mucositis with ulceration secondary to plaque- and tartar-laden maxillary incisors, canines, premolars, and molars.

*Paradental* refers to the mucous membranes on the inside of the lips and cheeks, palate, and tongue.<sup>1</sup> The inflammatory lesions do not include the teeth and rarely include the attached gingiva unless accompanied by periodontal disease. The syndrome's appearance results in the term *kissing lesions* because the injuries are located where the oral mucous membranes rub against the plaque- and calculus-laden teeth (*Figure 1*).<sup>2</sup>

CUPS = chronic ulcerative paradental stomatitis

### Additional Terminology

Because the syndrome affects companion animals, is usually not chronic or ulcerative, and rarely affects the entire mouth, it was given the name *contact mucositis* and *contact mucosal ulceration* by the American Veterinary Dental College (AVDC) in 2013.<sup>3</sup> The AVDC concluded:

*Contact mucositis and contact mucosal ulceration are lesions in susceptible individuals that are secondary to mucosal contact with a tooth surface bearing the responsible irritant, allergen, or antigen. They have also been called “contact ulcers” and “kissing ulcers.”<sup>3</sup>*

Even the terminology *contact mucositis*, however, is confusing in companion animal practice. In human dentistry, *contact mucositis*<sup>4</sup> refers to contact with something ingested that inflames the gingiva because of an allergic reaction. In veterinary practice, affected patients (usually dogs) are generally immune-compromised and develop a hyperimmune mucosal response in the tissues that physically touch plaque (*Figure 2*).<sup>1</sup>

### Examination and Progression

Histopathological examination of lesions should show a population of lymphocytes and plasmacytes, confirming that the syndrome is inflammatory rather than infectious.<sup>1</sup> The antigens in bacterial plaque are theorized to be the stimulants.<sup>1</sup>

At syndrome onset, gingivitis is usually present around the teeth that touch the inflamed alveolar mucosa. If untreated, the gingivitis often progresses to periodontal disease. Areas of gingival recession with root exposure appear to be more prevalent in these cases, exacerbating inflammation and pain.

Examination is often difficult without general anesthesia; most affected patients experience significant pain on manipulation of the oral mucosa. In dogs and cats, the mucosa apical to the maxillary canines and fourth premolars are the most likely to be involved.<sup>4</sup> They exhibit marked

inflammation with or without ulceration and necrosis. In general, the vestibular mucosa in areas that contact tooth surfaces are also affected (*Figure 3*).

### Breeds Prone to CUPS

Any dog can be affected by contact mucositis. There may be a genetic predisposition to the syndrome, especially in the Maltese dog, greyhound, Cavalier King Charles spaniel, and the Scottish terrier.<sup>4</sup>

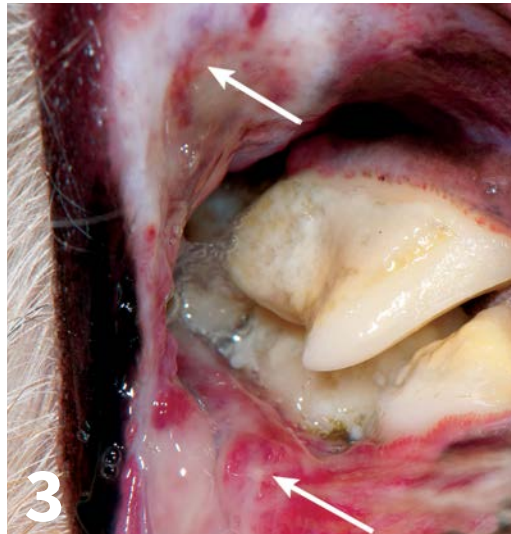
### Clinical Signs

Signs include marked halitosis; ptyalism with thick, ropy, and occasionally bloody saliva (*Figure 4*); pain in and around the mouth; and difficulty prehending hard food and chew toys, especially in cases where the lateral mucosal surfaces of the tongue are eroded from contact with lingual mandibular surfaces (*Figure 5*).

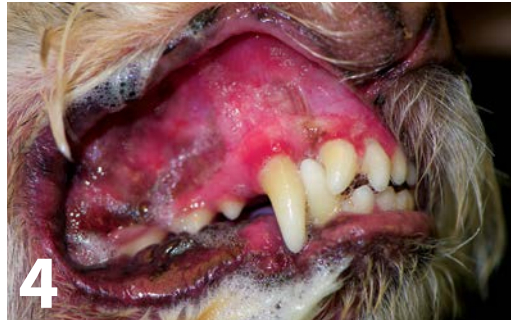Visual examination findings include inflamed mucosal gingiva where contact is present, ulceration with formation of a pseudomembrane, and mucosal necrosis. At times, the paradental infection is so marked that the necrotic buccal mucosal damage extends through the skin. This is in contrast to periodontal infection that affects the socket holding the tooth—the cementum, periodontal ligament, alveolar bone, and gingiva. Patients may have both contact mucositis and periodontal disease (*Figures 6 and 7*, next page).

### Mimics and Diagnosis

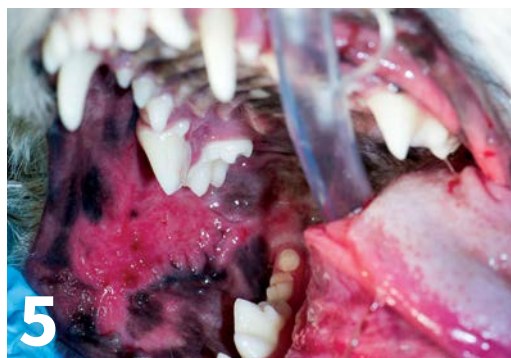Diagnosis can be made visually where mucosal lesions lie directly against plaque- and tartar-encrusted exposed tooth root surfaces. Differential diagnoses include azotemia and autoimmune diseases (eg, mucous membrane pemphigoid, systemic lupus erythematosus, bullous pemphigoid, erythema multiforme, epidermolysis bullosa). Histologic examination of a wedge biopsy is generally diagnostic. Autoimmune bullous diseases are characterized by subepithelial clefting. Contact mucositis lesions typically show plasmacytic and lymphocytic infiltrates.



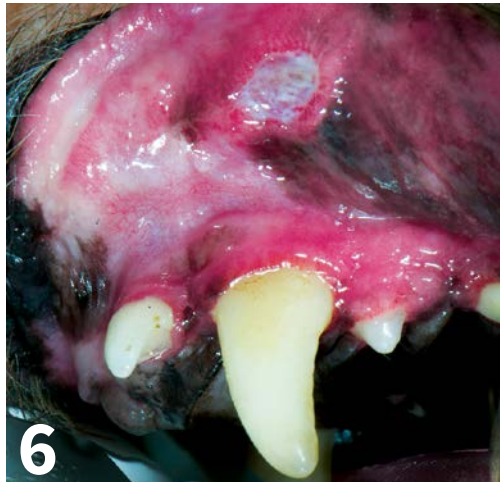▲ Swelling, ulceration, and marked inflammation (**arrows**) of the vestibular mucosa caused by plaque and tartar on the maxillary cheek teeth.



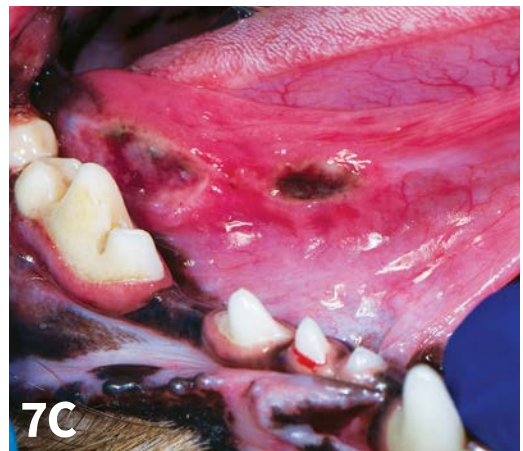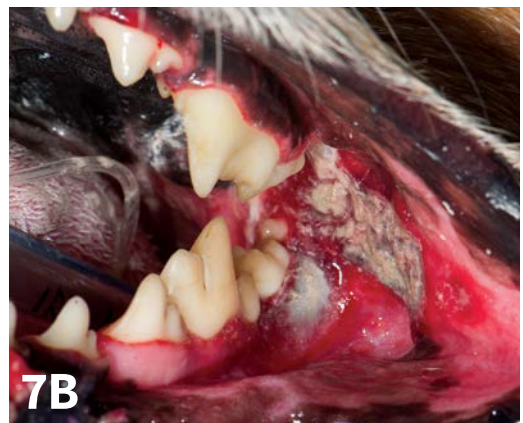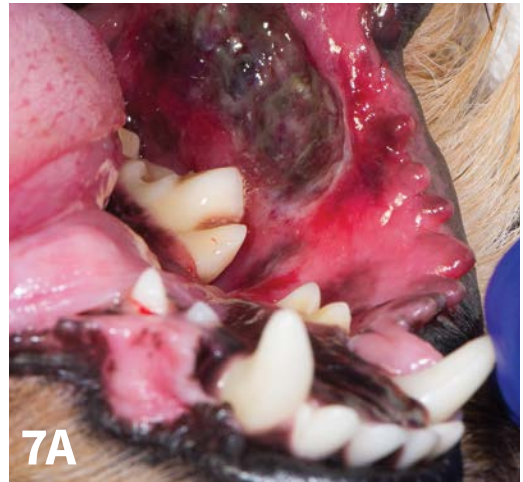▲ Marked ptyalism and gingival inflammation in a Maltese dog affected by contact mucositis.



▲ Buccal mucositis and glossitis secondary to contact mucositis.



▲ Ulcer with fresh fibrinous pseudomembrane.



▲ Marked buccal necrosis with hemorrhage (A), marked pseudomembrane and mucosal necrosis (B), and sublingual ulceration and necrosis (C).

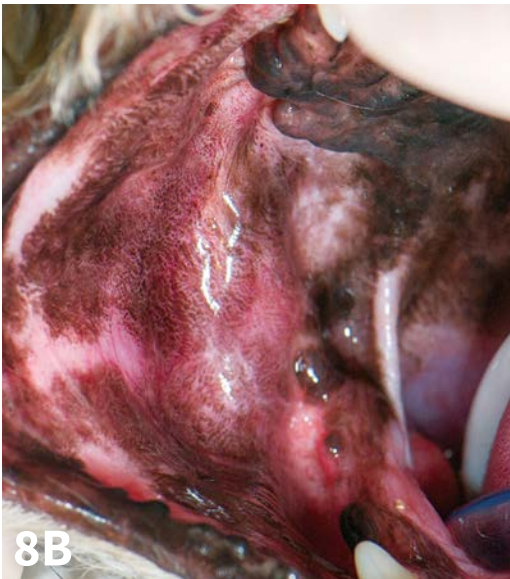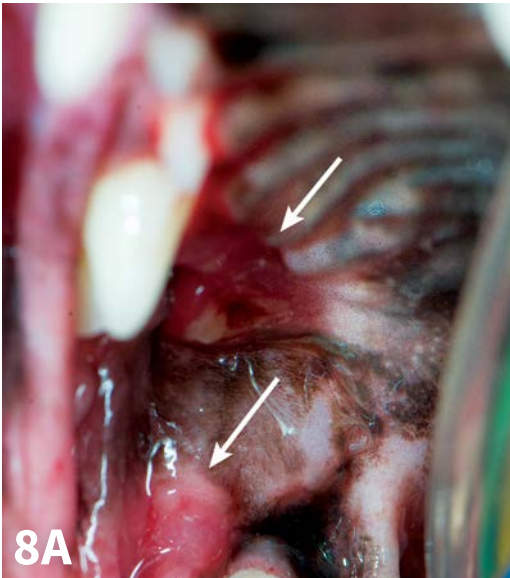
**Treatment**

Preoperative testing (eg, CBC, serum chemistry panel, urinalysis) and a thorough oral examination under anesthesia should be pursued. Elevated total protein and neutrophilia are typical findings in CUPS patients. While the patient is under general anesthesia with intubation, a tooth-by-tooth examination should be conducted, including periodontal probing and intraoral radiographs. The teeth should be thoroughly cleaned above and below the gum line and then polished.

Oral examination findings should be discussed with the clients to consider the best way to tailor patient-specific therapy, which often initially or eventually involves multiple extractions and future plaque-control options.

In these patients, even a small amount of plaque can initiate a painful ulcerative inflammatory reaction. Teeth affected by grades 3 and 4 periodontal disease should be extracted.

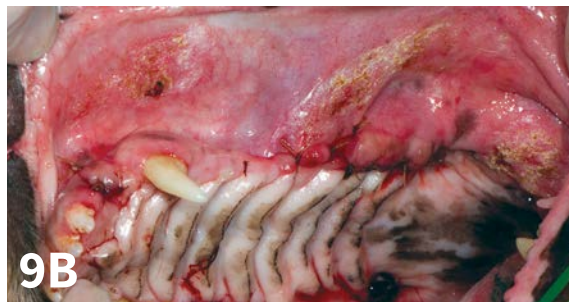
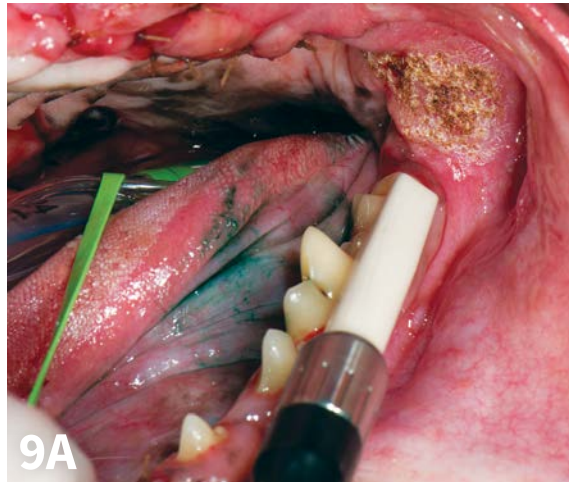
Either a dental sealant applied at the time of anesthesia that lasts 6 months or a waxy polymer applied weekly is recommended to help decrease plaque accumulation in teeth that have not been extracted. Antibiotics approved for dental infections are not



▲ Selective extractions of caudal cheek teeth prompt a cure (A; arrows and B).

indicated as sole therapy. Contact mucositis, even with ulceration, is considered a primarily inflammatory disease and not infectious.

Other medications that have been used in the past with limited success include pentox-

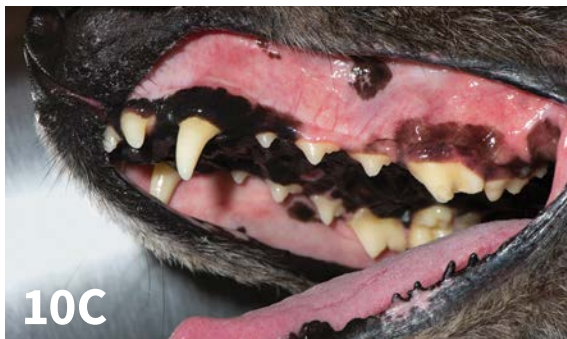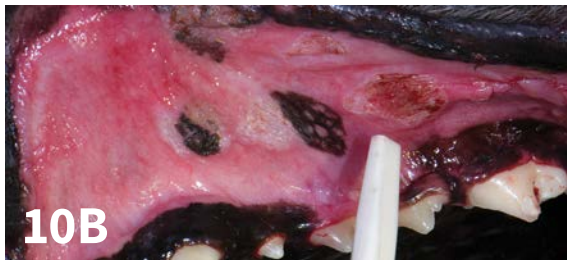
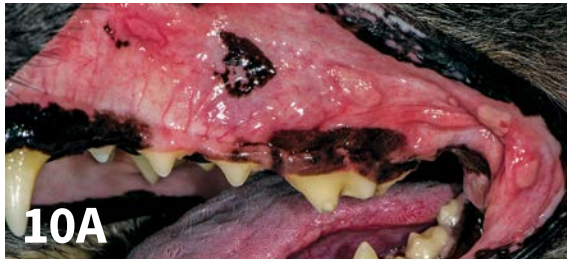


▲ CO<sub>2</sub> laser used in addition to extractions to treat contact mucositis case featured in *Figure 2*.

ifylline to decrease inflammation.<sup>5</sup> Niacinamide may also be helpful. Pain relief is likewise indicated.<sup>5</sup> Pulsed antibiotic therapy (dental-approved antimicrobial administered the first 5 days of each month) is not recommended.<sup>2,5</sup> The use of anti-inflammatory medications in control of CUPS may be helpful but is controversial because the cause of the syndrome (plaque and tartar rubbing against the mucosa) is not addressed.<sup>2,4</sup>

Home care, including teeth brushing twice a day to prevent plaque accumulation *and* extralabel daily application of a plaque gel barrier, may be helpful in controlling mucositis and ulceration.

In advanced cases in which the client cannot provide twice-daily plaque control or if such care



▲ Multiple contact mucositis with ulceration lesions (A), CO<sub>2</sub> laser rastering of the lesions (B), and resolution of mucositis (C).

is not successful, removal of the teeth adjacent to the ulcerated areas or, in some cases, all teeth can result in rapid elimination of inflammation and pain (**Figure 8**, previous page).

The use of the CO<sub>2</sub> laser to photovaporize contact mucositis and mucositis with ulceration lesions has met with favorable results when combined with strict plaque control. The laser should be set between 3 to 6 watts in continuous mode. CO<sub>2</sub> laser treatment of the exposed ulcer surfaces may be beneficial to lessen patient discomfort and aid healing (**Figures 9**, previous page, and **10**).<sup>6</sup> ■

## References

1. Harvey CE, Emily PP. Oral inflammatory and immune-mediated disease. *Small Animal Dentistry*. Mosby-Year Book, St. Louis, MO: Mosby; 1993:145-155.
2. Wiggs RB, Lobprise HB. Clinical oral pathology. *Veterinary Dentistry: Principles and Practice*. Philadelphia, PA: Lippincott-Raven; 1997:104-139.
3. Nomenclature. American Veterinary Dental College. [www.avdc.org/nomenclature](http://www.avdc.org/nomenclature). Accessed October 2015.
4. Contact mucositis. Medscape. [reference.medscape.com](http://reference.medscape.com). Accessed November, 2015.
5. Lobprise HB. Oral ulceration and chronic ulcerative paradental stomatitis. *Blackwell's Five-Minute Veterinary Consult Clinical Companion—Small Animal Dentistry*. 2nd ed. Ames, IA: Wiley-Blackwell; 2012:243-247.
6. Niemiec BA. Practical dentistry canine and feline oral ulcerative disease. *Today Vet Pract*. 2015;4(1).

## Suggested Reading

- Neville BW, Damm DD, Allen CM, Bouquot JE. Periodontal diseases. In: Neville BW, Damm DD, Allen CM, Bouquot JE, eds. *Oral and Maxillofacial Pathology*. 2nd ed. Philadelphia, PA: Saunders; 2002:137-162.
- Niemiec BA. Chronic ulcerative paradental stomatitis. In: Niemiec BA, ed. *Small Animal Dental, Oral and Maxillofacial Disease: A Color Handbook*. London, UK: Manson Publishing; 2010:189-191.
- Boutoille F, Hennet P. Maxillary osteomyelitis in two Scottish terrier dogs with chronic ulcerative paradental stomatitis. *J Vet Dent*. 2011;28(2):96-100.
- Buelow ME, Marretta SM, Barger A, Lichtensteiger C. Lingual lesions in the dog and cat: Recognition, diagnosis, and treatment. *J Vet Dent*. 2011;28(3):151-162.
- Olivry T, Linder KE. Dermatoses affecting desmosomes in animals: A mechanistic review of acantholytic blistering skin diseases. *Vet Dermatol*. 2009;20(5-6):313-326.
- Pedersen NC. A review of immunologic diseases of the dog. *Vet Immunol Immunopathol*. 1999;69(2-4):251-342.
- Olivry T, Jackson HA. Diagnosing new autoimmune blistering skin diseases of dogs and cats. *Clin Tech Small Anim Pract*. 2001;16(4):225-229.
- Olivry T, Dunston SM, Schachter M, et al. A spontaneous canine model of mucous membrane (cicatricial) pemphigoid, an autoimmune blistering disease affecting mucosae and mucocutaneous junctions. *J Autoimmun*. 2001;16(4):411-421.
- Scott DW, Miller WH. Erythema multiforme in dogs and cats: Literature review and case material from the Cornell University College of Veterinary Medicine (1988-1996). *Vet Dermatol*. 1999;10(4):297-309.
- Nemec A, Zavodovskaya R, Affolter VK, Verstraete FJ. Erythema multiforme and epitheliotropic T-cell lymphoma in the oral cavity of dogs: 1989 to 2009. *J Small Anim Pract Vet*. 2012;53(8):445-452.
- Olivry T, Bradley G. Diseases of the oral mucosa. *Can Fam Physician*. 1988;34:1443-1451.