

Allergic Dermatitis in a Puppy: More Than Meets the Ear

Jennifer Schissler Pendergraft, DVM, MS, DACVD
Colorado State University

Beignet, a 3-month-old, 10-kg, castrated Chinese shar-pei, presented for a 1-month history of scratching his ears, neck, and chest along with excessive licking of his forelimbs.

History

On a scale of 0 to 10, with 0 representing minimal pruritus and 10 representing severe, constant pruritic behaviors, the client reported a score of 7.

The patient's diet consisted of a commercial chicken and rice-based dry food with occasional table scraps. He received monthly heartworm prevention (ivermectin 0.006 mg/kg PO) but not flea control. Vaccines were up-to-date. Beignet was primarily an indoor dog with outdoor access to groomed, grassy areas. The other nonrelated pet in the home, a 10-year-old spayed shar-pei, was not pruritic.

Physical Examination

The patient was bright, alert, and responsive. His heart rate, temperature, and respiratory rate were within normal limits. Cardiac and thoracic auscultation and abdominal palpation were unremarkable.

Cutaneous examination revealed diffuse alopecia, erythema, hyperpigmentation, papules, crusts, and mild lichenification of the ventral neck and chest. The distal forelimbs were diffusely erythematous with mild alopecia.

The ear canals were palpably firm and pliable, and pain was elicited during external manipulation. The pinnal-pedal reflex was negative. Otoscopic examination revealed bilateral moderate erythema and severe stenosis of the horizontal ear canals with purulent exudate (**Figure 1**, next page).

Diagnostics

Deep skin scrapings of the ventral neck and chest were negative for *Demodex* spp. Superficial skin scrapings of the neck and chest were negative for *Sarcoptes scabiei*. Acetate tape cytologic samples of the ventral neck and chest revealed 10 to 20 rods and 5 to 10 *Malassezia* spp per high power field (hpf).

Cytologic samples from beneath crusts on the ventral neck and chest showed neutrophils and 3 to 10 intracellular and extracellular cocci/hpf. Cytology of the right ear was positive for 20 to 50 rods/hpf and 10 to 20 cocci/hpf. Cytology of the left ear was positive for 10 to 20 cocci/hpf. Mite preparation of ear exudate was negative.

hpf = high power field

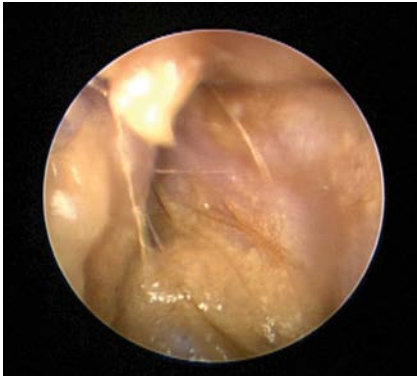


Ask Yourself

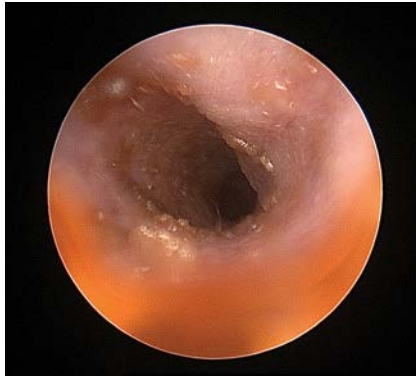

1. What is your differential diagnosis for this dermatitis and otitis presentation?
2. Which diagnostic would you perform next?
3. Which topical otic ingredients are considered safer to use if a tympanic membrane is ruptured?
4. How would you treat the otic stenosis?

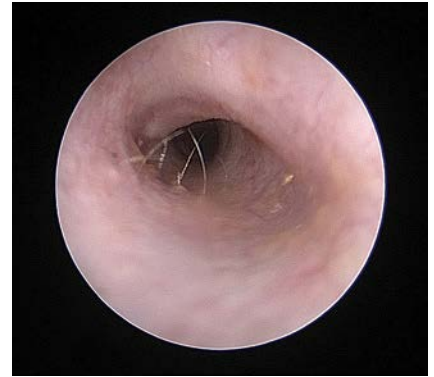continues



1 On presentation, stenosis of the horizontal canal with purulent exudate was noted during otoscopic examination in a 3-month-old shar-pei.



2 At the first recheck (2 weeks after initiation of treatment), the dog's ear was erythematous with mild hyperplasia and ceruminous exudates. The breed-related narrowness of the ear canal in addition to discomfort precluded a complete view of the tympanic membrane without anesthesia.



3 Eight weeks after initial presentation, the otitis externa had resolved and the tympanic membrane could be visualized.

Diagnosis

Cutaneous adverse food reaction

Preliminary Diagnosis

A preliminary diagnosis of allergic dermatitis and allergic otitis externa was made based on the lack of overt causes of otitis (eg, ticks, mites, tumor) as well as the findings of superficial staphylococcal folliculitis, *Malassezia* spp dermatitis and bacterial overgrowth of the neck, and bacterial and yeast otitis externa with stenosis.

Treatment

The following treatment plan was recommended for Beignet's bacterial and yeast dermatitis:

- Cephalexin 25 mg/kg PO q12h until recheck
- Miconazole (2%)–chlorhexidine gluconate (2%) shampoo twice weekly
- Ketoconazole (1%)–chlorhexidine gluconate (2%)–acetic acid (2%) wipe applied to the neck and chest once daily

The following treatment plan was recommended for otitis externa with stenosis:

- Prednisolone 1 mg/kg PO q24h until recheck. The client was informed that prednisolone might result in temporary shrinking of the muzzle and wrinkles, because of reduced hyaluronic acid production. The characteristic skin wrinkles and muzzle appearance of the shar-pei breed are secondary to cutaneous mucinosis.
- Enrofloxacin (0.5% w/v)–silver sulfadiazine otic (1.0% w/v) emulsion 0.3 mL applied q12h for 1 week, then q48h until recheck.

- Fluocinolone acetonide (0.01%)–dimethyl sulfoxide (DMSO; 60%) otic solution: 5 drops q48h.

A restrictive diet trial was instituted with a prescription dry venison and potato diet, approved for growing puppies. The canned formula was provided for hiding pills, and treats were limited to cooked potato.

A monthly topical spot-on containing moxidectin (2.5%) and imidacloprid (10%) was recommended for heartworm control to replace the flavored chewable. Flavored medications and supplements should be replaced with non-oral or non-flavored formulations during an elimination diet trial because many products include animal- and plant-derived proteins that may be allergenic.

A recheck was recommended in 10 to 14 days.

Outcome

Recheck 1

Beignet's pruritus score was 2/10. The owners reported mild polyuria/polydipsia and polyphagia. Crusting and papular dermatitis were nearly resolved. The ventral neck, chest, and distal forelimbs were mildly alopecic and erythematous. The muzzle was approximately 30% reduced in size.

The ears were normal on palpation. Stenosis of the horizontal canal was mild for the breed with mild hyperplasia. Yellow-brown ceruminous exudate and medication were present, preventing complete visualization of the tympanic membranes (**Figure 2**).

Repeat cytology of the ears revealed occasional rods and cocci. The restrictive diet trial was continued, and cephalexin was continued for 1 additional week. Prednisolone at 0.25 mg/kg PO q48h was continued for 2 additional weeks.

The shampoo and wipes were maintained twice weekly. Flushing the ear canal with a Tris-EDTA product twice weekly was prescribed to remove exudate and enhance the antibacterial effect prior to application of the enrofloxacin–silver sulfadiazine emulsion. Fluocinolone–DMSO otic solution was also continued twice weekly with instructions to discontinue 1 week prior to the next recheck, which was recommended in 4 weeks.

Recheck 2 & Beyond

At the second recheck, 8 weeks after initial presentation, Beignet's pruritus score was 0. Mild hypotrichosis was present on the neck. The ears were nonpainful and pliable on palpation. The ear canals demonstrated scant erythema. Tympanic membranes

were visualized and normal (Figure 3).

Repeat cytology of the ears revealed no etiologic agents.

A tentative diagnosis of cutaneous adverse food reaction was made. However, the seasonality of the pruritus was unknown given the young age of the patient. Therefore, the possibility remained that maintenance of a clinically normal ear upon discontinuation of antiinflammatory therapy may have been the result of a season change in an atopic patient rather than improvement because of the elimination diet.

Re-challenge of the diet elimination trial with the patient's original diet after week 8 was performed to confirm cutaneous adverse food reaction. Pruritus and otitis returned several days after feeding of the previous diet. The strict diet was resumed and pruritus once again resolved within 2 weeks. No further treatment was required.

Did You Answer?



1. The most likely differential for this combination of signs is allergic dermatitis (cutaneous adverse food reaction or atopic dermatitis). Differentials for bilateral otitis externa in puppies include *Otodectes cynotis*, *Otobius megnini*, plant material foreign bodies, and possibly secondary bacterial and *Malassezia* spp dermatitis. Sarcoptic mange may cause pruritus of the pinnae but is not typically associated with otitis externa. Otodermoidosis may also occur in the context of canine generalized demodicosis.

The most common cause of otitis externa in dogs is allergic dermatitis. Although this condition commonly manifests initially in dogs 1 to 3 years of age, patients younger than 1 year of age may develop signs. Shar-peis with allergic dermatitis have been documented to develop clinical signs at a younger age than other breeds. A recent review revealed that 44% of shar-peis with allergic dermatitis demonstrate clinical signs at less than 6 months of age.¹

The most common causes of crusting dermatitis in a young dog include demodicosis, dermatophytosis, and staphylococcal bacterial folliculitis.

Differentials for pruritus in this patient include allergic dermatitis, flea allergy dermatitis, secondary bacterial or *Malassezia* spp dermatitis, and sarcoptic mange. Patients with sarcoptic mange are typically severely pruritic with involvement of the ventrum, hocks, elbows, and/or

pinnae. Of note, at least 50% of patients with sarcoptic mange will have a negative superficial skin scraping.² If clinical signs are consistent with sarcoptic mange, treatment is recommended to definitively rule out this condition.

2. Cutaneous adverse food reaction and nonseasonal canine atopic dermatitis are clinically identical. A proper history and a well-executed elimination diet trial are necessary for an accurate diagnosis. Beignet did not have the classic extreme pruritus, nor did he have involvement of some of the classic locations (hocks, pinnae) for sarcoptic mange. Therefore, sarcoptic mange was not considered highly as a differential. Nevertheless, imidacloprid–moxidectin is an effective topical treatment for sarcoptic mange³ as well as a nonflavored heartworm preventive that is appropriate for an elimination diet trial.

3. Reports regarding the safety and adverse effects of topical otic medications in dogs are lacking. If the tympanic membrane is absent or damaged, there may be an increased likelihood of medication-induced ototoxicity involving the vestibulocochlear nerve in the inner ear (deafness, vestibular syndrome), facial nerve in the middle ear (facial nerve paresis or

Of note, at least 50% of patients with sarcoptic mange will have a negative superficial skin scraping.²

continues

paralysis), and sympathetic nerve in the middle ear (Horner syndrome). If the tympanum is damaged, infection can also involve the middle and inner ear causing the aforementioned signs.

Aminoglycosides, namely gentamicin, are associated with ototoxicity (hearing loss), particularly when administered systemically. However, ototoxicity caused by topical application appears to be unpredictable and is suspected to be non-dose dependent, although this is not well documented in the literature. In one study, ototoxicity could not be induced experimentally with instillation of gentamicin directly into the tympanic cavity of dogs.⁴ Commercially available ingredients and products that are generally considered safe in the presence of a ruptured tympanic membrane include Tris-EDTA, squalene, fluoroquinolones, silver sulfadiazine, antifungals, and corticosteroids.

- Severe otic stenosis is best managed initially with an anti-inflammatory course of oral prednisolone (0.5–1 mg/kg q24h) for 2 to 4 weeks. Patients with severe pain may require administration of prednisolone for several days to relieve pain prior to application of topical otic therapy. Stenosis impedes efficacy of topical treatment and precludes safe and effective anesthetized deep ear flushing. Should the stenosis fail to improve, however, the prognosis for effective medical management is guarded.

Topical steroids may be used as an adjunct therapy with oral prednisolone and may be continued to prevent further progression of hyperplasia and stenosis. The combination of the potent corticosteroid fluocinolone with the penetrating vehicle DMSO is a rational adjunct and topical maintenance therapy for severe stenosis and/or hyperplasia. ■ **cb**

References

- Wilhem S, Kovalik M, Favrot C. Breed-associated phenotypes in canine atopic dermatitis. *Vet Dermatol.* 2011;22(2):143-149.
- Feather L, Gough K, Flynn RJ, Elsheikha HM. A retrospective investigation into risk factors of sarcoptic mange in dogs. *Parasitol Res.* 2010;107(2): 279-283.
- Fourie JJ, Horak IG, de la Puente Redondo V. Efficacy of a spot-on formulation of pyriprole on dogs infested with *Sarcoptes scabiei*. *Vet Rec.* 2010;167(12): 442-445.
- Strain GM, Merchant SR, Neer TM, Tedford BL. Ototoxicity assessment of a gentamicin sulfate otic preparation in dogs. *Am J Vet Res.* 1995;56(4): 532-538.

Brief Summary of Prescribing Information

convenia[®]

(cefovecin sodium)

Antimicrobial for Subcutaneous Injection in Dogs and Cats Only

CAUTION: Federal (USA) law restricts this drug to use by or on the order of a licensed veterinarian.

INDICATIONS:

Dogs

CONVENIA is indicated for the treatment of skin infections (secondary superficial pyoderma, abscesses, and wounds) in dogs caused by susceptible strains of *Staphylococcus intermedius* and *Streptococcus canis* (Group G).

Cats

CONVENIA is indicated for the treatment of skin infections (wounds and abscesses) in cats caused by susceptible strains of *Pasteurella multocida*.

CONTRAINDICATIONS: CONVENIA is contraindicated in dogs and cats with known allergy to cefovecin or to β -lactam (penicillins and cephalosporins) group antimicrobials. Anaphylaxis has been reported with the use of this product in foreign market experience. If an allergic reaction or anaphylaxis occurs, CONVENIA should not be administered again and appropriate therapy should be instituted. Anaphylaxis may require treatment with epinephrine and other emergency measures, including oxygen, intravenous fluids, intravenous antihistamine, corticosteroids, and airway management, as clinically indicated. Adverse reactions may require prolonged treatment due to the prolonged systemic drug clearance (65 days).

WARNINGS: Not for use in humans. Keep this and all drugs out of reach of children. Consult a physician in case of accidental human exposure. For subcutaneous use in dogs and cats only. Antimicrobial drugs, including penicillins and cephalosporins, can cause allergic reactions in sensitized individuals. To minimize the possibility of allergic reactions, those handling such antimicrobials, including cefovecin, are advised to avoid direct contact of the product with the skin and mucous membranes.

PRECAUTIONS: Prescribing antibacterial drugs in the absence of a proven or strongly suspected bacterial infection is unlikely to provide benefit to treated animals and may increase the risk of the development of drug-resistant animal pathogens.

The safe use of CONVENIA in dogs or cats less than 4 months of age and in breeding or lactating animals has not been determined. Safety has not been established for IM or IV administration. The long-term effects on injection sites have not been determined. CONVENIA is slowly eliminated from the body, approximately 65 days is needed to eliminate 97% of the administered dose from the body. Animals experiencing an adverse reaction may need to be monitored for this duration.

CONVENIA has been shown in an experimental *in vitro* system to result in an increase in free concentrations of carprofen, furosemide, doxycycline, and ketoconazole. Concurrent use of these or other drugs that have a high degree of protein-binding (e.g. NSAIDs, propofol, cardiac, anticonvulsant, and behavioral medications) may compete with cefovecin-binding and cause adverse reactions.

Positive direct Coombs' test results and false positive reactions for glucose in the urine have been reported during treatment with some cephalosporin antimicrobials. Cephalosporin antimicrobials may also cause falsely elevated urine protein determinations. Some antimicrobials, including cephalosporins, can cause lowered albumin values due to interference with certain testing methods.

Occasionally, cephalosporins and NSAIDs have been associated with myelotoxicity, thereby creating a toxic neutropenia⁴. Other hematological reactions seen with cephalosporins include neutropenia, anemia, hypoprotrombinemia, thrombocytopenia, prolonged prothrombin time (PT) and partial thromboplastin time (PTT), platelet dysfunction and transient increases in serum aminotransferases.

ADVERSE REACTIONS:

Dogs

A total of 320 dogs, ranging in age from 8 weeks to 19 years, were included in a field study safety analysis. Adverse reactions reported in dogs treated with CONVENIA and the active control are summarized in Table 2.

Table 2: Number of Dogs* with Adverse Reactions Reported During the Field Study with CONVENIA.

Adverse Reaction	CONVENIA (n=157)	Active Control (n=163)
Lethargy	2	7
Anorexia/Decreased Appetite	5	8
Vomiting	6	12
Diarrhea	6	7
Blood in Feces	1	2
Dehydration	0	1
Fatulence	1	0
Increased Borborygmi	1	0

*Some dogs may have experienced more than one adverse reaction or more than one occurrence of the same adverse reaction during the study.

Mild to moderate elevations in serum γ -glutamyl trans-ferase or serum alanine aminotransferase were noted post-treatment in several of the CONVENIA-treated dogs. No clinical abnormalities were noted with these findings.

One CONVENIA-treated dog in a separate field study experienced diarrhea post-treatment lasting 4 weeks. The diarrhea resolved.

Cats

A total of 291 cats, ranging in age from 2.4 months (1 cat) to 21 years, were included in the field study safety analysis. Adverse reactions reported in cats treated with CONVENIA and the active control are summarized in Table 3.

Table 3: Number of Cats* with Adverse Reactions Reported During the Field Study with CONVENIA.

Adverse Reaction	CONVENIA (n=157)	Active Control (n=163)
Vomiting	10	14
Diarrhea	7	26
Anorexia/Decreased Appetite	6	6
Lethargy	6	6
Hyper/Acting Strange	1	1
Inappropriate Urination	1	0

*Some cats may have experienced more than one adverse reaction or more than one occurrence of the same adverse reaction during the study.

Four CONVENIA cases had mildly elevated post-study ALT (1 case was elevated pre-study). No clinical abnormalities were noted with these findings.

Twenty-four CONVENIA cases had normal pre-study BUN values and elevated post-study BUN values (37–39 mg/dL post-study). There were 6 CONVENIA cases with normal pre- and mildly to moderately elevated post-study creatinine values. Two of these cases also had an elevated post-study BUN. No clinical abnormalities were noted with these findings.

One CONVENIA-treated cat in a separate field study experienced diarrhea post-treatment lasting 42 days. The diarrhea resolved.

FOREIGN MARKET EXPERIENCE: The following adverse events were reported voluntarily during post-approval use of the product in dogs and cats in foreign markets: death, tremors/ataxia, seizures, anaphylaxis, acute pulmonary edema, facial edema, injection site reactions (alopecia, scabs, necrosis, and erythema), hemolytic anemia, salivation, pruritus, lethargy, vomiting, diarrhea, and inappetence.

For a copy of the Material Safety Data Sheet, (MSDS) or to report a suspected adverse reaction call Zoetis Inc. at 1-888-963-8471.

STORAGE INFORMATION:

Store the powder and the reconstituted product in the original carton, refrigerated at 2° to 8° C (36° to 46° F). **Use the entire contents of the vial within 56 days of reconstitution.** PROTECT FROM LIGHT. After each use it is important to return the unused portion back to the refrigerator in the original carton. As with other cephalosporins, the color of the solution may vary from clear to amber at reconstitution and may darken over time. If stored as recommended, solution color does not adversely affect potency.

HOW SUPPLIED:

CONVENIA is available as a 10 mL multi-use vial containing 800 milligrams of cefovecin as a lyophilized cake.

NADA# 141-285, Approved by FDA

zoetis

Distributed by
Zoetis Inc.
Kalamazoo, MI 49007

January 2013
PAA035845A&P