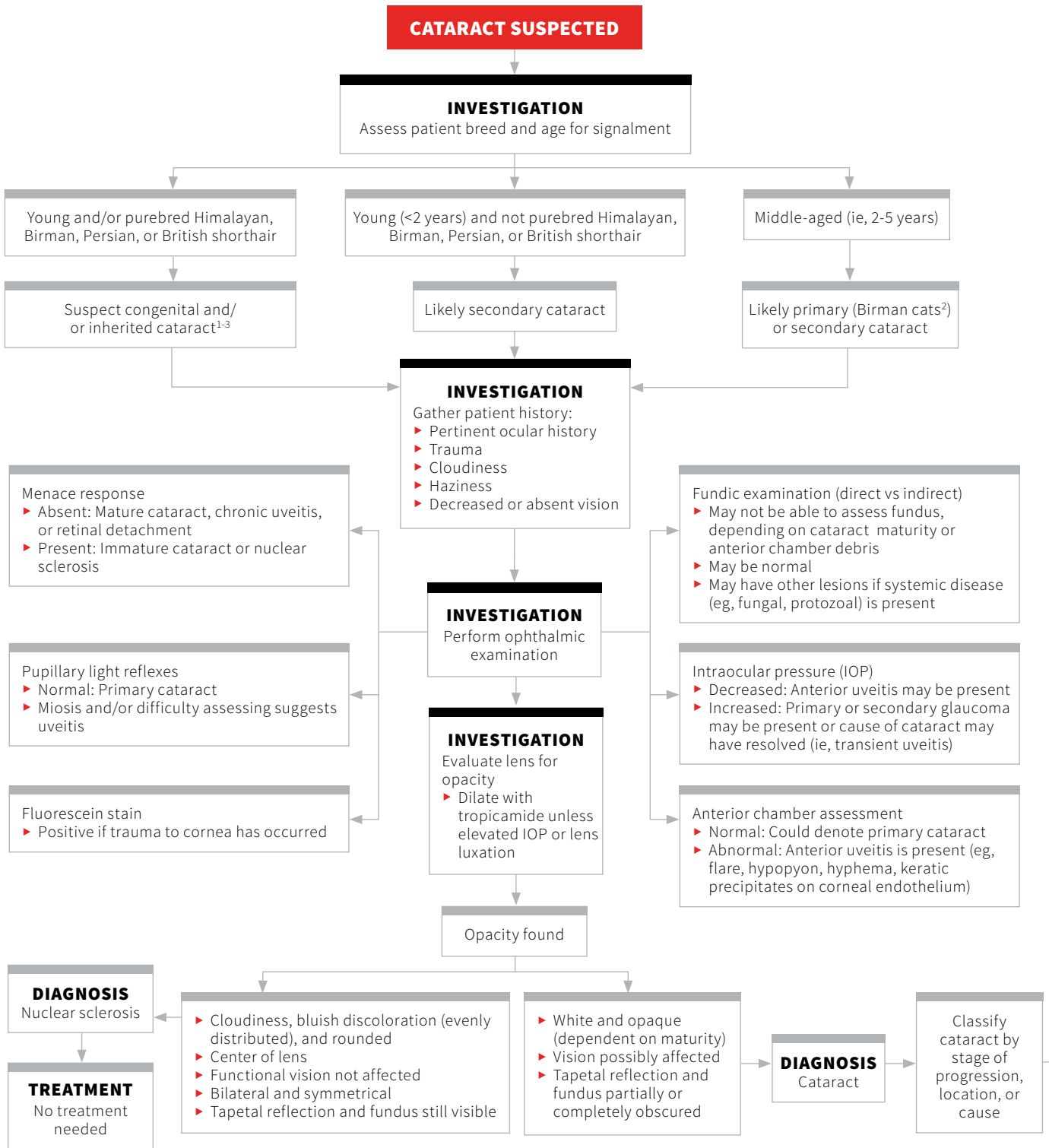
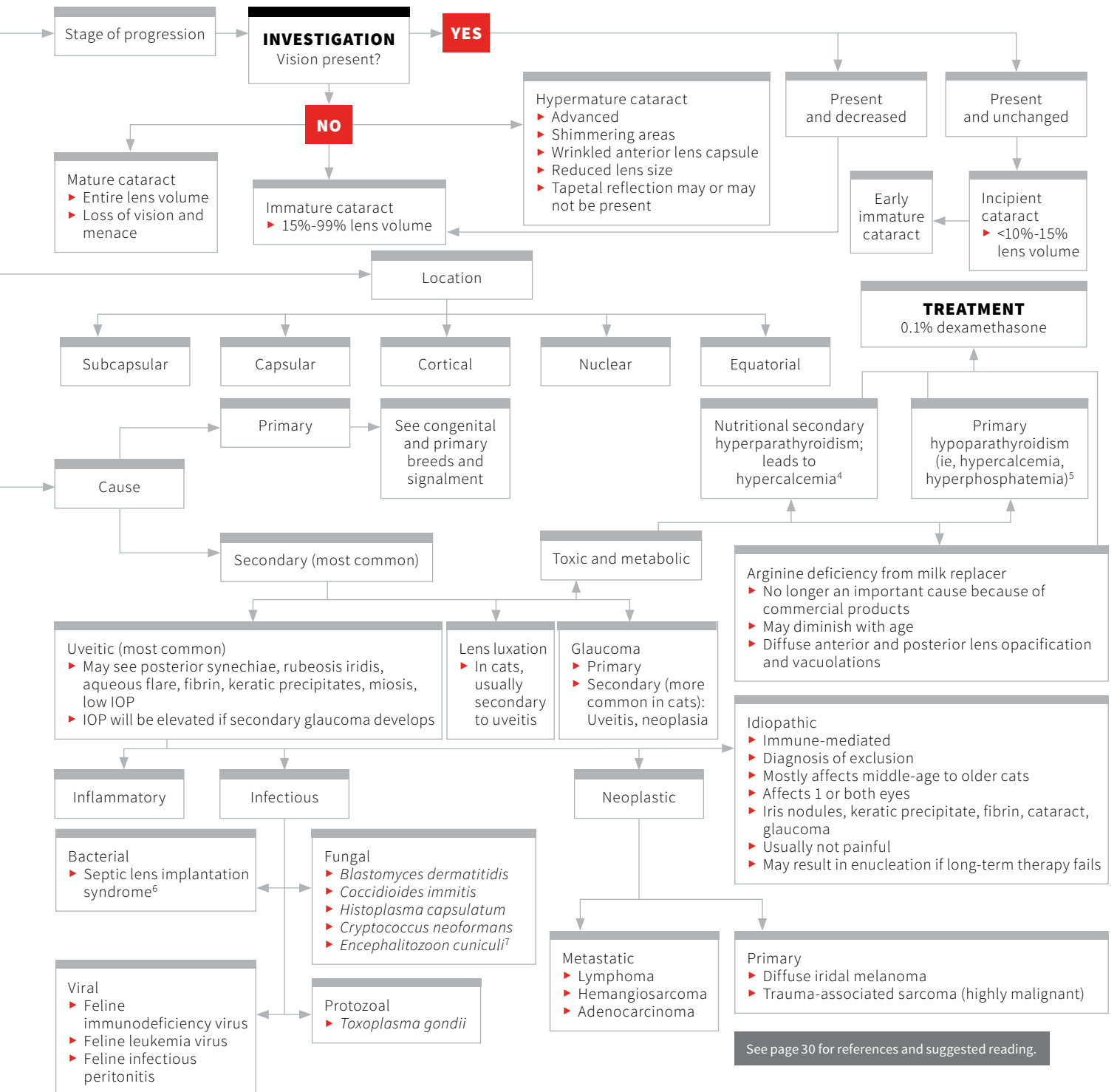


CATARACTS IN CATS: DIAGNOSIS

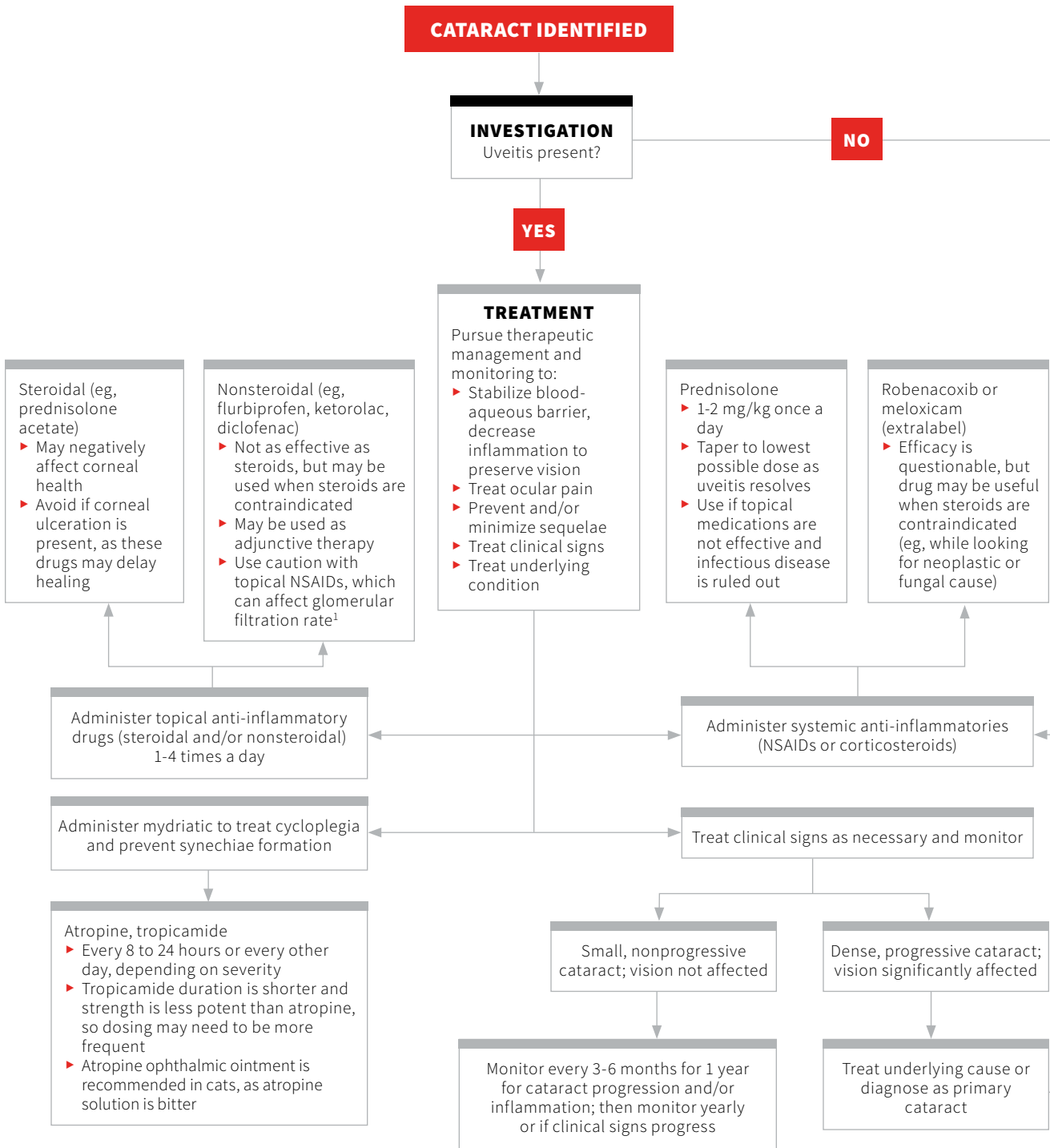
Mary Rebecca Telle, DVM
 Diane Hendrix, DVM, DACVO
 University of Tennessee

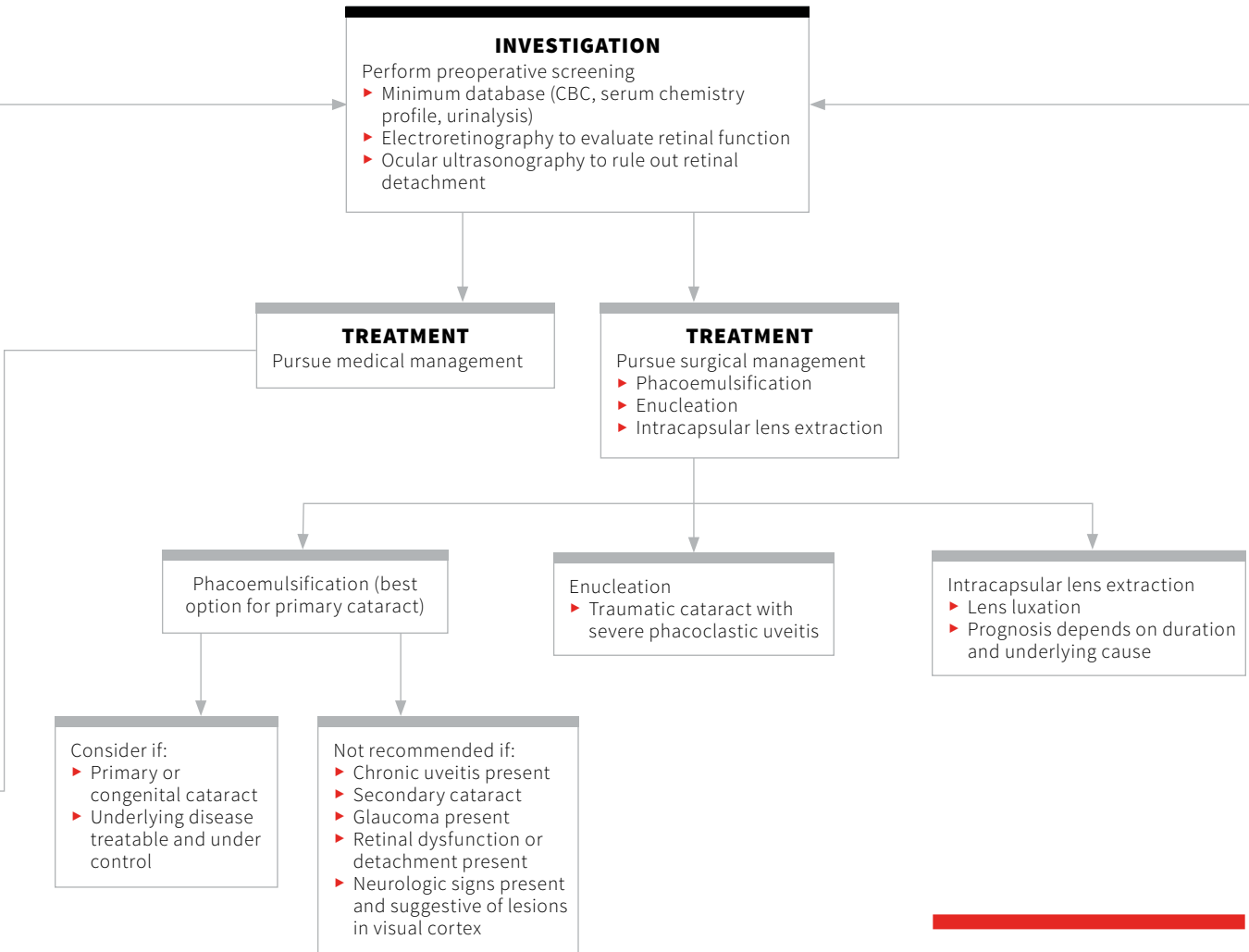




CATARACTS IN CATS: TREATMENT

Mary Rebecca Telle, DVM
 Diane Hendrix, DVM, DACVO
 University of Tennessee





Reference

1. Lanuza R, Rankin AJ, KuKanich B, Meekins JM. Evaluation of systemic absorption and renal effects of topical ophthalmic flurbiprofen and diclofenac in healthy cats. *Vet Ophthalmol.* 2015;19(Suppl 1):24-29.

**Veraflox (pradofloxacin) Oral Suspension for Cats
25 mg/mL**

For the treatment of skin infections (wounds and abscesses) in cats.
Do not use in dogs.

BRIEF SUMMARY:

Before using Veraflox Oral Suspension for Cats, please consult the product insert, a summary of which follows:

CAUTION:

Federal law restricts this drug to use by or on the order of a licensed veterinarian. Federal law prohibits the extra-label use of this drug in food-producing animals.

PRODUCT DESCRIPTION:

Pradofloxacin is a fluoroquinolone antibiotic and belongs to the class of quinolone carboxylic acid derivatives. Each mL of Veraflox Oral Suspension provides 25 mg of pradofloxacin.

INDICATIONS:

Veraflox is indicated for the treatment of skin infections (wound and abscesses) in cats caused by susceptible strains of *Pasteurella multocida*, *Streptococcus canis*, *Staphylococcus aureus*, *Staphylococcus felis*, and *Staphylococcus pseudintermedius*.

CONTRAINDICATIONS:

DO NOT USE IN DOGS. Pradofloxacin has been shown to cause bone marrow suppression in dogs. Dogs may be particularly sensitive to this effect, potentially resulting in severe thrombocytopenia and neutropenia. Quinolone-class drugs have been shown to cause arthropathy in immature animals of most species tested, the dog being particularly sensitive to this side effect. Pradofloxacin is contraindicated in cats with a known hypersensitivity to quinolones.

HUMAN WARNINGS:

Not for human use. Keep out of reach of children. Individuals with a history of quinolone hypersensitivity should avoid this product. Avoid contact with eyes and skin. In case of ocular contact, immediately flush eyes with copious amounts of water. In case of dermal contact, wash skin with soap and water for at least 20 seconds. Consult a physician if irritation persists following ocular or dermal exposure or in case of accidental ingestion. In humans, there is a risk of photosensitization within a few hours after exposure to quinolones. If excessive accidental exposure occurs, avoid direct sunlight. Do not eat, drink or smoke while handling this product. For customer service or to obtain product information, including a Material Safety Data Sheet, call 1-800-633-3796. For medical emergencies or to report adverse reactions, call 1-800-422-9874.

ANIMAL WARNINGS:

For use in cats only. The administration of pradofloxacin for longer than 7 days induced reversible leukocyte, neutrophil, and lymphocyte decreases in healthy, 12-week-old kittens.

PRECAUTIONS:

The use of fluoroquinolones in cats has been associated with the development of retinopathy and/or blindness. Such products should be used with caution in cats. Quinolones have been shown to produce erosions of cartilage of weight-bearing joints and other signs of arthropathy in immature animals of various species. The safety of pradofloxacin in cats younger than 12 weeks of age has not been evaluated. The safety of pradofloxacin in immune-compromised cats (i.e., cats infected with feline leukemia virus and/or feline immune-deficiency virus) has not been evaluated. Quinolones should be used with caution in animals with known or suspected central nervous system (CNS) disorders. In such animals, quinolones have, in rare instances, been associated with CNS stimulation that may lead to convulsive seizures. The safety of pradofloxacin in cats that are used for breeding or that are pregnant and/or lactating has not been evaluated.

ADVERSE REACTIONS:

In a multi-site field study, the most common adverse reactions seen in cats treated with Veraflox were diarrhea/loose stools, leukocytosis with neutrophilia, elevated CPK levels, and sneezing.

ANIMAL SAFETY:

In a target animal safety study in 32, 12-week-old kittens dosed at 0, 1, 3, and 5 times the recommended dose for 21 consecutive days. One 3X cat and three 5X cats had absolute neutrophil counts below the reference range. The most frequent abnormal clinical finding was soft feces. While this was seen in both treatment and control groups, it was observed more frequently in the 3X and 5X kittens.

HOW SUPPLIED: 15mL and 30mL

U.S. Patent No. 6,323,213
NADA141-344, Approved by FDA
Made in Germany
Bayer, the Bayer Cross and Veraflox
are registered trademarks of Bayer.
52423B
June 2016

Bayer

Bayer HealthCare LLC
Animal Health Division
Shawnee Mission, Kansas 66201, U.S.A.

References

1. Thomas WB. Hydrocephalus in dogs and cats. *Vet Clin North Am Small Anim Pract.* 2010;40(1):143-159.
2. Dewey CW, Coates JR, Axlund TW, Smith J. Hydrocephalus in dogs and cats. *Compend Contin Educ Vet.* 2006;28(2):136-146.
3. Summers BA, Cummings JF, de Lahunta A. Malformations of the central nervous system. In: *Veterinary Neuropathology.* St. Louis, MO: Mosby; 1994:68-94.
4. Scott FW, LaHunta A, Schultz RD, Bistner SJ, Riis RC. Teratogenesis in cats associated with griseofulvin therapy. *Teratology.* 1975;11(1):79-86.
5. Csiza CK, Scott FW, Gillespie JH, De Lahunta A. Feline viruses XIV: transplacental infections in spontaneous panleukopenia of cats. *Cornell Vet.* 1971;61(3):423-439.
6. Selby LA, Hayes HM Jr, Becker SV. Epizootiologic features of canine hydrocephalus. *Am J Vet Res.* 1979;40(3):411-413.
7. Hudson JA, Simpson ST, Buxton DF, Cartee RE, Steiss JE. Ultrasonographic diagnosis of canine hydrocephalus. *Vet Radiol.* 1990;31(2):50-58.
8. Simpson ST. Hydrocephalus. In: Kirk RW, Bonagura JD, eds. *Current Veterinary Therapy X: Small Animal Practice.* Philadelphia, PA: WB Saunders; 1988:842-847.
9. Harrington ML, Bagley RS, Moore MP. Hydrocephalus. *Vet Clin North Am Small Anim Pract.* 1996;26(4):843-856.
10. Javaheri S, Corbett WS, Simbartl LA, Mehta S, Khosla A. Different effects of omeprazole and Sch 28080 on canine cerebrospinal fluid production. *Brain Res.* 1997;754(1-2):321-34.
11. Biel M, Kramer M, Forterre F, et al. Outcome of ventriculoperitoneal shunt implantation for treatment of congenital internal hydrocephalus in dogs and cats: 36 cases (2001-2009). *JAVMA.* 2013;242(7):948-958.
12. Kay ND, Holliday TA, Hornof WJ, Gomez J. Diagnosis and management of an atypical case of canine hydrocephalus using computed tomography, ventriculoperitoneal shunting, and nuclear scintigraphy. *JAVMA.* 1986;188(4):423-426.

DIAGNOSTIC TREE ▶ CONTINUED FROM PAGE 21

References

1. Rubin LF. Hereditary cataract in Himalayan cats. *Feline Pract.* 1986;16:14-15.
2. Schwink K. Posterior nucleus cataracts in two Birman kittens. *Feline Pract.* 1986;16:31-33.
3. Narfström K. 1999 Hereditary and congenital ocular disease in the cat. *J Feline Med Surg.* 1999;1(3):135-141.
4. Bassett JR. Hypocalcemia and hyperphosphatemia due to primary hypoparathyroidism in a six-month-old kitten. *JAAHA.* 1998;34(6):503-507.
5. Stiles J. Cataracts in a kitten with nutritional secondary hyperparathyroidism. *Prog Vet Comp Ophthalmol.* 1991;4:296-298.
6. Bell CM, Pot SA, Dubielzig RR. Septic implantation syndrome in dogs and cats: a distinct pattern of endophthalmitis with lenticular abscess. *Vet Ophthalmol.* 2013;16(3):180-185.
7. Benz P, Maass G, Csokai J, et al. Detection of Encephalitozoon cuniculi in the feline cataractous lens. *Vet Ophthalmol.* 2011;14(Suppl 1):37-47.

Suggested Reading

Peiffer RL JR, Belkin PV. Keratolenticular dysgenesis in a kitten. *JAVMA.* 1983;182(11):1242-1243.

Peiffer RL, Gelatt KN. Cataracts in the cat. *Feline Pract.* 1974;4:34-38.

Lim CC, Reilly CM, Thomasy SM, Kass PH, Maggs DJ. Effects of feline herpesvirus type 1 on tear film break-up time, Schirmer tear test results, and conjunctival goblet cell density in experimentally infected cats. *Am J Vet Res.* 2009;70(3):394-403.

Richter M, Guscetti F, Spiess B. Aldose reductase activity and glucose-related opacities in incubated lenses from dogs and cats. *Am J Vet Res.* 2002;63(11):1591-1597.

Shukla AK, Pinard CL. Feline uveitis. *Compend Contin Educ Vet.* 2012;34(9):E1.

Stiles J. Feline Ophthalmology. In: Gelatt KN, Gilger BC, Kern TJ, eds. *Veterinary Ophthalmology.* 5th ed. Ames, IA: Wiley-Blackwell; 2013:1519-1520.

Williams DL, Heath MF. Prevalence of feline cataract: results of a cross-sectional study of 2000 normal animals, 50 cats with diabetes and one hundred cats following dehydrational crises. *Vet Ophthalmol.* 2006;9(5):341-349.

Zhan GL, Miranda OC, Bitto LZ. Steroid glaucoma: corticosteroid-induced ocular hypertension in cats. *Curr Eye Res.* 1992;5(4):211-218.