

# Flushing the External Ear Canal

**T**horough ear canal cleaning is an integral part of management of otitis in the dog. Cleaning facilitates the removal of exudate and cerumen and allows visualization of the canal and the tympanic membrane. The extent and type of ear cleaning are determined by the severity of disease and underlying cause.

In addition, cleaning facilitates the action of medicated otic preparations. Discharge within the canal physically prevents antibiotics and glucocorticoids from reaching target areas and the presence of purulent discharge in bacterial infections inactivates many antibiotics, including polymyxin and aminoglycosides.

In mild cases of otitis externa, where the ear is not severely painful and the dog is cooperative, most owners are able to clean the ear canal prior to application of appropriate ear medications. However, if the ear is too painful to examine and/or the ear canal is occluded with debris, flushing of the external ear canal while the patient is anesthetized is often necessary.

CONTINUES

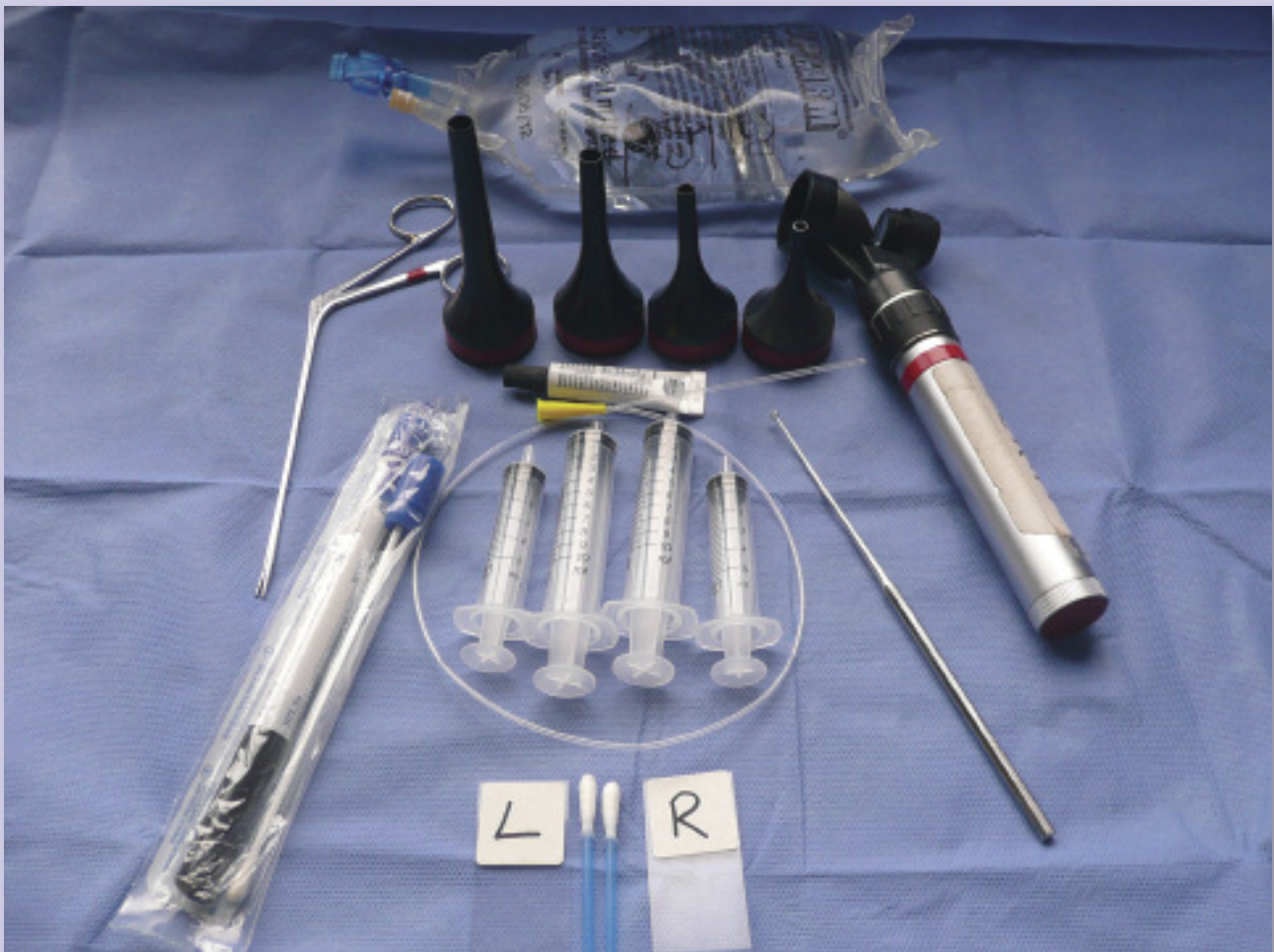

## WHAT YOU WILL NEED

Ear flushing can be performed using video otoscopy; however, it can also be safely and effectively done using a handheld otoscope (with a strong light source and operating head with magnification). In addition, you will need:

- Alligator forceps
- Cotton-tipped swabs for routine cytology
- Ear culettes if bacterial culture and sensitivity need to be performed
- Ear curette
- Eye drops
- Flushing solutions:
  - ▶ Ceruminolytic solutions (eg, dioctyl sodium sulfosuccinate [DSS], propylene glycol, squalene, urea peroxide)
  - ▶ Aqueous flushing solutions (eg, isotonic sterile saline [0.9%])
- Glass microscope slide
- Range of sterile otoscope cones
- Multiple 5- and 10-mL syringes
- 6- or 8-French polypropylene urinary catheter

The distal tip of the catheter should be cut off with sharp scissors (if the end is rough it can be smoothed with a file or by heating). This reduces the risk for damage to the tympanic membrane and also allows the flush solution to be expelled from the end rather than the side holes.



DSS = dioctyl sodium sulfosuccinate



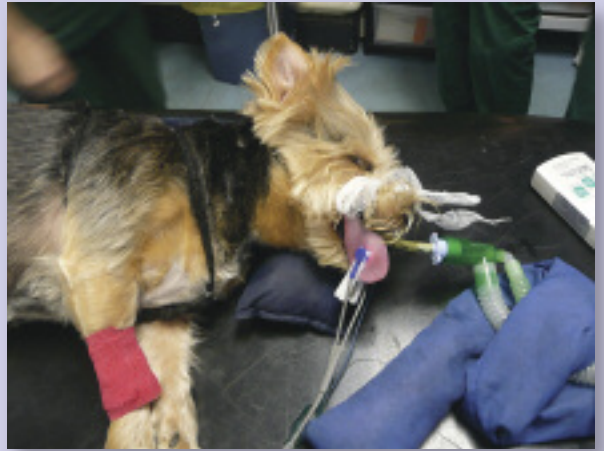## STEP BY STEP FLUSHING THE EXTERNAL EAR CANAL

### STEP 1

General anesthetic is required for thorough otic flushing. As always, clinicians should use protocols that are most familiar to them. I use a sedative (eg, medetomidine hydrochloride, 0.001–0.005 mg/kg IV) and analgesic (eg, butorphanol, 0.10–0.40 mg/kg IV) premedication combination prior to intravenous induction with a short-acting anesthetic, such as propofol (2.2–4.4 mg/kg IV).

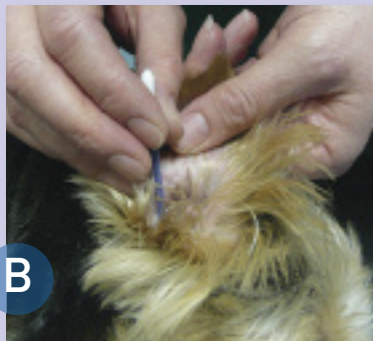
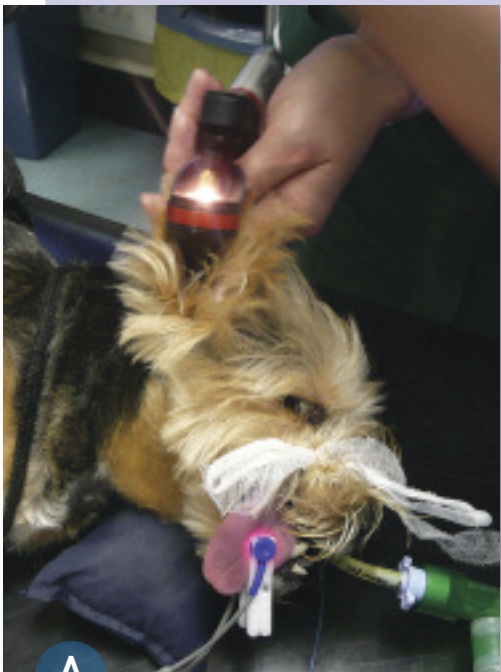Because patients will be maintained on gas anesthesia, an endotracheal tube will be needed and cuff inflated. This will prevent any potential respiratory tract contamination if flushing fluid flows through a damaged tympanum and down the Eustachian tube.

The patient should be placed in lateral recumbency with the head slightly elevated. The application of a lubricant eye cream is useful to prevent damage to the cornea. Additional eye protection with a towel is helpful.



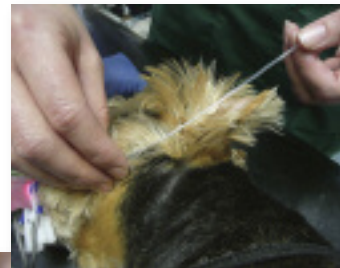
### STEP 2

The ear canal should be examined with the otoscope (A) and samples should be collected for cytology and culture and sensitivity (B and C). If imaging studies are needed, they should be performed prior to flushing of the ear canal. Products that have recognized ototoxicity should be avoided if ruptured ear drum is found.



#### AUTHOR INSIGHT

**When flushing using a handheld otoscope, it is useful to measure the approximate length of the vertical canal so the flushing tube can be cut to an appropriate length. The use of an overlong tube may increase the risk for iatrogenic damage to the tympanic membrane.**



CONTINUES

**STEP 3**

Assessment of the type of discharge in the ear allows selection of an appropriate initial flush:

- If the discharge is waxy, a cleaner with good ceruminolytic properties should be employed.
- Soft waxy discharges can be removed using agents such as DSS or propylene glycol. Both products are potentially ototoxic, they so must be used with care and be completely removed if there is evidence of damage to the tympanic membrane.
- Thicker drier discharges can be removed with squalene, which is gentle, not irritating, and not ototoxic.
- Urea peroxide is a very potent, potentially ototoxic ceruminolytic that should be reserved for ears containing tenacious secretions.
- If the discharge is mucoïd and purulent, an aqueous cleaner is preferable (see Step 4).

A 5-mL syringe should be filled with the ceruminolytic cleaner. The 6- or 8-French polypropylene catheter should be carefully inserted into the canal with the syringe attached to the proximal end. Apply gentle pressure to the syringe to empty the contents into the ear canal. Gently massage the ear and suction the fluid from the canal.

If any negative pressure is felt during suction, reposition the syringe in case it is against the side of the ear canal. If this does not solve the problem, remove it and determine if the end is obstructed with debris. Once flushing is completed, the ear should be examined with the otoscope and if significant amounts of wax remain, the procedure can be repeated.



**STEP 4**

Copious flushing of the ear canal with a warmed aqueous flush should be performed after the initial flush to remove any residual ceruminolytic ear cleanser and minimize any irritant reactions from the cleanser. Catheters are inexpensive and cannot be adequately sterilized between steps; a new catheter should be used for this step.

Ten mL of aqueous flush (isotonic sterile saline [0.9%] or sterile water) should be drawn into a clean syringe, attached to the catheter positioned within the ear canal, and instilled into the ear. The solution should then be withdrawn and expelled into a clean bowl so that the contents of the flush can be inspected. This procedure should be repeated until the flush solution is clear.



**Cleanser Contamination**

Some practices use stock ear cleanser directly from the bottle to fill the ear canal with fluid. This would be acceptable if a new bottle of ear cleanser was purchased for each patient; however, if ear cleansers are used as "stock solutions," it is important to prevent contamination of the solution by instilling it in the ear through a syringe and catheter.

**AUTHOR INSIGHT**

Using a large catheter allows easy suction of debris from the ear canal.

DSS = dioctyl sodium sulfosuccinate

## STEP 5

The ear should be examined again with the otoscope to ensure it is clean before it is dried. If debris, such as hair, ceruminoliths, or foreign bodies, remains within the canal, it can be removed using an ear curette or alligator forceps. Pediatric ear curettes are very useful since they are disposable, plastic, and the end is flexible.

This step should not be attempted unless an operating head otoscope that allows simultaneous instrument manipulation is available. In addition, any instrument introduced through the handheld otoscope impairs visualization of the canal, so this procedure should be undertaken with extreme care to avoid damage to the tympanum or ear wall.



## STEP 6

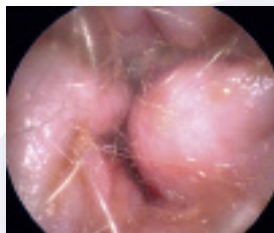Finally, 2 mL of an otic solution labelled as a drying agent should be introduced into the ear to reduce maceration of the canal lining, assuming that the canal is not damaged and the tympanic membrane is intact. Suitable drying agents include:

- Acetic acid
- Aluminum acetate
- Benzoic acid
- Boric acid
- Isopropyl alcohol
- Lactic acid
- Salicylic acid.

These are rarely available as individual solutions but are often found as components of general ear cleaning solutions. Before prescription ear drops are instilled, any residual drying solution can be suctioned out using the syringe or absorbed with a cotton swab. The initial choice of drops should be made on the basis of previous cytologic findings.

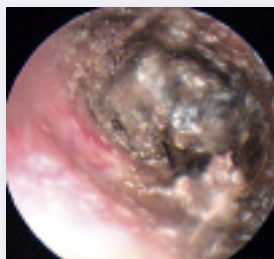
## AUTHOR INSIGHT

Since many antibiotics are inactivated by low pH, acid solutions with low pH should be avoided if antibiotic drops are to be used immediately after flushing. An alkaline flush, such as tris-EDTA (trisaminomethamine-ethylenediaminetetra acetic acid) can be used to enhance the effect of antibiotics.

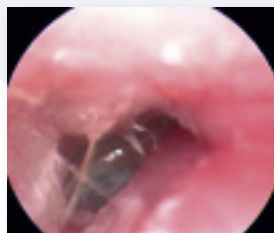

### Otoscopic Ear Canal Images

An ear canal that is hyperplastic and partially closed; glucocorticoids can be used prior to flushing to help open up the canal.



Thick tenacious cerumen within the ear canal; a potent ceruminolytic cleanser is required.



An ulcerated ear canal with mucoid discharge; a gentle water-based cleanser is preferred over a ceruminolytic cleanser.

See Aids & Resources, back page, for references and suggested reading.