

Cyclophosphamide-Induced Sterile Hemorrhagic Cystitis

Timothy M. Fan, DVM, PhD, DACVIM
(Oncology, Internal Medicine)

University of Illinois at Urbana–Champaign

In the Literature

Setyo L, Ma M, Bunn T, Wyatt K, Wang P. Furosemide for prevention of cyclophosphamide-associated sterile hemorrhagic cystitis in dogs receiving metronomic low-dose oral cyclophosphamide. *Vet Comp Oncol.* 2017;15(4):1468-1478.

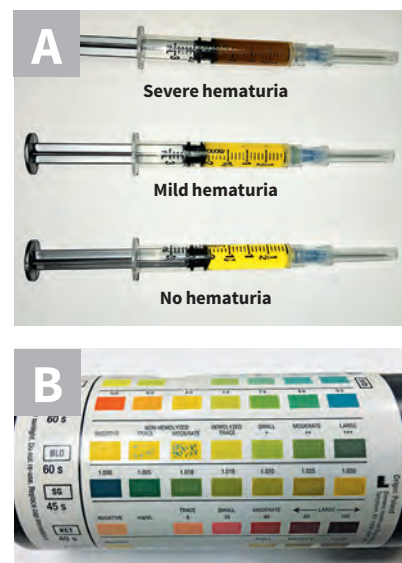
FROM THE PAGE ...

Systemic chemotherapy remains a cornerstone for treating companion animals with cancer. The manner by which antineoplastic drugs are administered can be categorized in 2 therapeutic strategies: maximum-tolerated dose or metronomic chemotherapy (ie, low-dose daily oral administration).^{1,2} Oral cyclophosphamide, either alone or in conjunction with NSAIDs (eg, piroxicam), is the most common cytotoxic agent used for metronomic chemotherapy in veterinary patients.^{3,4} Although metronomic cyclophosphamide administration does not typically cause

myelosuppression or GI toxicities, the metabolism of cyclophosphamide still results in production of acrolein, a potent uroepithelial irritant with the potential to cause sterile hemorrhagic cystitis (SHC).⁵ Strategies for mitigating the development of SHC involve reducing acrolein contact time with uroepithelial cells via drug-induced polyuria and administering furosemide or prednisolone.⁶

This retrospective study examined the incidence of clinically relevant SHC in pet dogs receiving long-term (>6 months) metronomic cyclophosphamide therapy with or without concurrent oral furosemide. Over a span of 6 years at a single institute, 115 dogs meeting study inclusion criteria were categorized into 2 groups and evaluated for the development of clinically relevant SHC. Among the dogs, 25 cases of SHC were either diagnostically confirmed (via urinalysis, urine culture, ultrasonography) or clinically suspected (unresponsiveness to antibiotic), amounting to an incidence of 21.7%. Significantly, the incidence of SHC was reduced in dogs treated with concurrent furosemide therapy (10.2% [5/49 dogs]) as compared with that in dogs not treated with furosemide (30.3% [20/66

dogs]). Collectively, these findings suggest that coadministration of furosemide along with long-term metronomic cyclophosphamide therapy can reduce the incidence of clinical signs associated with SHC.



▲ **FIGURE** Visual (A) and chemical (B; ie, colorimetric) detection methods useful in complementing clinical signs (eg, hematuria, stranguria, pollakiuria) to support the presumed diagnosis of SHC. Visual assessments should be limited to detecting gross hematuria, whereas chemical detection (ie, urine dipstick) provides improved sensitivity for the identification of microscopic hematuria.

... TO YOUR PATIENTS

Key pearls to put into practice:

- 1** Oral metronomic cyclophosphamide therapy can result in uroepithelial irritation secondary to acrolein formation, even at low doses.
- 2** The overall incidence of SHC in pet dogs treated with metronomic cyclophosphamide is clinically relevant, with approximately 1 in 5 dogs being affected during long-term (>6 months) treatment.
- 3** Coadministration of furosemide (0.5-1.0 mg/kg q24h) with metronomic cyclophosphamide therapy can substantially reduce the likelihood of SHC-associated clinical signs (ie, hematuria, stranguria, pollakiuria).

References

1. Gately S, Kerbel R. Antiangiogenic scheduling of lower dose cancer chemotherapy. *Cancer J.* 2001;7(5): 427-436.
2. Benzekry S, Pasquier E, Barbolosi D, et al. Metronomic reloaded: theoretical models bringing chemotherapy into the era of precision medicine. *Semin Cancer Biol.* 2015;35:53-61.
3. Biller B. Metronomic chemotherapy in veterinary patients with cancer: rethinking the targets and strategies of chemotherapy. *Vet Clin North Am Small Anim Pract.* 2014;44(5):817-829.
4. Mutsaers AJ. Metronomic chemotherapy. *Top Companion Anim Med.* 2009;24(3):137-143.
5. Cox PJ. Cyclophosphamide cystitis—identification of acrolein as the causative agent. *Biochem Pharmacol.* 1979;28(13):2045-2049.
6. Laberke S, Zenker I, Hirschberger J. Mesna and furosemide for prevention of cyclophosphamide-induced sterile haemorrhagic cystitis in dogs—a retrospective study. *Vet Rec.* 2014;174(10):250.



JorVet Specialty Products

www.JorVet.com Info@JorVet.com (800) 525-5614


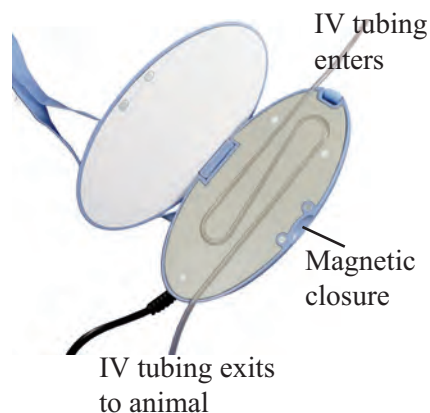
Warm Line IV Fluid Line Warmer

Intravenous fluids should be administered as close to body temperature as possible, especially when hypothermia or shock is a concern.

The **Warm Line** is a small, lightweight warming unit that is easily placed over any standard I.V. line to warm the fluids to 104°F.

Colored Lights

- Green - Power Light
- Yellow - Run Indicator
- Red - Alarm Indicator



Features include:

- A flow rate up to 2-6ml/min
- AC - just plug in and turn on
- Adjustable hanging strap
- No separate cartridges needed
- Celsius or Fahrenheit setting