

Canine Urinary Tract Infections

Gregory F. Grauer, DVM, MS, DACVIM
Kansas State University



Georgia, an 8-year-old spayed black Labrador retriever, was presented with urinary incontinence of several months' duration.

History

Georgia's incontinence, most pronounced when she was sleeping or lying down, had been present for several months and preceded more recent signs of lower urinary tract inflammation (ie, pollakiuria, dysuria/stranguria, breaking normal house-training behavior).

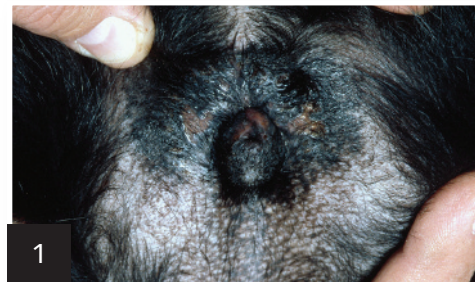Examination

Georgia was slightly overweight and had excessive perivulvar skinfolds with some perivulvar inflammation and evidence of licking and pigmentation change (Figure 1). Physical examination, including rectal examination and palpation of the urinary bladder, was unremarkable.

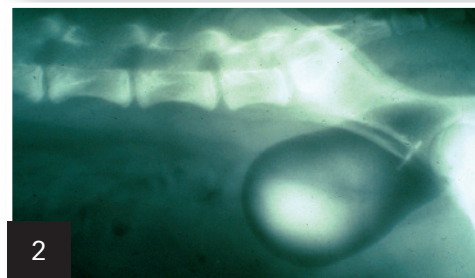
Initial Laboratory Evaluation

CBC and biochemistry profile were within normal limits. Urinalysis obtained by cystocentesis revealed a cloudy appearance with pH of 7.5, urine specific gravity of 1.037, 2+ proteinuria, 25 to 30 RBCs/hpf, 10 to 15 WBCs/hpf, 25 struvite crystals/hpf, and gram-negative rods. Urine culture yielded *Escherichia coli* (>1000 cfu/mL) sensitive to amoxicillin-clavulanic acid.

Plain film radiographs of the abdomen followed by a double-contrast cystogram demonstrated a pelvic bladder (Figure 2).



Radiograph of the vulvar region demonstrating recessed vulva and perivulvar dermatitis.



Double-contrast cystogram demonstrating the pelvic bladder.

Ask Yourself



- Is this urinary tract infection:
- A. Simple?
 - B. Complicated?

MORE ►

CORRECT ANSWER

B. Complicated

Simple vs Complicated Urinary Tract Infections

Simple or uncomplicated urinary tract infections (UTIs) lack structural or functional abnormalities in the host's defense mechanisms. This form of infection is easiest to treat and usually clears soon after appropriate antibiotic treatment. Simple, uncomplicated UTIs are the most common type to occur in female dogs.

Complicated UTIs are associated with 1 or more defects in the host's defense mechanisms: for example, interference with normal micturition, anatomic defects, damage to mucosal barriers, or alterations in urine volume or composition. Health of host defense mechanisms appears to be most important in influencing the pathogenesis of UTIs. Although antibiotic treatment is the cornerstone of UTI management, status of host defense mechanisms is thought to be the most important determinant of long-term treatment outcome. Antibiotic treatment should control the pathogenic bacterial growth for a period sufficient to allow host defense mechanisms to be corrected and prevent colonization of the urinary tract without further antibiotic administration.

Diagnosis

Georgia had a UTI caused or complicated by probable urethral sphincter mechanism incompetence (USMI), abnormal vulvar anatomy, and subsequent perivulvar inflammation. The pelvic bladder location results in a shortened urethra, which has been associated with USMI. Decreased urethral sphincter tone allows bacteria to more easily ascend to the bladder. Abnormal vulvar

anatomy and USMI resulted in a moist perivulvar dermatitis and increased the number of pathogenic bacteria at the vulvar opening. Excessive perivulvar skinfolds likely occurred secondary to weight gain.

Treatment

Georgia was treated with amoxicillin-clavulanic acid at 13.75 mg/kg PO q12h for 4 weeks, indefinite administration of phenylpropanolamine at 1.5 mg/kg PO q12h for sphincter incompetence, local treatment (astringents, hot-packing, topical antibiotics), and an Elizabethan collar to prevent licking of the perivulvar dermatitis.

Follow-up

The owner reported that the vulva appeared improved and the patient rarely leaked urine and showed none of the previous signs of lower urinary tract inflammation. Urine sediment was inactive. Urine culture 10 days after antibiotic withdrawal showed no growth. Approximately 2 months after antibiotic treatment was discontinued, Georgia again showed signs of lower urinary tract inflammation (ie, pollakiuria, breaking house training). Urine culture obtained by cystocentesis again yielded *E coli* but with a markedly different sensitivity profile (sensitive to fluoroquinolones).

Ask Yourself



- Is this recurrent urinary tract infection a:
- A. Relapse?
 - B. Reinfection?



Cranberry Extract & *E coli*

Proanthocyanidins, specifically A-type isoforms found in cranberry extract (CE), can potentially inhibit *E coli* attachment by blocking interaction of bacterial P-fimbriae with the surface of uroepithelial cells. Canine studies evaluating the efficacy of CEs are limited to in vitro data. One study demonstrated that *E coli* in urine from dogs receiving oral CE (Crananidin, nutramaxlabs.com) had decreased ability to agglutinate to human RBCs. Similarly, a second study demonstrated that *E coli* in urine from dogs receiving oral CE (Paxon, vetoquinolusa.com) had decreased ability to adhere to Madin-Darby canine kidney cells.

Based on these studies, oral administration of CE may help reduce *E coli* reinfections in patients with compromised host defense mechanisms.^{1,2}

CE = cranberry extract, USMI = urethral sphincter mechanism incompetence, UTI = urinary tract infection

TX at a Glance

Complicated & Recurrent UTIs

- Long-term antibiotic treatment (4–6 weeks) based on culture and sensitivity
- Thorough patient assessment for compromised host defense mechanisms
 - Chemistry profile and follow-up testing to rule out systemic immunocompromise (eg, chronic kidney disease, diabetes mellitus, hyperadrenocorticism)
 - Imaging to rule out local anatomic abnormalities
- Correction/control of compromised host defense mechanisms, if possible
- Prophylactic preventive measures if host defense mechanisms cannot be corrected (only after appropriate antibiotic treatment has sterilized the urinary tract)
 - Urinary antiseptics/acidifiers
 - CE
 - Long-term, low-dose prophylactic antibiotic treatment



CORRECT ANSWER

B. Reinfection

Recurrent UTIs

Relapses are infections caused by the same species of bacteria, usually within several days of treatment cessation. With a relapsed UTI, previous antibacterial treatment failed to eliminate infection. Relapses may be caused by improper antibiotic or dose, emergence of drug-resistant pathogens, or failure to eliminate predisposing causes that alter normal host defense mechanisms and allow bacteria to persist (eg, viable bacteria sequestered within struvite uroliths).

In reinfections, previous antibacterial treatment can clear the first infection and the urinary tract subsequently becomes infected with another bacteria. The time between reinfections is usually greater than the time between relapses. Reinfections often indicate failure to eliminate predisposing causes that alter normal host defense mechanisms.

Because of the length of time between the UTIs and markedly different sensitivity profile, Georgia's recurrent UTI is most likely a reinfection with a different uropathogenic *E coli*. Even though the phenylpropanolamine and local treatment of the perivulvar dermatitis helped improve host defense mechanisms, abnormalities were still present (USMI, abnormal vulvar anatomy). Subclinical urinary incontinence associated with USMI may persist despite phenylpropanolamine treatment. In addition, episioectomy may be considered if the perivulvar dermatitis persists or recurs.

Ancillary therapies designed to prevent recurrent UTIs are considered in cases where breaches in host defenses are present but not correctable or in which an underlying cause for reinfection is not identified. Ancillary therapies include urinary antiseptics and acidifiers, CE (see **Cranberry Extract & *E coli***), and prophylactic long-term, low-dose antibiotic treatment. Of note, these ancillary therapies have not been proven effective in controlled, prospective clinical trials.

Outcome

Once Georgia's recurrent UTI had been effectively treated (follow-up urine cultures had no growth), long-term CE treatment was initiated to help support her compromised host defense mechanisms. Recheck urinalyses were performed quarterly. Long-term prophylactic antibiotic treatment was not used because of the potential for creating an antimicrobial-resistant UTI. ■ **cb**

See **Aids & Resources**, back page, for references & suggested reading.

Dr. Grauer was a coinvestigator on a grant/study funded by Vetoquinol to assess in vitro effects of cranberry extract product on E coli adherence to canine kidney epithelial cells.