

Treatment Options for Oronasal Fistulae

Carlos A. Rice, DVM, DAVDC

Animal Emergency & Referral Associates

Fairfield, New Jersey

Oronasal fistulae can present with varying forms and causes, with chronic end-stage periodontitis being the most common cause (Figure 1). Oronasal fistulae are often associated with a diseased or missing maxillary tooth, but they can result from other congenital, traumatic, or neoplastic conditions affecting the primary and secondary palate.

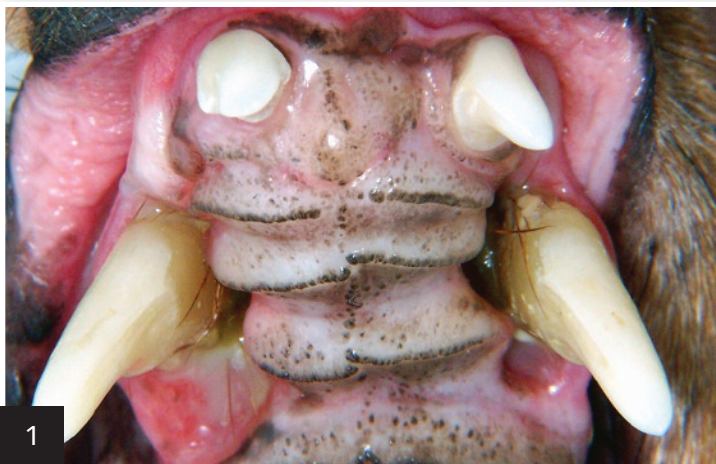An oronasal fistula may occur secondary to surgical extraction of a maxillary canine tooth. In these cases, excessive force placed on the crown causes medial tooth displacement, perforating the nasal surface of the alveolar bone (Figure 2, next page). An oronasal fistula can also result from extraction of a diseased or missing incisor, premolar, or molar (Figure 3, next page).

Affected patients often have a history of chronic rhinitis and present with ipsilateral mucopurulent or serohemorrhagic nasal discharge. Clinical signs often correlate positively with the defect's size and location; larger and caudally located defects are typically most clinical.

Regardless of the cause, treatment often involves surgical intervention.

Affected patients often have a history of chronic rhinitis and present with ipsilateral mucopurulent or serohemorrhagic nasal discharge.

MORE ►



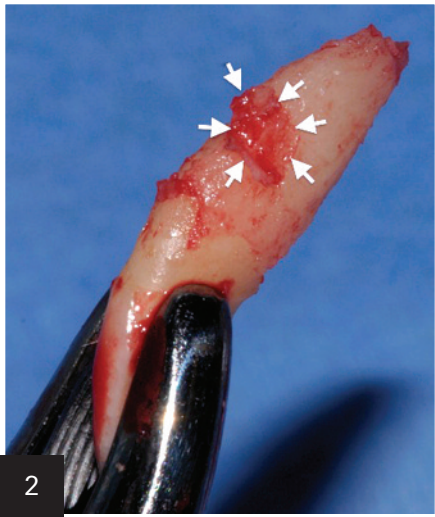
1

The most common cause of oronasal fistula is chronic end-stage periodontitis.

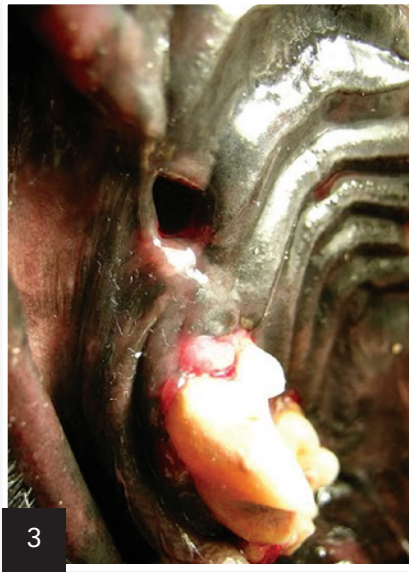Courtesy Dr. Jan Bellows

Surgical Treatment

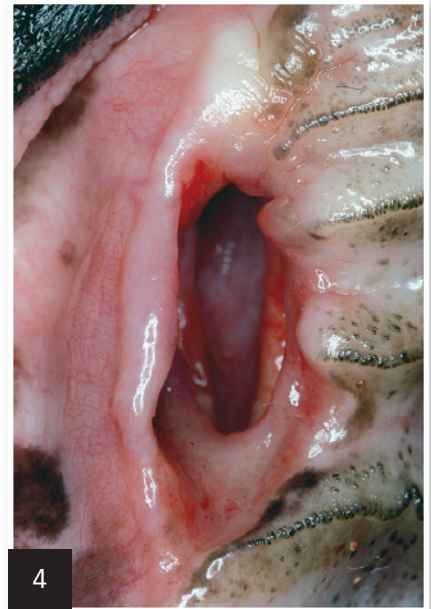Before surgery, a complete oral examination (eg, tooth-by-tooth assessment with periodontal probe, full-mouth intraoral radiography) must be performed while the patient is under general anesthesia. Basic principles of oral surgery must be followed: awareness of surgical anatomy, fundamentals of flap design, creation of tension-free closure, selection of appropriate suture material (Figures 4 and 5).



2
Surgically extracted maxillary canine tooth (note the small remaining piece of nasal alveolar bone [arrows])



3
Palatal defect associated with a previously extracted right maxillary third premolar (#107)
Courtesy Dr. Slava Eroshin



4
Typical appearance of a chronic nonhealing oronasal fistula following extraction of a right maxillary canine tooth (#104) in a dog
Courtesy Dr. Jan Bellows

5

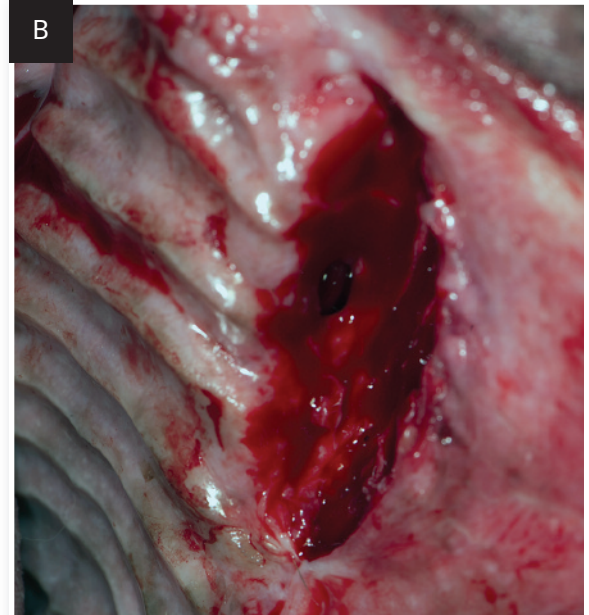
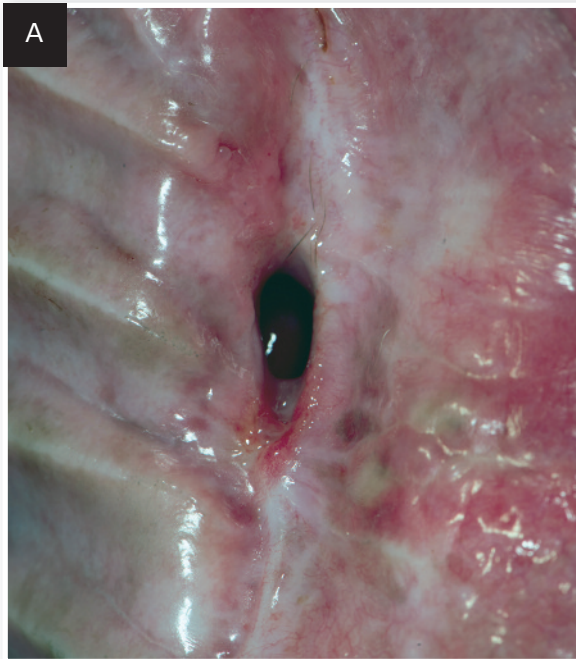Chronic nonhealing oronasal fistula secondary to extraction of a left maxillary canine tooth (#204, A)

A single mucoperiosteal pedicle flap was created (B).

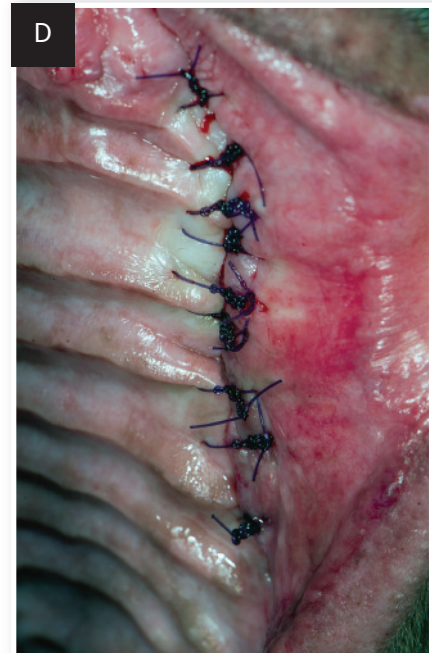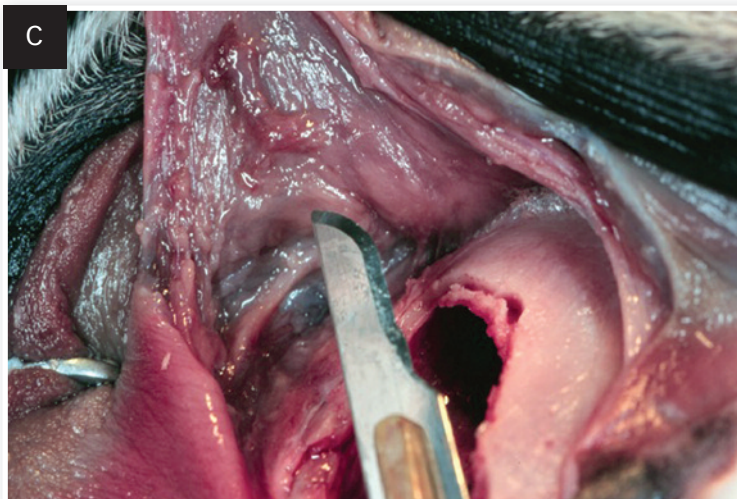
All epithelialized tissue surrounding the defect should be debrided. Releasing incisions are created at the mesial and distal aspects of the defect. The incisions must extend beyond the attached gingiva into the alveolar mucosa. The flap is at least twice as wide at the base as at the apex. A periosteal releasing incision

(C) is created to eliminate any tension along the entire suture line (demonstrated in a cadaver). Care must be taken to avoid perforating the mucoperiosteal flap during incision of the periosteum. A successful outcome is predicated on performing a tension-free closure.

The author's preferred suture pattern and material (D) are simple interrupted 4-0 or 5-0 absorbable monofilament sutures using a small taper needle.



Courtesy Dr. Jan Bellows



Courtesy Dr. Jan Bellows

MORE ►

Nonsurgical Treatment

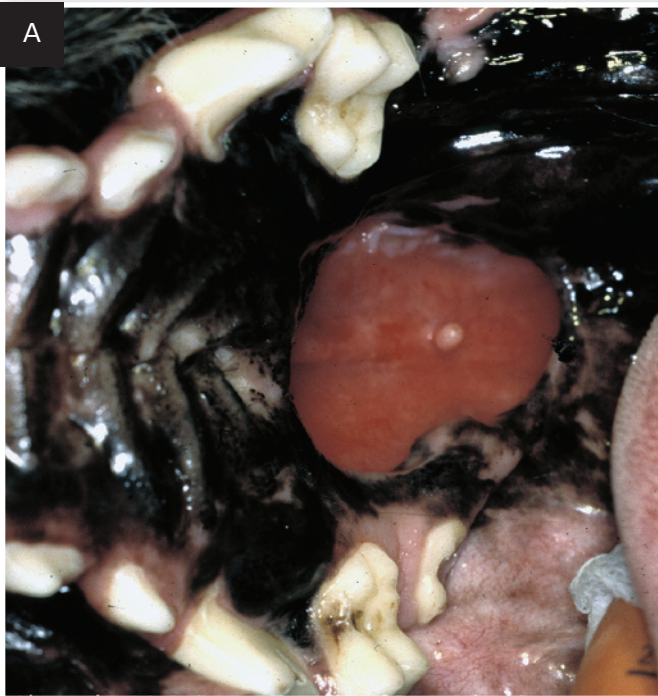
If the defect is not amenable to surgical management or previous surgical intervention has failed, a prosthetic palatal obturator can be considered. Palatal obturators can be obtained prefabricated and trimmed to fit the patient or can be custom made chairside with composite or acrylic (Figure 6).

6

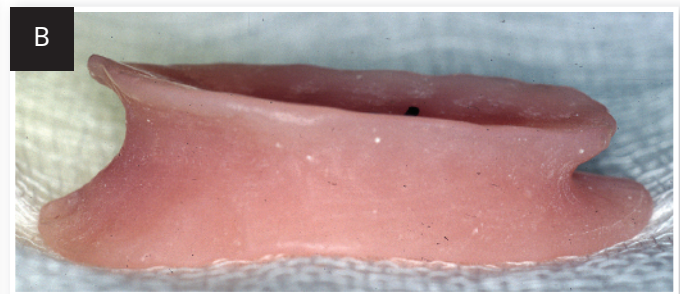
A large congenital defect of the caudal hard palate was present in a young golden retriever (A).

A custom-made acrylic prosthetic palatal obturator (B) was fabricated chairside from a polyvinyl siloxane negative of the defect.

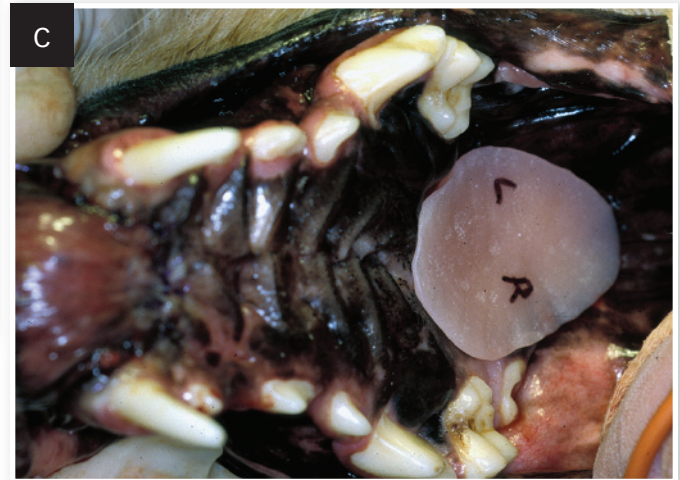The acrylic prosthesis fits snugly into the defect (C) and prevents food and debris from entering the nasal cavity. Care typically includes semiannual follow-up visits, which may involve sedation or anesthesia to remove, clean, and reposition the prosthesis. If the prosthesis no longer fits, a new impression of the defect should be made and a new obturator fabricated.



© Dr. Alexander M. Reiter



© Dr. Alexander M. Reiter



© Dr. Alexander M. Reiter

When to Refer

Scarring from previous surgery may result in less elastic tissue and compromised blood supply, potentially impairing healing after future surgeries; thus, the first attempt to close a palatal defect is typically the best one.

Because surgical treatment of most palatal defects is technique sensitive, palate surgery can prove challenging. Referral to a board-certified veterinary dentist and oral surgeon (avdc.org) should often be considered. ■ **cb**

See **Aids & Resources**, back page, for references & suggested reading.