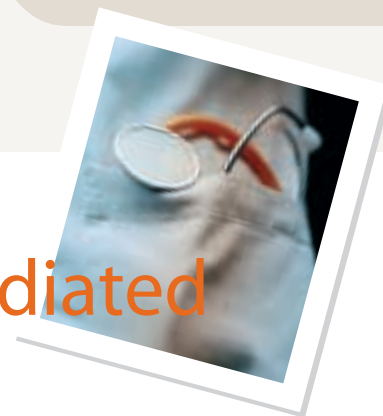



Treatment of Canine Primary Immune-Mediated Hemolytic Anemia

Ann E. Hohenhaus, DVM, Diplomate ACVIM (Oncology & Internal Medicine), The Animal Medical Center, New York, New York

P Profile

DEFINITION

Primary IMHA is caused by an autoantibody directed against an epitope on the red blood cell membrane. Unlike secondary IMHA—which is caused by formation of antibodies induced by microorganisms, drugs, or previous transfusions—the event that results in formation of antibodies is unknown in primary IMHA.

Systems

Although the primary body system affected is the erythron, immune-mediated thrombocytopenia can occur concurrently (Evans's syndrome). In addition to the hematopoietic system, other body systems are affected by such sequelae as pulmonary thromboembolism, systemic thromboembolism, disseminated intravascular coagulation, hepatic dysfunction, and gastric ulceration and hemorrhage.

Incidence/Prevalence/Geographic Distribution

IMHA occurs worldwide. Neither the incidence nor the prevalence has been determined. An increase in cases during the summer as been reported.^{1,2}

Signalment

Breed Predislection. Many breeds of dogs have been reported to be predisposed. The strongest evidence for a breed predislection is in cocker spaniels, which have been impli-

cated in several studies.¹⁻⁷ Other breeds include English springer spaniels, collies, poodles, and miniature schnauzers.

Age and Range. Dogs are diagnosed from 1 to 13 years, with a median of 6 years.

Gender. Intact and spayed females are overrepresented.

Causes/Risk Factors

Several studies have attempted to identify a link between vaccination and IMHA. Only one study has found an increase in vaccinated dogs.⁸ The absence of dog erythrocyte antigen 7 in cocker spaniels has been shown to be a risk factor for IMHA.³

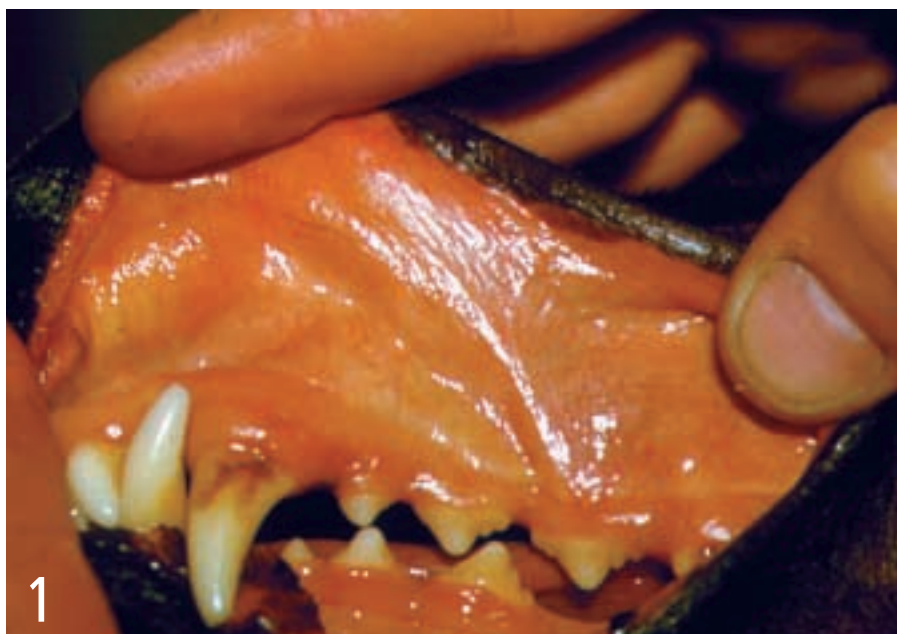Pathophysiology

A type II hypersensitivity reaction mediates destruction of red blood cells in IMHA.⁹ Antibodies specific for a component of the red blood cell membrane binds to red blood cells. Destruction of these cells occurs in the spleen (extravascular) or, following complement fixation, hemolysis occurs intravascularly. Antibodies may be directed at red blood cell precursors, resulting in a nonregenerative variant of IMHA.¹⁰ Antibodies are from either the IgG or the IgM class.

Signs

Vague and usually referable to acute anemia, including acute onset of depression,

continues



1 Icteric mucous membranes in a dog with severe immune-mediated hemolytic anemia

Courtesy Dr. Colin Burrows

IMHA = immune-mediated hemolytic anemia

anorexia, weakness, and lethargy. Owners may report discolored urine.

History

Ingestion of acetaminophen and onions and administration of vitamin K may cause hemolytic anemia. Obtain a careful history to identify these causes and treat them appropriately.

Physical Examination

Pale, often icteric mucous membranes (**Figure 1**). Pigmenturia from either hemoglobinurina or bilirubinurina. In severe cases, tachycardia and a heart murmur may be found; palpation reveals hyperdynamic pulses. Abdominal palpation identifies hepatomegaly or splenomegaly in 40% of cases.⁶ Petechiae appear if concurrent immune-mediated thrombocytopenia is present. Occasionally, lymphadenopathy is present.

Pain Index

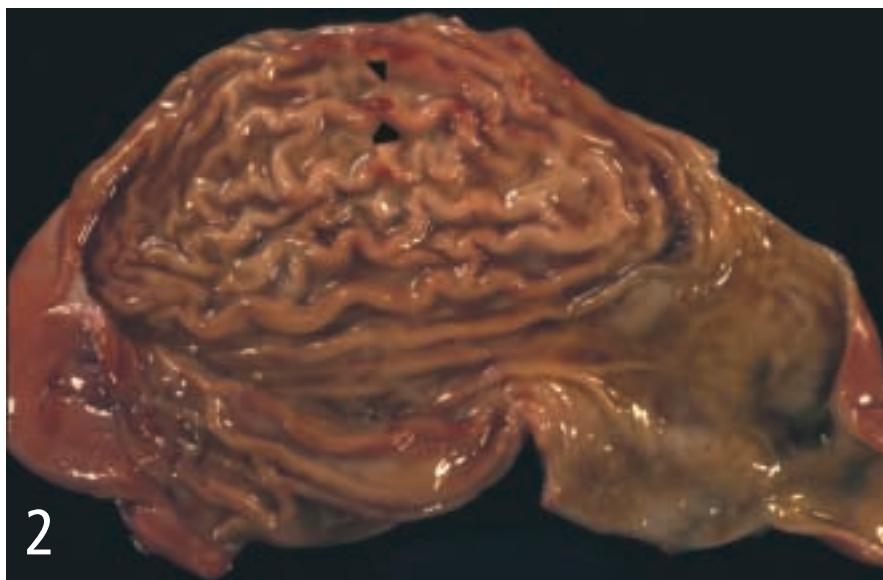
Pain is not a prominent feature.

Dx Diagnosis

Not typically made on the basis of history or physical examination findings. A minimum database is obtained during evaluation of an acutely ill dog, the results of which indicate anemia resulting from a hemolytic process. Identifying a hemolytic disorder and eliminating causes of secondary IMHA make the definitive diagnosis of IMHA. Several disease processes can cause hemolytic anemia in dogs, such as zinc toxicosis; infectious diseases, such as ehrlichiosis, mycoplasmosis (hemobartonellosis), babesiosis, and bartonellosis; neoplasia (hemangiosarcoma or lymphoma); and drug or onion toxicity. Because of this wide range of differential diagnoses and the array of diagnostic tests needed to rule them out, diagnosis is not covered in this article.

POSTMORTEM FINDINGS

The prominent feature is macro- and microthrombi coupled with systemic fibrin deposition.¹¹ Pulmonary thromboemboli are



Gastric erosions seen on necropsy in a dog treated with prednisone. The dog died of sepsis.

commonly associated with acute death. Thrombi are also seen in abdominal organs; in one study, the spleen was the most commonly affected organ.¹

Tissue necrosis and infarction, which result from a lack of blood flow, are other post-mortem findings. Infarction, which occurs after formation of an embolus, frequently occurs in the spleen, heart, and kidneys. Necrosis occurs independent of embolism and is postulated to result from anemia-induced hypoxia, as evidenced by centrilobular necrosis in the liver.

Complications of therapy are often identified during necropsy. Secondary infections, such as pneumonia or pyelonephritis, occur as a result of immunosuppressive therapy. Gastric erosions and gastric ulcers have been described as a sequela to prednisone therapy (Figure 2).

Tx Treatment

INPATIENT OR OUTPATIENT

Because the published studies of treatment of dogs with IMHA originate from teaching hospitals, bias toward inclusion of sicker dogs and management of dogs with IMHA as inpatients is likely. Consequently, reported cases are managed as inpatients and the average hospital stay is 6 days.^{1,5,6}

TRANSFUSION THERAPY

Most dogs with IMHA receive packed red blood cell transfusions as a treatment for anemia (Figure 3). Those who have comorbid disseminated intravascular coagulation, with prolonged prothrombin and activated partial thromboplastin times, should also receive fresh frozen plasma. Routine transfusion of fresh frozen plasma is not recommended because it does not prevent

pulmonary thromboembolism. Theoretically, providing increased oxygen-carrying capacity with a hemoglobin solution lacking the antigenic red blood cell membrane of intact red blood cells should provide a treatment advantage, although one study showed the opposite effect.¹²

However, because of this study's retrospective design, its results cannot be considered to provide definitive evidence against the use of hemoglobin-based oxygen carriers in IMHA.

ACTIVITY

Activity restriction is unnecessary—the critical nature of the illness often prevents ambulation.

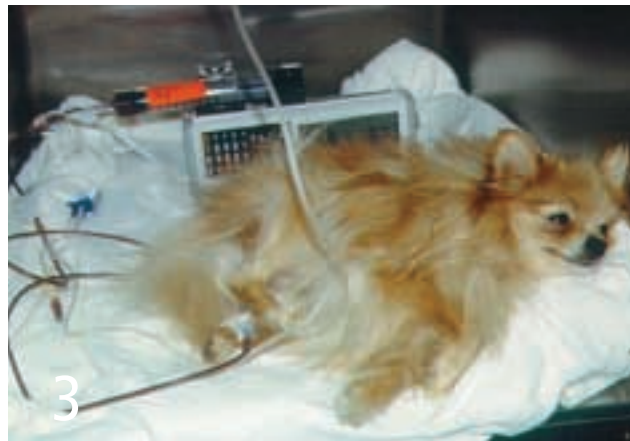Drug Therapy

ANTIBIOTIC THERAPY

Administer doxycycline while the results of infectious disease tests are pending. In dogs with secondary infections from immunosuppressive agents, the type of infection or culture results will dictate antibiotic choice.

IMMUNOSUPPRESSIVE AGENTS

Prednisone is considered first-line therapy, although its use has not been evaluated in a clinical trial. The benefit of adding other immunosuppressive agents to prednisone therapy is unclear because the data are conflicting. The information on the outcome of treatment with azathioprine is mixed, despite its having been recommended for treatment of IMHA for decades. All studies of azathioprine use are retrospective. One



Courtesy Dr. Colin Burrows

Blood transfusions are an aspect of treatment in most dogs with immune-mediated hemolytic anemia.

study showed no survival advantage in dogs given azathioprine in addition to prednisone¹² and 3 showed a survival advantage.^{1,4,6} Because the dogs were not randomly assigned to the various treatment groups, selection bias is likely, as the dogs treated with azathioprine may have had a better prognosis than those not treated with azathioprine. Mounting retrospective and prospective data suggest that cyclophosphamide administration does not benefit dogs with IMHA.^{5,7,12} Evidence from three retrospective studies suggests that IV immunoglobulin may be effective in controlling hemolysis on a short-term basis, but as with azathioprine, a randomized, controlled trial must be done to confirm this interpretation of the available evidence.¹²⁻¹⁴ Currently, few data are available on the outcome of dogs given cyclosporine.

ANTICOAGULANT THERAPY

The anticoagulant effects of unfractionated heparin, low-molecular-weight heparin, and aspirin have been studied in dogs. To date, no dose of heparin has been shown to prevent thromboembolic disease.^{1,5} An ultralow dose of aspirin (0.5 mg/kg daily) was associated with improved survival, but its effect on rates of thromboembolism were not reported.¹

continues



Follow-up

CLIENT EDUCATION

Clients must be made aware of the high mortality rate and the possibility of sudden death from pulmonary thromboembolism.

PATIENT MONITORING

Dogs released from the hospital should be examined once a week until the CBC indicates consistent improvement or stabilization of hematologic values. Owners should monitor the pet for lethargy or discolored urine, which may indicate relapse. Dogs maintained on long-term prednisone therapy or any other immunosuppressive agents should have urine obtained for culture every 3 months to identify subclinical urinary tract infections.

LONG-TERM MANAGEMENT

Because of the side effects from immunosuppressive drugs, they should be tapered gradually over approximately 12 months after control of hemolysis. However, relapse is common and can occur after therapy has been stopped or even while the patient is still receiving immunosuppressive drugs. Prednisone is typically administered at a dose of 1 to 2 mg/kg twice daily. Once hemolysis ceases, the dose is decreased by approximately 25% every 2 to 6 weeks until a dose of 0.5 mg/kg every other day is achieved. The dog should be maintained at this dose for 6 or more months. Tapering the

dose of azathioprine is often done after the dose of prednisone reaches an every-other-day regimen.



In General

RELATIVE COST

Hospitalization at an average stay of 6 days may cost as much as \$5000 because of the need for 24-hour-a-day ICU care, laboratory testing to rule out causes of secondary IMHA, and multiple transfusions.

PROGNOSIS

The rate of death is highest in the first two weeks after diagnosis. Laboratory factors associated with a poor prognosis include elevated bilirubin levels, low packed cell volume, and low reticulocyte count. One year after diagnosis, approximately 50% of dogs are still alive.^{2,4,6} Dogs may die acutely from pulmonary thromboembolism even if the anemia has resolved with immunosuppressive therapy.

FUTURE CONSIDERATIONS

Identification of the optimal protocol to prevent pulmonary thromboembolism is essential to improving outcome. ■

See Aids & Resources, back page, for references, contacts, and appendices.



at a glance

• Antibiotic Therapy

- Doxycycline 10 mg/kg once daily
- Other antibiotics, pending culture results
- Immunosuppressive agents
- Prednisone, 1–2 mg/kg Q 12 H tapered over 6–12 months
- Azathioprine, 2 mg/kg tapered to 0.5 mg/kg every other day
- IV immunoglobulin, 0.5–1 g/kg as an infusion over 6–8 hours

• Anticoagulation Therapy

• Transfusion Therapy

Doses of blood products are approximate.

- Blood products are administered until clinical signs of anemia or coagulopathy resolve.
- Packed red blood cells 6-10 ml/kg intravenously
- Fresh frozen plasma (for dogs with comorbid disseminated intravascular coagulation and prolonged prothrombin and activated partial thromboplastin times), 6–10 ml/kg IV; repeat prn

COMING SOON

to these pages...

- **NEW! Applied Endoscopy:** Canine Protein-Losing Enteropathy
- **Procedures Pro:** Urethral Catheterization
- **Consultant on Call:** Treatment of Chronic Gastrointestinal Disease
- **How to Refer:** Diabetes
- **Make Your Diagnosis:** Anaphylaxis in Cats

Plus, of course, Capsules, Diagnostic Tree, Applied Cytology, Comparative Imagery, and much more!