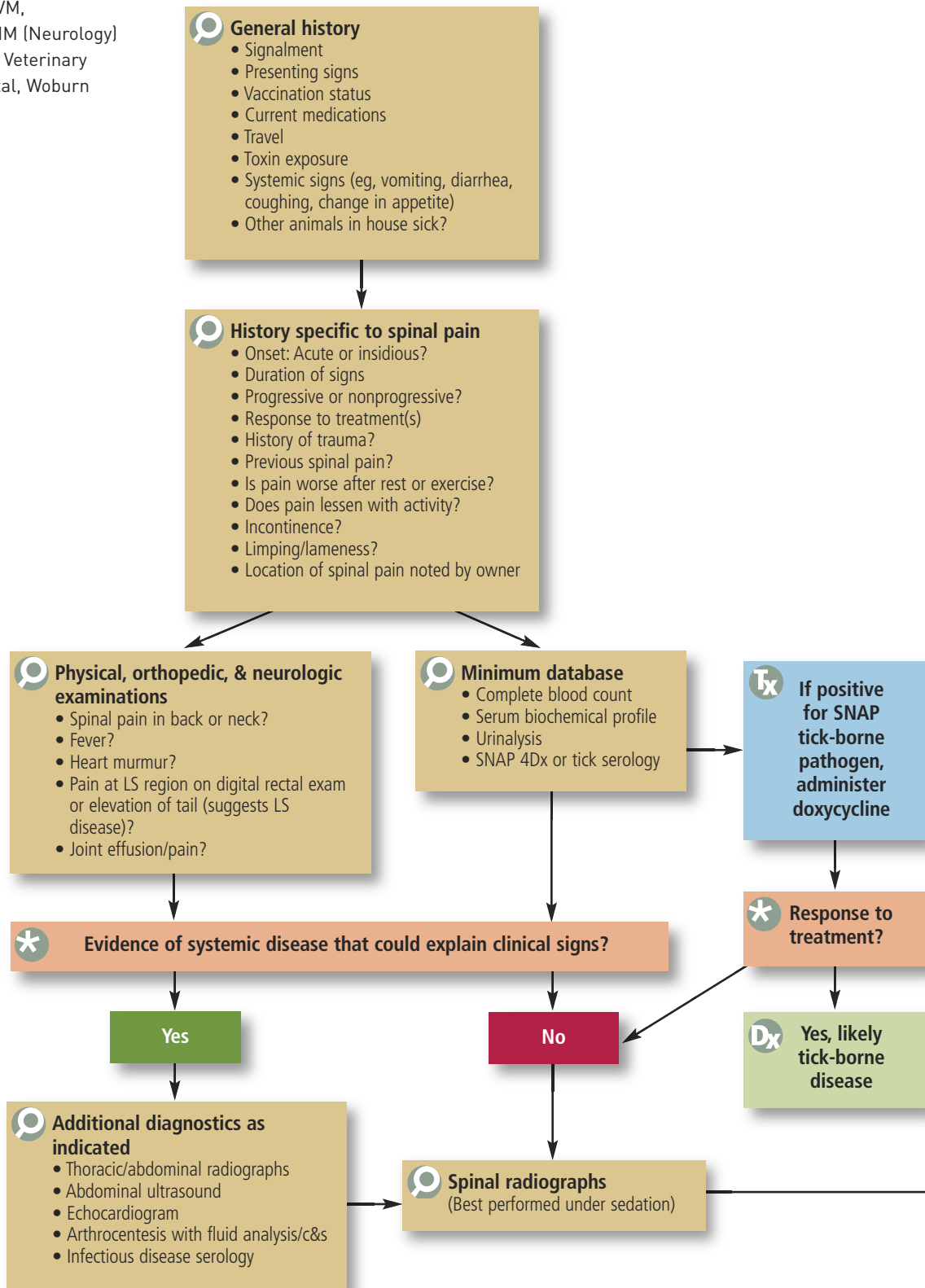
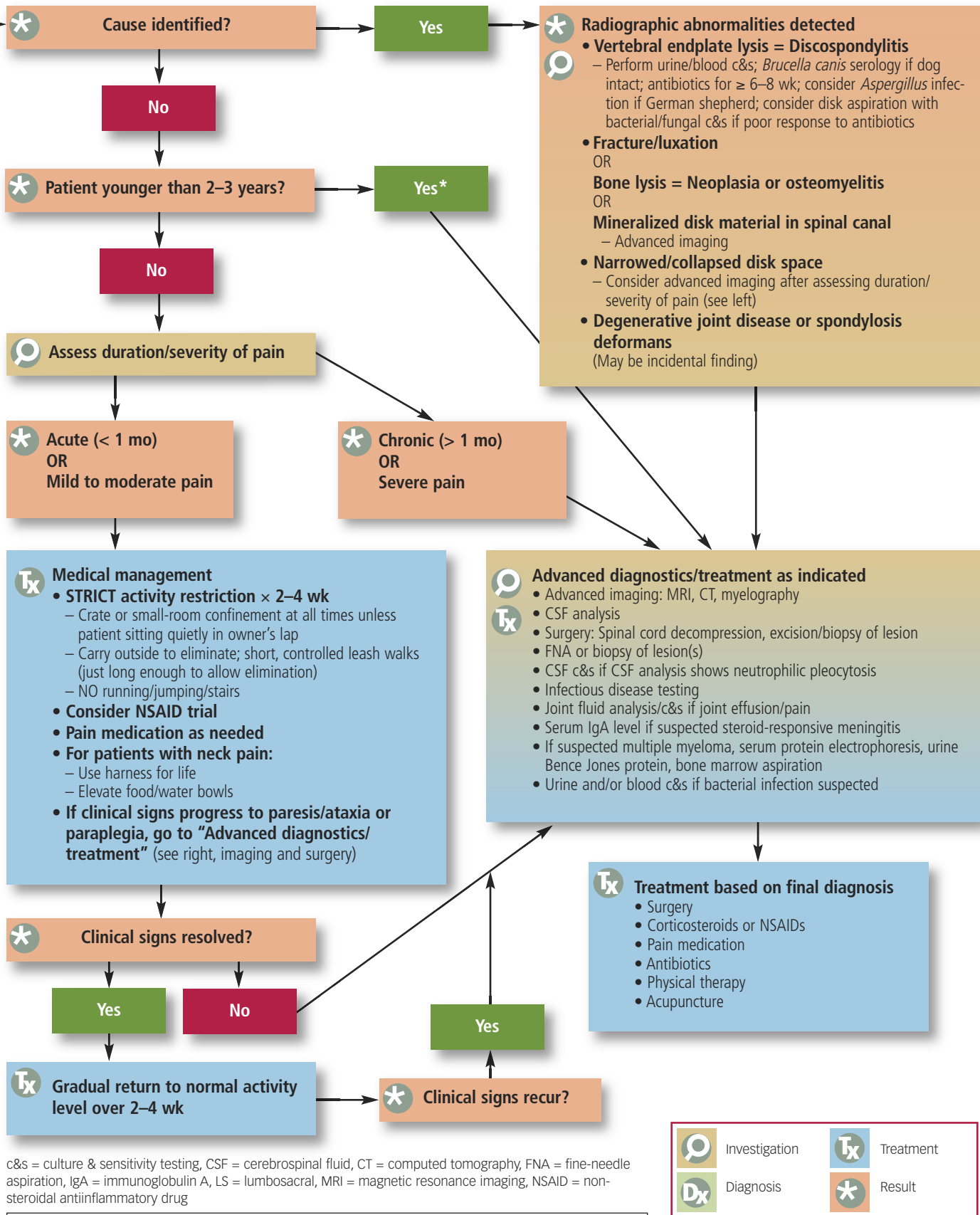


Spinal Pain

Mark Troxel, DVM,
Diplomate ACVIM (Neurology)
Massachusetts Veterinary
Referral Hospital, Woburn





c&s = culture & sensitivity testing, CSF = cerebrospinal fluid, CT = computed tomography, FNA = fine-needle aspiration, IgA = immunoglobulin A, LS = lumbosacral, MRI = magnetic resonance imaging, NSAID = non-steroidal antiinflammatory drug

*** Patients younger than 2 to 3 years are more likely to have meningitis than intervertebral disk disease, so early intervention is recommended.**

	Investigation		Treatment
	Diagnosis		Result

This algorithm can be downloaded and printed for use in your clinic at cliniciansbrief.com/journal.