

Elizabeth A. Giuliano, DVM, MS, Diplomate ACVO, University of Missouri–Columbia

Exophthalmos in a Dog

An 8-year-old, 4.8-kg, spayed female dachshund presented with a 4-day history of progressive, bilateral exophthalmos.

Physical Examination. No pain or restriction was detected when opening the mouth. No pain, atrophy, or swelling of the temporalis or masseter muscles was noted. Complete ophthalmic examination revealed bilateral restrictive exophthalmos and nictitans elevation with slight exotropia (OD > OS), superficial corneal erosion OS, mild anterior uveitis OS, and distichiasis OU (**Figure 1**).

Initial Diagnostics. Results of a CBC, chemistry profile, serum creatine phosphokinase (CK), and urinalysis were normal. Total thyroxine (T₄) and triiodothyronine (T₃), free T₃ and T₄, T₃ and T₄ autoantibodies, and thyroid-stimulating hormone levels were normal. Serum IgG titers for *Blastomyces dermatitidis*, *Histoplasma capsulatum*, *Cryptococcus neoformans*, *Neospora caninum*, and IgG and IgM titers for *Toxoplasma gondii* were negative.

Lupus erythematosus and antinuclear antibody testing were negative. The patient's fresh frozen serum was incubated with normal canine extraocular muscle and staphylococcal protein A conjugated with horseradish peroxidase (SPA-HRPO), then stained for peroxidase localization.¹ No labeling of myofiber components was observed. Serology for type 2M myofibers was negative.^{2,3} Thoracic radiographs demonstrated no evidence of neoplasia or fungal disease.



Bilateral extraocular photograph of the patient showing bilateral exophthalmos, slight exotropia (OD > OS), and bilateral elevation of the third eyelid. A focal, axial, superficial corneal erosion was also present in the left eye.

ASK YOURSELF ...

What additional diagnostic testing should be pursued?

- A. Schirmer's tear test and rose bengal stain
- B. Ultrasonography, CT, and muscle biopsy
- C. Fluorescein stain and intraocular pressure measurement
- D. Conjunctival biopsy
- E. Gonioscopy with scleral depression

CBC = complete blood count; CT = computed tomography; MRI = magnetic resonance imaging; OD = right eye; OS = left eye; OU = each eye

Correct Answer: B Ultrasonography, CT, and muscle biopsy

Diagnostic imaging techniques are often useful in the diagnosis of exophthalmos (protrusion of the globe out of the orbit). In this patient, ocular ultrasound revealed markedly swollen extraocular muscles OU (**Figure 2**) with homogeneous low-reflective enlargement, suggestive of myositis.^{4,7}

Head CT and extraocular muscle biopsy were performed under general anesthesia. Enlargement of the extraocular muscles was apparent OU (**Figure 3**). No bone lysis, soft tissue mineralization, orbital fractures, foreign bodies, or other abnormalities were detected. Open extraocular muscle biopsy was performed. Dorsal rectus muscle with tendinous insertion (7 mm × 1 mm) was harvested from the lateral one third of the muscle belly.⁵ Fixed and frozen biopsy sections were submitted for complete muscle profiles. These biopsies showed myofibers and dense connective tissue mixed with cellular infiltrates (lymphocytes,

macrophages, and scattered eosinophils) in an endomysial distribution (**Figure 4**).

Diagnosis. This patient's clinical signs, signalment, medical history (previously healthy and current on vaccinations and heartworm prevention), and regional habitat (Midwest), coupled with the results of ophthalmic examination, were highly suggestive of bilateral extraocular polymyositis (BEP). The most likely cause of the focal, axial corneal erosion OS was exposure keratitis secondary to the lagophthalmos.⁸

Orbital myositis is a well recognized, idiopathic inflammatory condition involving one or more extraocular muscles.^{4, 5, 9-14} Canine bilateral extraocular polymyositis is a unique type of orbital myositis characterized by a mononuclear inflammatory cell infiltrate of all extraocular muscles except for the retractor bulbi.^{8,15,16}

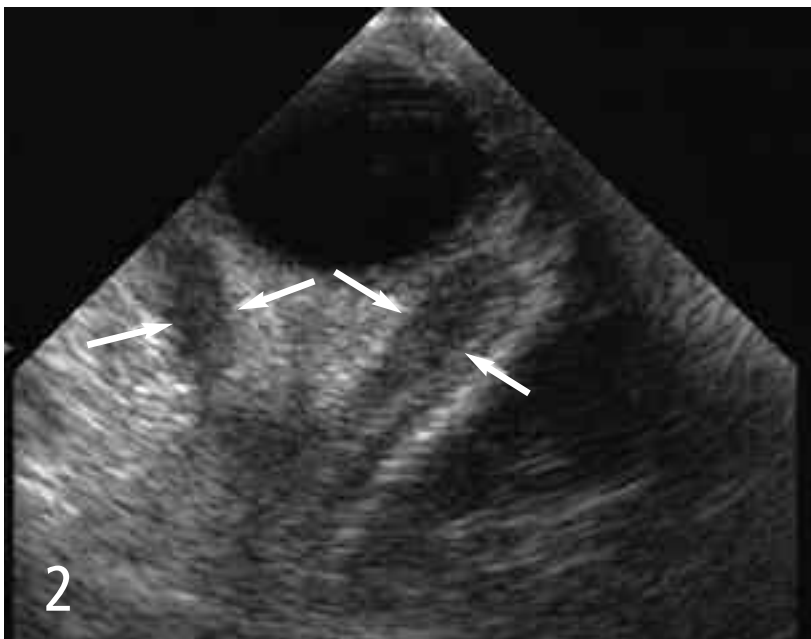When supportive clinical findings are present, diagnosis is based on several criteria: Masticatory muscle myositis should be ruled out based on normal CK levels and lack of autoantibodies against type 2M myofibers in extraocular tissue sections and patient sera.^{2, 8, 17, 18} Normal thy-

roid function should be established; other systemic infectious, autoimmune, or neoplastic disease should be excluded; imaging studies should demonstrate abnormalities limited to the extraocular muscles; and characteristic extraocular muscle histology should be documented.^{8, 16, 19-27} Exact etiology of BEP is currently unknown; however, an autoimmune pathogenesis has been proposed based on pattern of muscle involvement, pathologic characteristics, and response to therapy.^{15,16}

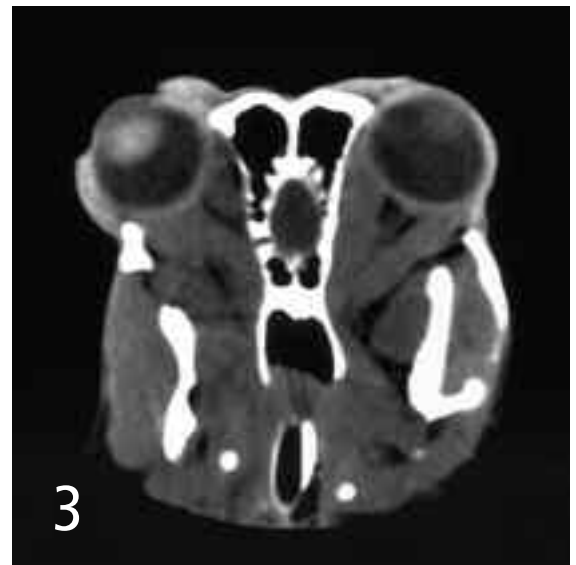Differential Diagnosis. Differential considerations for canine exophthalmos are numerous. This condition may result from primary orbital conditions or secondary to disease extension from surrounding tissues, including the oral cavity, muscles of mastication, brain, globes, nasal sinuses, or mandibular ramus.^{17, 28-34}

Treatment. Objectives were to resolve the extraocular myositis and prevent additional muscle fibrosis by treating with immunosuppressive agents, minimize exposure keratitis OU, prevent secondary corneal infection OS, and treat the reflex uveitis OS.

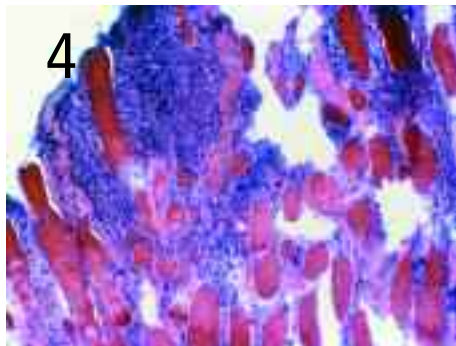
continues



Ocular ultrasonography of the right eye. Note the markedly swollen extraocular muscles (arrows) with homogeneous low-reflective enlargement, diagnostic of myositis. The appearance of the left eye was similar.



A 43° oblique dorsal plane CT image. This technique was used to optimize extraocular muscle imaging. Abnormalities were limited to bilateral extraocular muscle enlargement.



4 Photomicrograph demonstrating the histologic characteristics of the dorsal rectus muscle biopsy. Myofibers infiltrated with lymphocytes, macrophages, and scattered eosinophils in an endomyisial distribution are seen. (Hematoxylin and eosin stain; magnification 20×)



5 Bilateral extraocular photograph obtained at 6-month recheck. No evidence of exophthalmos or corneal ulceration was seen OU. The dog had excellent ocular motility.

Initial treatment consisted of prednisone (1 mg/kg PO Q 12 H), azathioprine (2 mg/kg PO Q 24 H), triple antibiotic ointment (OU Q 6 H), atropine (OS Q 24 H for 3 days), and an Elizabethan collar to prevent self-trauma. Prednisone and azathioprine were initiated concurrently due to histologic evidence of sclerosing inflammation. Immunoregulatory agents such as cyclophosphamide, azathioprine, methotrexate, and/or cyclosporine, in combination with corticosteroid therapy, may reduce the amount of fibrosis and cicatricial sequelae to this type of extraocular inflammation.⁵

Outcome. Two weeks after initial presentation, complete ophthalmic examination revealed marked improvement in exophthalmos, ocular motility, and retropulsion OU. Clinical evidence of BEP was resolved by 3 weeks.

Serial CBC and serum chemistry panels were monitored for side effects from systemic therapy. Prednisone taper began at 3 weeks; the drug was discontinued at 8 weeks. Azathioprine was slowly tapered and was discontinued at 10

TAKE-HOME MESSAGES

- Extraocular muscle myositis should be considered as a differential diagnosis in dogs presenting with sudden-onset bilateral exophthalmos.
- Imaging modalities such as ultrasound, CT, and/or MRI are often very helpful in reaching a diagnosis, since swelling of the extraocular muscles is evident.
- Patients generally respond favorably to immunosuppressive therapy, although recurrence is possible. Careful monitoring is warranted.

weeks. Caution should be exercised to avoid tapering immunosuppressive therapy too quickly, which imposes risk of a recurrence in clinical signs.

At 6 months, the dog had not received any medical therapy for 4 months, demonstrated no recurrence in BEP, had no restrictive fibrosis, and had good ocular motility OU (**Figure 5**). The patient is currently disease free but continues to be regularly monitored. ■

See Aids & Resources, back page, for references, contacts, and appendices.

Article archived on www.cliniciansbrief.com

Tx at a glance...

- Prednisone: 1 mg/kg PO Q 12 H
- Azathioprine: 2 mg/kg PO Q 24 H
- Triple antibiotic ointment: OU Q 6 H
- Atropine: OS Q 24 H for 3 days

BEP = bilateral extraocular polymyositis; CBC = complete blood count; CT = computed tomography; MRI = magnetic resonance imaging; OS = left eye; OU = each eye