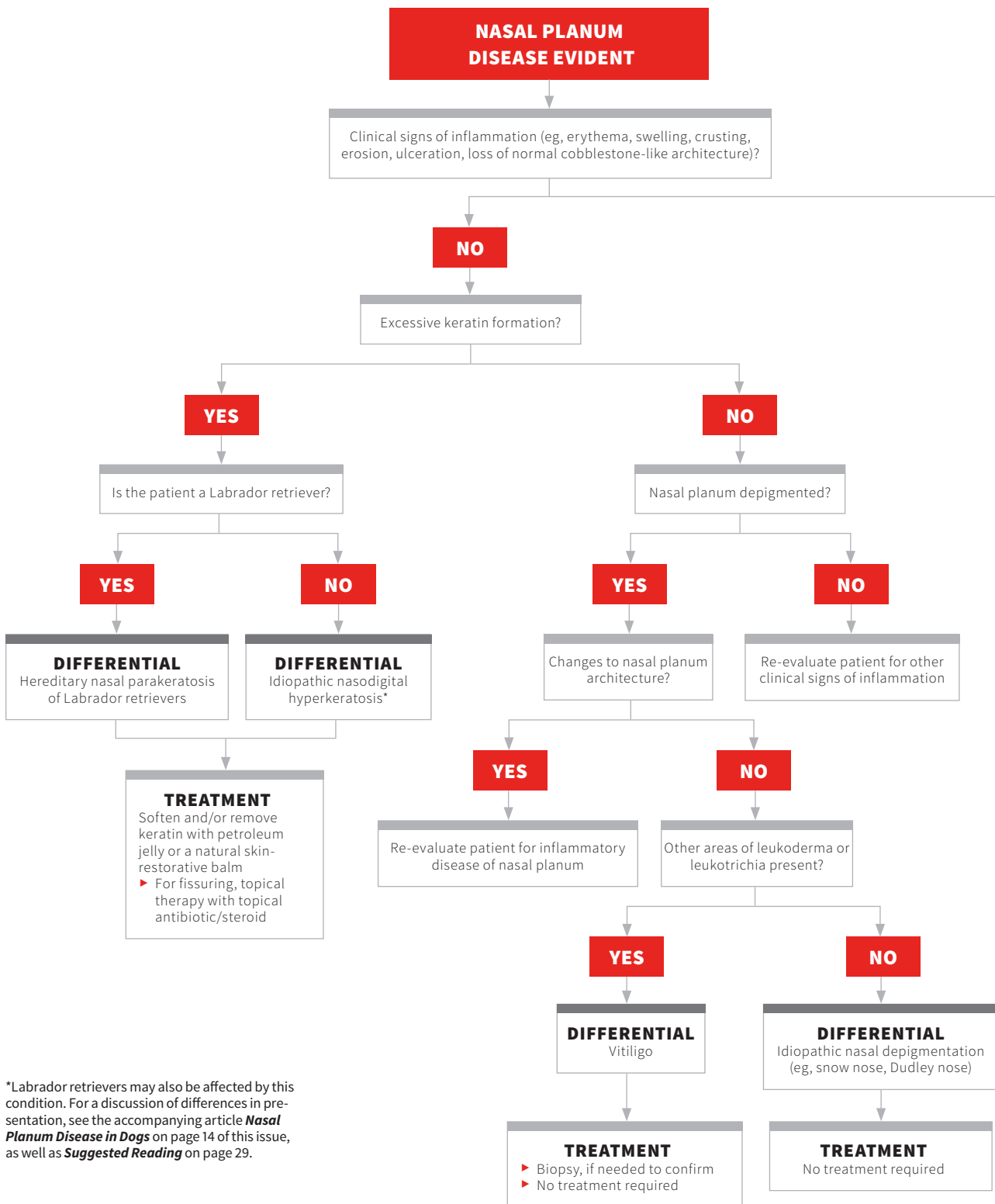
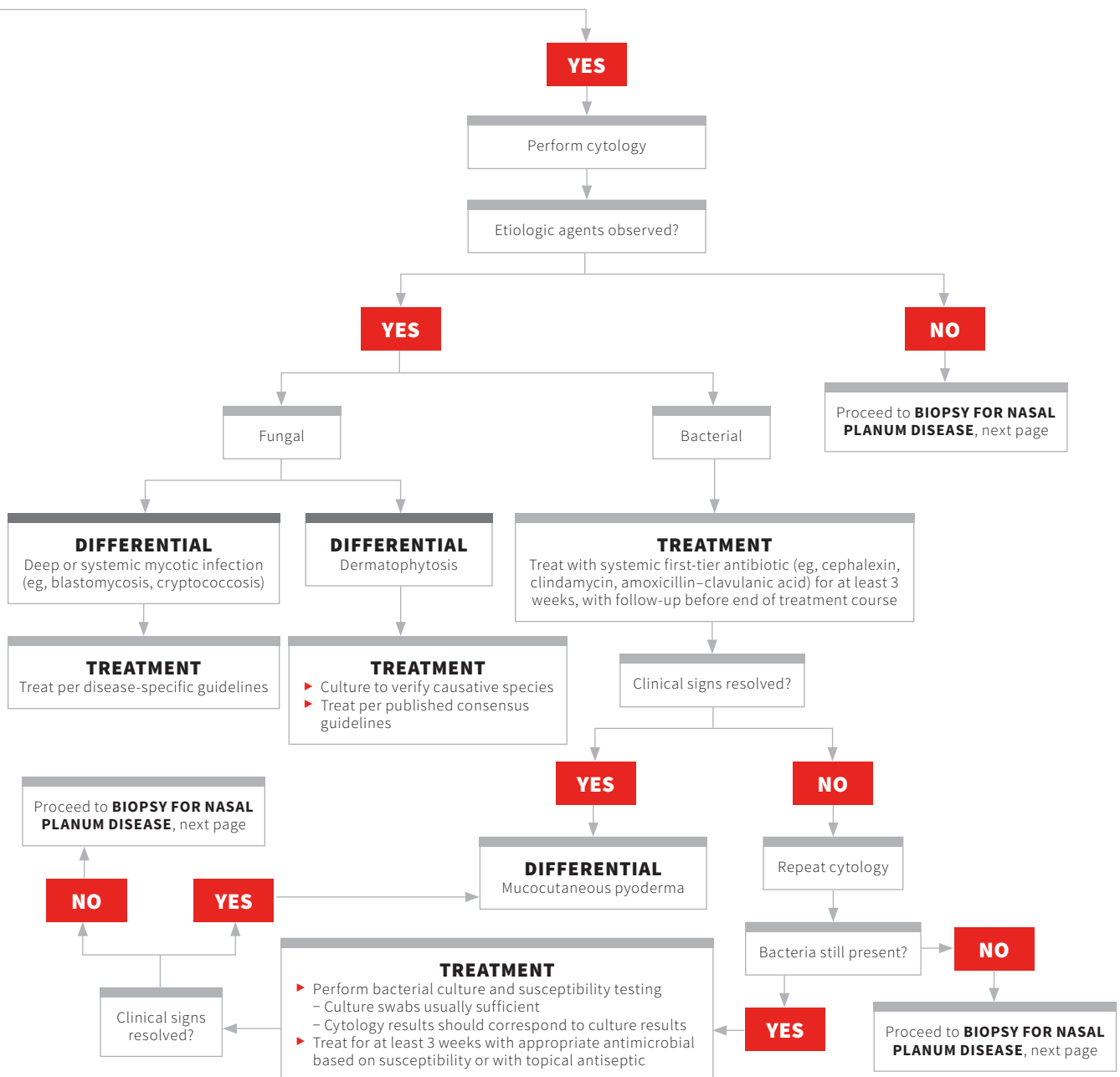


# DIAGNOSING NASAL PLANUM DISEASE IN DOGS

Darren Berger, DVM, DACVD  
Iowa State University



\*Labrador retrievers may also be affected by this condition. For a discussion of differences in presentation, see the accompanying article *Nasal Planum Disease in Dogs* on page 14 of this issue, as well as *Suggested Reading* on page 29.



## BIOPSY FOR NASAL PLANUM DISEASE

Clinical signs or diagnostic test results consistent with uveitis?

**YES**

**DIFFERENTIAL**  
Uveodermatologic syndrome

**TREATMENT**  
Systemic and topical therapy to prevent ocular complications

**NO**

Focal, well demarcated linear or circular ulceration of the nasal philtrum?

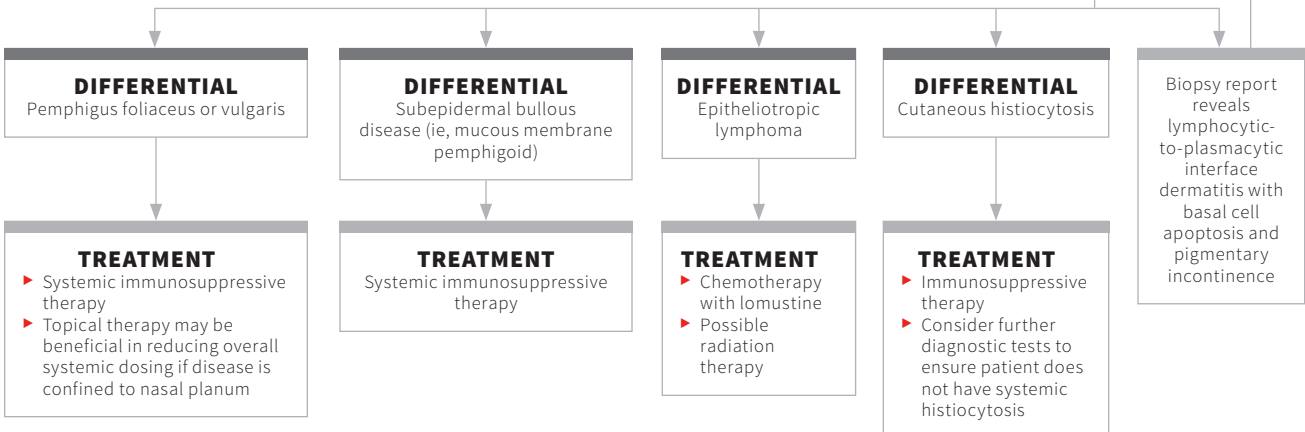
**YES**

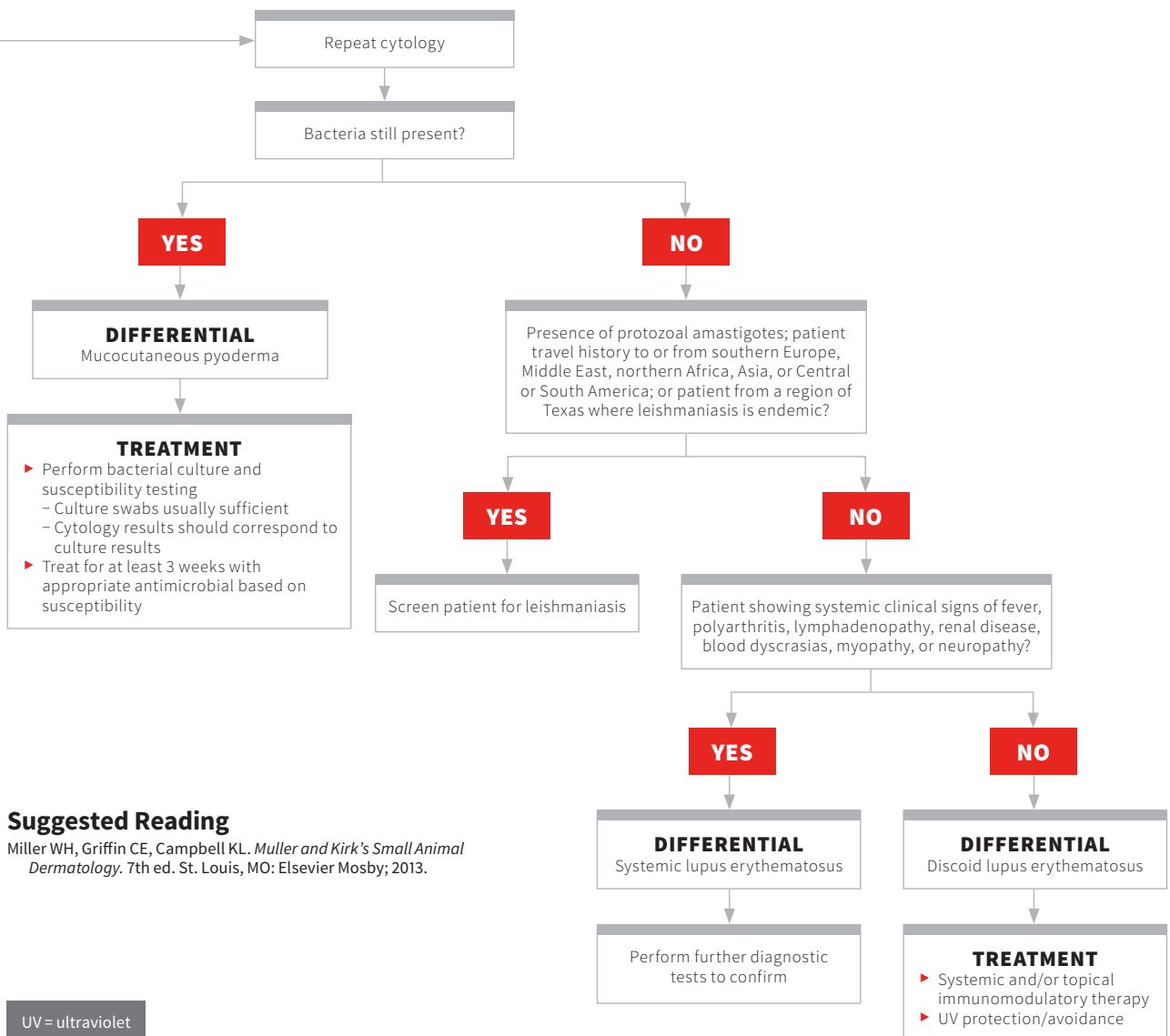
**DIFFERENTIAL**  
Dermal arteritis of the nasal philtrum

**TREATMENT**  
Systemic immunosuppressive medications and/or topical steroids or tacrolimus

**NO**

Biopsy the nasal planum





**Suggested Reading**

Miller WH, Griffin CE, Campbell KL. *Muller and Kirk's Small Animal Dermatology*. 7th ed. St. Louis, MO: Elsevier Mosby; 2013.

UV = ultraviolet