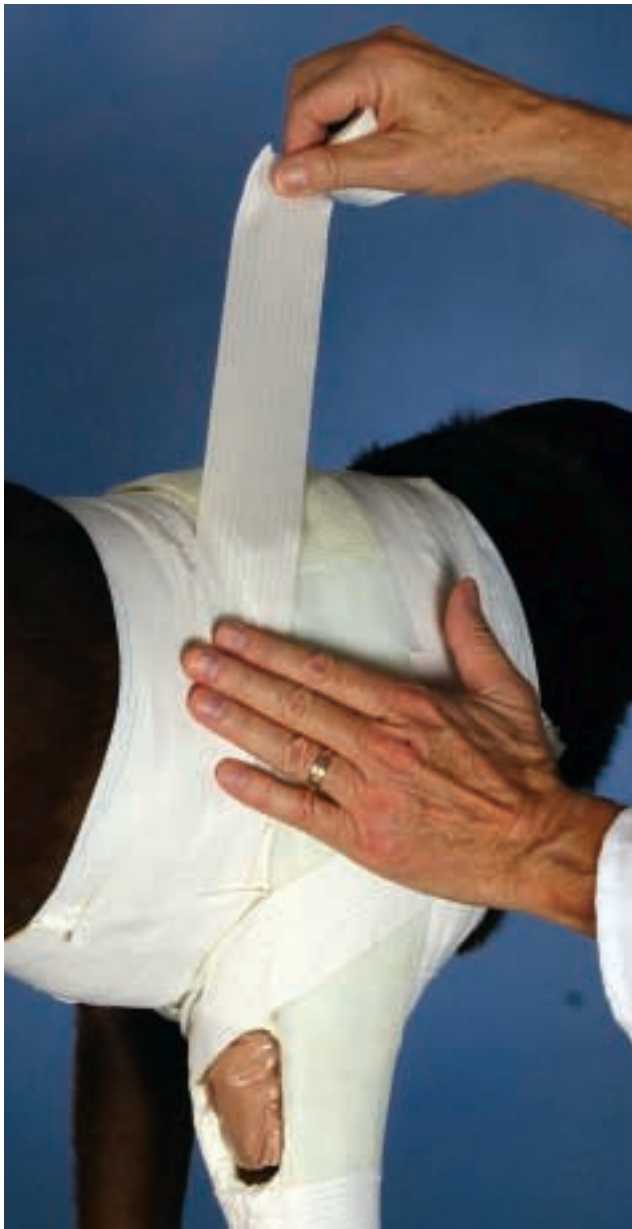

Bandaging and Splinting Canine Elbow Wounds

Steven F. Swaim, DVM, MS, Auburn University, Alabama, and Mark W. Bohling, DVM, University of Tennessee



Why Bandage and Splint Elbow Wounds?

Wounds in the elbow area require special attention to promote healing. Two factors are important in bandaging and splinting this area: extension and immobilization.

Movement of wounded tissue causes nonhealing or abnormal healing. On the flexion surface of the elbow, movement can impair healing of sutured, grafted, and flap-repaired wounds. In the presence of an open wound, flexion can also result in wound contraction, ending in a constricted wound (i.e., wound contracture) and restricted joint movement. On the extension surface (over the olecranon) of the joint, flexion separates the wound edges, due to outward tension, and impairs healing. Thus, immobilization of the joint promotes healing.

Extension is also important to promote healing of elbow wounds. With wounds over the flexion surface of the elbow, splinting the joint in extension helps prevent contraction from ending in contracture, which is primarily a problem with open wound healing. With wounds over the extension surface of the elbow, splinting the joint in extension prevents the dog from being able to lie in sternal recumbency, which results in elbow flexion and pressure on the wound and subsequently impaired healing.

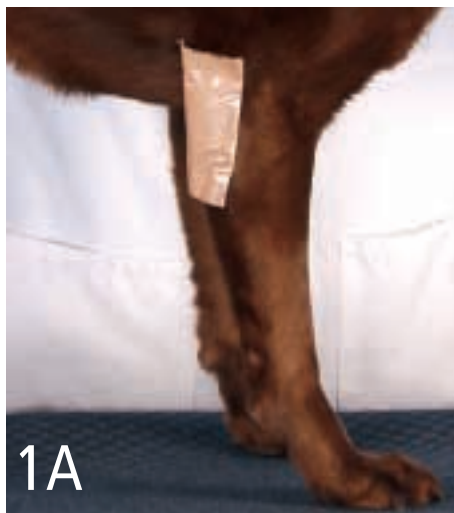Techniques have been described to immobilize the upper portion of the forelimb for both orthopedic and soft tissue injuries.¹⁻⁵ Spica bandages or splints, using an aluminum splint rod, thin plywood, or fiberglass casting tape for lateral support, can be used to immobilize the upper extremity.^{4,5} To immobilize and keep pressure off the elbow, a foam-rubber pipe insulation bandage with a hole cut in it to accommodate the olecranon area has been described.¹⁻³ An aluminum splint rod loop incorporated in the cranial aspect of an elbow bandage has been reported to immobilize an elbow in extension.^{2,3} This article describes the use of a "windowed" forelimb spica bandage/splint that immobilizes a forelimb in extension and allows access to an elbow wound for treatment.

continues

STEP BY STEP A WINDOWED FORELIMB SPICA BANDAGE / SPLINT

1 Apply the appropriate primary bandage material to the elbow wound (Table) (**Figure 1A**).

Wrap a soft, relatively bulky secondary bandage (Sof-Band bulky bandage—Johnson & Johnson, Arlington, TX, or Kerlix Roll—Tyco HealthCare/Kendall, Mansfield, MA) around the limb immediately above the paw, up the full length of the forelimb. Cover the primary bandage layer over the elbow wound; the wrap should be four to five layers thick (**Figure 1B**).



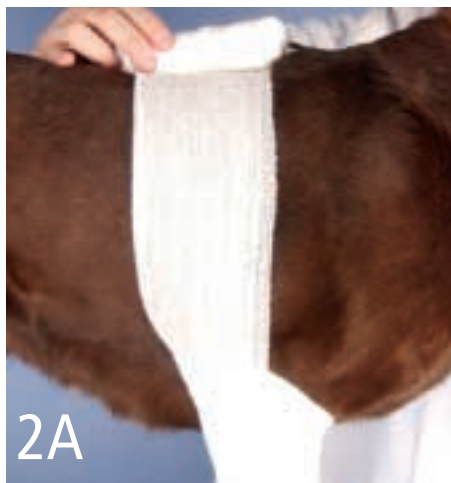1A



1B

2 After the limb is wrapped and the bandage roll is at the top of the limb on the lateral aspect, bring the roll over the top of the shoulder area (**Figure 2A**) and then down the patient's other side.

Wrap four to five layers around the thorax, alternating wraps in front and behind the forelimb. Wraps in front of the limb will cover the pectoral area. Continue to wrap as needed—especially in the elbow area—to produce a smooth transition/junction between the limb and body bandage (**Figure 2B**). Another bandage material option is to use cast padding (Specialist Cast Padding—Johnson & Johnson Professional Inc., Raynham, MA) followed by a layer of self-adherent gauze before applying the tertiary layer.



2A



2B

Primary Bandage Layer for Wounds of the Elbow Area*

Open wound (inflammatory/debridement stage)

- **Open-mesh gauze sponge** (for wet-to-dry or dry-to dry bandages)
- **Open-mesh gauze with antimicrobial** (for dry-to-dry bandages) (Kerlix AMD, Super Sponges—Tyco HealthCare/ Kendall, Mansfield, MA)
- **Polyurethane foam sponge** (Hydrasorb—KenVet Animal Care Group, Ashland, OH)
- **Acellular collagen matrix** (Vet BioSist—Cook Veterinary Products, Bloomington, IN; ACell Vet—ACell, Inc., Jessup, MD)
- **Calcium alginate dressing** (Curasorb—Tyco HealthCare/Kendall, Mansfield, MA)

Open wound (repair stage)

- **Nonadherent semiocclusive sponges** (Release—nonadhering dressing—Johnson & Johnson, Arlington, TX; Telfa "Ouchless" adhesive pads—Tyco HealthCare/Kendall, Mansfield, MA)
- **Hydrogel dressing** (BioDres—Dermatologics in Veterinary Medicine Pharmaceuticals, Miami, FL)

- **Polyurethane foam sponge** (Hydrasorb—KenVet Animal Care Group, Ashland, OH)

Sutured wound (with or without dependent drain)

- **Open-mesh gauze sponge**

Skin flap

(with or without dependent drain)

- **Open-mesh gauze sponge**

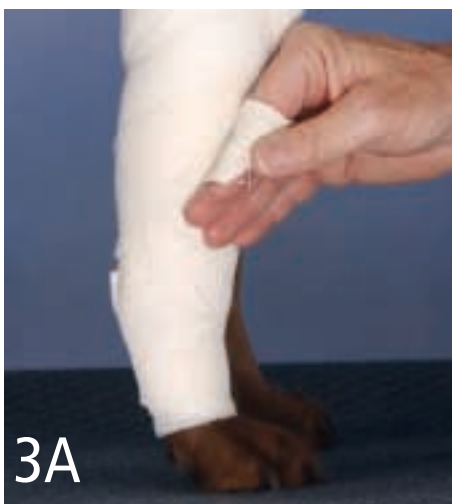* There are a variety of good bandaging products on the market. The products listed here are those commonly used by the authors. Other similar products can be substituted.

PROCEDURE PEARL

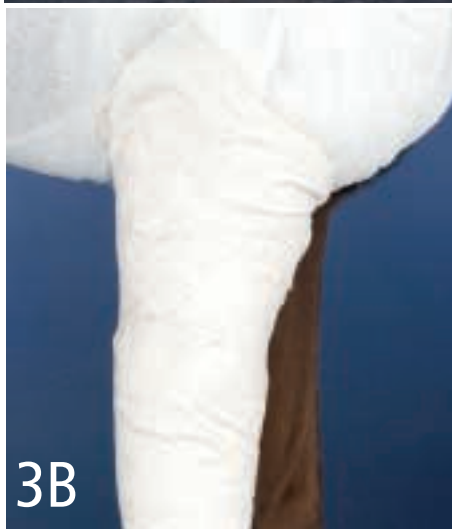Wrap as needed—especially in the elbow area—to produce a smooth transition/junction between the limb and body bandage.

3

The secondary bandage layer is covered with a tertiary layer of 2-inch-wide adhesive tape (Zonas Porous Tape—Johnson & Johnson, Arlington, TX, or Curity Standard Porous Tape—Tyco HealthCare/Kendall, Mansfield, MA). Begin tape placement at the distal end of the leg bandage, using circumferential wraps of pre-torn strips of tape. A dovetail pattern of application can be used (Figures 3A and 3B). Use long strips of tape to cover the thoracic portion of the bandage (Figure 3C) and intermediate-length strips over the juncture area between the limb and body bandage. The result is a spica-type bandage with a smooth



3A

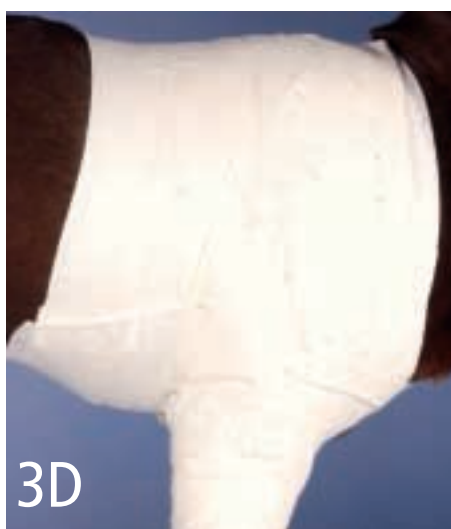

3B

transition/junction between the limb and body portions of the bandage (Figure 3D). Alternatively, elastic tapes (Elasticon—Johnson & Johnson, Arlington, TX, or Vetrap—3M Animal Care Products, St. Paul, MN) can be used to give a tight, smooth application. To help ensure application of elastic tape under proper tension, secure the tape near the bandage with one hand while removing a length of tape from the roll. Then apply the removed tape to the bandage.



3C



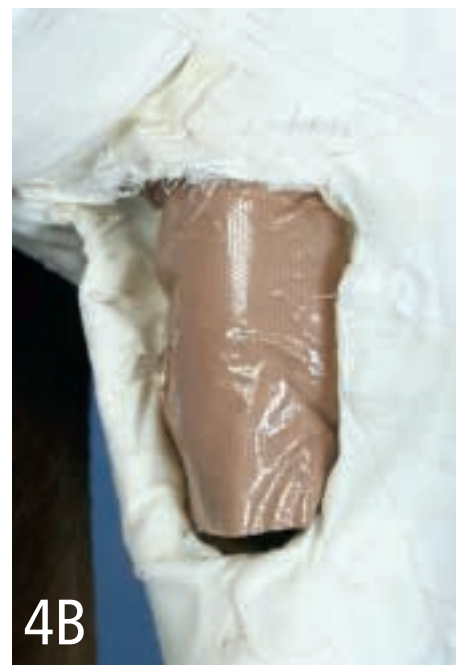3D

4

Using a razor blade or scalpel blade and scissors, carefully cut a hole in the bandage over the area of the elbow wound (Figure 4A). Smooth the edges of the hole by using short strips of adhesive tape to cover the cut edges of the secondary wrap (Figure 4B). The hole allows access to the wound for inspection and treatment.⁴



4A



4B

PROCEDURE PEARL

To help ensure application of elastic tape under proper tension, secure the tape near the bandage with one hand while removing a length of tape from the roll.

continues

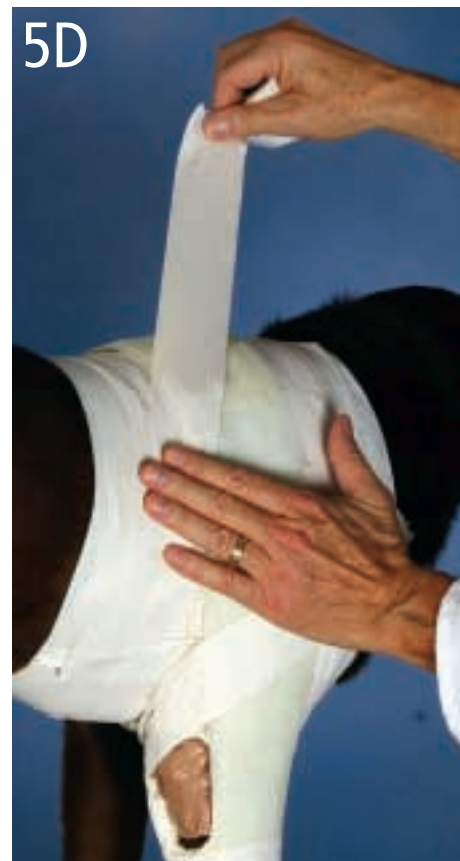
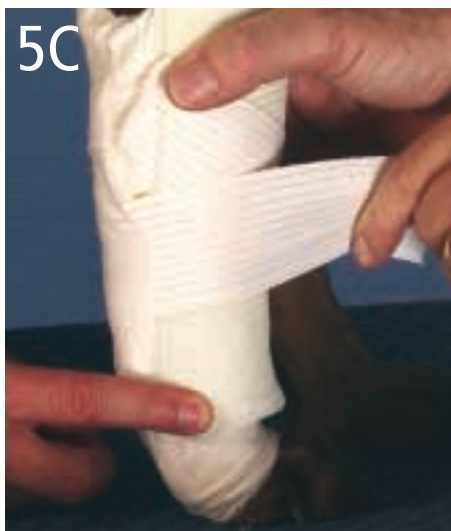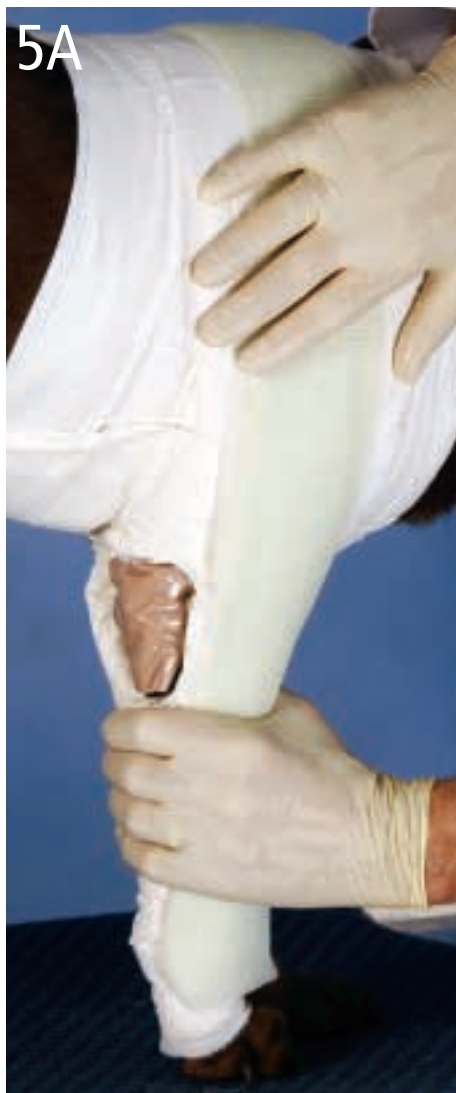5

Use fiberglass casting tape (Delta-Lite "S" fiberglass casting tape—Johnson & Johnson, Raynham, MA) to provide the extension and immobilization. Starting at the distal end of the leg bandage, unroll the tape up the lateral side of the bandage, over the dorsal scapular area. Fold it back on itself and bring it down the leg to its origin, where you again fold it back on itself and take it back up the leg; repeat this step several times to provide a multilayered fiberglass splint on the lateral aspect of the spica bandage. Use your hands to mold the tape to the lateral and dorsal aspects of the bandage until the tape hardens (**Figure 5A**). The splint should resemble a shepherd's crook or a ques-

tion mark (**Figure 5B**). Tape the splint to the lateral aspect of the leg portion of the bandage with a few circumferential strips of adhesive tape (**Figure 5C**). Affix the dorsal portion of the fiberglass splint over the dorsal scapular area of the bandage with a few strips of adhesive tape (**Figure 5D**). The entire splint does not have to be covered with tape. Splint-fixing tape strips can be placed above and below the hole in the bandage. Alternatively, an aluminum splint rod can be bent in the form of an

elongated loop. The dorsal portion of the loop is bent to curve over the dorsal scapular area of the dog. This then serves as the splint portion of the covering. ■

See Aids & Resources, back page, for references, contacts, and appendices.



Aftercare

At each treatment, the wound can be medicated as needed. A piece of primary bandage material and a thick pad of secondary bandage material can be placed over the wound. Use a few overlying strips of adhesive tape to hold these in place until the next treatment. Frequency of treatment depends on the nature of the wound.

Leave the spica bandage/splint in place during wound treatment to provide the necessary extension and immobilization to promote healing. Occasional tape additions and adjustments may be needed, depending on the activity level of the dog since the cotton materials of the bandage may stretch and shift over time.

After the wound has healed, gradual return to elbow function is in order as the wound healing process matures. Removing the splint from the bandage can be done in conjunction with placing some additional padding in the flexion surface of the bandage to limit flexion, and the padding can gradually be decreased to allow a slow return of flexion. Because scar tissue is always weaker than normal skin, take measures to prevent recurrence of wounds over the olecranon, such as bedding the dog on soft surfaces and/or applying a commercial elbow padding product (DogLeggs, Reston, VA).