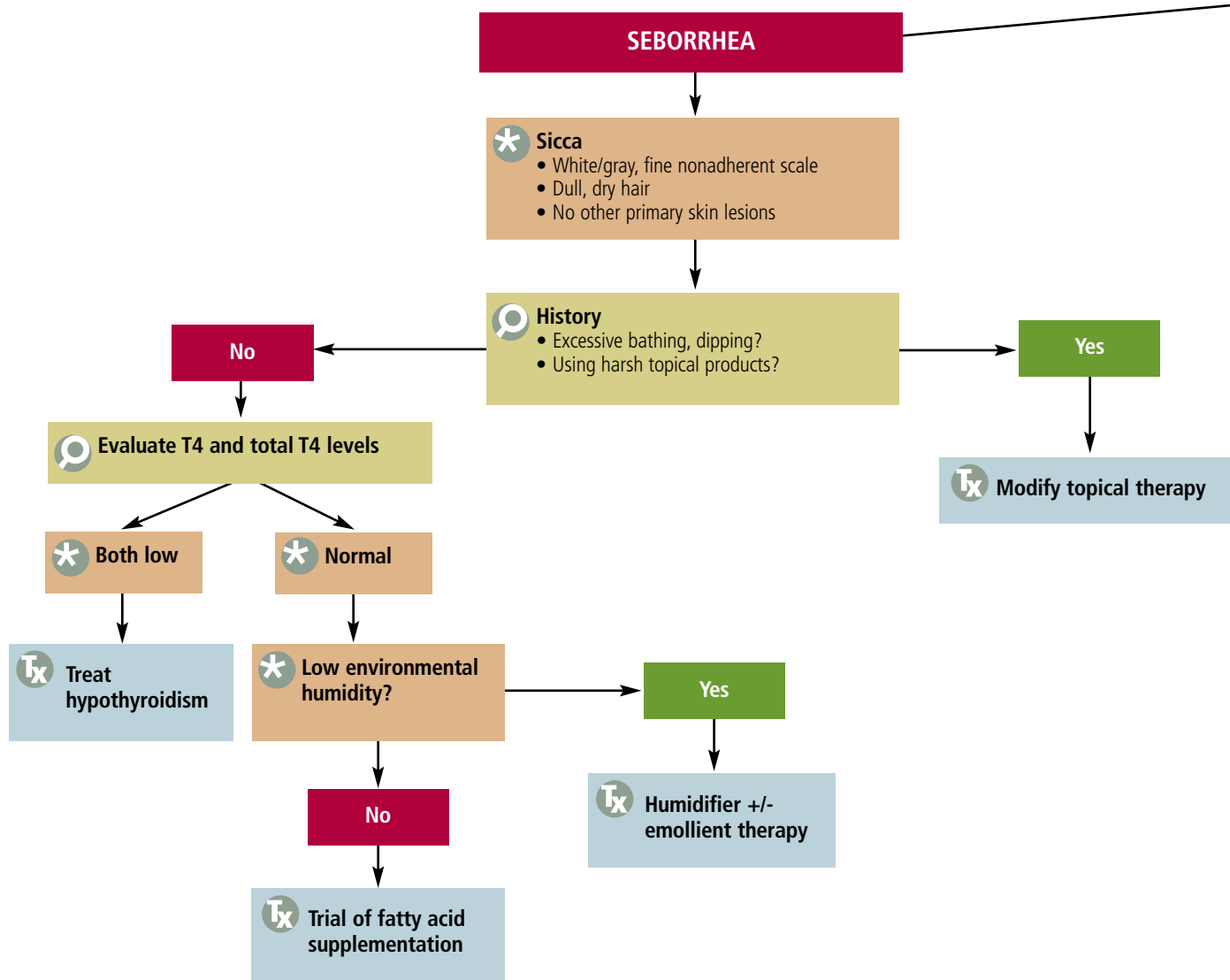


# Seborrhea

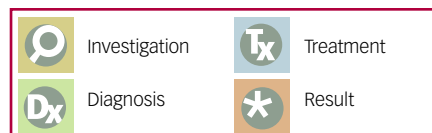
Alison Flynn-Lurie, DVM, Diplomate ACVD, Miami Veterinary Specialists, Florida

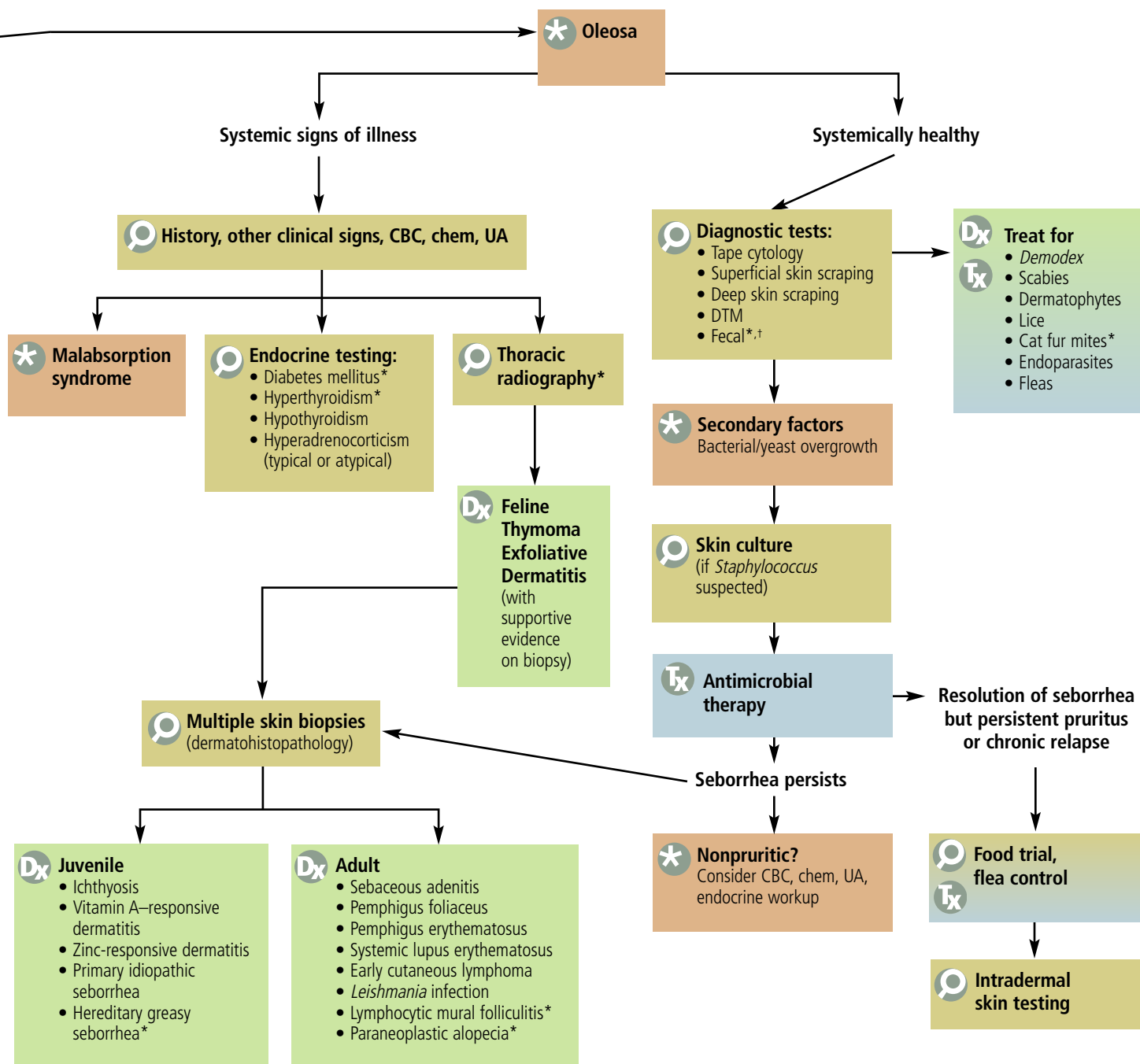


SEBORRHEA can be defined based on clinical signs as *seborrhea oleosa* or *seborrhea sicca*.

*Seborrhea oleosa* is characterized by greasy, malodorous, adherent scale; when erythema and folliculitis are present, many call it "seborrheic dermatitis." There may be concurrent ceruminous otitis and, with chronicity, there is hyperpigmentation.

*Seborrhea sicca* involves white/gray, fine scale; a dull, dry hair coat; and no other primary skin lesions.





\* = feline specific, † = empirical therapy indicated if diagnostic test is negative, CBC = complete blood count, chem = serum biochemical profile, DTM = dermatophyte test medium, T4 = thyroxine, UA = urinalysis

This algorithm can be downloaded and printed for use in your clinic at [cliniciansbrief.com](http://cliniciansbrief.com).