

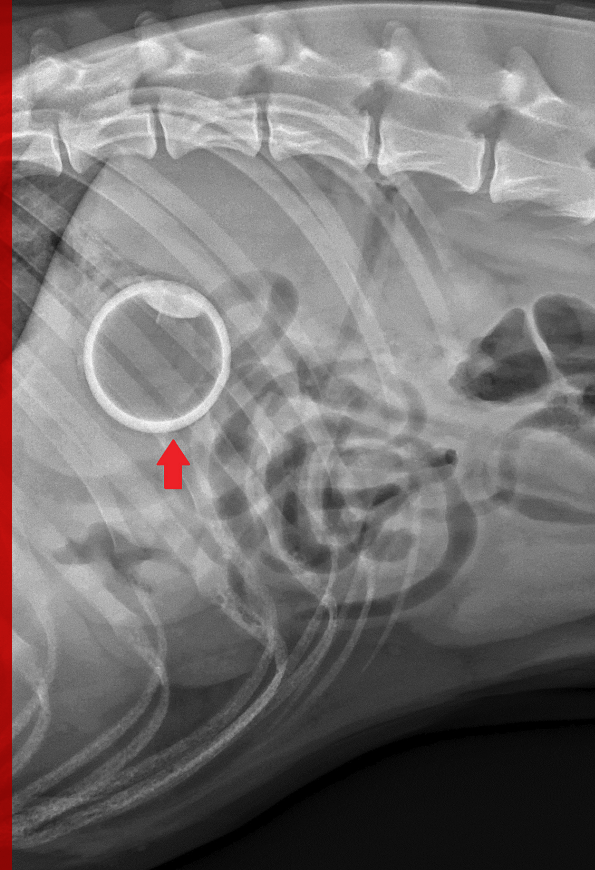Foreign Body Ingestion

Mary Dell Deweese, DVM

*The Animal Medical Center
New York City, New York*

Karen M. Tobias, DVM, MS, DACVS

University of Tennessee

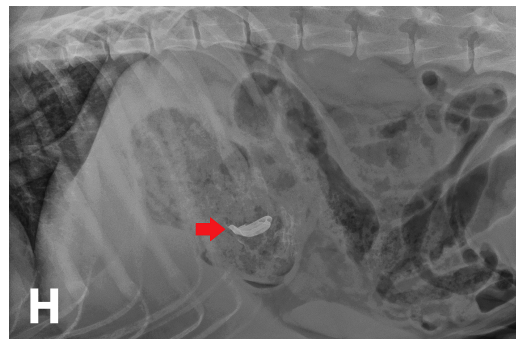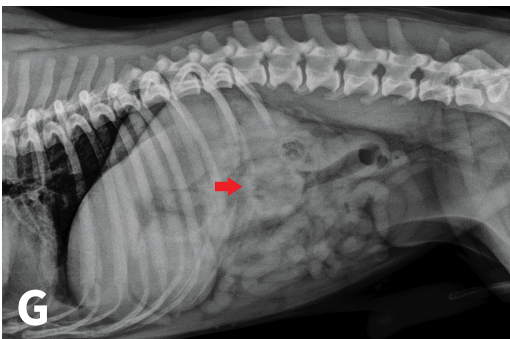
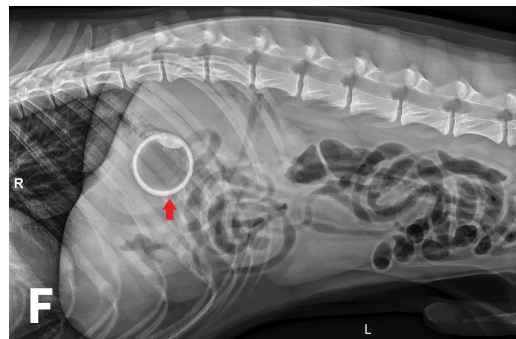
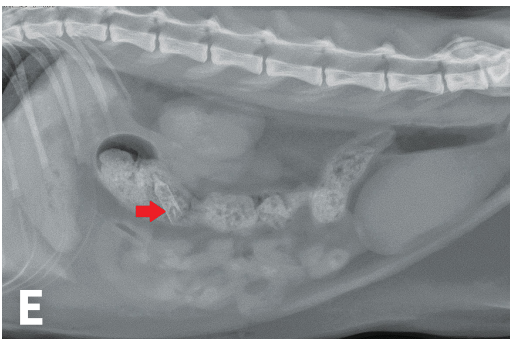
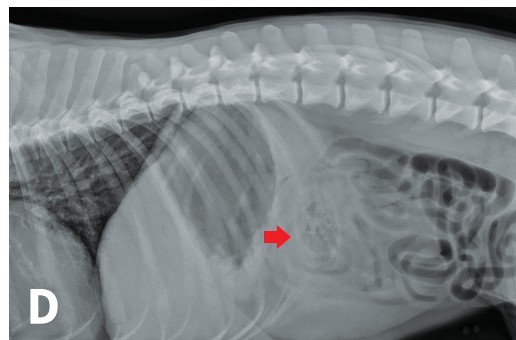
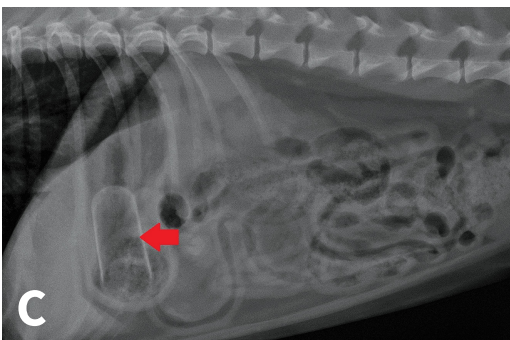
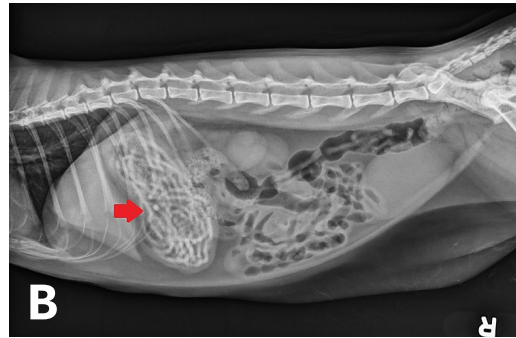
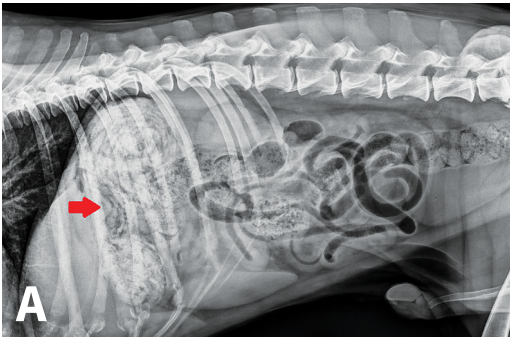


Foreign body ingestion with subsequent GI mechanical obstruction is among the most common indications for emergency surgery in veterinary medicine. The need for surgical intervention is determined by a combination of clinical signs, blood work, and diagnostic imaging. Despite its frequency, diagnosis and treatment of GI foreign body ingestion can be a challenge.

MATCH THE IMAGES

The following radiographs exhibit various foreign bodies ingested by dogs. Match each radiograph with the correct item.

Despite its frequency, diagnosis and treatment of GI foreign body ingestion can be a challenge.

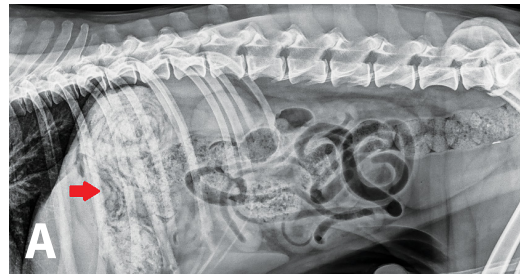


FOREIGN BODY

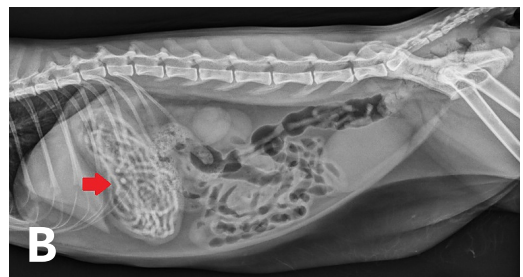
- Aerosol can top
- Finger toothbrush
- Glass bulb
- Gloves
- Pacifier
- Rubber bands
- Tennis ball
- Walnut

ANSWER KEY

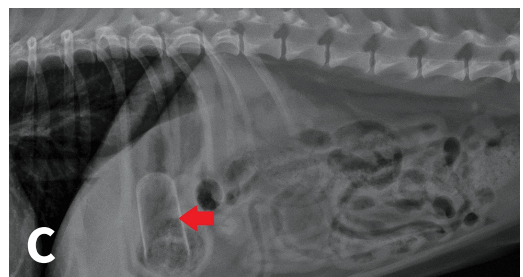
A **Gloves**
 A soft tissue to mineral opacity fills the stomach on the lateral view, with a striated pattern (**arrow**). The duodenum contains a small amount of gas. The remainder of the small intestine is normal in diameter and contains a normal amount of fluid and gas. The colon contains formed fecal material. *Photo courtesy of University of Tennessee College of Veterinary Medicine*



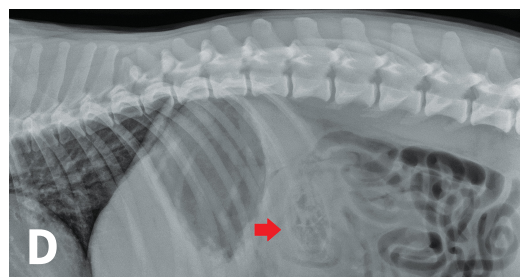
B **Rubber bands**
 Multiple mineral opaque tubular structures (**arrow**) are in the stomach. The kidneys are bilaterally small, and the margin of the left kidney is mildly irregular. *Photo courtesy of University of Tennessee College of Veterinary Medicine*



C **Finger toothbrush**
 The stomach is small but contains a structured, thin-walled, mineral opaque cylindrical foreign body (**arrow**) outlined by a small amount of gas. The small intestines are normal in size and uniform in diameter. A small volume of fluid is shown in the caudal thoracic esophagus. *Photo courtesy of The Animal Medical Center in New York City*



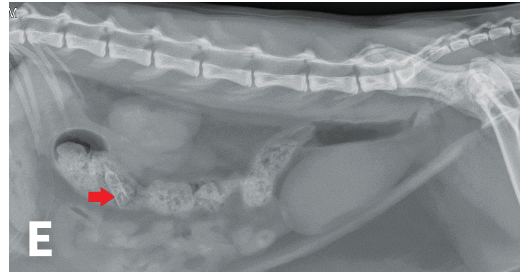
D **Pacifier**
 There is an $\approx 3 \times 5$ cm partially radiopaque foreign body (**arrow**) within the proximal duodenum. The duodenum is mildly dilated, and the stomach is mildly gas-filled. The remainder of the small intestine is normal, and the abdomen is otherwise unremarkable. *Photo courtesy of The Animal Medical Center in New York City*



E Glass bulb

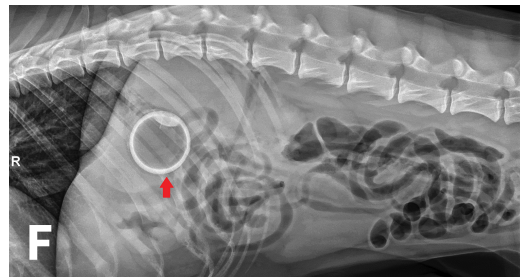
There is an $\approx 2.0 \times 0.5$ cm opacity (**arrow**) within the colon present on the lateral view. The remainder of the small intestinal tract is empty and the abdomen is otherwise unremarkable. *Photo courtesy of The Animal Medical Center in New York City*

For more on glass ingestion, read **Glass Ingestion in a Boxer: 1 Case, 2 Options** on page 70 of this issue.



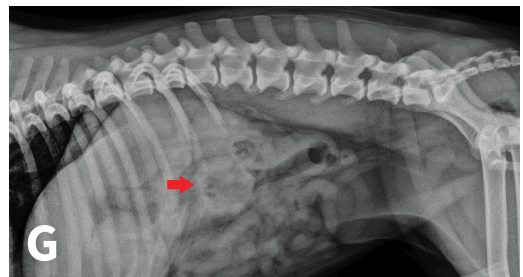
F Tennis ball

There is an ≈ 6 -cm radiopaque, well-defined, centrally gas-filled foreign body (**arrow**) observed within the stomach. The stomach is otherwise empty, and the intestines are gas-filled without dilation or plication. The abdomen is otherwise normal. *Photo courtesy of The Animal Medical Center in New York City*



G Walnut

The stomach is moderately distended with fluid and a small amount of gas. The duodenum is distended with fluid and gas. There is an ≈ 4 -cm soft tissue to mineral opaque rimmed foreign body (**arrow**) that is ovoid with a gas-filled center. The remainder of the intestinal tract is empty, and the abdomen is otherwise unremarkable. *Photo courtesy of The Animal Medical Center in New York City*



H Aerosol can top

The stomach is moderately distended with soft-tissue opacity ingesta. There is an $\approx 3 \times 1$ cm metallic opaque foreign object (**arrow**) within the body of the stomach. The remainder of the small intestine is filled with fluid and gas and has a uniform diameter. The remainder of the abdomen is unremarkable. *Photo courtesy of The Animal Medical Center in New York City*

