

Acute Respiratory Distress: The Blue Patient

PROFILE

Acute respiratory distress is a serious and common emergency presentation. Respiratory distress occurs for various reasons, and prompt recognition of the underlying source is essential to providing appropriate therapy.

Acute respiratory distress can be broadly divided into 8 categories based on anatomic localization. Several of these can be distinguished by simple observation and physical examination, whereas others require additional diagnostics.

- Upper airway obstruction
- Lower airway obstruction
- Thoracic wall disorders
- Pleural space disorders
- Pulmonary parenchymal disease
- Pulmonary vascular disorders
- Abdominal distension
- Nonrespiratory disorders (mimics)

INITIAL ASSESSMENT & DIAGNOSIS

Initial assessment of these patients involves observation of the patient's mentation, posture,

and respiratory rate and effort, as well as auscultation of the thorax. Evaluation of the mucous membranes may reveal cyanosis, suggestive of hypoxemia.

Anemic animals may have pale mucous membranes, and cyanosis may not be apparent, even with severe hypoxemia. The pattern of respiration can help localize the problem and guide further diagnostics and treatments.

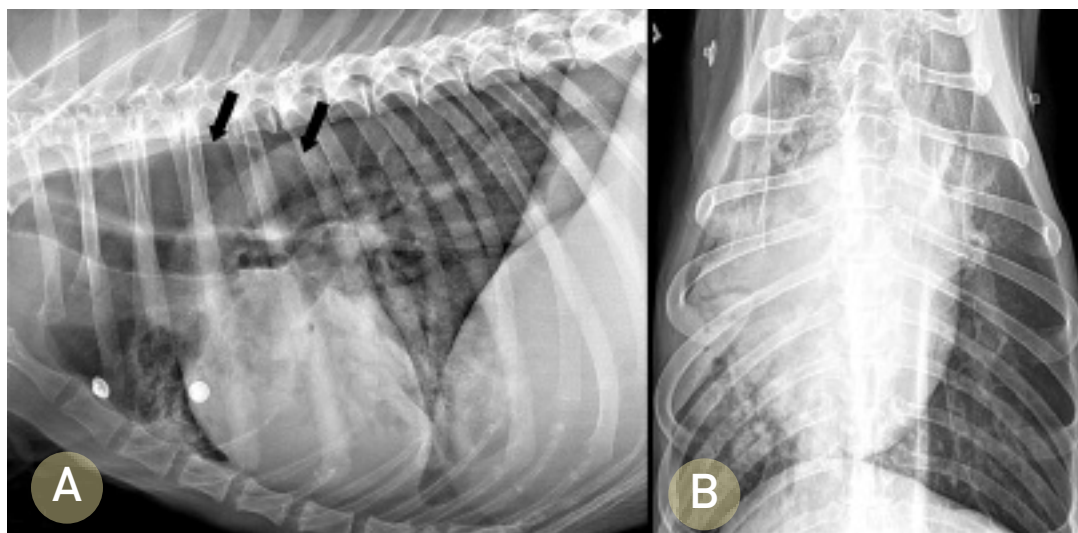
Categorical causes of hypoxemia include:

- Ventilation-perfusion mismatch (pulmonary parenchymal disease)
- Diffusion impairment (edema, fibrosis, neoplasia)
- Alveolar hypoventilation (airway obstruction, pleural space disorders)
- Vascular shunts (right-to-left shunts)
- Decreased fraction of inspired oxygen or oxygen concentration (high altitudes).

Upper airway obstructions can lead to inspiratory dyspnea and stridor. Examples of such obstructions include laryngeal paralysis, extrathoracic

Prompt recognition of the underlying reason for respiratory distress is essential to providing appropriate therapy.

CONTINUES



1 Right lateral (A) and ventrodorsal (B) radiographic projections of the thorax of a dog presenting with acute respiratory distress. An alveolar lung pattern is present in the right cranial, middle, and caudal lung lobes, a pattern consistent with aspiration pneumonia. Megaesophagus is present (black arrows), likely leading to chronic regurgitation and secondary aspiration.

tracheal collapse, compressive masses, foreign bodies, and brachycephalic syndrome.

Lower airway obstructions result in expiratory dyspnea with auscultable expiratory wheezes. Causes of such obstructions include bronchoconstriction/spasms, inflammation of the bronchial walls (feline asthma, chronic bronchitis), intraluminal exudative/mucoid debris, intrathoracic tracheal collapse and bronchomalacia, or bronchial compression secondary to left atrial enlargement.

Thoracic wall disorders (eg, flail chest, “sucking” chest wounds) can lead to paradoxical respiration with the affected area of the thorax collapsing inward on inspiration and forced outward on expiration.

Pleural space disorders, such as pleural effusion or pneumothorax, can lead to rapid, shallow breathing patterns with inspiratory distress.

Pulmonary parenchymal disorders, such as pneumonia (Figure 1), edema (cardiogenic or noncardiogenic), pulmonary contusions, interstitial lung disease, and neoplastic or fungal infiltration (Figure 2), can lead to both inspiratory and expiratory

difficulty. The presence of heart murmurs, gallops, or arrhythmias may suggest underlying heart disease but not necessarily congestive heart failure.

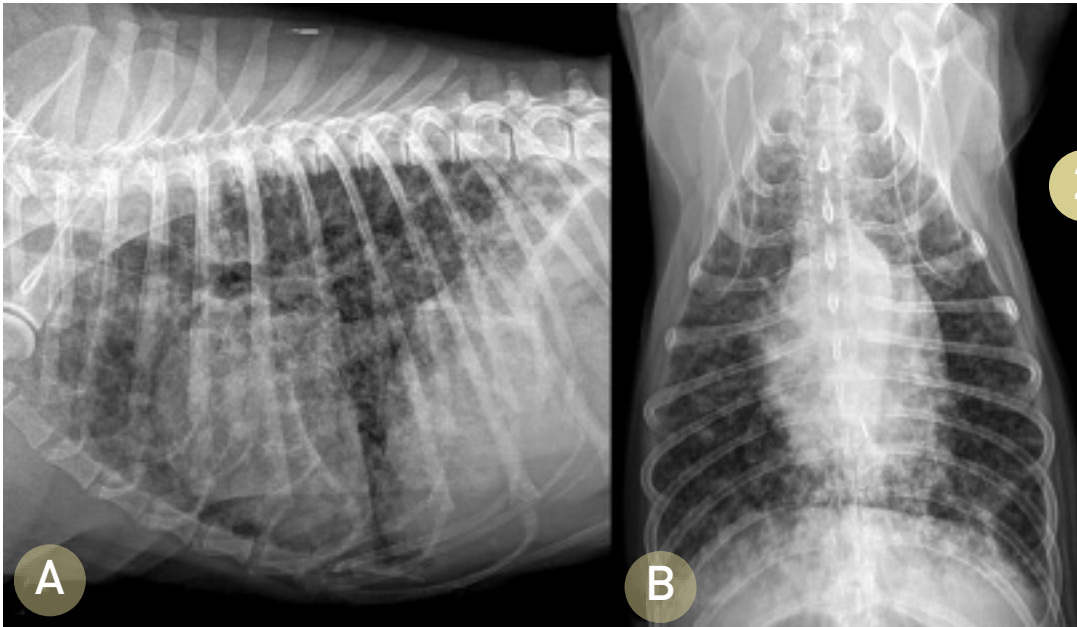
Congestive heart failure can lead to activation of the sympathetic nervous system, which almost invariably results in tachycardia. Primary respiratory disease often induces a vagal response leading to normal sinus rhythms, sinus arrhythmias, or sinus bradycardias.

Pulmonary vascular disorders are most commonly pulmonary thromboembolism and heartworm disease. Clinical signs of pulmonary vascular diseases are variable and include hemoptysis, coughing, dyspnea, and syncope. Other clinical signs may be noted and attributed to the predisposing disease process.¹ Split heart sounds may be heard due to concurrent pulmonary hypertension.

Severe abdominal distension can impair diaphragmatic contraction, leading to inspiratory distress that is typically characterized by a slow

MORE

Go to cliniciansbrief.com/journal to view and download the algorithm **Acute Breathing Difficulty: Initial Management** (in the January 2005 issue of *Clinician's Brief*).



Right lateral (A) and ventrodorsal (B) radiographic projections of the thorax of a dog presenting for progressive coughing and acute dyspnea. A diffuse structured interstitial lung pattern is present. Primary differentials would include metastatic neoplasia and fungal disease.

and exaggerated pattern. Differentials include ascites, gastric dilatation-volvulus, organomegaly, and pregnancy.

Nonrespiratory diseases that may mimic respiratory distress include acidosis, anemia, pain, and hypotension.

STABILIZATION

Oxygen supplementation is the cornerstone therapy for the dyspneic patient and is often needed

prior to performing a physical examination or diagnostic procedures (Figure 3, page 72). Several strategies may be used for providing oxygen, with the patient's temperament dictating the most appropriate method.

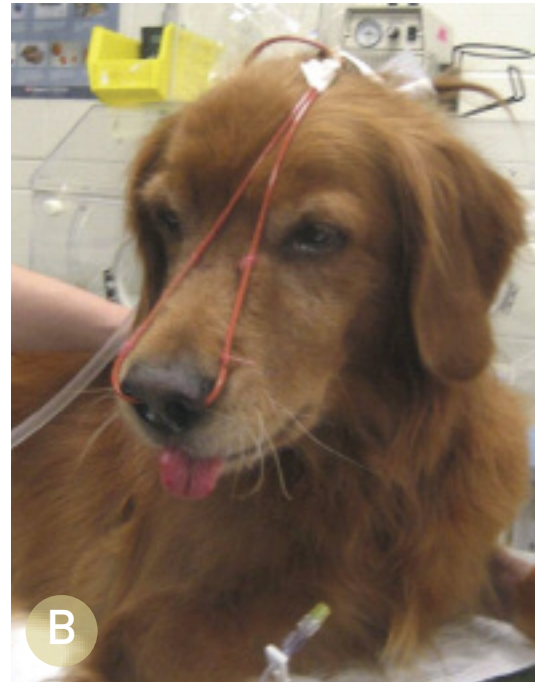
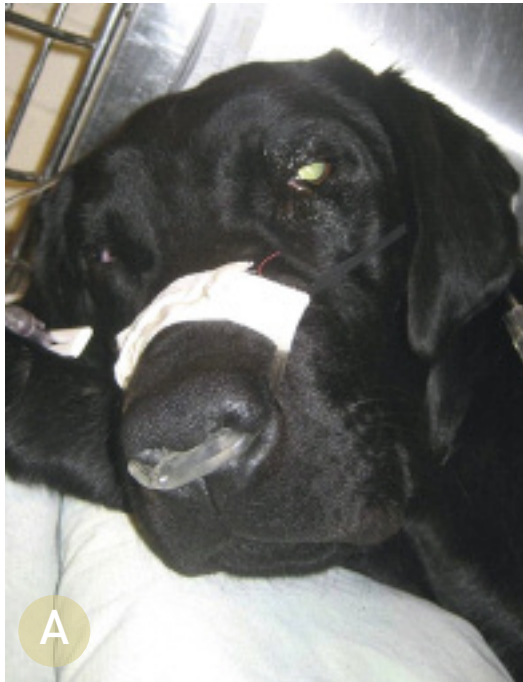The clinician should ensure the airways are patent; otherwise more invasive measures may be indicated (eg, intubation, tracheostomy, mechanical ventilation). In some cases, sedation may be

CONTINUES

Prioritizing Patient Care

- Ensure patent airway
- Begin oxygen supplementation (oxygen cage, face mask, intranasal, flow-by)
- Obtain vascular access
- Perform brief physical examination to identify
 - Mentation changes
 - Abnormal mucous membrane color (cyanotic, pale, hyperemic)
- Abnormal respiratory patterns
 - Inspiratory distress: Upper airway obstruction, pleural space disorder, abdominal distension, thoracic wall disorders
 - Expiratory distress: Lower airway obstruction
 - Mixed: Pulmonary parenchymal or pulmonary vasculature disorder
- Abdominal distension
- Thoracic wall disorder
- Thoracic findings on auscultation
 - Heart rate and rhythm
 - Abnormal heart sounds
 - Muffled or adventitious lung sounds

Oxygen supplementation is the cornerstone therapy for the dyspneic patient.



3

Oxygen therapy is the mainstay of treatment for acute respiratory distress and can be provided using a variety of methods. Oxygen cages are the least stressful for the patient but can limit access for further treatments and diagnostic procedures. Intranasal administration of oxygen can be supplied using a nasal prong (A) or red rubber catheters (B) and can provide a FiO_2 of 40% to 50% when using 50 to 100 mL/kg per minute of oxygen flow. Face mask and flow-by oxygen can also be used if the patient will tolerate it.

warranted to reduce anxiety associated with respiratory distress. Vascular access should be obtained, if possible, without disrupting oxygen supplementation to allow intravenous administration of medications or fluids if indicated.

DIAGNOSTICS

Initial diagnostics may include:

- Blood pressure measurement
- Pulse oximetry
- Blood sampling to determine packed cell volume, total protein, blood urea nitrogen, creatinine, glucose, and electrolytes
- Thoracocentesis if pleural disease is suspected
- Fluid analysis of pleural effusion (cytology, cell counts, total protein, and triglyceride/cholesterol concentrations if chylous appearing)
- Bacterial cultures of pleural fluid.

Once the patient has been stabilized, additional diagnostics dependent on the clinical situation may include:

- Complete blood count, serum biochemical profile, urinalysis

- Thoracic or cervical radiography
- Echocardiography
- Coagulation profile, D-dimer assay
- Bronchoscopy and bronchoalveolar lavage
- Fine-needle aspiration of the lung
- Laryngoscopy
- Serial pulse oximetry, arterial blood gas analysis.

TREATMENT

Specific treatment is targeted to the underlying cause of respiratory distress. Continued oxygen supplementation and preventing stress is vital to avoid further decompensation.

Upper Airway Obstruction

- Sedation with acepromazine (eg, 0.025–0.2 mg/kg IV or IM) or butorphanol (eg, 0.1–0.4 mg/kg IV or IM) may be needed to relieve anxiety and facilitate further evaluation.
- If a patent airway cannot be maintained, intubation, tracheostomy, or other invasive measures may be required.

FiO_2 = fraction of inspired oxygen

- Glucocorticoids (eg, dexamethasone, 0.1–0.25 mg/kg IV) may be needed to reduce laryngeal and pharyngeal inflammation and edema.
- Often these patients are hyperthermic and may benefit from active cooling (eg, applying icepacks, cooling fans, cooled IV fluids).
- Noncardiogenic pulmonary edema may develop in patients with upper airway obstructions and will require further supportive care.

Lower Airway Obstruction

- Bronchodilators (eg, terbutaline, 0.01 mg/kg IM) may be attempted to quickly relieve bronchospasm.
- Glucocorticoids (eg, dexamethasone, 0.1–0.25 mg/kg IV or IM) can also be used with acute asthmatic episodes in cats.

Thoracic Wall Disorders

- Pain and concurrent pulmonary contusions from the initiating traumatic event are the likely main contributory factors in respiratory distress.²
- Administration of parenteral opioids in combination with local anesthetics (intercostal nerve blocks) may provide more complete analgesia than either alone. Nonsteroidal anti-inflammatories may also be used if no contraindications are observed.
- Stabilization of a flail segment (splinting or restraining in lateral recumbency) may lead to improvement in ventilation and facilitate further evaluation and treatment; however, it can also impede the patient's inspiratory effort.
- Intermittent thoracocentesis may be needed initially to relieve a concurrent pneumo/hemothorax until the patient has stabilized or the placement of a chest tube is required.

Pulmonary Parenchymal Disorders

- Thoracic radiographs are required for definitive diagnosis and treatment. However, empirical therapy may be necessary initially in extremely unstable patients.
- If pneumonia is suspected, therapy includes broad-spectrum antibiotics, such as ampicillin (22 mg/kg IV Q 8 H) and enrofloxacin (10–20 mg/kg IV Q 24 H for dogs and 5 mg/kg IV Q 24 H for cats), pending results of bacterial cultures and nebulization and coupage.
- Therapy for cardiogenic pulmonary edema primarily includes a loop diuretic (furosemide, initially 2–6 mg/kg IV or IM) at repeated dosing intervals dependent on the patient's clinical response. Nitroglycerin ointment (0.25–2 inches transdermally Q 6–8 H) can be attempted to reduce preload in congestive heart failure but absorption is variable.
- No specific therapy exists for noncardiogenic pulmonary edema and pulmonary contusions other than supportive care, oxygen supplementation, and mechanical ventilation, if needed. Diuretics are generally contraindicated in this context.³

Pulmonary Vascular Disorders

Therapy for pulmonary thromboembolism remains largely supportive but may include a combination of anticoagulants, antiplatelet medications, thrombolytics, bronchodilators, and selective pulmonary arterial vasodilators (eg, sildenafil, 1 mg/kg PO Q 8–12 H; pimobendan, 0.25 mg/kg PO Q 8–12 H) for concurrent pulmonary hypertension.¹

Specific treatment is targeted to the underlying cause of respiratory distress.

See Aids & Resources, back page, for references & suggested reading.

CONTINUES

DX AT A GLANCE

Upper Airway Obstruction

- **Clinical Signs:** Inspiratory dyspnea, stridor
- **Differentials:** Laryngeal paralysis, extrathoracic tracheal collapse, compressive masses, foreign bodies, brachycephalic syndrome

Lower Airway Obstruction

- **Clinical Signs:** Expiratory dyspnea with auscultable expiratory wheezes
- **Differentials:** Bronchoconstriction/spasms, bronchial wall inflammation (feline asthma, chronic bronchitis), intraluminal exudative/mucoid debris, intrathoracic tracheal collapse & bronchomalacia, bronchial compression secondary to left atrial enlargement

Thoracic Wall Disorders

- **Clinical Signs:** Paradoxical respiration with the affected area of the thorax collapsing inward on inspiration & forced outward on expiration
- **Differentials:** Flail chest, “sucking” chest wounds

Pleural Space Disorders

- **Clinical Signs:** Rapid, shallow breathing patterns with inspiratory distress
- **Differentials:** Pleural effusion, pneumothorax

Pulmonary Parenchymal Disorders

- **Clinical Signs:** Inspiratory & expiratory difficulty; presence of heart murmurs, gallops, or arrhythmias may suggest underlying heart disease

- **Differentials:** Pneumonia, edema (cardiogenic or noncardiogenic), pulmonary contusions, interstitial lung disease, neoplastic or fungal infiltration

Pulmonary Vascular Disorders

- **Clinical Signs:** Hemoptysis, coughing, dyspnea, syncope; split heart sounds possible if concurrent pulmonary hypertension
- **Differentials:** Pulmonary thromboembolism, heartworm disease

Severe Abdominal Distension

- **Clinical Signs:** Inspiratory distress typically characterized by slow, exaggerated pattern
- **Differentials:** Ascites, gastric dilatation-volvulus, organomegaly, pregnancy

TX AT A GLANCE

Upper Airway Obstruction

- **Sedation** with acepromazine (eg, 0.025–0.2 mg/kg IV or IM) or butorphanol (eg, 0.1–0.4 mg/kg IV or IM)
- **Intubation, tracheostomy, etc** if patent airway cannot be maintained
- **Glucocorticoids** (eg, dexamethasone, 0.1–0.25 mg/kg IV) to reduce laryngeal & pharyngeal inflammation & edema
- **Active cooling** for hyperthermic patients

Lower Airway Obstruction

- **Bronchodilators** (eg, terbutaline, 0.01 mg/kg IM) to relieve bronchospasm
- **Glucocorticoids** (eg, dexamethasone, 0.1–0.25 mg/kg IV or IM) for acute asthma in cats

Thoracic Wall Disorders

- **Parenteral opioids** in combination with local anesthetics; NSAIDs may be used if no contraindications
- **Stabilization** of flail segment to improve ventilation & facilitate evaluation & treatment; can impede inspiratory effort
- **Intermittent thoracocentesis** to relieve concurrent pneumo/hemothorax

Pulmonary Parenchymal Disorders

- **Empirical therapy** in extremely unstable patients
- **Thoracic radiographs** for definitive diagnosis and treatment
- **Broad-spectrum antibiotics** (eg, ampicillin, 22 mg/kg IV Q 8 H; enrofloxacin, 10–20 mg/kg IV Q 24 H for dogs & 5 mg/kg IV Q 24 H for cats), if pneumonia suspected
- **Loop diuretic** (furosemide, initially 2–6 mg/kg IV or IM) at repeated dosing intervals for cardiogenic pulmonary edema
- **Supportive care**, oxygen supplementation, and mechanical ventilation for noncardiogenic pulmonary edema

Pulmonary Vascular Disorders

- **Anticoagulants, antiplatelet medications, thrombolytics**
- **Bronchodilators** (eg, theophylline, 10 mg/kg PO Q 12 H)
- **Pulmonary arterial vasodilators** (eg, sildenafil, 1 mg/kg PO Q 8–12 H; pimobendan, 0.25 mg/kg PO Q 8–12 H) for concurrent pulmonary hypertension