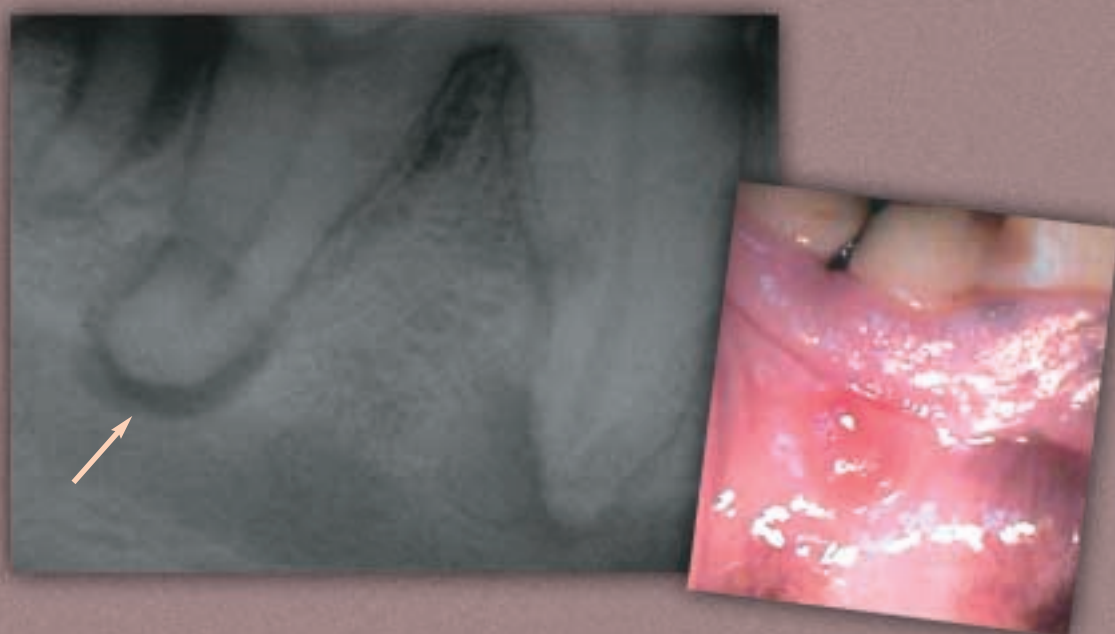


# Parulis or Gumboil

Linda J. DeBowes, DVM, MS, Diplomate ACVIM (Small Animal Internal Medicine) & AVDC, Shoreline Veterinary Dental Practice, Seattle, Washington;  
Series Editor, Michael Schaer, DVM, Diplomate ACVIM and ACVECC



**A PARULIS (GUMBOIL)** below the mucogingival line of the lower right first molar indicates where a fistula from a periapical abscess is draining into the oral cavity. Such fistulas take the path of least resistance; therefore, the parulis generally forms through the alveolar mucosa or at the level of the mucogingival line where the attached gingiva begins. A dental radiograph should be made to identify the source of the draining fistula. This radiograph shows the periapical lucency typical of a chronic periapical abscess.

THIS COLUMN features clinical images of diagnostic importance that say far more than words can convey. If you have an image—whether a photomicrograph, radiograph/diagnostic image, or a photograph—that you would like to share, please submit it for consideration along with a brief statement (maximum 150 words) of what is shown and why it is so important to: [toni@cliniciansbrief.com](mailto:toni@cliniciansbrief.com).