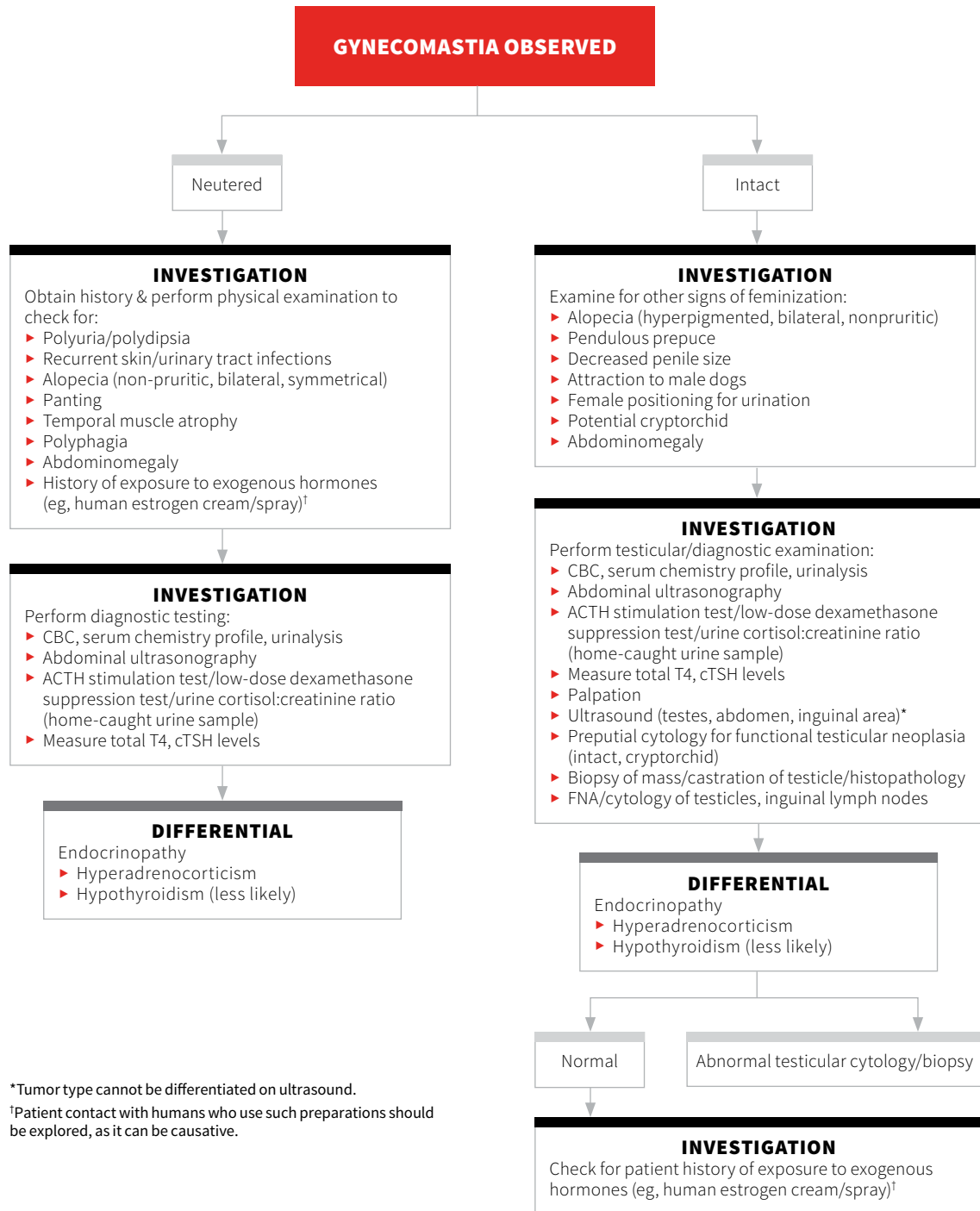


# Mammary Gland Enlargement in Male Dogs

Valeria M. Tanco, DVM, MSc, PhD, DACT  
 Charleston Veterinary Referral Center  
 Charleston, South Carolina



\*Tumor type cannot be differentiated on ultrasound.

<sup>†</sup>Patient contact with humans who use such preparations should be explored, as it can be causative.

