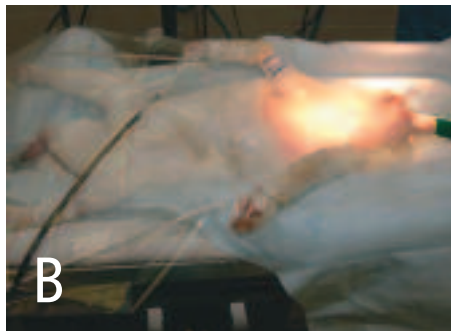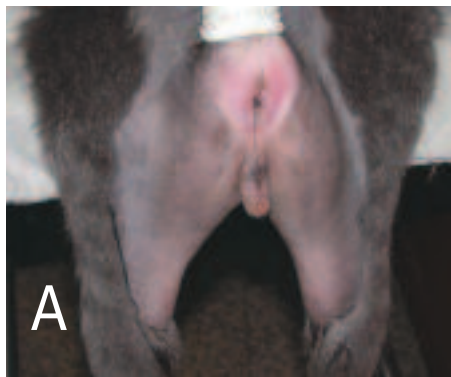


Karen M. Tobias, DVM, MS, Diplomate ACVS, University of Tennessee

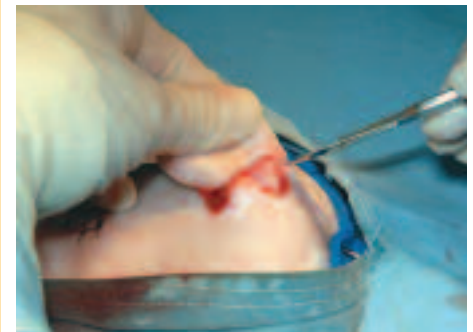
Perineal Urethrostomy in the Cat

Feline lower urinary tract disease is estimated to occur in 0.5% to 1% of cats in the United States and the United Kingdom. The most common causes include bacterial cystitis and urolithiasis. Other causes include fungal or parasitic urinary tract infection, crystalluria, anatomic abnormalities, trauma, neoplasia, and idiopathic disease. Medical management is recommended in most cats; however, occasionally the obstruction cannot be relieved or the distal urethra becomes stenosed, causing recurrent obstructions. Surgical correction is recommended in cats with irresolvable or recurrent obstructions or permanent urethral narrowing. The most common surgical procedure is perineal urethrostomy, where the wider postprostatic portion of the urethra is anastomosed to the skin to make a new urinary stoma.

STEP BY STEP PERINEAL URETHROSTOMY



cat is head down (A). Perineal urethrostomy can also be performed with the cat in dorsal recumbency and its rear legs pulled cranially so that the pelvis is tilted upward and the anus is facing the surgeon (B). This position provides excellent exposure to the pelvic attachments of the penile body and is useful for cats that also require cystotomies.



What You Will Need

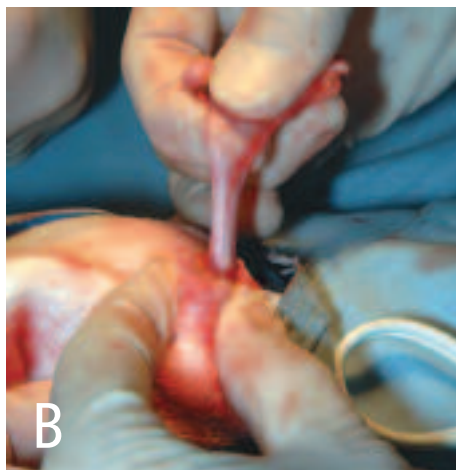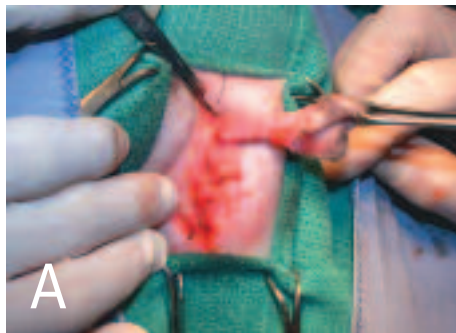
- Iris or tenotomy scissors
- Small needle holders (eg, Derf or Castroviejo)
- Fine thumb forceps
- 8-French red rubber catheter or straight Kelly hemostatic forceps
- 4-0 or 5-0 rapidly absorbable monofilament sutures

Helpful items: Sterile cotton swabs, magnification

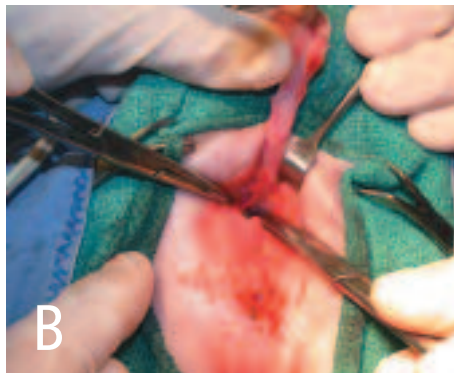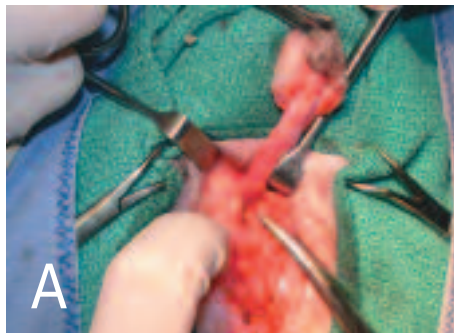1 After clipping the perineal region, including the prepuce and scrotum, place a pursestring suture in the anocutaneous junction. Complete the sterile prep once the cat is positioned on the surgery table. Most veterinarians perform perineal urethrostomies with the cat in sternal recumbency in the “perineal” position, with its hind legs hanging over the padded back edge of a surgery table and the table tilted so that the

2 If the cat is intact, it can be castrated routinely through scrotal incisions before perineal urethrostomy is performed, or the spermatic cords can be ligated during subcutaneous dissection after the periscrotal skin is incised. Make an elliptical incision around the scrotum and prepuce near the crease where this tissue joins the perineum. The scrotum and prepuce can be pulled laterally so the incision occurs at the base of these tissues.

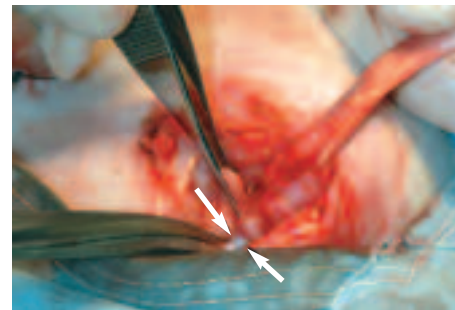
continues



3 Bluntly dissect along the penile body to its base, where it firmly attaches to the pelvis (ventral recumbency in **A**). Dissection can be performed with Metzenbaum scissors close to the penile body. Alternatively, subcutaneous tissues around the penile body can be stripped toward the pelvis with a gauze sponge (dorsal recumbency in **B**), which quickly and cleanly removes the adipose tissues.



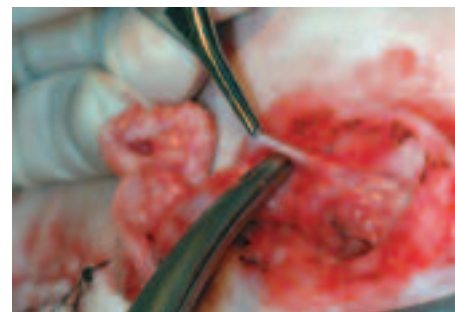
4 The penile body must now be detached from the pelvis so that it can be exposed to the level of the bulbourethral glands. A tight, thin band of fibrous tissue that connects the penis to the pubis can be palpated immediately ventral to the penile body (**A**). Transect the caudal aspect of the tissue (**B**), then insert an index finger between the penile body and caudal rim of the pelvis and gently separate the tissues to the level of the cranial pubic brim.



5 Now the ischiocavernosus muscles should be easily identifiable laterally at the 4 and 8 o'clock positions. These muscles can be transected sharply by placing the blades of the Metzenbaum scissors on either side of the muscle (**arrows**) and pressing them against the pelvis while cutting (dorsal recumbency in photograph). Cutting close to periosteal attachments will reduce hemorrhage from these muscles. Once these muscles are transected, the penile body should be freely moveable and no attachments to the pelvis will be palpable.

PROCEDURE PEARL

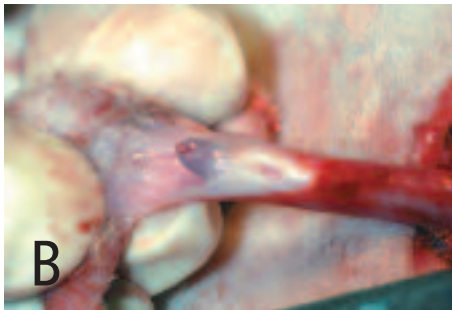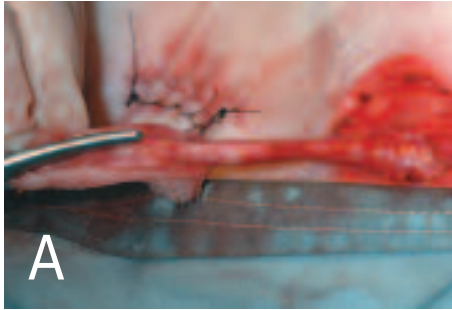
To avoid nerve damage, subcutaneous dissection should not extend cranial to the brim of the pubis.



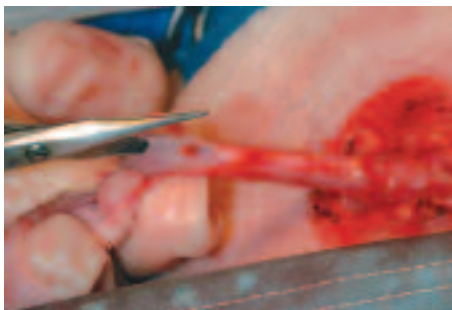6 If still present, the retractor penis muscle is excised from the dorsal penile body; this muscle may already have been removed if subcutaneous dissection was performed with a gauze sponge.

PROCEDURE PEARL

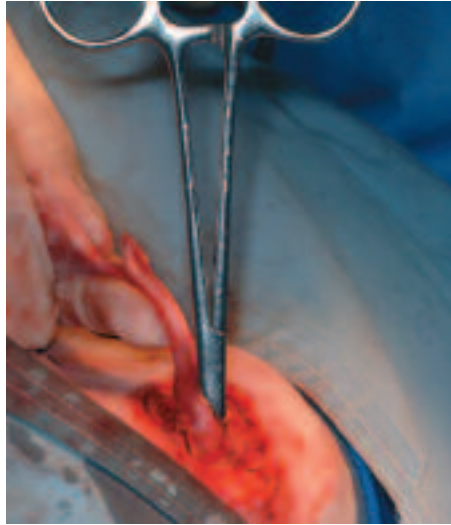Because of increased diaphragmatic pressure, cats in a perineal position may require ventilatory assistance during perineal urethrostomy. The impact of this positioning can be avoided, however, by placing a support under the sternum and extended forelimbs of the patient so that the abdomen is not resting on the table.



7 Cut the prepuce open dorsally (A) to expose the distal penis and urethral opening (B). For image A, a cystostomy had already been performed.

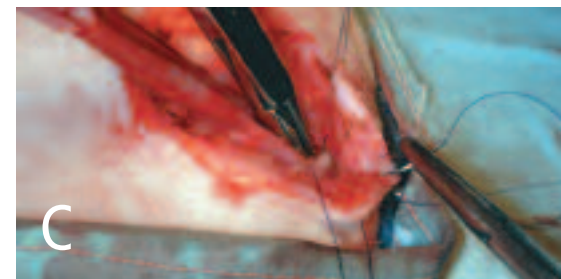
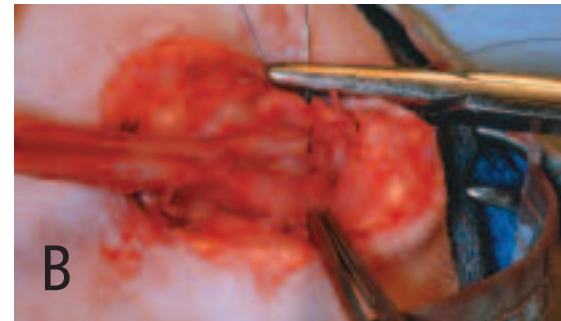
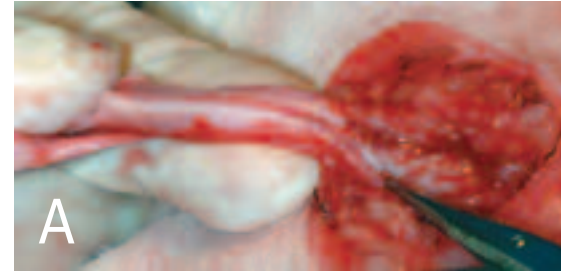


8 Insert one blade of an iris scissors into the urethral opening and cut along the dorsal midline cranially to the level of the bulbourethral glands. At that level, closure of the scissors often elicits a palpable crunch when the tissues are cut.



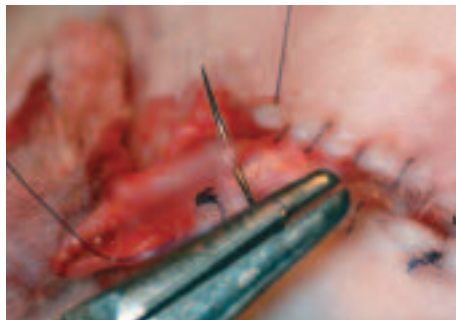9 The final urethral diameter should be large enough to permit insertion of a straight Kelly hemostatic forceps to its box locks. Alternatively, an 8FG urethral catheter should be accommodated by the urethrostomy and can be useful as a guide during subsequent suturing.

PROCEDURE PEARL
To avoid narrowing the stoma, take bites of the urethral mucosa that are less than one third of the diameter of the urethra. Avoid trauma to the mucosa produced by swabbing by using damp sterile cotton swabs to wipe blood from the urethral surface during suturing. Use small needle holders (eg, Castroviejo or Derf) for suturing. If grasping urethral mucosa directly, use fine tissue forceps (Adson 2-by-1 rat teeth or smaller). Alternatively, grasp the periurethral tissue with DeBakey thumb forceps and evert it to expose the mucosa during suturing. Excellent illumination is essential, and magnification may be helpful.

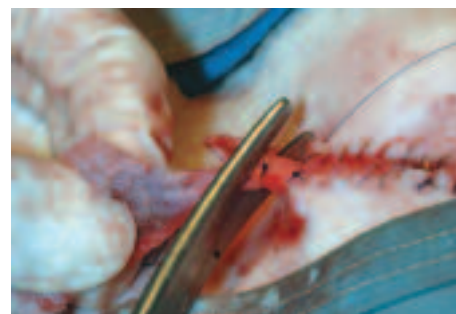

10 Identify the striated, white, glistening urethral mucosa at the dorsal extent of the incision (A). The mucosa retracts away from the penile body and can be easily missed, especially if obscured by hemorrhage. Using 4-0 or 5-0 rapidly absorbable monofilament suture, such as glycomer 631 (Biosyn; Tyco Healthcare/Kendall, www.kendallhealthcare.com) or poliglecaprone 25 (Monocryl; Ethicon, Inc, www.ethiconinc.com), preplace interrupted sutures at the 10, 12, and 2 o'clock positions between the skin and the urethral mucosa (B and C). To avoid grabbing the ventral portion of the urethra during placement of the 12 o'clock suture, insert a hemostat in the urethral stoma and open the jaws to separate the dorsal and ventral portions of the urethra (C). The penile body and subcutaneous tissues are not included in the sutures. Tie the preplaced sutures and cut the ends short (≥ 1 mm).

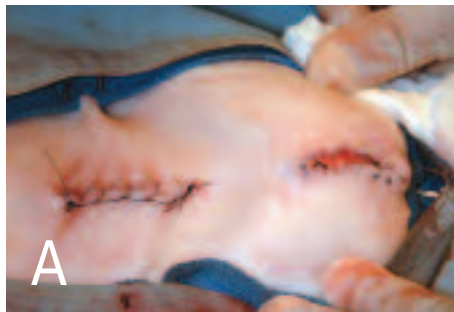continues



11 Starting dorsally, appose the urethral mucosa on one side of the urethral incision to the skin with a simple continuous pattern using the same suture material. The suture pattern is continued until the penile body and urethra begin to narrow. Tie off at this point, and cut the suture ends of the knot short. Appose the remaining urethral mucosa on the opposite side in a similar manner. This will produce a “drainboard” of 15 to 20 mm.

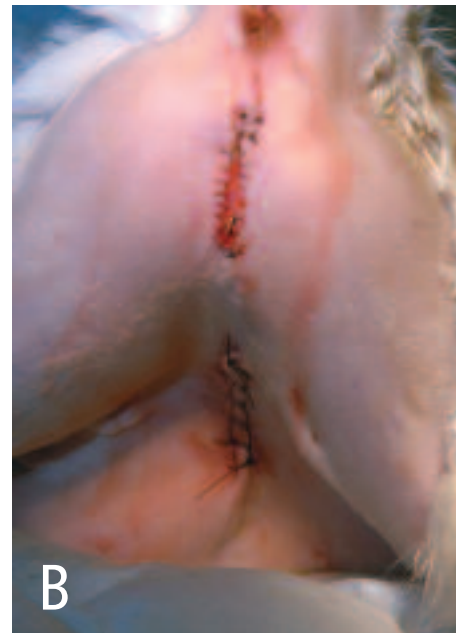

12 Ligate the penile body distal to the mucocutaneous closures and amputate the tip of the penis before finishing the ventral portion of the second mucocutaneous suture pattern. Close any remaining gaps in the subcutaneous tissues and skin with buried sutures. Remove the purse-string suture from the anus.



13 The completed perineal urethrostomy will have a drainboard that is 1.5 to 2 cm long (A and B). The stoma should allow the passage of an 8FG urethral catheter at this stage. ■

See Aids & Resources, back page, for references, contacts, and appendices.



Postoperative Care

Place an Elizabethan collar on the cat before recovery, and leave the collar on for at least 7 days. Sutures will not need to be removed in most cats; once the site is healed, the sutures will probably come out during grooming. Urine cultures are recommended 1, 3, 6, and 12 months after surgery because risk for urinary tract infections is increased after perineal urethrostomy in cats previously diagnosed with uropathies.

Potential Complications

Complications include dysuria, pollakiuria, hematuria, hemorrhage, dehiscence, dermatitis, cellulitis, perineal urine extravasation, stricture, urinary or fecal incontinence, urinary tract infection, recurrence of lower urinary tract disease, rectal prolapse, rectourethral fistula formation, and perineal hernia. Stricture (12%) and bacterial urinary tract infections (23%) are the most common postoperative complications. Strictures usually occur at the mucocutaneous junction and are related to inadequate mobilization of the body of the penis (failure to identify and transect the ischiocavernosus muscles), or inadequate mucosa-to-skin apposition with subsequent urine extravasation.

Placement of an Elizabethan collar is essential to prevent patient interference during the healing phase and subsequent stricture formation. In most cases, a urethral catheter should not be in place after surgery because it has been related to an increased incidence of postoperative stricture formation; however, cats with subcutaneous urine extravasation after surgery may require placement of a Foley catheter for 2 to 3 days until the mucocutaneous junction seals.