

# Brachycephalic Syndrome

**Heidi Phillips, VMD, DACVS (Small Animal)**  
University of Illinois

Brachycephalic syndrome affects dogs with markedly shortened craniofacial conformation and can result in dyspnea, exercise intolerance, collapse, and death if not treated appropriately. Corrective airway surgery is best implemented early in life and can be safely performed in dogs as young as 4 to 6 months.<sup>1-8</sup> Delaying surgery can predispose brachycephalic dogs to laryngeal collapse, pneumonia, fibrotic lung conditions, and cardiovascular disease, including heart base tumors.<sup>7-10</sup> Older dogs may also have more difficulty recovering from surgery.



## Case Overview

Maggie, an 8-year-old spayed English bulldog with a history of noisy breathing, presented to University of Illinois Veterinary Teaching Hospital because of 2 episodes, within 1 week of each other, of severe respiratory distress requiring emergency sedation. An oral examination by her primary veterinarian

TABLE  
**1** | **Brachycephalic Dog Breeds**<sup>3,16</sup>

Small Breed	Medium-to-Large Breed
Boston terrier	Boxer
Brussels griffon	Bull mastiff
French bulldog	Chinese shar-pei
Lhasa apso	Dogue de Bordeaux
Pekingese	English bulldog
Pug	
Shih tzu	

**Most dogs with brachycephalic syndrome have moderate-to-severe upper airway obstruction because of anatomic abnormalities.**

showed an elongated soft palate, everted laryngeal sacculles, and stenotic nares. Maggie was prescribed prednisone for at-home management and referred for surgical assessment and treatment for brachycephalic syndrome.

Brachycephalic syndrome is a chronic, debilitating, and potentially fatal condition in dog breeds with markedly shortened craniofacial conformation.<sup>1-3</sup> (See **Table 1**.)

Congenital and acquired deformities result from selection for craniofacial bony shortening without a concomitant reduction in the volume of nasopharyngeal and oropharyngeal soft tissues.<sup>3-8</sup> Anatomic abnormalities include stenotic nares, an elongated soft palate, and a hypoplastic trachea, diagnosed in 58% to 85%, 62% to 100%, and 13% of brachycephalic dogs, respectively.<sup>9-11</sup> Aberrant rostral and caudal nasopharyngeal turbinates and intranasal mucosal contact points have also been described.<sup>12,13</sup>

Most dogs with brachycephalic syndrome have moderate-to-severe upper airway obstruction because of anatomic abnormalities.<sup>1</sup> Mild-to-severe respiratory clinical signs predominate and include snoring or stertor, coughing, stridor, inspiratory dyspnea, difficulty eating, exercise intolerance, cyanosis, collapse, syncope, and death.<sup>3,7-9</sup> Affected

dogs are more likely to experience respiratory signs when stressed or anxious, during exercise or restraint, and in hot weather. Panting caused by overheating can worsen swelling of tissue within the airway. Obesity also contributes to dyspnea in many dogs with brachycephalic syndrome, and an inability to exercise vigorously may predispose these dogs to weight gain.<sup>8-9</sup>

Gastrointestinal disorders such as regurgitation, vomiting, gastritis, duodenitis, hiatal hernia, and aspiration pneumonia can accompany respiratory issues.<sup>3,10</sup> Brachycephalic dogs may also be diagnosed with sleep disorders, including sleep apnea, which may be linked to systemic hypertension development.<sup>3,10</sup> Cardiopulmonary disorders, including hypoxemia, hypercapnea, bronchial collapse, polycythemia, heatstroke, and hypertension, and neoplastic disorders such as chemodectoma may also be present.<sup>2,3,7-10,14</sup>

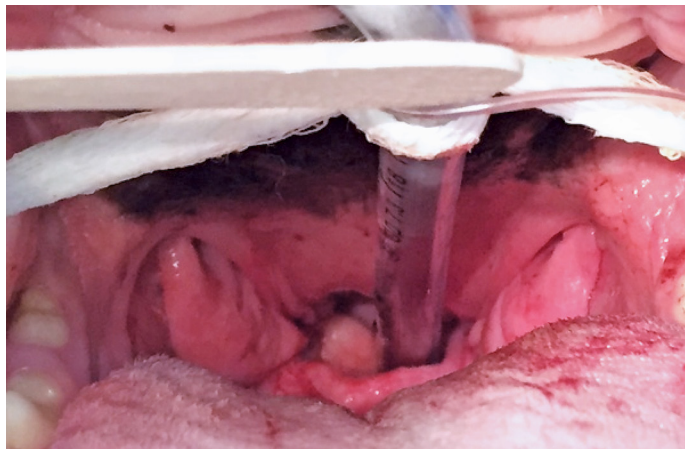
Demand for brachycephalic conformation as a breed standard persists despite health issues associated with the anatomic abnormalities.<sup>15</sup> The American Kennel Club and Kennel Club of the United Kingdom reported increases of more than 450% in registration of brachycephalic breeds from 2000-2010, indicating a sizable at-risk population.<sup>3-4,11,15</sup>

## Diagnosis

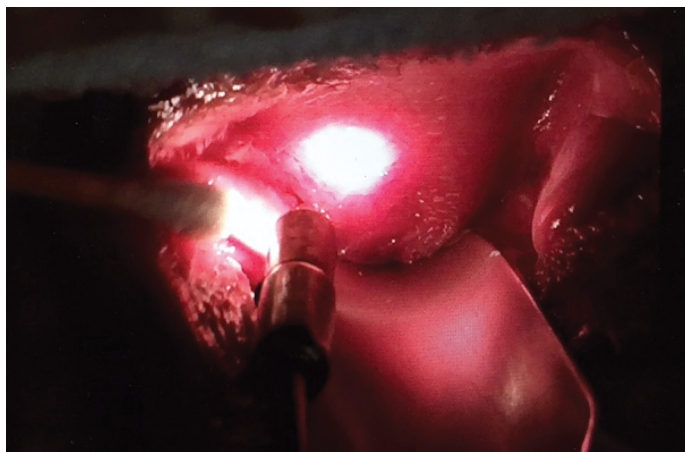Maggie had a body condition score of 8/9. Physical examination showed stenotic nares. Auscultation of the larynx, trachea, and lung fields disclosed upper airway noise. Routine clinical laboratory tests, including CBC, serum chemistry profile, and urinalysis, were within normal limits. Neck and thoracic radiographs showed a hypoplastic trachea and no signs of underlying cardiac disease or aspiration pneumonia.

Differential diagnoses included brachycephalic syndrome, laryngeal paralysis, upper airway foreign body, neoplasia, and trauma. Following IV administration of butorphanol and propofol, examination of Maggie's airway disclosed everted, markedly enlarged palatine tonsils (see **Figure 1**), an elongated soft palate (see **Figure 2**), and everted laryngeal sacculae (see **Figure 3**). Visual examination of the larynx during inspiration and expiration showed no laryngeal paralysis, but focal contact of the corniculate and cuneiform processes of the arytenoid cartilages on inspiration confirmed mild Stage III laryngeal collapse. The stages are:

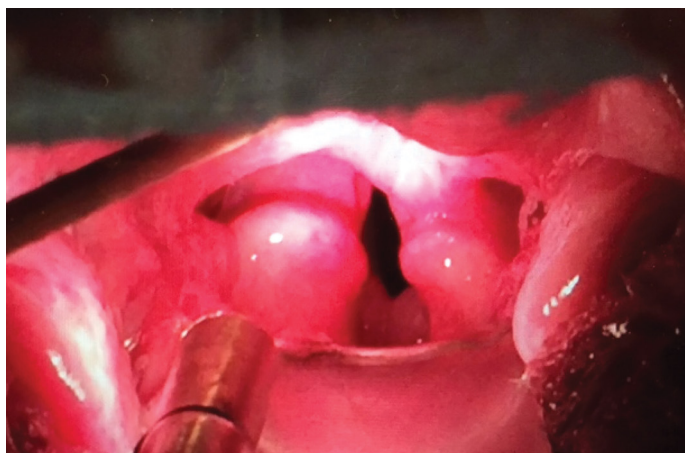
- **Stage I:** Everted laryngeal sacculae
- **Stage II:** Collapse or paradoxical motion of cuneiform processes of the arytenoid cartilages
- **Stage III:** Collapse or paradoxical motion of the corniculate processes of the arytenoid cartilages



▲ **FIGURE 1** Intraoral view of everted tonsils in the brachycephalic patient



▲ **FIGURE 2** Intraoral view of the elongated soft palate; note the palate extends caudal to the caudal-most aspect of the tonsillar crypts



▲ **FIGURE 3** Intraoral view of everted sacculae in the brachycephalic patient

Photos courtesy of Heidi Phillips, VMD, DACVS (Small Animal)



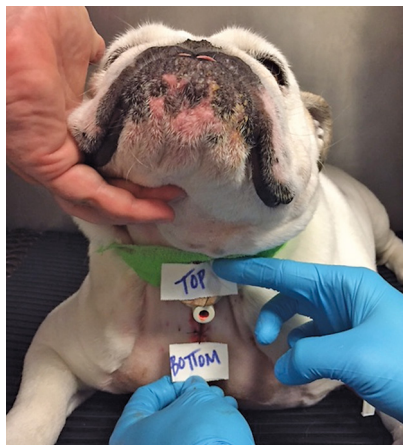## Treatment

Treatment for laryngeal collapse includes unilateral arytenoid lateralization or permanent tracheostomy, which may predispose patients to aspiration pneumonia or require lifestyle changes, respectively. Because Maggie's tissue-related airway obstruction was severe, the surgeon chose to treat the airway anatomic abnormalities before addressing the laryngeal collapse.

Maggie was anesthetized, the elongated soft palate was trimmed sharply to the level of the caudal tonsillar crypts, and the oral and nasal mucosa were sutured in a simple continuous pattern of 3-0 poliglecaprone-25. The everted palatine tonsils were trimmed by clamping lateral to the tonsillar tissue with a Kelly hemostat and sharply excising each tonsil with a #15 blade.

The everted sacculles were removed by gentle grasping of the everted mucosa, pulling toward the midline, and sharply transecting the base of the tissue with a #15 blade. The nares were widened using wedge resection alaplasty. A large pyramid-shaped tissue wedge was resected from the alar wing, and the remaining tissues were joined with interrupted sutures of 4-0 poliglecaprone-25.

## Outcome



▲ **FIGURE 4** Postoperative view of the temporary tracheostomy site. The cranial-most stay suture is passed circumferentially around the tracheal ring just cranial to the tracheotomy and labeled *Top*. The caudal-most suture is passed circumferentially around the tracheal ring just caudal to the tracheotomy and labeled *Bottom*. These stay sutures remain in place as long as the tracheostomy tube is needed. They facilitate replacement of a temporary tube removed for cleaning or replacement of a tube inadvertently dislodged.

Postoperatively, Maggie had swelling of the oral and laryngeal tissues, a common consequence of airway surgery, and required temporary tracheostomy during recovery. (See **Figure 4**.) The tracheostomy tube remained in place while she was monitored and managed in the ICU. The tube was removed on postoperative day 4 after the swelling resolved, and Maggie was able to breathe without significant difficulty. ■

### References

1. Bernaerts F, Talavera T, Leemans J, et al. Description of original endoscopic findings and

- respiratory functional assessment using barometric whole-body plethysmography in dogs suffering from brachycephalic airway obstruction syndrome. *Vet J*. 2010;183(1):95-102.
2. Hendricks JC. Brachycephalic airway syndrome. *Vet Clin North Am Small Anim Pract*. 1992;22(5):1145-1153.
3. Packer RM, Hendricks A, Tivers MS, Burn CC. Impact of facial conformation on canine health: brachycephalic obstructive airway syndrome. *PLoS One*. 2015;10(10):e0137496.
4. Liu NC, Sargan DR, Adams VJ, Ladlow JF. Characterization of brachycephalic obstructive airway syndrome in French bulldogs using whole-body barometric plethysmography. *PLoS One*. 2015;10(6):e0130741.
5. Oechtering GU, Pohl S, Schlueter C, et al. A novel approach to brachycephalic syndrome. 1. Evaluation of anatomical intranasal airway obstruction. *Vet Surg*. 2016;45(2):165-172.
6. Oechtering GU, Pohl S, Schlueter C, Schuenemann R. A novel approach to brachycephalic syndrome. 2. laser-assisted turbinectomy (LATE). *Vet Surg*. 2016;45(2):173-181.
7. Pratschke K. Current thinking about brachycephalic syndrome: more than just airways. *Comp Anim*. 2014;19(2):70-78.
8. Roedler FS, Pohl S, Oechtering GU. How does severe brachycephaly affect dog's lives? Results of a structured preoperative owner questionnaire. *Vet J*. 2013;198(3):606-610.
9. Fasanella FJ, Shivley JM, Wardlaw JL, Givaruangsawat S. Brachycephalic airway obstructive syndrome in dogs: 90 cases (1991-2008). *J Am Vet Med Assoc*. 2010;237(9):1048-1051.
10. Hoareau GL, Jourdan G, Mellema M, Verwaerde P. Evaluation of arterial blood gases and arterial blood pressures in brachycephalic dogs. *J Vet Intern Med*. 2012;26(4):897-904.
11. Meola SD. Brachycephalic airway syndrome. *Top Companion Anim Med*. 2013;28(3):91-96.
12. Ginn JA, Kumar MS, McKiernan BC, Powers BE. Nasopharyngeal turbinates in brachycephalic dogs and cats. *J Am Anim Hosp Assoc*. 2008;44(5):243-249.
13. Schuenemann R, Oechtering GU. Inside the brachycephalic nose: intranasal mucosal contact points. *J Am Anim Hosp Assoc*. 2014;50(3):149-158.
14. Poncet CM, Dupre GP, Freiche VG, Bouvy BM. Long-term results of upper respiratory syndrome surgery and gastrointestinal tract medical treatment in 51 brachycephalic dogs. *J Small Anim Pract*. 2006;47(3):137-142.
15. Asher L, Diesel G, Summers JF, McGreevy PD, Collins LM. Inherited defects in pedigree dogs. Part 1: disorders related to breed standards. *Vet J*. 2009;182(3):402-411.
16. Packer RMA, Hendricks A, Burn CC. Do dog owners perceive the clinical signs related to conformational inherited disorders as 'normal' for the breed? A potential constraint to improving canine welfare. *Animal Welfare*. 2012;21(S1):81-93.

# Team Management

**Michelle Jaeger, BS, CVT, VTS (Surgery)**  
University of Illinois

Brachycephalic dogs (see **Table 1**, page 32) often experience respiratory difficulties caused by their common anatomic abnormalities. All veterinary team members should be prepared to provide immediate care to brachycephalic patients that arrive in respiratory distress.

## Client Communication

Client care team members are usually the first approached about these patients and should instruct a client who calls about a pet in respiratory distress to keep the animal calm and in a cool environment, limit activity, and bring him or her to the practice as quickly as possible for evaluation.

If a brachycephalic patient is in respiratory distress, immediate treatment, including oxygen and sedative administration, and possibly endotracheal intubation or tracheostomy to secure an airway, is required. Also, these patients often become overheated; in these cases, administer IV fluids, apply isopropyl alcohol to the foot pads, or use a fan to cool the patient. If the patient is not in distress but has been brought to the practice because the client is concerned about signs that may be associated with brachycephalic

syndrome, team members should take the following steps.

## Patient History

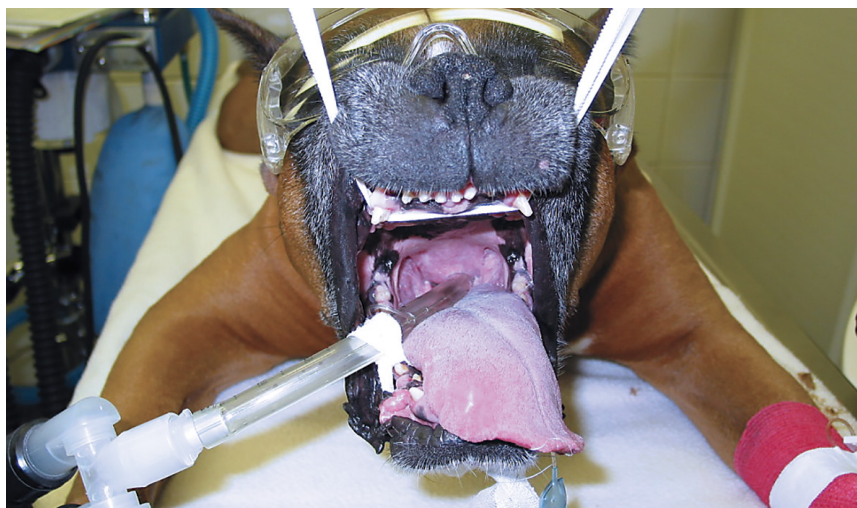With any brachycephalic patient, obtain a patient history that focuses on respiratory issues, including noisy breathing, dyspnea, difficulty sleeping because of open-mouth breathing, coughing, vomiting, regurgitation, gagging, exercise intolerance, heat intolerance, cyanosis, and collapse.<sup>1</sup> These signs are caused by anatomical abnormalities (collectively known as brachycephalic syndrome), including stenotic nares, elongated soft palate (see **Figure 1**), everted laryngeal sacculles, hypoplastic trachea, redundant pharyngeal tissue, and laryngeal collapse, which cause upper airway obstruction.<sup>2</sup>

Clear communication with clients during history-taking is important because they often believe their

brachycephalic pet's snoring is normal. The team member should explain that snoring is actually not normal and likely part of brachycephalic syndrome, but proper medical management and surgery could help the pet be more comfortable and prevent a potentially life-threatening situation.

Also, a team member should explain briefly to the client that the veterinarian may suggest various diagnostic tests (eg, thoracic radiography)

**With any brachycephalic patient, a thorough patient history should focus on respiratory issues.**



▲ **FIGURE 1** Elongated soft palate

Photo courtesy of Michelle Jaeger, BS, CVT, VTS (Surgery)

## A brachycephalic patient must be closely monitored postoperatively for respiratory distress.

to evaluate the patient for brachycephalic syndrome and other conditions, such as aspiration pneumonia, hypoplastic trachea, and cardiac disease, and that surgery may be necessary. The client should also be informed the patient may need multiple procedures that will not be identified until the patient is anesthetized and the airway examined.

### Patient Evaluation

After studying the patient and the history, the veterinarian should discuss with the client potential surgical procedures that may be necessary following the evaluation, including alar wedge resection, staphylectomy, and laryngeal sacculectomy.

Alar wedge resection involves removing a small piece of the nares to create a wider opening. Staphylectomy entails shortening the soft palate using appropriate anatomic landmarks as a guideline. Often, because of other anatomic abnormalities, the laryngeal saccules become everted and require removal with Allis tissue forceps and Metzenbaum scissors.

The veterinarian should also explain that before any surgery, the patient's larynx would be examined under light anesthesia to evaluate soft palate length, if the tonsils and laryngeal saccules are everted, and if laryngeal

collapse has occurred. Performing this examination and then proceeding immediately with surgery, if necessary, is an advantage because the patient only undergoes one anesthetic event. Treatment with oral steroids to decrease airway swelling may also be indicated.

After the veterinarian's explanation, a team member should always provide the client with an estimate of all potential charges.

### Surgical Procedures

When the decision has been made to perform surgery, the patient should be placed in sternal recumbency with the head resting on a rolled towel. The veterinary nurse should use aseptic technique to prepare the area around the nares and suspend the maxilla using white tape or gauze threaded behind the maxillary canines and tied on either side of the surgical table to IV fluid poles.

If alar wedge resection is performed using either a surgical scalpel blade or carbon dioxide laser, cotton tip applicators and phenylephrine hydrochloride can be utilized topically to control bleeding.<sup>3</sup> Long, curved instruments, including Allis tissue forceps, Metzenbaum scissors, and needle drivers, will be used for soft palate resection and everted laryngeal sacculectomy.

Some veterinarians routinely perform tracheostomy following multiple upper airway procedures, whereas others do so only in patients with emergent respiratory distress, but tracheostomy instruments and supplies should always be available when performing any procedure on these patients.

Small-diameter endotracheal tubes should be readily available in case immediate intubation is necessary because brachycephalic dogs often require tubes smaller than other similarly-sized dog breeds that do not have the same anatomical abnormalities.

The veterinary nurse must closely monitor a brachycephalic patient postoperatively for respiratory distress. Instruments needed to reintubate or perform a temporary tracheostomy because of swelling or edema should be readily available. A patient may be placed postoperatively in an oxygen cage for 24-hour monitoring for indications of swelling impacting respiratory function.

### Client Care

When the patient is ready for discharge, the veterinary nurse should review at-home care with the client, including:

- Elizabethan collar instructions, if an alar wedge resection was performed
- Exercise restrictions
- Diet restrictions (eg, soft food only for 2 weeks) if staphylectomy or sacculectomy was performed

- Recommending harness use when walking
- Pain management
- Follow-up appointment instructions (eg, when to schedule, if patient should fast before the appointment if suture removal will require sedation)
- Long-term management, if necessary (eg, weight loss in obese patients)

### Conclusion

Brachycephalic patients require special knowledge and care. Team members should be thoroughly trained and know their role when these patients are brought to the practice, whether their visit is for routine problems associated with their breed, for follow-up care after

stabilization, or because they are in respiratory distress. ■

### References

1. Hedlund CS. Surgery of the upper respiratory system. In: Fossum TW. *Small Animal Surgery*. 3rd ed. St. Louis, MO: Mosby, Inc; 2007:817-867.

2. Reiter AM, Holt DE. Palate. In: Tobias KM, Johnston SA, eds. *Veterinary Surgery: Small Animal*. St. Louis, MO: Saunders; 2012:1707-1718.
3. Macintire DK, Drobatz KJ, Haskins SC, Saxon WD. *Manual of Small Animal Emergency and Critical Care Medicine*. 2nd ed. West Sussex, UK: Wiley-Blackwell; 2012:620.



## TEAM TAKEAWAYS

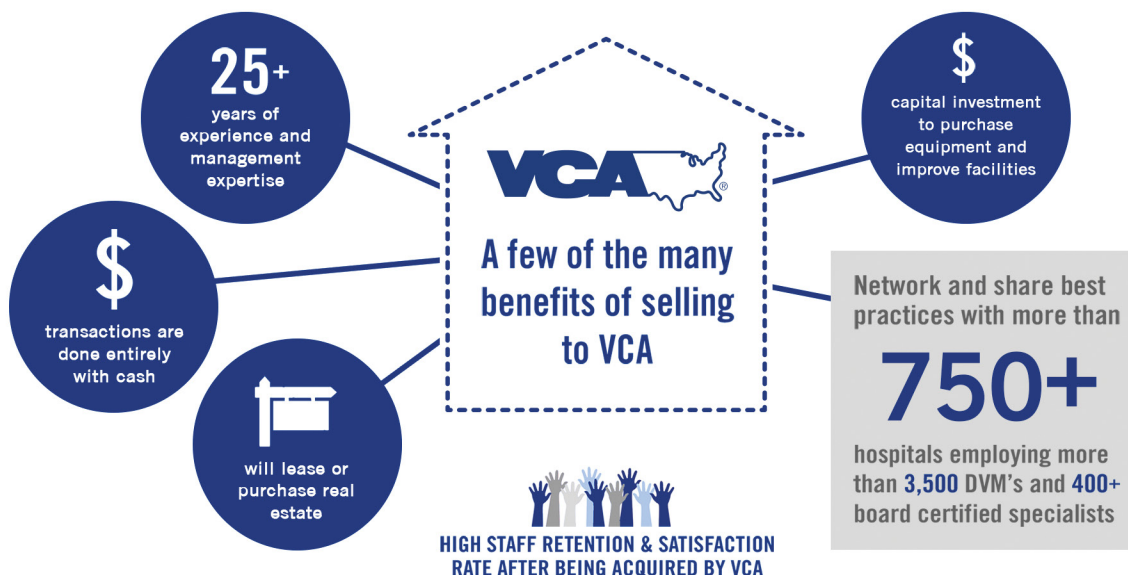
**Veterinarians:** Take time to explain to clients that brachycephalic breeds with respiratory difficulties may need multiple tests and surgical procedures, first to determine if they have brachycephalic airway syndrome and then to correct the syndrome.

**Nursing Team:** When taking the patient's history, be sure the client understands that many signs they may consider normal for their pet (eg, noisy breathing, snoring) may actually be signs of brachycephalic syndrome and require treatment.

**Client Care Team:** Clients whose brachycephalic pet is experiencing respiratory difficulties will first reach a client care team member, so be knowledgeable about what the client must do before bringing the patient to the practice.

# Considering Selling Your Practice?

VCA is selectively acquiring practices throughout the United States.



## Start the Conversation Today!

**West, Northwest, Southwest**  
Director of Acquisitions  
**Trent Homec**  
925.939.3965  
trent.homec@vca.com

**Central & Midwest**  
Director of Acquisitions  
**Sean Hayes**  
243.915.5794  
sean.hayes@vca.com

**Northeast & Southeast**  
Director of Acquisitions  
**Peter Kilkelly**  
203.707.0850  
peter.kilkelly@vca.com

