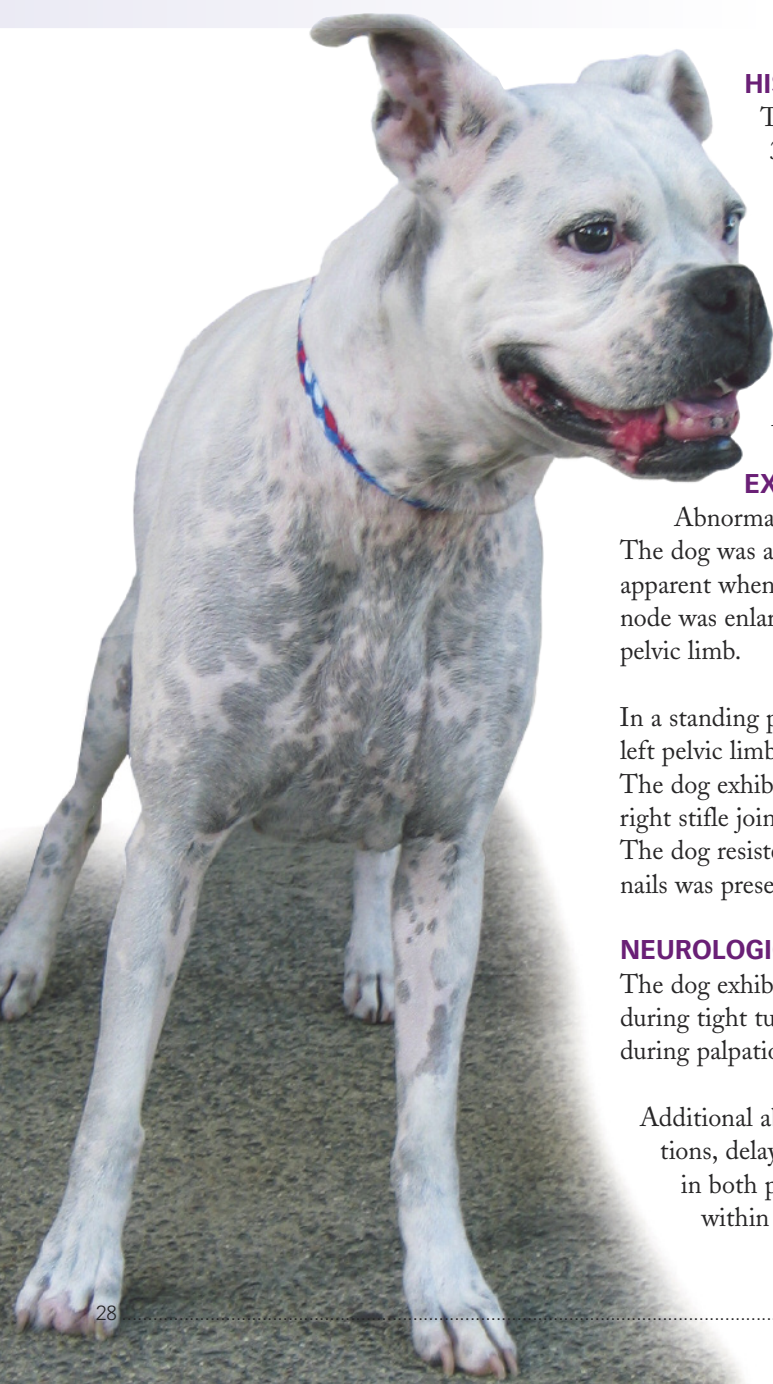

Pelvic Limb Lameness

An 8-year-old female boxer dog was presented for persistent right pelvic limb lameness.



HISTORY

The owner had noted right pelvic limb lameness of sudden onset 3 months before presentation. The lameness had worsened despite glucocorticoid administration (prednisone, 0.3 mg/kg PO Q 24 H for 4 weeks), followed 2 weeks later by an NSAID (carprofen, 2 mg/kg PO Q 12 H for 3 weeks). The owner also reported that during the past 5 months the dog had been “scraping the nails” of both pelvic limbs on the ground while walking.

All medications were discontinued 2 weeks before presentation.

EXAMINATION

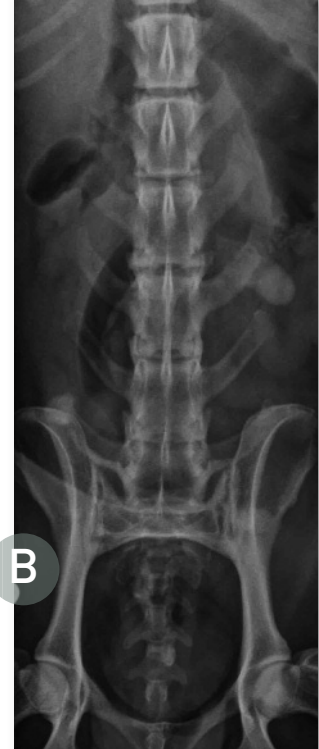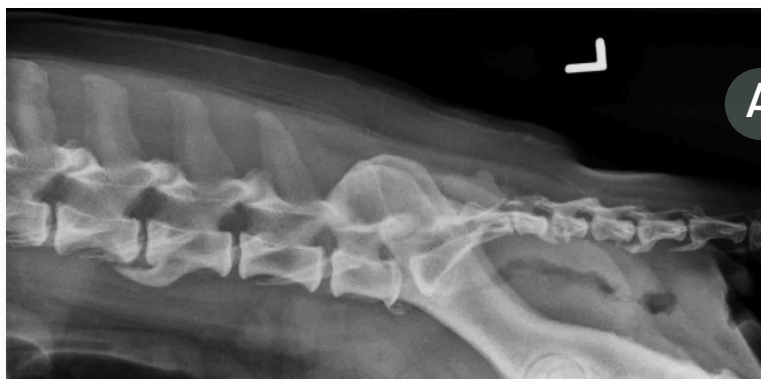Abnormalities noted on examination were confined to the pelvic limbs. The dog was ambulatory. Mild atrophy of muscles of the right pelvic limb was apparent when compared with the left pelvic limb. The right popliteal lymph node was enlarged. Moderate weight-bearing lameness was present in the right pelvic limb.

In a standing position, the dog appeared to bear weight predominantly on the left pelvic limb while holding the right pelvic limb in a slightly flexed position. The dog exhibited signs of apparent pain on manipulation and palpation of the right stifle joint, although cranial drawer or tibial thrust could not be elicited. The dog resisted manipulation of both coxofemoral joints. Abnormal wear of nails was present in both pelvic limbs.

NEUROLOGIC EVALUATION

The dog exhibited subtle pelvic limb paresis and ataxia that were exacerbated during tight turns and while ascending or descending stairs. Pain was evident during palpation of the dorsal mid-lumbar vertebral column.

Additional abnormalities included absent proprioceptive positioning reactions, delayed hopping and hemiwalking reactions, and absent patellar reflex in both pelvic limbs. The remainder of the neurologic evaluation was within normal limits.



1 Lateral (A) and ventrodorsal (B) radiographs of the lumbosacral vertebral column. Note multiple levels of spondylosis deformans.

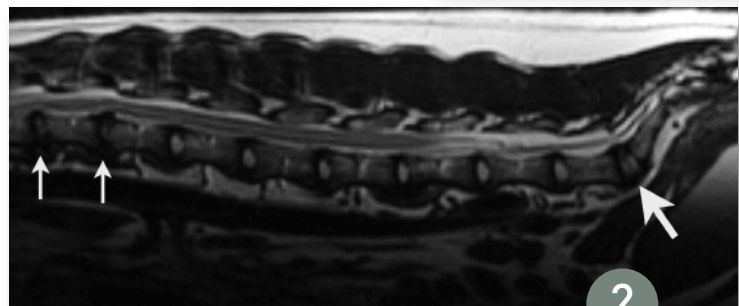
DIAGNOSTIC FINDINGS

CBC, serum biochemical panel, and urinalysis findings were normal. Thoracic radiography and abdominal ultrasonography were unremarkable. Radiographs of the stifle joints and coxofemoral joints were normal.

Cytologic examination of fine-needle aspirates from the right popliteal lymph node revealed marked reactive and plasma cell lymphoid hyperplasia and mild histiocytic hyperplasia. Cytologic examination of fluid aspirated from the right stifle joint revealed a normal density of background glycosaminoglycans and low (normal) numbers of nucleated cells that were almost exclusively large mononuclear/synoviocyte-type cells.

Plain radiography of the entire vertebral column completed with the dog under general anesthesia confirmed partial mineralization of multiple intervertebral disks as well as moderate multifocal spondylosis of the thoracic and lumbar vertebral column (Figure 1). Mild spondylosis and sclerosis of vertebral endplates were observed at the lumbosacral junction. Flexed and extended lateral projections of the region failed to reveal evidence of abnormal L7–S1 motion.

Cerebrospinal fluid collected from the lumbar cistern was clear, colorless, and acellular, with a protein content of 38 mg/dL (reference range, <30 mg/dL). The results of pre- and postcontrast MRIs of the caudal thoracic, lumbar, and sacral vertebral column (Figure 2) confirmed spondylosis deformans and mild protrusion without



2 Paramedian MRI of the lumbosacral vertebral column. Note intervertebral disk degeneration at T12–T13 and T13–L1 (small arrows), and at L7–S1 (large arrow).

notable impingement of partially dehydrated intervertebral disks at T12–T13, T13–L1, and L7–S1.

The only abnormality noted on electromyography and nerve conduction studies of the right pelvic limb was reduced amplitude and dispersion of sensory-evoked potentials in the presence of normal determinations for sensory nerve conduction velocity.

ASK YOURSELF ...

- Is this dog's lameness the result of an orthopedic problem, a neurologic problem, or a combination of both?
- What are the diagnostic differentials for this dog's problem(s)?
- Based on laboratory findings, what is the most likely diagnosis?
- Would genetic testing confirm that diagnosis?

CBC = complete blood count, MRI = magnetic resonance imaging, NSAID = nonsteroidal antiinflammatory drug

CONTINUES

You know our products, *take time to know our name.*



Visit us at **Booth #631**



JOIN BOEHRINGER INGELHEIM VETMEDICA, INC. FOR OUR SYMPOSIA DAY

Monday, January 16, 2012

8:00 a.m. – 9:15 a.m.

Leptospirosis: A Re-emerging Disease

• Dr. Carrie White, DVM, DACVIM

Associate Staff Doctor, Animal Medical Center, NYC

9:55 a.m. – 10:45 a.m.

Problems in Diagnosing Leptospirosis: Keeping Your Head Above Water

• Dr. George Moore, DVM, PhD, DACVPM, DACVIM

Director, Clinical Trials Group, Associate Professor of Clinical Epidemiology, School of Veterinary Medicine, Purdue University

10:55 a.m. – 11:45 a.m.

Feline Vaccine Issues

• Dr. Mike Lappin, DVM, PhD, DACVIM

Assistant Department Head for Research, The Kenneth W. Smith Professor in Small Animal, Clinical Veterinary Medicine
Colorado State University

1:45 p.m. – 2:35 p.m.

Managing a Canine Patient with Heart Disease Before You Get the Echo

• Dr. Andy Beardow, BVM&S, MRCVS, DACVIM

Veterinary Cardiologist

2:45 p.m. – 3:35 p.m.

Managing a Murmur: Building a Winning Partnership Between the Practitioner & Dog Owner

• Dr. Andy Beardow, BVM&S, MRCVS, DACVIM

Veterinary Cardiologist

3:55 p.m. – 4:50 p.m.

Have We Seen Your Cat Lately? Driving Feline Care

• Dr. Karen Felsted, CPA, MS, DVM, CVPM

CEO-National Commission on Veterinary Economic Issues

Visit Boehringer Ingelheim Vetmedica, Inc. at booth #631

DIAGNOSIS:

Degenerative myelopathy and right stifle arthropathy

In dogs older than 5 years of age, degenerative myelopathy (DM) refers to a disorder in which diffuse axonal necrosis is present primarily in the lateral and ventral funiculi of the thoracolumbar spinal cord segments. However, DM must be considered as a possible cause of prolonged, slow progression of pelvic limb paresis and ataxia in any dog (**Figure 3**). Secondary demyelination and astrogliosis are associated with this axonopathy (**Figure 4**). Definitive diagnosis is determined postmortem by histopathologic examination of the spinal cord.

Although it was first reported in the German shepherd, DM has now been recognized in many other breeds (eg, boxer, Rhodesian ridgeback, Bernese mountain dog, Pembroke Welsh corgi). A diagnosis of DM is challenging because clinical presentation can mimic that of many acquired spinal cord diseases.

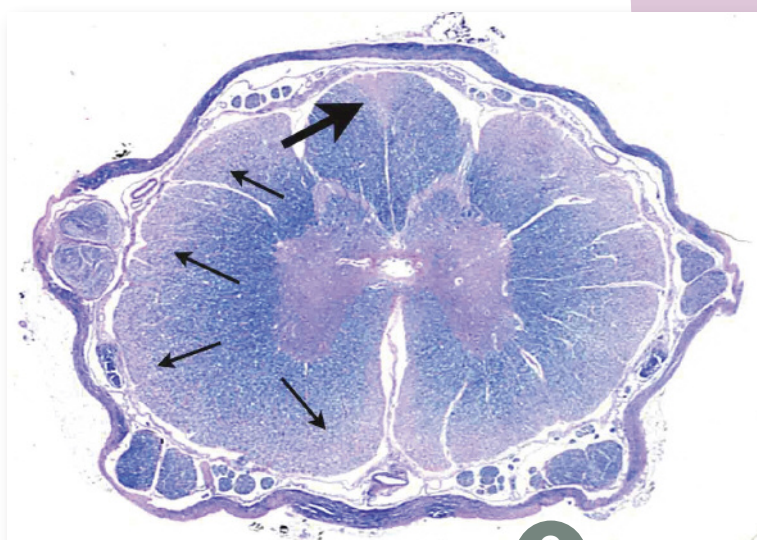
TREATMENT

Physiotherapy, exercise, vitamin supplementation, glucocorticoids, and treatment with the protease inhibitor aminocaproic acid have all been advocated as potential therapies for DM. However, definitive evidence-based data to support their routine and consistent therapeutic use are still not available.

OUTCOME

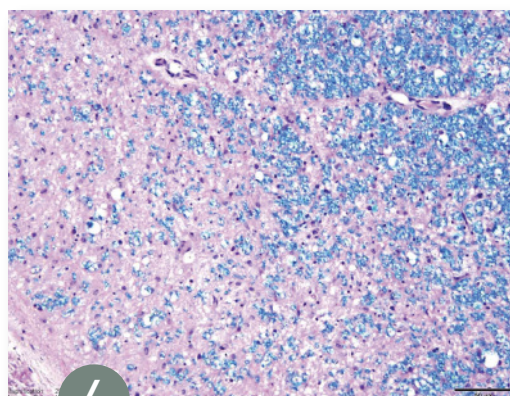
Clinical signs in dogs affected with DM will progress to lower motor neuron paralysis of the pelvic limbs. Eventually thoracic limbs may become involved. The clinical course for DM varies after a presumptive diagnosis has been made. A mean time of 6 to 9 months for progression from onset of clinical signs to nonambulatory pelvic limb paresis is expected in larger breeds. Owners usually elect euthanasia when dogs are no longer able to support weight on their pelvic limbs.

CONTINUES



3

Transverse section of thoracic spinal cord of a German shepherd with DM. Note the bilaterally symmetric areas of myelin loss (secondary to axonal loss), which is most prominent in lateral and ventromedial funiculi (**small arrows**) and the medial dorsal column (**large arrow**). (Luxol fast blue/hematoxylin-eosin)



4

High-power view of the lateral funiculus of the dog in **Figure 3**. Note the extensive axonal loss with demyelination and reactive astrocytosis as a replacement (**reddish area** in lower left) compared with "normal" myelinated axons (**blue area** in upper right). (Horizontal bar = 50 μ m, Luxol fast blue/hematoxylin-eosin)

DM = degenerative myelopathy

Table 1. Diseases Affecting the Thoracolumbar* & Lumbar Enlargement† Segments in Dogs

Hereditary/congenital	Congenital vertebral anomalies‡ Spina bifida Myelodysplasia Syringomyelia/hydromyelia Pilonidal sinus/epidermoid cyst/dermoid cyst Vertebral canal stenosis	Inflammatory/infectious	Diskospondylitis‡ Distemper myelitis Bacterial/fungal/rickettsial/protothecal myelitis Protozoal myelitis Spinal nematodiasis Granulomatous meningo-encephalomyelitis
Degenerative	Intervertebral disk disease type I/II‡ Degenerative myelopathy‡ Lumbosacral vertebral canal stenosis‡ Spondylosis deformans Synovial cyst	Neoplastic/traumatic/vascular	Neoplasia‡ Spinal cord trauma‡ Ischemic myelopathy‡ Progressive hemorrhagic myelomalacia Hemorrhage Vascular malformations & benign vascular tumors
		Idiopathic	Osteochondroma Spinal intraarachnoid cyst Calcinosis circumscripta

* T3–L3 spinal cord segments

† L3–caudal spinal cord segments

‡ Common cause

Table 2. Interpretation of DNA Testing for Degenerative Myelopathy

Normal (n/n)

- A dog with this result is homozygous n/n, with 2 normal copies of the gene.
- In 7 breeds studied in-depth at University of Missouri, dogs with this result were confirmed not to have DM.
- A dog with this result can transmit only a normal gene to its offspring; it is unlikely that this dog or its offspring will develop DM.

Carrier (a/n)*

- A dog with this result is heterozygous a/n, with 1 mutated copy of the gene and 1 normal copy of the gene, and is classified as a carrier.
- In 7 breeds studied at University of Missouri, dogs with this result were confirmed not to have DM.
- While it is highly unlikely a dog with this result will develop DM, this dog may transmit either the normal gene or the mutated gene to its offspring.

At risk (a/a)

- A dog with this result is homozygous a/a, with 2 mutated copies of the gene, and is at risk for developing DM.
- Research has shown that all dogs with confirmed DM have had a/a DNA test results; however, not all dogs testing as a/a have shown clinical signs of DM.

- DM typically is a late-onset disease, and dogs that tested as a/a and are clinically normal may still begin to show signs of the disease as they age. Some dogs testing as a/a did not begin to show clinical signs of DM until they were 14 years of age.
- Research is ongoing to estimate the percentage of dogs testing as a/a that will develop DM (caninegeneticdiseases.net).
- At this point, mutation may only be interpreted as being “at risk for developing DM within the animal’s life.”
- For dogs showing clinical signs with a presumptive diagnosis of DM, affected (a/a) test results may be used as an additional tool to aid in the antemortem diagnosis of DM.
- Dogs with this test result can only pass the mutated gene on to their offspring.

Note: Owners with dogs testing as carriers (a/n) or at risk (a/a) should be strongly encouraged to share these results with their veterinarians and to seek genetic counseling when making breeding decisions. The mutated allele appears to be very common in some breeds, and an overly aggressive breeding program to eliminate dogs testing as a/a or a/n might be devastating to the breed as a whole because it would eliminate many high-quality dogs that would otherwise contribute desirable qualities to the breed.

a/a = abnormal/abnormal, a/n = abnormal/normal, n/n = normal/normal

*Recent evidence suggests that these dogs are at “slight risk” for developing DM.



DID YOU ANSWER ...?



- **Both neurologic dysfunction and orthopedic disease are contributing factors to the clinical signs.** Based on the examination and laboratory findings, this dog has right stifle arthropathy. The history would suggest acute onset; however, examination confirmed neurologic dysfunction in both pelvic limbs (loss of patellar reflexes, absent proprioceptive positioning reactions).

Based on the history, the neurologic problem likely preceded the orthopedic problem and was more insidious in onset and progression. Concurrent orthopedic and neurologic disease frequently may confound interpretation of the neurologic examination.

- **Diagnostic differentials to consider** for right stifle arthropathy of acute onset include joint sprain or muscle strain, neoplasia, patellar luxation, cranial or caudal cruciate ligament injury, primary meniscal injury, long digital extensor tendon avulsion, primary or secondary arthritides, and immune-mediated arthritis.

Constructing a list of causes for the neurologic problems in this dog requires determination of a neuroanatomic localization. Essential considerations include whether the pelvic limbs are affected while thoracic limbs are normal and whether the patellar reflex is absent in both pelvic limbs (lower motor neuron [LMN] sign). Based on the finding of LMN signs in both pelvic limbs, the most likely location of this dog's neurologic problem is the lumbar enlargement of the spinal cord (ie, L3–caudal spinal cord segments). A peripheral neuromuscular disorder of the pelvic limbs is less likely. Other possible causes of myelopathy in this spinal cord region are summarized in **Table 1**.

Examination and laboratory findings are most consistent with a diagnosis of physical injury in the absence of ligamentous or meniscal injury. However, considering the chronicity of the problem, ligamentous or meniscal injury cannot be ruled out and may only be confirmed by visual inspection of the joint using arthroscopy or arthrotomy.

The “reactive” right popliteal lymph node remains on the problem list for this dog pending resolution or development of additional related clinical signs. Submission of the entire right popliteal lymph node for histopathologic analysis should be considered if lymphadenopathy persists or worsens.

- **What is the most likely cause of myelopathy?** Based on laboratory findings, the most likely diagnosis is DM. Chronic intervertebral disk protrusion is the major disorder to be excluded as a cause. While MRI does confirm the presence of multiple chronic intervertebral disk protrusions in this dog, there is no evidence of spinal cord compression in the region of the spinal cord that mediates the patellar reflex.

A diagnosis of DM is determined after making every reasonable effort to exclude the other most presumptive clinical diagnoses (ie, it is a “diagnosis of exclusion”).

- **Can genetic testing confirm a diagnosis of DM?** A DNA test for DM cannot confirm a diagnosis in this dog. The test, available through the Orthopedic Foundation for Animals (offa.org) in association with the Animal Molecular Genetic Diseases Laboratory of the University of Missouri (caninegeneticdiseases.net), can be useful as one of many factors in the planning of a balanced breeding program and is primarily designed for breeding purposes. A pet owner or veterinarian can order the test through the OFA and a kit will be sent for collection of DNA in the form of a cheek swab. Interpretation guidelines for this test are provided in **Table 2**. (Addendum: Serum was submitted for DNA testing for DM. Results confirmed that the dog was homozygous [a/a], with 2 mutated copies of the gene.)

For More Information...

on the Orthopedic Foundation for Animals, see **Canine Hip Dysplasia Part 1** by Dr. Wendy Baltzer in the October 2011 issue of *Clinician's Brief* at cliniciansbrief.com/journal

DM = degenerative myelopathy, LMN = lower motor neuron, MRI = magnetic resonance imaging, OFA = Orthopedic Foundation for Animals

See Aids & Resources, back page, for references & suggested reading.