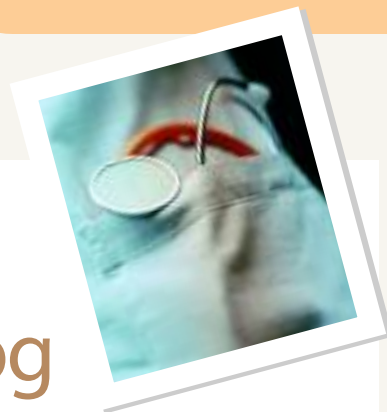



# Management of Shoulder Instability in the Dog

Derek B. Fox, DVM, PhD, Diplomate ACVS, University of Missouri—Columbia

## Profile

### DEFINITION

Shoulder instability can be defined as a compromise of any single component or combination of the stabilizing periarticular soft tissues of the shoulder with resulting excessive joint excursion or laxity.<sup>1</sup> The soft tissues most responsible for shoulder stability are the passive ligamentous structures, including the medial and lateral glenohumeral ligaments, the joint capsule, and the fibrocartilaginous labrum. Recent evidence has also revealed that the tendon of the biceps brachii contributes to passive shoulder stability.<sup>2</sup>

**Genetic Implications.** Although not positively linked to shoulder instability, DJD of the shoulder has been reported to have a higher-than-expected prevalence in dogs with concurrent hip dysplasia, thus implicating genetic factors.<sup>1</sup>

**Incidence/Prevalence/Geographic Distribution.** The incidence and the prevalence of shoulder instability have not been determined. The disease occurs globally and, according to some reports, may be the leading cause of shoulder pain.<sup>1,3</sup>

### SIGNALMENT

**Breed Predisposition.** Medium-sized and large breeds and athletic and hyperactive dogs are reported to be more frequently

affected.<sup>1,3</sup> Labrador retrievers have been implicated to be overrepresented; however, the frequency of their presentation with the disease may reflect breed popularity.

**Age and Range.** Dogs are diagnosed from 1.5 years to 13 years. Mean age of presentation is approximately 5 years.<sup>1,3</sup>

**Gender.** In the two largest studies evaluating shoulder instability in dogs, males were presented with the condition twice as frequently as females.<sup>1,3</sup>

### CAUSES/RISK FACTORS

Although definitive causes of shoulder instability have not been determined, trauma, glenoid malformations, high-demand repetitive use, aging, and concurrent hip dysplasia may be risk factors.

### PATHOPHYSIOLOGY

Depends on the initiating causes of the disease. However, joint incongruencies, repetitive microtrauma, and acute trauma can each stretch the passive restraints of the shoulder. Although these injuries may not necessarily result in catastrophic failure of any of the structures, they compromise functional integrity, allowing instability and DJD to ensue. The nature and direction of the instability are dictated by which shoulder stabilizers are affected. Medial instability is most frequently caused by pathologic conditions of the medial glenohumeral ligament, subscapularis tendon, and medial joint cap-

sule.<sup>3</sup> Although not completely understood at this time, nonuniform mechanoreceptor distribution within both medial and lateral glenohumeral ligaments and between normal and unstable joints may also play a role in the development of instability.<sup>4</sup>

### PAIN INDEX

Most dogs with instability have persistent forelimb lameness that does not entirely respond to NSAIDs. Approximately 10% of dogs are unable to bear weight on the affected side.<sup>1</sup>

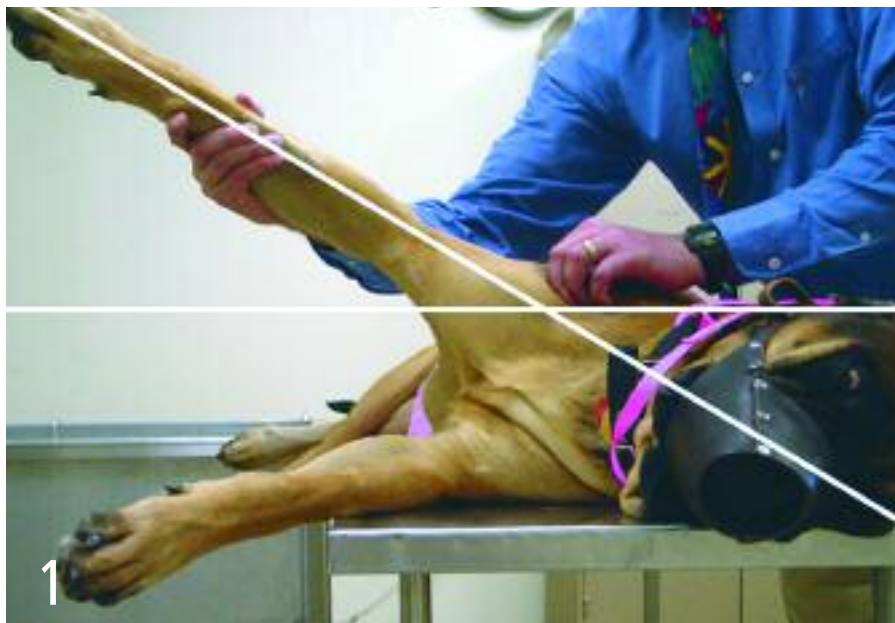## Diagnosis

### HISTORY/PHYSICAL EXAMINATION

The most consistent historical sign is persistent, unilateral, weight-bearing lameness. Orthopedic examination reveals spinatus muscle atrophy and pain on joint hyperextension and deep palpation of the biceps tendon. Other palpation findings can be specific to the direction of instability. By carefully noting the position of the acromion head with respect to the greater tubercle, shoulder "drawer" may be elicited, which can help the diagnostician determine whether the direction of the instability is medial, lateral, or multidirectional. An additional palpation maneuver (**Figure 1**) has been recently validated. It shows that medial shoulder instability results in more excessive angles of abduction (53°) than in unaffected shoulders (32°).<sup>5</sup>

DJD = degenerative joint disease; NSAIDs = nonsteroidal antiinflammatory drugs

continues



Shoulder abduction test. White lines represent the angles of humerus and scapula as they intersect during maximal abduction. Clinically, this angle should be measured with a goniometer and compared with the opposite side for reference. Courtesy Dr. James Cook

## DEFINITIVE DIAGNOSIS

Radiographs of the elbow and shoulder are recommended to rule out other sources of forelimb lameness, although their diagnostic utility for instability is limited. Pain elicited on biceps brachii palpation may warrant ultrasonographic evaluation of the tendon; however, biceps pain may be more indicative of shoulder laxity than tenosynovitis.<sup>1</sup> Neurologic causes of pain, atrophy, and disuse can be diagnosed with CT, MRI, and EMG. Instability is diagnosed presumptively on palpation and definitively on arthroscopic examination.

## DIFFERENTIAL DIAGNOSIS

Differential diagnoses include trauma, osteochondrosis, osteoarthritis, infraspinatus contracture, biceps brachii tenosynovitis, calcification of the supraspinatus, suppurative arthropathies, neoplasia, cervical intervertebral disk disease, and brachial plexus injuries or neoplasia.

## LABORATORY FINDINGS/IMAGING

The severity and extent of the pathologic condition varies based on the type, severity, and chronicity of the disease process. Arthroscopy routinely reveals some combination of synovitis, articular cartilage wear or erosion on the humeral head or glenoid cavity; osteophytosis; tearing or thickening of the glenohumeral ligaments; tearing of the labrum; distention and tearing of the joint capsule; and inflammation and tearing of the biceps tendon and subscapularis tendon (**Figure 2**). Between 9% and 57% of cases have signs of DJD, and 16% have calcification of the supraspinatus tendon on radiographs.<sup>1,3</sup>



## Treatment

Depending on the severity of the condition, treatment, and clinician preference, either inpatient or outpatient care may be instituted.

## ACTIVITY

After conservative or surgical care, a period of activity restriction (4 to 6 weeks) should be initiated to allow the damaged soft tissues to heal through fibroplasia. Most surgeons advocate placing the limb in a Velpeau sling for this period, with weekly removal, replacement, and range-of-motion exercises.

## CLIENT EDUCATION

A comprehensive preoperative discussion is essential to ensure that the owners understand the diagnosis, treatment options, risk for complications, expense, required after-care, and prognosis. As with most surgical conditions, success after treatment is largely contingent on owner compliance.

## SURGERY

Surgical options can be divided into extracapsular and intracapsular techniques. Extracapsular methods are completed through full approaches to the shoulder and involve capsulorrhaphy and imbrication, glenohumeral ligament reconstruction, prosthetic ligament replacement, and myotendinous (biceps, deep pectoral) transpositions. One study suggests that prosthetic glenohumeral ligaments are more effective than biceps tendon transpositions in maintaining the normal range of motion and instant center of motion of the joint.<sup>6</sup> Intracapsular techniques can be completed in closed fashion with arthroscopy and include radiofrequency-induced thermal capsulorrhaphy,<sup>3</sup> capsular imbrication, and glenohumeral ligament repair. These intracapsular, closed procedures require specific instrument sets and advanced technical expertise.

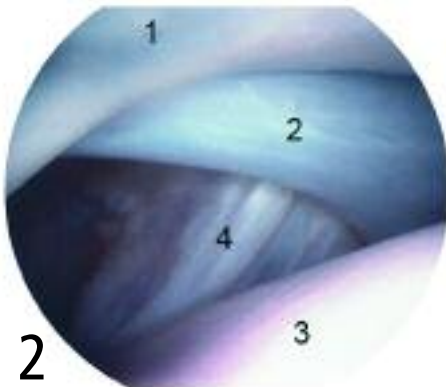
## MEDICATIONS

Appropriate postoperative analgesia is recommended. The type of analgesia used is dependent on the procedure and the level

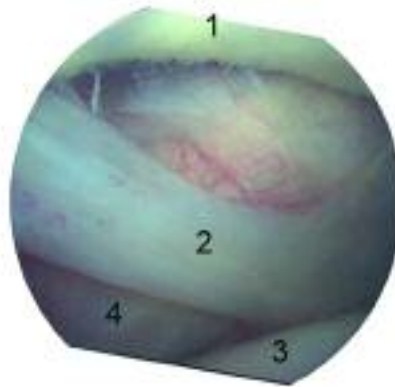
CT = computed tomography; DJD = degenerative joint disease; EMG = electromyography; MRI = magnetic resonance imaging; NSAIDs = nonsteroidal antiinflammatory drugs

## Medial Compartment of Shoulder Joint

NORMAL



UNSTABLE



Normal: 1 = glenoid, 2 = medial glenohumeral ligament, 3 = humeral head, 4 = subscapularis tendon. Unstable: 1 = fibrillated cartilage of glenoid; 2 = deformed, loose, and torn medial glenohumeral ligament; 3 = humeral head; 4 = stretched subscapularis tendon. Note the wider distance between humeral head and glenoid in unstable compared with normal joint. Courtesy Dr. James Cook

of patient discomfort. Most dogs are discharged with several weeks of NSAID therapy to treat the inflammation and pain associated with the condition and surgery.

### ALTERNATIVE THERAPY

If surgery is prohibited by cost or contraindicated because of the general health of the patient or other reasons, conservative management can be attempted. Success has been reported with a single intraarticular injection of methylprednisolone and strict cage confinement for 6 to 8 weeks.<sup>7</sup> This treatment is likely to work only if the damage to the passive shoulder stabilizers is not extensive. The use of nutraceuticals and physical therapy may also have some benefit if damage to the stabilizers is, again, not too extensive.



### Follow-Up

#### PATIENT MONITORING

Regardless of the type of therapy, patients should be followed closely to determine the success of treatment. A Velpeau sling requires careful monitoring and should be

changed weekly with concurrent completion of carpal and elbow range-of-motion exercises and close examination for bandage sores.

### COMPLICATIONS

Most commonly, complications involve inefficacy and recurrence, but they vary according to the treatment.<sup>3</sup> Axillary neuropathy has been reported as a complication of radiofrequency-induced thermal capsulorraphy in humans, and although it has not positively been linked with the therapy in a series of dogs, it was reported to occur in one dog.<sup>3</sup> Complications were considered higher in bilaterally affected cases.<sup>3</sup> Potential complications associated with application of a Velpeau sling can be severe and include foot swelling, dermatitis, joint stiffness, and bandage sores. Again, careful monitoring and regular bandage changes are essential to preclude most complications. Less severe side effects typically resolve after sling removal.

#### AT-HOME TREATMENT/ FUTURE FOLLOW-UP

Monitoring the permissible activity at the appropriate postoperative stage is the most critical aspect of at-home care. Initially, dogs

must be cage-confined for 4 weeks. After removal of the sling, they are typically allowed short periods of controlled activity for 4 to 6 weeks and performance of passive range-of-motion exercises. A reexamination should be scheduled to determine whether the next phase of rehabilitation can be initiated; this phase involves a slow return to normal function over a 6- to 8-week period and may be accomplished either through increasing frequency or duration of low-impact activities.



### In General

#### RELATIVE COST

Surgical treatment of a single joint and subsequent hospitalization and care typically costs around \$1500. However, frequent bandage changes and reexaminations are necessary and can cost between \$20 and \$100 apiece.

#### PROGNOSIS

Prognosis may depend on the general health of the patient, including age, body condition score, and concurrent orthopedic diseases, as well as owner compliance. Large studies evaluating the long-term outcome with treatment are limited to a single report that determined that the percentage of cases that were clinically improved at least 1 year after radiofrequency-induced thermal capsulorraphy was 93%, with 79% considered excellent.<sup>3</sup>

#### FUTURE CONSIDERATIONS

Ongoing studies on the pathophysiology and long-term success with other treatment methods will probably contribute to improving the future treatment of this condition. ■

See Aids & Resources, back page, for references, contacts, and appendices.