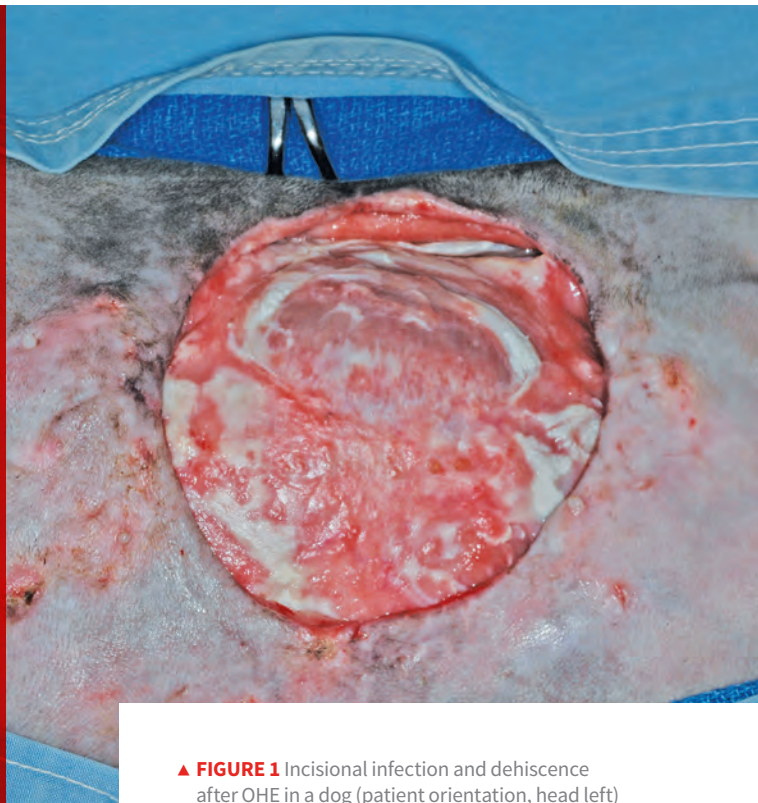

Top 5 Complications of Gonadectomy

Karen M. Tobias, DVM, MS, DACVS
University of Tennessee



▲ **FIGURE 1** Incisional infection and dehiscence after OHE in a dog (patient orientation, head left)

Gonadectomy (ie, ovariectomy [OHE] or neutering) is one of the most commonly performed veterinary surgical procedures.¹⁻⁶ Gonadectomy reduces pet overpopulation and euthanasia in animal shelters and decreases the risk for gonadal tumors, mammary neoplasia and pyometra in dams and queens, and perianal adenomas and benign prostatic hyperplasia in male dogs.⁷ It may also increase longevity and reduce hormonally driven behavior.⁷

Although gonadectomy is considered a routine procedure, complications can arise. Following are 5 of the most common complications of gonadectomy according to the author.

1 **Incisional Complications**
Incisional inflammation is an expected effect of any surgery and typically resolves without treatment⁸; incisional complications, however, occur less frequently¹

and are likely underreported, as clinicians may not closely evaluate the incision line after anesthetic recovery or may not record findings they consider expected, minor, or self-limiting. Incisional complications associated with gonadectomy can include incisional and/or scrotal swelling, pain, redness, seromas, hernias, peri-incisional dermatitis, and skin bruising and generally occur more frequently in dogs >50 lb (22.7 kg) and in cats.^{4,9-11}

TOP 5 COMPLICATIONS OF GONADECTOMY

1. Incisional Complications
2. Intra-Abdominal Hemorrhage
3. Postoperative Pain
4. Surgical Errors
5. Hormonal Changes

OHE = ovariectomy

Incision location may affect complication rates. For example, in a study of kittens undergoing OHE, incisional complications occurred more commonly with a midline approach as compared with a flank approach.¹² In a study of dogs, pre-scrotal neuters resulted in a higher rate of self-trauma than did scrotal neuters,¹¹ which may be attributed to scrotal neuters being performed without suture closure, thus lessening the amount of tissue handling.^{10,11}

Surgical-site infections and other serious wound complications that are suggestive of infection (eg, wound pain and swelling, dehiscence, drainage; *Figure 1*) have been reported in 0.1% to 3% of elective gonadectomies.^{1,2,4,13} This rate is similar to the infection rates reported for clean, elective procedures in general (2.3%-5.7%).¹⁴ Infection rates can be reduced by decreasing surgery duration and using appropriate surgical technique (eg, gentle tissue handling, closure of dead space).^{14,15}

2 Intra-Abdominal Hemorrhage
Intraoperative hemorrhage is noted in 1.1% to 11% of dogs and cats undergoing gonadectomy and is most common in dogs >50 lb (22.7 kg) or when the surgery is performed by students.^{1,4,16} Postoperative abdominal hemorrhage is noted in ≤2.8% of patients undergoing gonadectomy.⁴ Rough tissue handling, poor ligation technique, inexperience, and inadequate exposure may play a role in intra-abdominal hemorrhage. Cats undergoing gonadectomy are less likely to experience intra-abdominal hemorrhage than are dogs, even if ligatures are not used for ovarian pedicle hemostasis, as feline ovarian pedicles are generally small, less vascular, and more mobile as compared with canine ovarian pedicles. In a study of 2136 cats undergoing pedicle tie OHE, 0.28% of cats experienced intra-abdominal hemorrhage¹⁷; most cases were recognized and corrected during the procedure. In that study, uterine pedicle hemorrhage was noted in 0.14% of cats, and suspensory ligament hemorrhage was noted in 0.05% of cats.

Another source of intra-abdominal hemorrhage is

splenic laceration, which can be caused by laparoscopic equipment or excessive spay hook use.¹⁸

Fatal abdominal hemorrhage from OHE or ovariectomy is rare, as most hemorrhaging is noted and addressed prior to closure.^{1,4,16,17} Patients with significant postoperative hemorrhage may have nonspecific signs (eg, slow anesthetic recovery, tachycardia, hypothermia, pale mucous membranes). Diagnosis is made via abdominal ultrasonography and abdominocentesis. In clinics without ultrasonography equipment, 4-quadrant abdominocentesis can be performed if the falciform ligament, which will block the needle, and spleen are avoided. Nonclotting blood on abdominocentesis confirms the diagnosis of hemoabdomen.¹⁹ If significant abdominal hemorrhage is detected, coagulation tests should be considered. The clinician must decide whether to treat the patient conservatively (eg, abdominal bandaging, sedation, monitoring, judicious use of fluids) or perform exploratory surgery. If surgery is chosen, the incision should be extended to provide adequate exposure, and the ovarian pedicles, suspensory ligaments, uterine stump, and other organs should be closely evaluated. If bleeding is identified, the tissue in question should be gently elevated from underlying structures with thumb forceps before the vessels are clamped and ligated. Transected ovarian pedicles commonly retract caudomedial to the kidneys and may rest immediately over the ureters. In cats, the distal ureters lie close to the uterine stump. Regardless of location,

Rough tissue handling, poor ligation technique, inexperience, and inadequate exposure may play a role in intra-abdominal hemorrhage.

the ureters can be inadvertently ligated. If no active hemorrhage is observed during surgery, all pedicles should be ligated again, as anesthetic hypotension may mask vessel leakage.

Serious hemorrhage from gonadectomy is rare, but bleeding can occur from the incision or, in dogs undergoing prescrotal neutering, in the scrotum. In one study of scrotal and prescrotal neutering in 437 dogs >6 months of age, hemorrhage was observed in 16% of all dogs.¹¹ Bleeding occurred more commonly in larger dogs, and surgical approach was not a factor in its occurrence.¹¹ In another study of scrotal neutering with sutureless pedicle ties in dogs <6 months of age, no postoperative hemorrhage was noted.¹⁰ Hemorrhage after neutering is often related to bleeding from the tunics or SC tissue and is usually self-limiting.¹⁴ Affected patients can be treated with local pressure (dogs, scrotum; cats, scrotum or inguinal ring), cold packs, sedation, and exercise restriction and monitored for significant changes in hematocrit. Dogs with severe scrotal hematomas may develop abscessation or scrotal necrosis necessitating scrotal ablation. In rare cases, testicular vessels can retract through the inguinal ring into the peritoneal cavity, resulting in intra-abdominal hemorrhage. In these patients, clinical signs and treatment are similar to those in patients with postoperative hemorrhage after OHE.

3 Postoperative Pain

Some clinicians consider postoperative pain a normal effect of surgery. In one study, ≤12% of clinicians did not administer any postoperative analgesics to their patients, and many others relied on butorphanol, which may provide insufficient analgesia.³ Most retrospective studies of elective gonadectomy do not list pain as a potential surgical complication, and dogs undergoing routine gonadectomy are less likely to be prescribed postoperative analgesics than those undergoing other surgeries.^{1,2,9,12,20}

OHE = ovariectomy
ORS = ovarian remnant syndrome

Inadequate treatment of postoperative pain may be due to generational or gender differences among clinicians, cost or regulatory concerns, lack of access to appropriate drugs, and/or insufficient knowledge of pharmacology or pain detection in various species. For example, pain in cats tends to be undertreated because cats rarely show signs of pain after elective procedures.²¹ However, when mechanical nociceptor threshold (scrotal pressure tolerance) was measured in a study of cats after neutering, cats often reacted for ≥8 hours after surgery.²¹ In another study, cats exhibited decreased tolerance to abdominal palpation 18 hours after OHE but appeared pain free on visual assessment.²²

Prolonged pain has also been noted in gonadectomized dogs. In one study, abdominal palpation and pain scores had not returned to normal by 72 hours after OHE.⁸ In another study, when pain was closely monitored after neutering, ≈50% of dogs required rescue analgesia within 3 to 4 hours of receiving preoperative morphine.²³ Owners may note patient discomfort in dogs in the form of lethargy, restlessness, vocalization, and/or decreased appetite 1 to 3 days after gonadectomy.^{20,24}

Clinicians should consider pre-emptive analgesics (eg, local or regional nerve blocks) and administer rescue opioids while the patient is being monitored in the clinical setting.^{3,25} Analgesics should also be prescribed for several days after the procedure.

4 Surgical Errors

Reported surgical errors include incomplete ovariectomy, pedicle granulomas and fistulas from use of nonabsorbable multifilament suture or nylon cable ties, inadvertent ureteral ligation, incisional hernias, retained surgical sponges or other foreign bodies (ie, gossypibomas), and inadvertent prostatectomy during cryptorchidectomy.^{1,14} The author has also seen uterine horns inadvertently tied together around the colon or urethra, resulting in stricture or obstruction. The exact incidence of surgical errors during elective gonadectomy is unknown. As with intra-abdominal

hemorrhage, surgical errors can occur from inexperience or lack of sufficient anatomic exposure.

Ovarian remnant syndrome (ORS) occurs when functional ovarian tissue is inadvertently left in the patient (**Figure 2**).¹⁴ Patients with ovarian remnants are often overweight or have been spayed through a small incision, both of which can interfere with ovary visualization and appropriate clamp or ligature placement.¹ Affected patients may display signs of estrus (eg, mammary or vulvar enlargement, behavior changes, vulvar discharge) or become clinically ill due to stump pyometra. Diagnosis of ORS is based on elevated concentrations of anti-Müllerian hormone and progesterone in peripheral blood.²⁶ Treatment includes exploratory celiotomy, ovariectomy, and/or, if stump pyometra is present, removal of the uterus. Retained ovarian remnants are easier to locate when the patient is showing signs of estrus, as associated vessels will be enlarged and cystic follicles may be present in retained tissue.¹⁴

Inadvertent prostatectomy during removal of a cryptorchid testicle can also result from inadequate exposure, in which the clinician incorrectly identifies the almond-shaped prostate as a retained intra-abdominal testicle without noting the attached bladder and urethra. The author has witnessed students inadvertently expose the prostate through an abdominal incision when using a spay hook in attempt to locate a retained testicle. Dogs that have undergone inadvertent prostatectomy will have azotemia and anuria from urethral transection and ligation; subsequent bladder necrosis from overdistension can result in uroabdomen. Some dogs will regain urinary continence with surgical reanastomosis of the urethra.²⁷

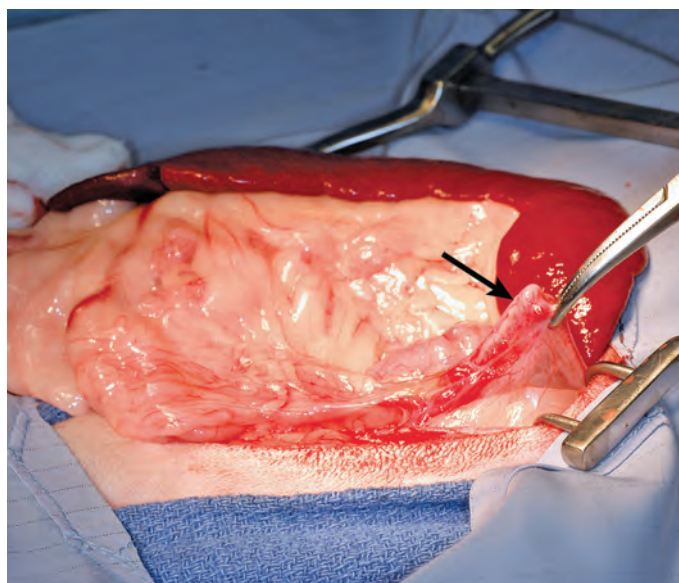
Retained surgical sponges can become walled off and cause no clinical signs for years; alternatively, affected patients may develop clinical signs as a result of adhesions, mass effect, fistulas or sinus tracts, vessel or visceral erosion, infection, or neoplastic transformation.^{28,29} Diagnosis can be difficult if a radiopaque marker is not present in

the sponge, although the mass is usually evident on ultrasonography or CT. Treatment entails surgical removal of the sponge, in which careful dissection is required to prevent damage to local structures.²⁹ Institution of sponge counts before and after each abdominal surgery can help decrease the risk for gossypibomas.

Ventral midline hernias occur in <1% of patients undergoing OHE.^{1,2,13,14} If the hernia is present within the first week after surgery, it is likely the result of technical error (eg, missed external rectus fascia, inappropriate suture size, suture bites that are too small or too far apart, knot failure).^{1,14}

5 Hormonal Changes

Gonadectomy is common in the United States due to its value in surgical sterilization and preventing or reducing reproductive diseases (eg, benign prostatic hyperplasia, testicular tumors, pyometra, mammary neoplasia) and sexually driven behaviors.⁷ Adoption rates of shelter dogs are often increased with preadoption gonadectomy; however, evidence of its potential negative effects has been accumulating.^{7,30-40}



▲ **FIGURE 2** Retained left ovary (**arrow**) in a cat with behavioral signs of estrus 6 months after OHE (patient orientation, head right)

Gonadectomy has been correlated with obesity in dogs and cats,³⁰⁻³² which may result from changes in fasting metabolic rate (as has been noted in female cats), increased food intake, and/or decreased activity.^{31,32} Obesity may increase the risk for or exacerbate osteoarthritis and/or other systemic illnesses. Owners should be instructed on how to adjust activity levels and food intake to maintain their pet's ideal body condition.

Another condition associated with neuter status is urinary incontinence in female dogs.³³ Urinary incontinence is rare in intact bitches (0%-1%) but reportedly occurs in 5% to 20% of spayed female dogs.^{7,33,39,40} The risk appears to be greatest in dogs >33 lb (15 kg).⁴⁰ Some studies have reported correlations with the dog's age at the time of OHE, whereas others have found no significant effects.³⁹⁻⁴¹ Signs of urinary incontinence can manifest as early as 4 weeks postoperation or may be delayed for 3 to 10 years.^{24,33} The pathophysiology of this acquired sphincter mechanism incompetence is unclear. Small-breed female dogs may have a greater risk for pyometra and mammary tumors than urinary incontinence; thus, the benefits of OHE before the first or second heat may outweigh the likelihood of complications.

Large- and giant-breed dogs, particularly golden retrievers, German shepherd dogs, and rottweilers, may be at greater risk for morbidity and mor-

tality from joint disease, neoplasia, and urinary incontinence resulting from gonadectomy at a young age. Gonadectomy has been shown to increase the incidence of joint disorders in large-breed dogs by 2 to 5 times that of intact dogs, especially when performed in dogs <6 months of age.^{7,34,35} For example, in one study, the incidence of joint disorders was 5% in intact adult male golden retrievers as compared with 27% in those neutered before 6 months of age.³⁴ In another study, joint disorders were diagnosed in 21% and 16% of male and female German shepherd dogs, respectively, gonadectomized at <1 year of age as compared with 7% and 5% of intact male and female German shepherd dogs, respectively.³⁵

Gonadectomy may also be associated with an increased risk for certain cancers in large-breed dogs, although controlled studies are lacking. In one study of 683 rottweilers, bone sarcoma was diagnosed in 12.6% of dogs³⁶; the risk for development of bone sarcomas was >3 times greater in dogs gonadectomized before 1 year of age. In other breeds, cancer-related deaths may be increased because gonadectomized animals live longer.⁷ Delaying gonadectomy until physical maturity (eg, >12 months of age) may be beneficial for large-breed dogs, although delaying surgery increases the risk for wound complications and surgical errors, likelihood of greater costs due to increased surgical time and anesthesia, and potential for unwanted litters before sterilization.

Because cats do not appear to experience many long-term ill effects from gonadectomy, other than the potential for obesity, prepubertal gonadectomy is usually considered acceptable for this species.³⁷ However, gonadectomy in animals <7 months of age will delay physeal closure, which could increase the risk for physeal fractures in male cats, particularly if they become obese.⁴²

Clinicians must weigh the risks and benefits of gonadectomy with the pet owner and determine the most appropriate age to neuter different breeds and species. ■

Gonadectomy has been shown to increase the incidence of joint disorders in large-breed dogs by 2 to 5 times that of intact dogs.

OHE = ovariectomy

WHEN IT COMES TO SELLING YOUR PRACTICE, GETTING THE BEST PRICE IS JUST THE FIRST STEP.

References

1. Muraro L, White RS. Complications of ovariectomy procedures performed in 1880 dogs. *Tierarztl Prax Ausg K Kleintiere Heimtiere*. 2014;42(5):297-302.
2. Pollari FL, Bonnett BN, Bamsey SC, Meek AH, Allen DG. Postoperative complications of elective surgeries in dogs and cats determined by examining electronic and paper medical records. *J Am Vet Med Assoc*. 1996;208(11):1882-1886.
3. Hewson CJ, Dohoo IR, Lemke KA. Perioperative use of analgesics in dogs and cats by Canadian veterinarians in 2001. *Can Vet J*. 2006;47(4):352-359.
4. Berzon JL. Complications of elective ovariectomies in the dog and cat at a teaching institution: clinical review of 853 cases. *Vet Surg*. 1979;8(3):89-91.
5. Warne LN, Robertson ID. A survey of veterinary consultations in Perth. *Aust Vet Pract*. 2003;33(1):33-36.
6. Wagner AE, Hellyer PW. Survey of anesthesia techniques and concerns in private veterinary practice. *J Am Vet Med Assoc*. 2000;217(11):1652-1657.
7. Howe LM. Current perspectives on the optimal age to spay/castrate dogs and cats. *Vet Med (Auckl)*. 2015;6:171-180.
8. Hancock RB, Lanz OI, Waldron DR, Duncan RB, Broadstone RV, Hendrix PK. Comparison of postoperative pain after ovariectomy by harmonic scalpel-assisted laparoscopy compared with median celiotomy and ligation in dogs. *Vet Surg*. 2005;34(3):273-282.
9. Snell WL, Orsher RJ, Larenza-Menzies MP, Popovitch CA. Comparison of caudal and pre-scrotal castration for management of perineal hernia in dogs between 2004 and 2014. *N Z Vet J*. 2015;63(5):272-275.
10. Miller KP, Rekers WL, DeTar LG, Blanchette JM, Milovancev M. Evaluation of sutureless scrotal castration for pediatric and juvenile dogs. *J Am Vet Med Assoc*. 2018;253(12):1589-1593.
11. Woodruff K, Rigdon-Brestle K, Bushby PA, Willits R, Huston C. Scrotal castration versus prescrotal castration in dogs. DVM360 website. <http://veterinarymedicine.dvm360.com/scrotal-castration-versus-prescrotal-castration-dogs>. Published May 2015. Accessed December 4, 2019.
12. Roberts ML, Beatty JA, Dhand NK, Barrs VR. Effect of age and surgical approach on perioperative wound complication following ovariectomy in shelter-housed cats in Australia. *JFMS Open Rep*. 2015;1(2):2055116915613358.
13. Kreisler RE, Shaver SL, Holmes JH. Outcomes of elective gonadectomy procedures performed on dogs and cats by veterinary students and shelter veterinarians in a shelter environment. *J Am Vet Med Assoc*. 2018;253(10):1294-1299.
14. Adin CA. Complications of ovariectomy and orchietomy in companion animals. *Vet Clin North Am Small Anim Pract*. 2011;41(5):1023-1039.
15. Travis BM, Hayes GM, Vissio K, Harvey HJ, Flanders JA, Sumner JP. A quilting subcutaneous suture pattern to reduce seroma formation and pain 24 hours after midline celiotomy in dogs: a randomized controlled trial. *Vet Surg*. 2018;47(2):204-211.
16. Burrow R, Batchelor D, Cripps P. Complications observed during and after ovariectomy of 142 bitches at a veterinary teaching hospital. *Vet Rec*. 2005;157(26):829-833.
17. Miller KP, Rekers W, Ellis K, Ellingsen K, Milovancev M. Pedicle ties provide a rapid and safe method for feline ovariectomy. *J Feline Med Surg*. 2016;18(2):160-164.
18. Corriveau KM, Giuffrida MA, Mayhew PD, Runge JJ. Outcome of laparoscopic ovariectomy and laparoscopic-assisted ovariectomy in dogs: 278 cases (2003-2013). *J Am Vet Med Assoc*. 2017;251(4):443-450.
19. Herold LV, Devey JJ, Kirby R. Clinical evaluation and management of hemoperitoneum in dogs. *J Vet Emerg Crit Care*. 2008;18(1):40-53.
20. Wagner AE, Worland GA, Glawe JC, Hellyer PW. Multicenter, randomized controlled trial of pain-related behaviors following routine neutering in dogs. *J Am Vet Med Assoc*. 2008;233(1):109-115.

Continues ▶



PROTECTING YOUR LEGACY SHOULD GUIDE THE JOURNEY.

Your practice is worth more than just a building with equipment. Its value includes your dedicated team, carefully crafted culture, and personal commitment to pets and their families.

That is why we approach selling your practice with the goal of ensuring you receive maximum return and that your legacy continues.

Whether you're considering a private or corporate sale, partner with the experts to navigate the process.

SIMMONS
Veterinary Practice Sales & Appraisals

42 Years | 3,200 Sales Transactions | 12,000 Practices Appraised

Call us today at **800.333.1984** for a complimentary and confidential conversation.

21. Slingsby LS, Jones A, Waterman-Pearson AE. Use of a new finger-mounted device to compare mechanical nociceptive thresholds in cats given pethidine or no medication after castration. *Res Vet Sci.* 2001;70(3):243-246.
22. Slingsby LS, Waterman-Pearson AE. Postoperative analgesia in the cat after ovariectomy by use of carprofen, ketoprofen, meloxicam or tolfenamic acid. *J Small Anim Pract.* 2000;41(10):447-450.
23. Huuskonen V, Hughes JML, Estaca Bañon E, West E. Intratesticular lidocaine reduces the response to surgical castration in dogs. *Vet Anaesth Analg.* 2013;40(1):74-82.
24. Binder C, Katić N, Aurich JE, Dupré G. Postoperative complications and owner assessment of single portal laparoscopic ovariectomy in dogs. *Vet Rec.* 2018;183(24):745.
25. Quarterone C, Luna SPL, Crosignani N, et al. Ovariectomy requires more post-operative analgesia than orchietomy in dogs and cats. *Can Vet J.* 2017;58(11):1191-1194.
26. Cornell University College of Veterinary Medicine Animal Health Diagnostic Center. Canine reproductive function tests. Cornell University website. <https://www.vet.cornell.edu/animal-health-diagnostic-center/testing/protocols/canine-reproductive-tests>. Accessed December 4, 2019.
27. Schulz KS, Waldron DR, Smith MM, Henderson RA, Howe LM. Inadvertent prostatectomy as a complication of cryptorchidectomy in four dogs. *J Am Anim Hosp Assoc.* 1996;32(3):211-214.
28. Zeltman P, Downs MO. Surgical sponges in small animal surgery. *Compend Contin Educ Vet.* 2011;33(6):E5.
29. Papazoglou LG, Tsioli V, Patsikas VT, Kazakos GM. Retained surgical sponges. *Compend Contin Educ Pract Vet.* 2004;26(8):634-644.
30. Goh CSS. Age of neutering in large- & giant-breed dogs. *Clinician's Brief.* 2016;14(8):18-23.
31. Fettman MJ, Stanton CA, Banks LL, et al. Effects of neutering on bodyweight, metabolic rate and glucose tolerance of domestic cats. *Res Vet Sci.* 1997;62(2):131-136.
32. Birmingham EN, Thomas DG, Cave NJ, Morris PJ, Butterwick RF, German AJ. Energy requirements of adult dogs: a meta-analysis. *PLoS One.* 2014;9(10):e109681.
33. Arnold S, Hubler M, Reichler I. Urinary incontinence in spayed bitches: new insights into the pathophysiology and options for medical treatment. *Reprod Dom Anim.* 2009;44(Suppl 2):190-192.
34. Hart BL, Hart LA, Thigpen AP, Willits NH. Long-term health effects of neutering dogs: comparison of Labrador retrievers with golden retrievers. *PLoS One.* 2014;9(7):e102241.
35. Hart BL, Hart LA, Thigpen AP, Willits NH. Neutering of German shepherd dogs: associated joint disorders, cancers and urinary incontinence. *Vet Med Sci.* 2016;2(3):191-199.
36. Cooley DM, Beranek BC, Schlittle DL, Glickman NW, Glickman LT, Waters DJ. Endogenous gonadal hormone exposure and bone sarcoma risk. *Cancer Epidemiol Biomark Prev.* 2002;11(11):1434-1440.
37. Porters N, Polis I, Moons CPH, et al. Relationship between age at gonadectomy and health problems in kittens adopted from shelters. *Vet Rec.* 2015;176(22):572.
38. Clevenger J, Kass PH. Determinants of adoption and euthanasia of shelter dogs spayed or neutered in the university of California veterinary student surgery program compared to other shelter dogs. *J Vet Med Educ.* 2003;30(4):372-378.
39. Beauvais W, Cardwell JM, Brodbelt DC. The effect of neutering on the risk of urinary incontinence in bitches – a systematic review. *J Small Anim Pract.* 2012;53(4):198-204.
40. Forsee KM, Davis GJ, Mouat EE, Salmeri KR, Bastian RP. Evaluation of the prevalence of urinary incontinence in spayed female dogs: 566 cases (2003-2008). *J Am Vet Med Assoc.* 2013;242(7):959-962.
41. Spain CV, Scarlett JM, Houpt KA. Long-term risks and benefits of early-age gonadectomy in dogs. *J Am Vet Med Assoc.* 2004;224(3):380-387.
42. McNicholas WT, Wilkens BE, Blevins WE, et al. Spontaneous femoral capital physal fractures in adult cats: 26 cases (1996-2001). *J Am Vet Med Assoc.* 2002;221(12):1731-1736.

Mirataz™ (mirtazapine transdermal ointment)

For topical application in cats only. Not for oral or ophthalmic use.

CAUTION: Federal law (USA) restricts this drug to use by or on the order of a licensed veterinarian.

Before using this product, please consult the product insert, a summary of which follows:

INDICATION: Mirataz™ is indicated for the management of weight loss in cats.

DOSAGE AND ADMINISTRATION: Administer topically by applying a 1.5-inch ribbon of ointment (approximately 2 mg/cat) on the inner pinna of the cat's ear once daily for 14 days. Wear disposable gloves when applying Mirataz™. Alternate the daily application of Mirataz™ between the left and right inner pinna of the ears. **See Product Insert for complete dosing and administration information.**

CONTRAINDICATIONS: Mirataz™ is contraindicated in cats with a known hypersensitivity to mirtazapine or to any of the excipients. Mirataz™ should not be given in combination, or within 14 days before or after treatment with a monoamine oxidase inhibitor (MAOI) [e.g. selegiline hydrochloride (L-deprenyl), amitraz], as there may be an increased risk of serotonin syndrome.

HUMAN WARNINGS: Not for human use. Keep out of reach of children. **Wear disposable gloves when handling or applying Mirataz™ to prevent accidental topical exposure.** After application, dispose of used gloves and wash hands with soap and water. After application, care should be taken that people or other animals in the household do not come in contact with the treated cat for 2 hours because mirtazapine can be absorbed transdermally and orally. However, negligible residues are present at the application site and the body of the cat at 2 hours after dosing. In case of accidental skin exposure, wash thoroughly with soap and warm water. In case of accidental eye exposure, flush eyes with water. If skin or eye irritation occurs seek medical attention. In case of accidental ingestion, or if skin or eye irritation occurs, seek medical attention.

PRECAUTIONS: Do not administer orally or to the eye. Use with caution in cats with hepatic disease. Mirtazapine may cause elevated serum liver enzymes (See **Animal Safety** in the product insert). Use with caution in cats with kidney disease. Kidney disease may cause reduced clearance of mirtazapine which may result in higher drug exposure. Upon discontinuation of Mirataz™, it is important to monitor the cat's food intake. Food intake may lessen after discontinuation of mirtazapine transdermal ointment. If food intake diminishes dramatically (>75%) for several days, or if the cat stops eating for more than 48 hours, reevaluate the cat. Mirataz™ has not been evaluated in cats < 2 kg or less than 6 months of age. The safe use of Mirataz™ has not been evaluated in cats that are intended for breeding, pregnant or lactating cats.

ADVERSE REACTIONS: In a randomized, double-masked, vehicle-controlled field study to assess the effectiveness and safety of mirtazapine for the management of weight loss in cats, 115 cats treated with Mirataz™ and 115 cats treated with vehicle control were evaluated for safety. The vehicle control was an ointment containing the same inert ingredients as Mirataz™ without mirtazapine. The most common adverse reactions included application site reactions, behavioral abnormalities (vocalization and hyperactivity), and vomiting. **See Product Insert for complete Adverse Reaction information.** To report suspected adverse events, for technical assistance or to obtain a copy of the SDS, contact Kindred Biosciences, Inc. at 888-608-2542. For additional information about adverse drug experience reporting for animal drugs, contact FDA at 1-888-FDA-VETS or online at <http://www.fda.gov/AnimalVeterinary/SafetyHealth>.

EFFECTIVENESS: The effectiveness of Mirataz™ (mirtazapine transdermal ointment) was demonstrated in a randomized, double-masked, vehicle-controlled, multi-site field study involving client-owned cats of various breeds. Enrolled cats were ≥ 1 year of age and had existing documented medical history of ≥ 5% weight loss deemed clinically significant. The most common pre-existing conditions included renal insufficiency, vomiting, and hyperthyroidism. Some cats had more than one pre-existing condition. Cats were randomized to treatment groups in a 1:1 ratio of Mirataz™ to vehicle control. A total of 230 cats were enrolled and received either Mirataz™ (115 cats) or a vehicle control (115 cats) containing the same inert ingredients without mirtazapine. The cats were 2.8-24.6 years of age and weighed 2.1-9.2 kg. The dosage was a 1.5-inch ribbon (approximately 2 mg/cat) mirtazapine or vehicle ointment administered topically to the inner pinna of the cat's ear. A total of 177 cats were determined to be eligible for the effectiveness analysis; 83 cats were in the Mirataz™ group and 94 cats were in the vehicle control group. The primary effectiveness endpoint was the mean percent change in body weight from Day 1 to the Week 2 Visit. At Week 2, the mean percent increase in body weight from Day 1 was 3.94% in the mirtazapine group and 0.41% in the vehicle control group. The difference between the two groups was significant (p<0.0001) based on a two-sample t-test assuming equal variances. A 95% confidence interval on the mean percent change in body weight for the Mirataz™ group is (2.77, 5.11), demonstrating that the mean percent change is statistically different from and greater than 0.

STORAGE: Store below 25°C (77°F). Multi-use tube. Discard within 30 days of first use.

HOW SUPPLIED: Mirataz™ is supplied in a 5 gram aluminum tube.

MANUFACTURED FOR:

Kindred Biosciences, Inc.
1555 Bayshore Highway, suite 200
Burlingame, CA 94010

NADA 141-481, Approved by FDA

Made in USA.
NDC 86078-686-01
REG-MTZBS-008 Rev. 26Apr2018

Mirataz™ is a trademark of Kindred Biosciences, Inc. ©2018 Kindred Biosciences, Inc. All rights reserved.