

Renal Amyloidosis in Shar-Peis and Other Breeds

Renal amyloidosis (RA) is generally idiopathic but can be associated with chronic inflammation, infection, or neoplasia. Familial amyloidosis has been described in the Chinese shar-pei (CSP) dog. Reactive amyloidosis in the dog is often associated with progressive chronic kidney disease (CKD) with primary glomerular involvement; however, in CSPs renal medullary lesions predominate. Extrarenal amyloid deposition has also been reported. Up to 23% of CSPs are affected by Familial Shar-Pei Fever (FSF), which may predispose CSPs to systemic reactive amyloidosis.

Records of 18 CSPs and 73 non-shar-pei (NSP) dogs with RA were evaluated. The study found that RA presents most commonly with clinical features of CKD in all dogs. A history of neoplastic, inflammatory, infectious or noninfectious disease

was present in 64% of all dogs. FSF was described in 44% of the CSPs. Clinical signs of nephrotic syndrome were found to be uncommon and recorded in only 10% of all dogs, all of which were NSPs. There was a high proportion of leukocytosis in the study (61%), likely associated with predisposing inflammatory and neoplastic disease and with the presence of FSF. CSPs developed RA at a relatively younger age when compared with NSPs and presented with more severe azotemia and milder proteinuria. Disseminated amyloidosis with glomerular involvement was more common in CSPs. Creatinine concentration was a prognostic indicator associated with death or euthanasia in both groups.

■ ■ Commentary

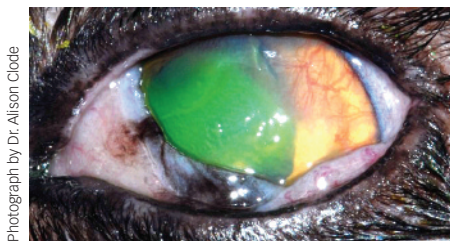
RA can be suspected based upon the presenting clinical features, but renal biopsies

are rarely performed. This study helps characterize differences between shar-pei and non-shar-pei dogs, which may help the practitioner when attempting to treat this potentially life-limiting disease. A specific interest in this study was the correlation between inflammation and the presence of disease, illustrating the need for more studies investigating the pathophysiology of RA and the role of inflammation in modulating the disease.—
Heather Troyer, DVM, DABVP, CVA

■ ■ Source

Renal amyloidosis in dogs: A retrospective study of 91 cases with comparison of the disease between shar-pei and non-shar-pei dogs. Segev G, Cowgill LD, Jessen S, et al. *J Vet Intern Med* 26:259-268, 2012.

Calicivirus & Ocular Lesions



Photograph by Dr. Alison Clode

Ocular lesions in association with upper respiratory tract disease (URTD) are globally recognized in cats. The major pathogens include feline herpes virus 1 (FHV-1), feline calicivirus (FCV), *Bordetella bronchiseptica*, *Chlamydomydia felis*, and *Mycoplasma felis* (to a lesser extent). One of the complications of URTD is feline ocular surface lesions, commonly caused by FHV-1. In this study, 99 cats with surface ocular infections and active or recent URTD underwent ocular examinations, clinical and ocular scorings, and samplings for RT-PCR for infectious agents. Cats were selected from shelters or private hospitals. An infectious agent was

isolated from 63/99 cats. In 40/63 cats, a single infectious agent was isolated: *Chlamydomydia spp* 16/63 (25%), FCV 11/63 (17%), FHV-1 8/63 (13%), and *Mycoplasma spp* 5/63 (8%). In the remaining 23/63 cats, multiple infectious agents were isolated, most commonly with some combination of FCV (19 isolates), FHV-1 (8 isolates), and *Mycoplasma spp* (16 isolates). FCV was isolated most frequently from shelter cats <2 months of age. In cats with FCV ocular lesions, key findings included erosive conjunctivitis. All cats with FCV had oral ulcers.

■ ■ Commentary

This study showed that FCV could be a more prevalent cause for shelter cats exhibiting URTD and conjunctivitis in Germany and the UK. An equal prevalence of FCV and FHV-1 was reported in shelter cats in the United States.¹ However, FHV-1 still remains the primary ocular

surface disease pathogen (herpetic keratoconjunctivitis) that general practitioners may see with or without URTD in US cat populations. Recognizing FCV as a more prevalent pathogen in shelter cats with URTD and conjunctivitis is helpful for improving shelter management, treatment/supportive care, and potential improvement for disease control.—
Cherlene Delgado, DVM

■ ■ Source

Feline calicivirus: A neglected cause of feline ocular surface infections? Gerriets W, Joy N, Huebner-Guthardt J, Eule JC. *VET OPHTHALMOL* 15:172-179, 2012.

1. **Epidemiologic evaluation of multiple respiratory pathogens in cats in animal shelters.** Bannasch MJ, Foley JE. *J Feline Med Surg* 7:109-19, 2005.

■ ■ ■ For More

See **Online Gallery: FHV-1 Images** by Dr. Alison Clode at cliniciansbrief.com/FHV-online-gallery

MORE ►