

URETHRAL CATHETERIZATION OF THE FEMALE DOG & CAT

Janet Aldrich, DVM, University of California-Davis

URETHRAL CATHETERIZATION is the passage of a urinary catheter from the external urethral orifice into the urinary bladder.

Benefits & Risks

Urinary catheters are used to quantify urine output and relieve the inability to empty the bladder. The primary risk is urinary tract infection from bacteria introduced during placement or ascending around or through the catheter. We recently reported the incidence of catheter-associated urinary tract infection as 10.3% in male and female dogs, with a mean duration of catheterization of 2 days.¹ This infection rate was lower than in previous reports, which we attributed to a standardized placement technique and catheter maintenance as described here. We found no association between gender and risk for catheter-associated urinary tract infection.

Technique

Various techniques have been described for placing urinary catheters in females. Most of these techniques include a speculum, light source, otoscope, and stylet.² In most of our patients we use a digital technique, also called a blind technique, that does not require a speculum, light source, or otoscope. Stylets are not routinely used. We prefer the technique described here for the following reasons:

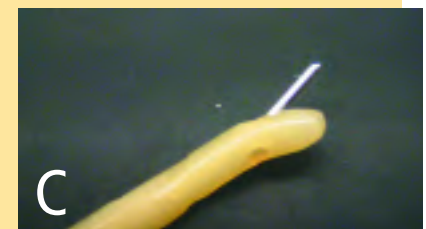
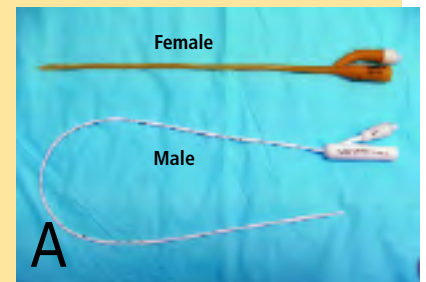
- We can position the patient in lateral recumbency, which is more comfortable than draping the rear legs over the end of the table as described for the instrument technique.

- Inserting a finger lubricated with sterile lidocaine jelly, rather than instruments, is more comfortable for the patient because it causes less distention of tissues.
- The positioning and local anesthesia with lidocaine jelly greatly reduce the need for sedation.
- Risk for tissue damage during insertion is reduced because stylets are used less often.

continues

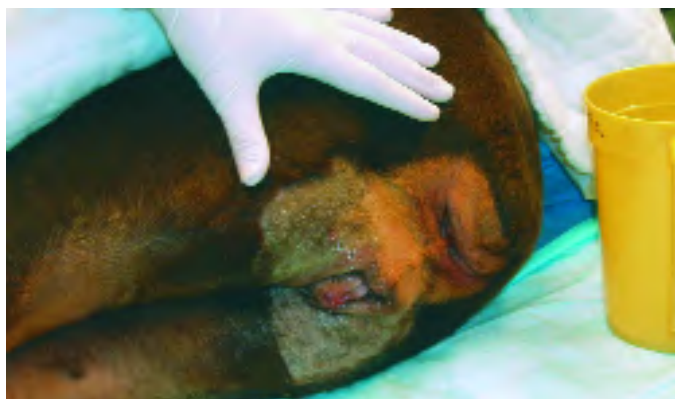What You Will Need

- We prefer Foley catheters (**Figure A**) because they are soft and pliable (decreased tissue trauma) and are self-retaining (no sutures needed).
- Use 5-French for small dogs, 8-French for medium dogs, and 10- to 12-French for large dogs.
- Multipurpose catheters, such as polypropylene and red rubber, can also be used; however, they must be sutured in place. Polypropylene catheters are made of semirigid plastic and although they are easier to introduce into the urethral opening, they are more likely to traumatize vestibular tissue and may damage the bladder if advanced too far. Our impression is that they are uncomfortable for the patient.
- Use 5- or 3.5-French catheters for cats and very small dogs. 5-French Foley catheters have a flexible stylet (**Figure B**). If a stylet is used, care must be taken that it does not become misdirected or dislodged during insertion. **Figure C** is the tip of a urinary catheter with a stylet. The stylet has become dislodged and is exiting through the side port rather than extending to the tip of the catheter. This misdirection of the stylet will preclude advancing the catheter tip into the urethra and repeated attempts to advance it can cause severe tissue injury.
- All in-dwelling urinary catheters should be attached to a sterile, closed collection system.

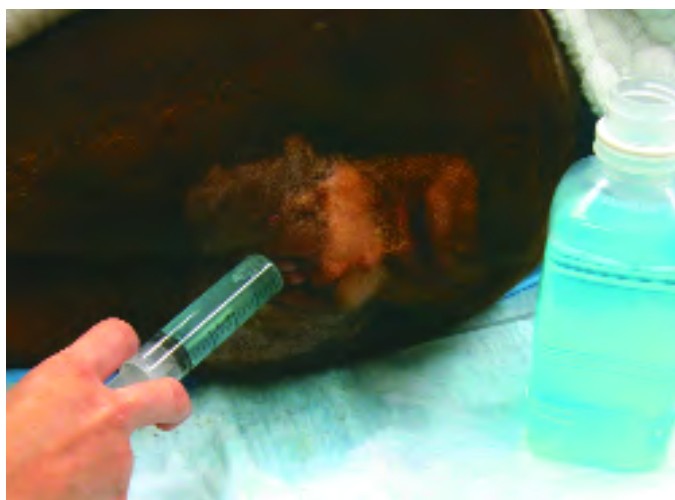

STEP BY STEP HOW TO PERFORM URETHRAL CATHETERIZATION

Patient Preparation



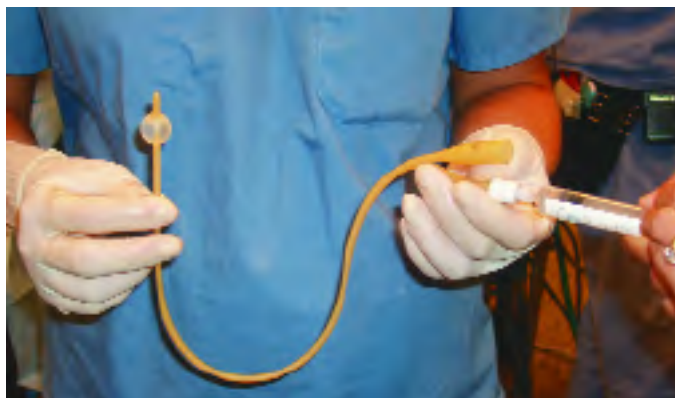1 Position the patient comfortably in right lateral recumbency (for right-handed operators). Sedation is usually not needed in dogs because this position is comfortable and lidocaine jelly in the vestibule provides adequate pain control. Sedation is usually needed in cats. Clip, clean, and aseptically prepare the perivulvar area.



2 Flush the vestibule with 0.05% Nolvasan solution (6.3 ml Nolvasan in 250 ml sterile water). Instill enough 2% lidocaine jelly (0.5 to 2 ml, depending on patient size) into the vulva and vestibule to provide local anesthesia and lubrication. Place sterile drapes.

Catheter Insertion

Maintain sterile technique throughout the procedure. Operators should use the dominant hand for palpation. The procedure described here is for a right-handed operator.



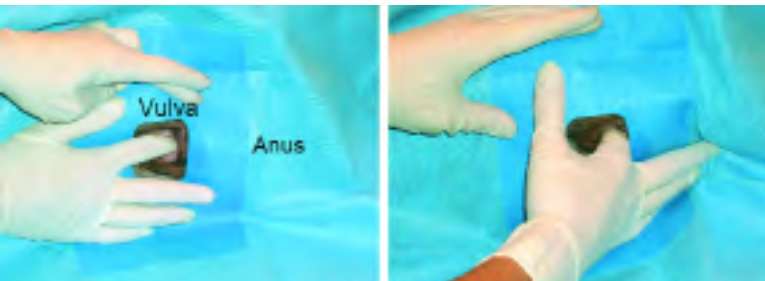3 Inspect the catheter, estimate the length of catheter required to reach the bladder, and verify patency of the balloon.

Anatomy

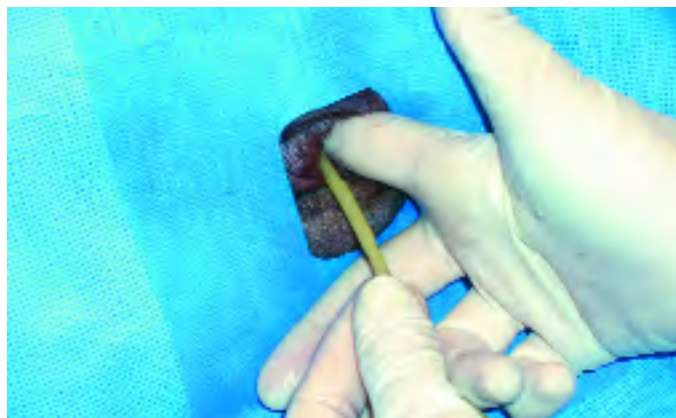The vagina is a canal extending from the vulva cranially to the cervix. It consists of two cavities, the most caudal is the vestibule, and the cranial cavity is the vagina. The urethral opening is covered by a soft mound of tissue and is located ventrally on midline in the vestibule, close to its junction with the vagina. The vestibular vaginal junction is palpable as a circular thickening that narrows the cavity.

PROCEDURE PEARL

With practice, one can learn to advance a catheter without a stylet using the technique described in this article.

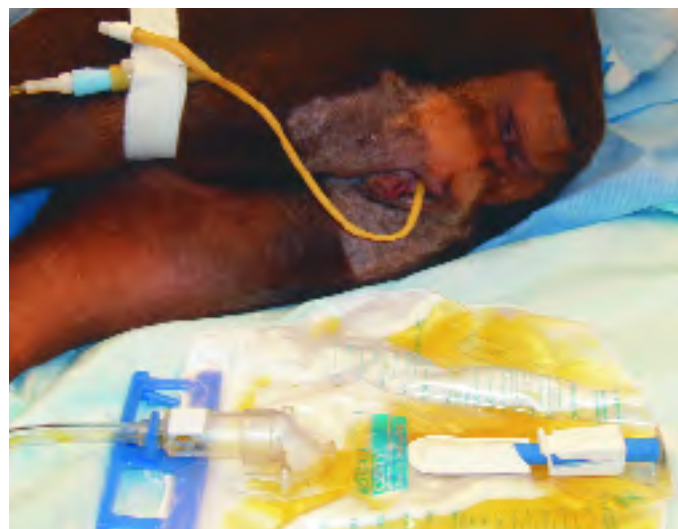

4 Insert a lubricated finger of the right hand between the labia of the vulva, direct the finger dorsally to avoid the clitoral fossa, then cranially to enter the vestibule. Slide the finger along the floor of the vestibule, on midline, and palpate the urethral opening at the junction of the vestibule with the vagina. The urethral opening is covered by a mound of tissue (papilla) that may be obvious or subtle. The junction of the vestibule and the vagina is a muscular thickening that is usually palpable as a narrowing of the lumen of the cavity to the extent that further advancement of the finger is impossible. Rather than an impediment, this anatomical landmark is usually helpful because the urethral opening is located just caudal to this junction. Inserting a finger into this opening prevents the catheter from advancing into the vagina rather than into the urethral opening.



5 Use the left hand to grasp the catheter near the tip, and gently insert it between the labia of the vulva and into the vestibule. Then place the finger of the right hand (which is within the vestibule) on the tip of the catheter and gently push it forward in very small increments to guide it along the ventral floor of the vestibule to the urethral opening. Do not expect to advance the catheter simply by pushing with the left hand: Gently advance it with the right finger while using the left hand to keep the catheter aligned. (Our students have compared this to advancing cooked spaghetti along a wet table.)

6 Position the tip of the catheter at the urethral opening and advance it in increments of a few millimeters until the catheter has entered the urethra. Verify placement in the urethra by palpating the tissue of the urethral papilla over the catheter. If the catheter has slipped over the papilla, it will continue to advance into the vagina but in that position the tissue cannot be palpated over the top of the catheter.



7 Once the catheter has entered the urethra, advance it until it rests in the bladder. Secure it by inflating the balloon for a Foley catheter, gently pull the catheter caudally to position its tip at the neck of the bladder, and attach a closed, sterile collection system. Secure the catheter to the rear leg or tail to prevent excessive traction on it. Maintain sterility of the closed system. See **Maintenance**, page 20.

Various strictures are present in some dogs. Most are cranial to the urethral opening and do not hamper catheterization. Rarely, the urethral opening is cranial to the stricture and the catheter must be directed through the stricture and then ventrally. In this case, the urethral opening cannot be palpated unless there is enough room for the finger to pass through the stricture. Nonetheless, blindly advancing the catheter along the correct path is often successful.

PROCEDURE PEARL

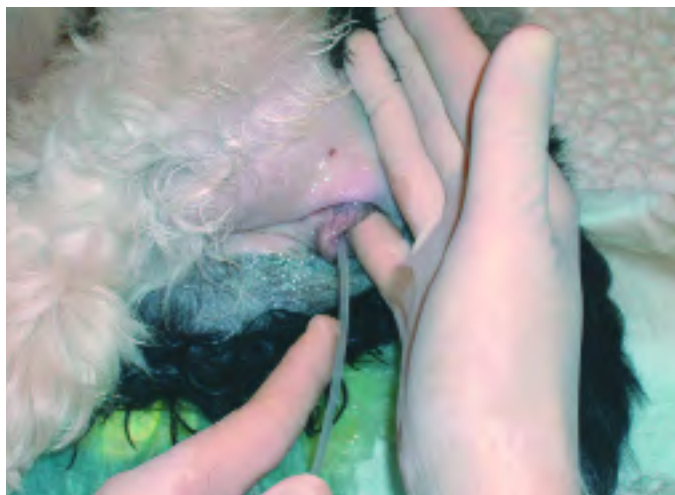Once the catheter tip is in the bladder the balloon is filled with the recommended volume of saline to retain the catheter in the bladder.

continues

Guiding Catheter & Instrument Techniques

If the catheter cannot be placed within a reasonable time by using the digital technique, switch techniques.

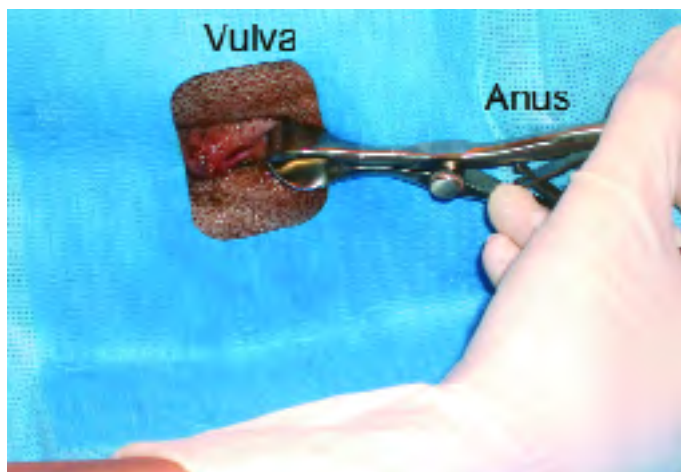
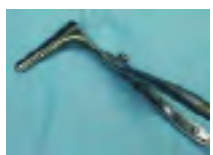Guiding Catheter Technique



Polypropylene catheters are easy to insert but we prefer not to leave them in place because of the potential for tissue trauma and discomfort caused by their stiffness. In a difficult insertion, a polypropylene catheter can be used to locate the urethral opening; then a Foley catheter can be placed in the vestibule alongside it, using the polypropylene catheter as a guide. The polypropylene catheter is then removed.

Instrument Technique

A speculum is used to separate the urethral tissue so that the urethral opening can be seen with the aid of a light source such as a headlamp or penlight. Insert the speculum with the handles toward the anus. Standing out of the operator's way, an assistant should hold the speculum in an open position to allow the otoscope cone to be inserted through it. The




Maintenance

Maintain the sterility of the closed collection system according to published recommendations.³

- Educate personnel in correct techniques of catheter insertion and care.
- Catheterize only when needed.
- Stress hand washing before and after handling catheter and collection system.
- Insert catheter using aseptic technique and sterile equipment.
- Maintain closed, sterile drainage system.
- Maintain unobstructed urine flow.
- Obtain urine samples aseptically.
- Keep urine collection bag below the patient.

We inspect the catheter site daily. We also gently clean the catheter and labia with Nolvasan scrub and water daily, or anytime the catheter is visibly soiled.



catheter is then inserted through the cone into the urethral opening and then into the urinary bladder. A stylet through the catheter is required. The otoscope cone

will not allow the distal portion of the Foley catheter to pass through, so the cone is removed from the otoscope but left in place on the catheter.



It is not necessarily more difficult to place catheters in very small dogs and cats. While their size precludes palpation of the urethral opening, it also

tends to direct a blindly inserted catheter along the correct pathway. Catheterization of female cats is generally easily done with the blind technique but usually requires a 3.5- or 5-French polypropylene tomcat catheter. The kitten shown here weighs 450 grams. We use 5-French Foley catheters in larger cats. The catheter is secured in place to the perivulvar area with a tape butterfly. ■

See Aids & Resources, back page, for references, contacts, and appendices.