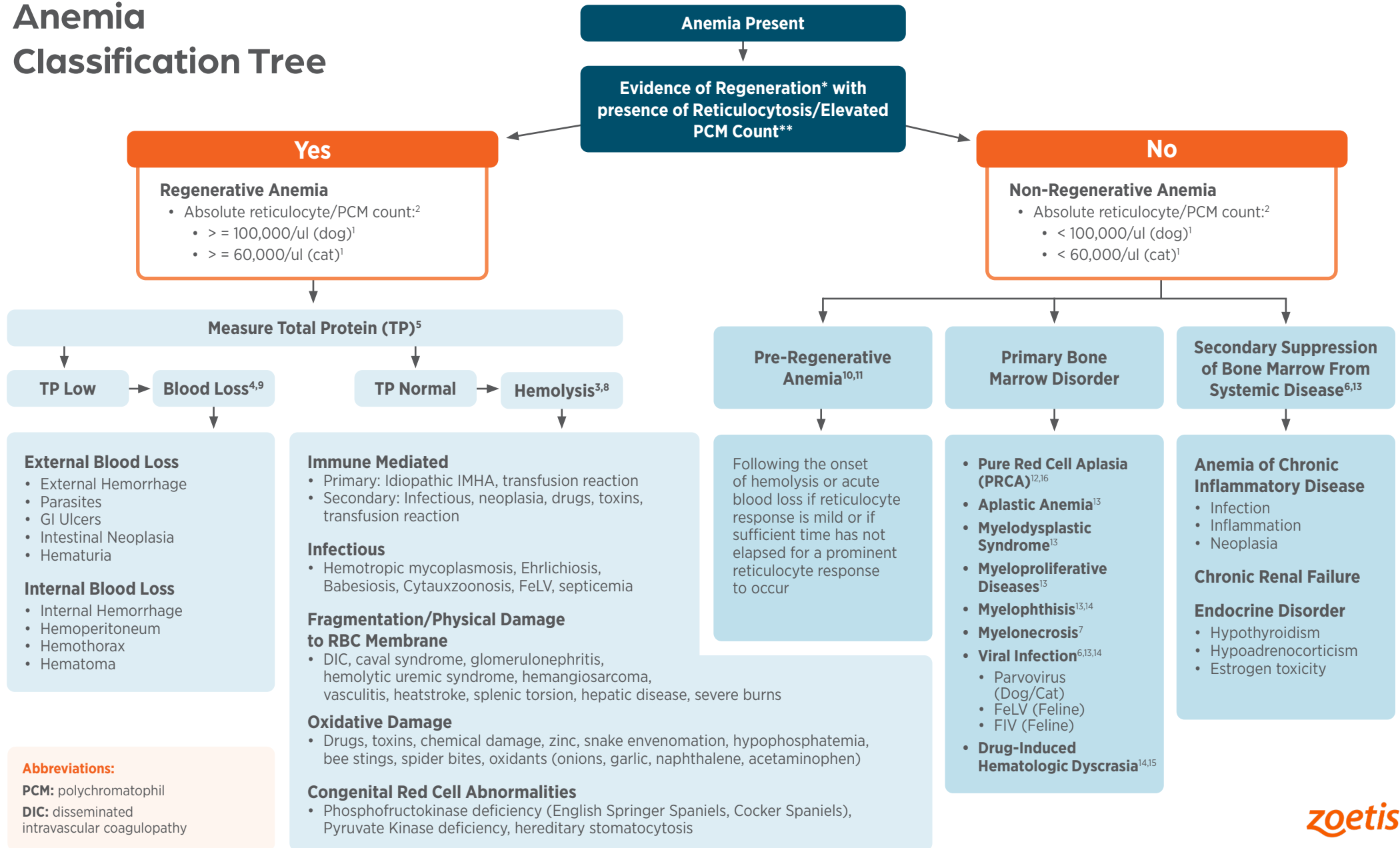


Anemia Classification Tree

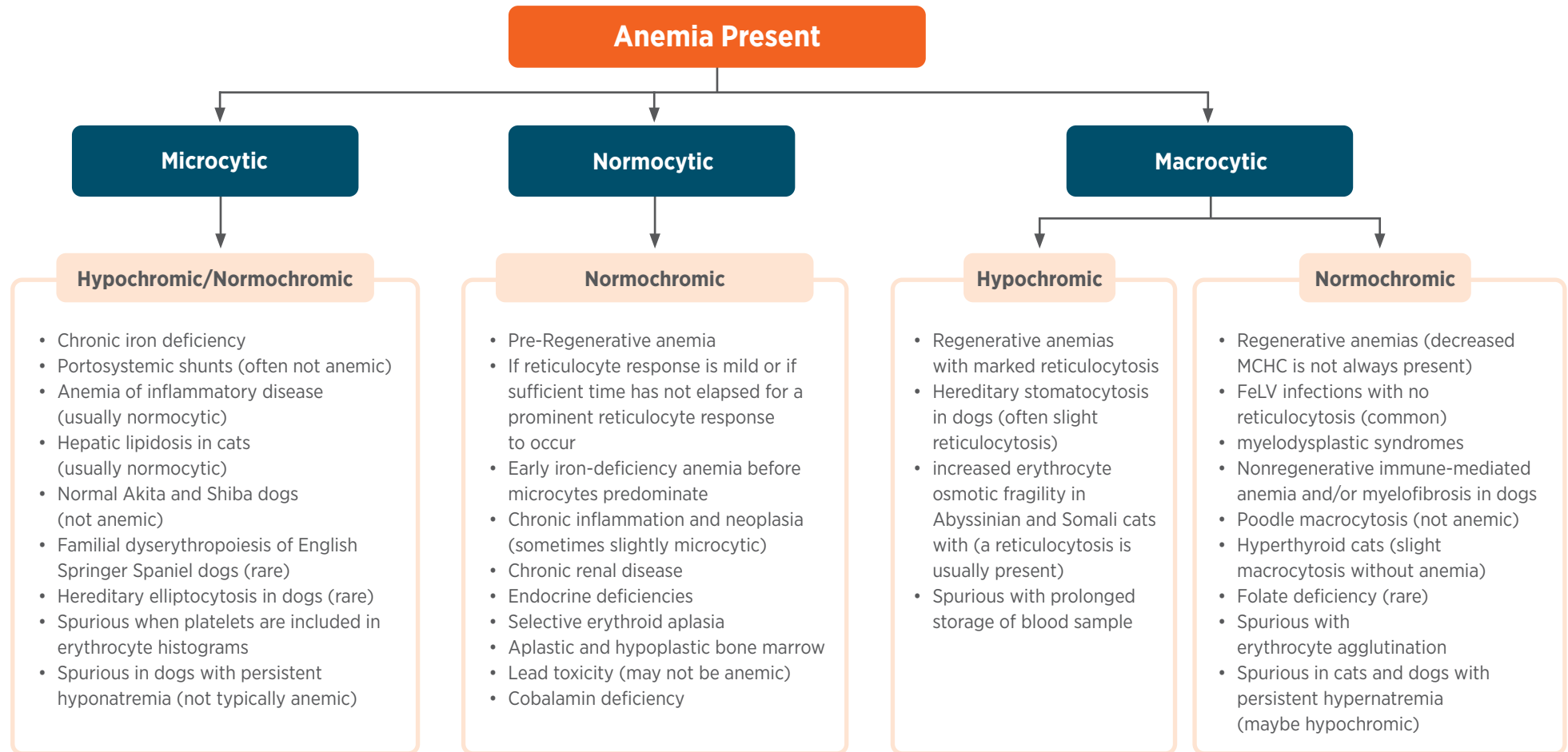


*Evaluation of the adequacy of the bone marrow regenerative response in the individual patient should also include consideration of severity and chronicity of the anemia, suspected cause of the anemia, and potential for multiple causes contributing to the patient's anemia. Trending the anemia and reticulocyte (RETIC)/polychromatophils (PCM) count through sequential Complete Blood Counts (CBC) may be helpful.

**Note: RETIC/PCM counts supporting regeneration can be seen in non-anemic patient. This may reflect a normal physiologic response or a response to an increased need. Serial evaluations of the CBC should be done to rule-out an emerging anemia in these patients. RETIC or elevated PCM counts in the absence of anemia (RAA) may indicate recovery from anemia or may be associated with non-anemic chronic hypoxia (e.g., cardiovascular disease, pulmonary disease). RAA has also been observed in patients with gastrointestinal, inflammatory, and neoplastic disorders, and in dogs with osteoarthritis or receiving osteoarthritis treatments (e.g., anti-inflammatory drugs, nutraceuticals).

1. Zoetis Reference Lab. Data on file. 2. Based on Zoetis Study on File DH7MR-US-21-038, Zoetis demonstrating PCM is an estimate for Reticulocytes on the VETSCAN IMAGYST AI. 3. Harvey, JW. (2012). *Veterinary Hematology: A Diagnostic Guide and Color Atlas*. Saunders/Elsevier, St. Louis, MO. 101. 4. Harvey, JW. (2012). *Veterinary Hematology: A Diagnostic Guide and Color Atlas*. Saunders/Elsevier, St. Louis, MO. 106. 5. Harvey, JW. (2012). *Veterinary Hematology: A Diagnostic Guide and Color Atlas*. Saunders/Elsevier, St. Louis, MO. 92. 6. Harvey, JW. (2012). *Veterinary Hematology: A Diagnostic Guide and Color Atlas*. Saunders/Elsevier, St. Louis, MO. 107. 7. Weiss, DJ. Myelonecrosis and acute inflammation. In: Weiss, DJ, Wardrop, KJ, eds. *Schalm's Veterinary Hematology*, 6th ed. Ames, IA: Wiley-Blackwell; 2010:106-111. 8. Weiss DJ, Wardrop KJ, eds. *Schalm's Veterinary Hematology*, 6th ed. Ames, IA: Wiley-Blackwell; 2010:160. 9. Weiss, DJ, Wardrop KJ, eds. *Schalm's Veterinary Hematology*, 6th ed. Ames, IA: Wiley-Blackwell; 2010:157. 10. Harvey, JW. 2012. *Veterinary Hematology: A Diagnostic Guide and Color Atlas*. Saunders/Elsevier, St. Louis, MO. 182. 11. Weiss, DJ. Bone marrow pathology in dogs and cats with non-regenerative immune mediated hemolytic anemia and pure red cell aplasia. *J Comp Pathol*. 2008;138:46-53. 12. Harvey, JW. (2012). *Veterinary Hematology: A Diagnostic Guide and Color Atlas*. Saunders/Elsevier, St. Louis, MO. 110. 13. Harvey, JW. (2012). *Veterinary Hematology: A Diagnostic Guide and Color Atlas*. Saunders/Elsevier, St. Louis, MO. 110. 14. Weiss, DJ, Klausner JS. Drug-associated aplastic anemia in dogs: eight cases (1984-1988). *J Am Vet Med Assoc*. 1990;196:472-475. 15. Moore, AH, Day, MJ, Graham, MW. (1993). Congenital pure red blood cell aplasia (Diamond-Blackfan anemia) in a dog. *Vet Rec*. 132, (16):414-415. 16. Harvey JW. (2012). *Veterinary Hematology: A Diagnostic Guide and Color Atlas*. Saunders/Elsevier, St. Louis, MO. 109.

Anemia Classification by Red Blood Cell Indices



Additional Anemia Information

- Macrocytic hypochromic:** Regenerative anemias with large, young erythrocytes that are not fully hemoglobinized.
- Normocytic normochromic:** Non-regenerative anemias with residual normal erythrocytes.
- Microcytic hypochromic:** Usually due to iron deficiency anemias.

