


Canine Cryptorchidism

Autumn P. Davidson, DVM, MS, DACVIM

University of California, Davis



Timmy, a 2-year-old castrated German shepherd dog, was referred to a veterinary internist for evaluation of possible cryptorchidism.

History

Timmy had been adopted as a rescued stray 1 year before presentation. At adoption, routine pre-scrotal castration was performed for the single scrotal testis present (reportedly the right testis); an extensive abdominal exploratory procedure failed to identify an abdominal testis. According to the owners, Timmy had recently started urine marking and showing interest in female dogs, and he was often distracted during training. Timmy was fed commercial dog food and received monthly flea and heartworm preventive medications.

Physical Examination

At presentation, Timmy appeared healthy with a body condition score of 3/5. The scrotal sac was empty and atrophied, and the prostate was moderate-sized, bilobed, and firm; palpation did not elicit a painful response.

Laboratory Results & Diagnostics

Results of human chorionic gonadotropin (hCG) response testing completed by the referring veterinarian after consultation with a commercial laboratory revealed a testosterone concentration of 1.7 ng/mL following IV administration of 50 IU/kg hCG (range, intact: 1–7 ng/mL; range, castrated: <0.1 ng/mL). No preadministration samples were submitted by the referring veterinarian.

Results revealed a testosterone concentration of 1.7 ng/mL following IV administration of 50 IU/kg hCG.

hCG = human chorionic gonadotropin, LH = luteinizing hormone, SAP = semen alkaline phosphatase

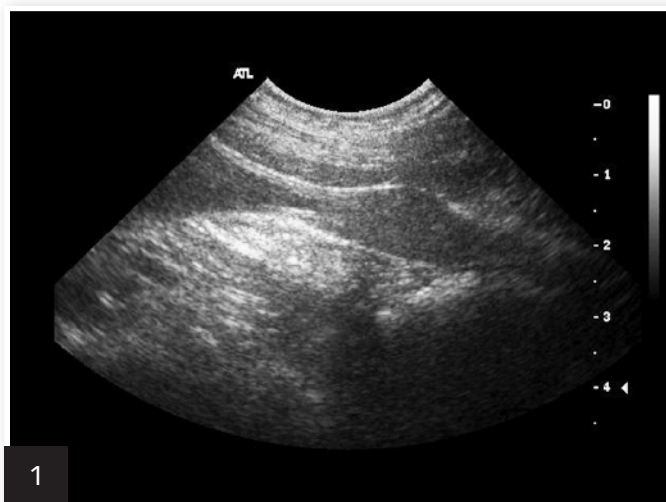Serum luteinizing hormone (LH) concentration, a test not labeled for male dogs, was negative at <1 ng/mL. A single positive test suggests a spayed female, although a second test should be performed at a later date to confirm that the patient has been spayed. Positive tests can occur just before ovulation in intact females.

Abdominal ultrasonography—including both inguinal canals to the extent that was possible—disclosed no abnormalities, including presence of an abdominal testis. The prostate appeared enlarged and hyperechoic—typical of a mature male (Figures 1 and 2).

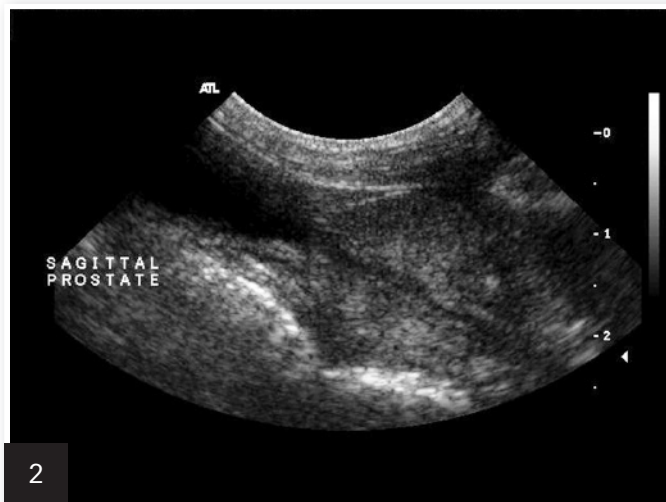In the presence of a bitch in estrus, Timmy displayed an active libido, and azoospermic semen was readily collected. Semen alkaline phosphatase (SAP) was 26,500 IU/L (>5000 IU/L is indicative of complete ejaculate).

Additional exploratory surgery was performed by a board-certified veterinary surgeon. An abdominal testis was not identified despite thorough evaluation of the abdomen.

MORE ►



Sagittal image of a normal prostate in a castrated dog



Sagittal image of a normal prostate in an intact dog; note the increased echogenicity of the prostatic parenchyma.

Ask Yourself



Why was this dog sent to surgery?

- A. Lack of negative feedback (estrogen or testosterone) from the gonads (ovary or testis) to the hypothalamus and pituitary gland results in elevated LH.
- B. Prostatic size and echogenicity visualized via ultrasonography supported testosterone influence.
- C. Bilaterally cryptorchid dogs are virile (normal testosterone concentrations) but sterile; unilateral cryptorchid dogs with the scrotal testis removed are virile and can be fertile.
- D. All of the above

Correct Answer

D. All of the above

On further investigation deep into the left inguinal canal, the left testis was reduced from the canal into the scrotum and removed (Figure 3).

Six weeks postoperatively, the owners reported that Timmy appeared calmer. At follow-up examination, serum LH paired testing was positive (>1 ng/mL).

Timmy's behavior, prostate size, prostate appearance on ultrasonography, serum testosterone concentration following administration of hCG, and negative LH testing was supportive of endogenous testosterone production.

Spermatogenesis is inhibited by the temperature in the abdomen, and a lack of spermatogenesis was supportive of a nonscrotal testis. Testosterone production is normal in dogs with abdominal testes. The unremarkable ultrasonography results and abdominal exploratory procedures supported an inguinal location of the left testis.

Cryptorchidism

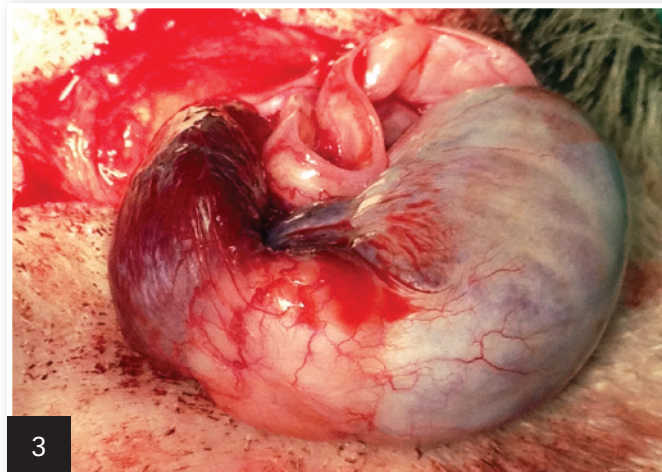
Cryptorchidism, a common congenital genital defect in male dogs, is diagnosed if either or both testes are not present in the scrotum at puberty. Testes typically descend into the scrotum by 6 to 16 weeks of age in puppies and before birth in kittens.

In dogs, descent can occur as late as 10 months of age, but that time frame is abnormal; late testicular descent and undescended testes are heritable defects.

Testicular hormone insulin-like factor 3 is produced by prenatal and postnatal Leydig cells and mediates transabdominal testicular descent from the caudal pole of the kidney to the inguinal canal. This hormone induces growth and differentiation of the gubernaculum from the caudal suspensory ligament.

Transabdominal migration of fetal testes is independent of androgen presence, but inguinoscrotal descent is mediated by

Castrated dogs can copulate and ejaculate.



3 Exteriorized inguinal testis and epididymis; the testis measured 1.2 × 2.3 cm.

testosterone, which causes regression of the cranial suspensory ligament. During the inguinoscrotal phase of migration, shortening of gubernaculum and eversion of cremaster muscle occur.

Localization of one or both cryptorchid testes on ultrasonography can confirm the condition in pediatric patients with unilateral or bilateral involvement and can assist the surgeon in planning the approach (ie, prescrotal vs cranial abdominal).

■ cb

The Take-Home



- Castrated dogs can copulate and ejaculate.
- Ultrasonography of the abdomen alone can miss cryptorchid testes in the inguinal canal because of interference from the bony pelvis. Retained testes can be positioned anywhere between the ipsilateral kidney and the scrotum.
- In dogs, most SAP is produced in the epididymis. Ejaculate without spermatozoa but with a SAP of >5000 IU/L suggests lack of spermatogenesis.

See Aids & Resources, back page, for references & suggested reading.