

Infundibular Keratinizing Acanthoma

(aka canine intracutaneous cornifying epithelioma, keratoacanthoma, "ice" tumor)

What is an infundibular keratinizing acanthoma?

This type of skin tumor is an uncommon, benign neoplasm which are believed to arise from the hair follicle.

Why is my dog getting these tumors?

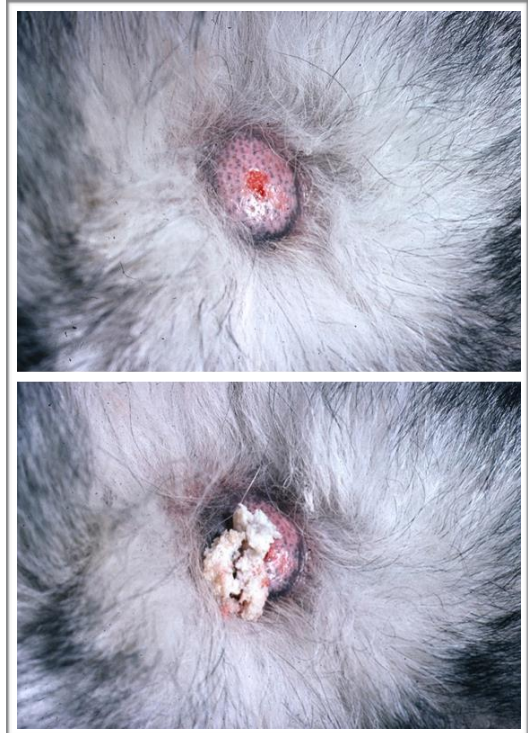
The ultimate underlying cause of infundibular keratinizing acanthomas are unknown. The generalized forms may have a hereditary basis in dogs and humans. Papillomavirus does NOT appear to be a contributing factor in this disease.

German shepherd dogs, Old English sheepdogs, Norwegian elkhounds and keeshonds are predisposed to the generalized form of these tumors.

What do these tumors look like?

They are classically intradermal masses that vary in size between 0.5 to 3 centimeters (approximately 1/2 to 3 1/2 inches) in diameter. They can have a central pore through which a grey keratinous material may be expressed. They can also appear as firm masses within the skin.

They can be found along the back, neck, chest and down the limbs. These tumors often rupture open on the skin and can become secondarily infected.

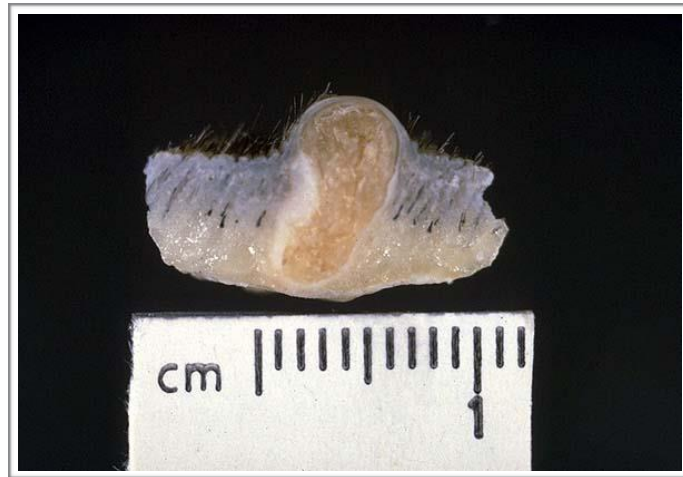

How are these tumors diagnosed?

Your veterinarian or veterinary dermatologist may perform a skin biopsy of one of these tumors in order to diagnose this disease. Fine needle aspirate (using a needle to obtain cells from the tumor) is also a method used to determine the contents of these tumors.

How are infundibular keratinizing acanthomas treated?

Unfortunately these tumors are difficult to manage. The options for clinical management are surgical excision, cryotherapy, electrotherapy, and observation without treatment. Surgical excision, laser therapy, cryotherapy or electrotherapy are more ideal if there only a few tumors in question. In the generalized form, the number of tumors may make surgical excision either too extensive or cost prohibitive. Oral administration of retinoids (chemical compounds that can affect skin cell growth) have been used in some dogs with the generalized form of this disease - however this treatment is often cost-prohibitive and there are risks to using these medications that should be discussed with your veterinarian. It is important to note that no treatment will prevent new tumors in forming.



Picture credits: Muller and Kirk's Small Animal Dermatology 6th edition,
<http://cal.vet.upenn.edu/projects/derm/Home/ADNEXAL/follic/infun.htm>

Written by: Brooke Simon, DVM