International Journal of Gynecology and Infertility
Case Report (ISSN: 2998-4831)

Prenatal Diagnosis and Reproductive Counselling in a Subsequent Pregnancy of a Couple with a Child Affected by FIG4-Related Leukoencephalopathy: A Case Report

Ashish Singh[1*], Tanya B. Rohatgi[2], Sonia Naik[3], Heera P[4], Binita Neupane[5]

[1]Department of Obstetrics and Gynecology, Max Super Speciality Hospital, New Delhi, India

[2]Director of Reproductive Medicine, Onco-Fertility, and IVF at Max Healthcare, New Delhi, India

[3]Principal Director Obstetrics and Gynecology at Max Helathcare New Delhi, India

[4]Senior Consualtant Obstetrics and Gynecology at Max Helathcare New Delhi, India

[5]Consultant in Obstetrics and Gynecology at Max Healthcare, New Delhi, India

Citation: *Ashish Singh, Tanya B. Rohatgi, Sonia Naik, Heera P, Binita Neupane. Prenatal Diagnosis and Reproductive Counselling in a Subsequent Pregnancy of a Couple with a Child Affected by FIG4-Related Leukoencephalopathy: A Case Report. Int Jour Gyn Infer. 2026;3(1):1-7.* ORCID ID: https://orcid.org/0009-0003-8479-6869

Received Date: 01 October 2026; **Accepted Date:** 03 October 2026; **Published Date:** 04 October 2026

***Corresponding author:** Dr. Ashish Singh, MBBS, RCOG Trainee, Department of Obstetrics and Gynecology, Max Super Speciality Hospital, New Delhi, India

Copyright: © Ashish Singh, Open Access 2026. This article, published in Int Jour Gyn Infer (IJGI) (Attribution 4.0 International), as described by http://creativecommons.org/licenses/by/4.0/

ABSTRACT

Background: FIG4-related leukoencephalopathy is a rare autosomal recessive disorder of central and peripheral myelination caused by biallelic pathogenic variants in FIG4, the same gene responsible for Charcot-Marie-Tooth disease type 4J. Couples who are both carriers face a 25% recurrence risk in each subsequent pregnancy, and prenatal diagnosis is central to reproductive decision-making.

Case Presentation: We describe a 32-year-old woman (G3P2L1) whose first child was diagnosed with FIG4-related leukoencephalopathy (compound heterozygous FIG4 variants, c.504C>G and c.1141C>T) after presenting with delayed development, and whose second pregnancy was terminated after prenatal testing showed the fetus to be homozygous for the familial variant. In her current, spontaneously conceived pregnancy, targeted testing on chorionic villus sampling showed the fetus to be heterozygous for the familial FIG4 variant— unlikely to be affected— while chromosomal microarray unexpectedly identified a de novo 6q27 duplication classified as a variant of uncertain significance. Serial growth ultrasound subsequently showed the fetus tracking on the 3rd–4th centile for estimated fetal weight with reassuring Doppler indices, and repeat amniocentesis reconfirmed the fetus was unlikely to be affected by FIG4-related leukoencephalopathy.

After 26 weeks plus 1 day of pregnancy, the patient directly reported in labour with lower abdominal pain at 37 weeks plus 6 days. The patient delivered a female baby by LSCS in view of persistent non-reassuring NST. Weighing 2.52 kg, which was on the 16th centile, the length of the baby was 47 cm, which was on the 28th centile, and the head circumference was 34 cm, which was on the 61st centile.

No resuscitation was required. The Apgar scores at 0, 5, and 10 minutes were 7, 8, and 8, respectively.

The baby underwent extended screening using the 48+6 parameter. The techniques used were fluoroenzyme immunoassay for newborn screening and tandem mass spectrometry for inborn errors of metabolism. The screening results were negative for all the listed parameters in the panel, including neonatal TSH, neonatal 17-OHP, G6PD, neonatal IRT, galactose, and biotinidase. Whole-exome sequencing of the newborn was negative for the FIG-4 mutation.

Conclusion: This case illustrates the value of targeted prenatal testing in a known carrier couple, the counselling challenge posed by an incidental variant of uncertain significance identified on chromosomal microarray, and the need for concurrent growth surveillance in a pregnancy already burdened by significant genetic anxiety.

Keywords: FIG4-related leukoencephalopathy; Prenatal diagnosis; Chorionic villus sampling; Chromosomal microarray**;** Genetic counseling; Variant of uncertain significance; Fetal growth restriction

INTRODUCTION

FIG4 encodes a phosphoinositide phosphatase required for normal endolysosomal trafficking in neurons, Schwann cells, and oligodendrocytes. Biallelic loss-of-function variants in FIG4 were first described as the cause of Charcot-Marie-Tooth disease type 4J (CMT4J), a severe demyelinating peripheral neuropathy, and of Yunis-Varón syndrome.[1,2] The phenotypic spectrum has since been expanded to include a central nervous system leukoencephalopathy with early-childhood-onset hypomyelination, described in several families with biallelic FIG4 variants and, in some cases, coexisting polymicrogyria.[3,4] Because FIG4-related disease is autosomal recessive, unaffected parents who are both carriers face a 25% recurrence risk in each pregnancy, and once a familial pathogenic variant is characterised, targeted prenatal testing on chorionic villus or amniotic fluid samples can determine the fetal genotype well before viability.[1]

Chromosomal microarray (CMA) is now routinely performed alongside or in place of targeted variant testing in invasive prenatal diagnosis, but its broader genomic resolution means that incidental copy-number variants of uncertain clinical significance (VUS) are not infrequently encountered, posing a distinct counselling challenge that is separate from — but can compound — anxiety around a known familial mutation.[5,6] We report a case in which both issues arose in the same pregnancy: reassuring targeted testing for a well-characterised familial FIG4 mutation, alongside an incidental microarray finding of uncertain significance, in a pregnancy that went on to show early fetal growth restriction.

MATERIAL AND METHOD

This report was prepared by retrospective review of the patient's available obstetric, genetic, and laboratory records, spanning documentation from a department of medical genetics, a fetal medicine centre, and a general hospital antenatal clinic. All investigations described were performed as part of routine clinical care rather than for research purposes. In accordance with patient confidentiality requirements, all personally identifying information— including the patient's name, her husband's name, and contact details— was removed prior to analysis, and the patient is referred to throughout as "Patient 2." Findings are reported descriptively from the source documents without interpretation beyond what is directly supported by the extracted data; where

handwritten entries were only partially legible (for example, individual trisomy risk ratios on serum screening), this is noted rather than inferred.

Clinical Findings

Patient ID: Patient 2

Age: 32 years

Sex: Female

Obstetric code: G3P2L1 (as recorded); spontaneous conception, singleton pregnancy

The patient's first child, delivered by caesarean section at term in 2020, was subsequently found to have delayed development and was diagnosed with FIG4-related leukoencephalopathy on whole-exome sequencing, showing a compound heterozygous variant in exon 6 and exon 11 of FIG4 (c.504C>G and c.1141C>T). A second pregnancy in 2023 was found on prenatal testing to be homozygous for the familial variant and was medically terminated at approximately four months' gestation. Parental carrier testing confirmed both the patient and her husband as heterozygous carriers.

In the current pregnancy, chorionic villus sampling was performed for targeted FIG4 testing: QF-PCR was normal, and targeted sequencing showed the fetus to be heterozygous for the familial variant, assessed as unlikely to be affected by FIG4-related leukoencephalopathy. Chromosomal microarray performed on the same tissue unexpectedly identified a de novo heterozygous duplication at 6q27 (arr[GRCh37]6q27(168,382,157_170,919,482)x3), absent from the Database of Genomic Variants and not reported in ClinVar; smaller overlapping duplications have been described in four DECIPHER patients with variable inheritance, and the variant was classified as being of uncertain significance. Parental microarray showed the same chromosome 6 gain in the husband (also a VUS) and no abnormality in the patient. A repeat amniocentesis subsequently reconfirmed that the fetus was unlikely to be affected by FIG4-related leukoencephalopathy.

Detailed obstetric ultrasound at 22 weeks 5 days (Department of Medical Genetics) showed a single live fetus with normal situs, spine, and intracranial anatomy; a normal four-chamber cardiac view; and no major limb or facial malformation. Biometry corresponded to a mean gestational age of 21 weeks 3 days, with no major malformation identified. Serial growth surveillance subsequently showed that the estimated fetal weight was tracking below the population mean:

Table 1: Serial fetal growth and Doppler assessment during pregnancy.

Date	POG	EFW / Centile	Doppler
30/09/2025	10w3d	Dating scan	—
13/01/2026	22w5d	No apparent structural defect	—
24/01/2026	26w1d	713 ± 104 g (4th centile)	Umbilical artery PI 1.08,

Date	POG	EFW / Centile	Doppler
			MCA PI 1.72, CPR 1.59 — all normal

At the 24 January 2026 growth scan, amniotic fluid was adequate (AFI 11.1 cm), the placenta was posterior and grade II, and cervical length was 36.0 mm with no funneling. The scan was formally reported as not an anomaly scan, with fetal growth on the 4th centile — small for gestational age — and a recommendation for a review growth scan after two weeks. Antenatal laboratory workup was otherwise unremarkable: blood group B Rh-positive, beta-thalassemia screen 2.9%/0.4%, non-reactive HIV/HBsAg/anti-HCV/VDRL, no homozygous SMN1 exon 7/8 deletion on maternal MLPA testing, and a high vaginal swab with no growth. Transferrin saturation was mildly reduced (18.22%) with normal serum iron, UIBC, and TIBC, and vitamin D was low (27.7 ng/mL).

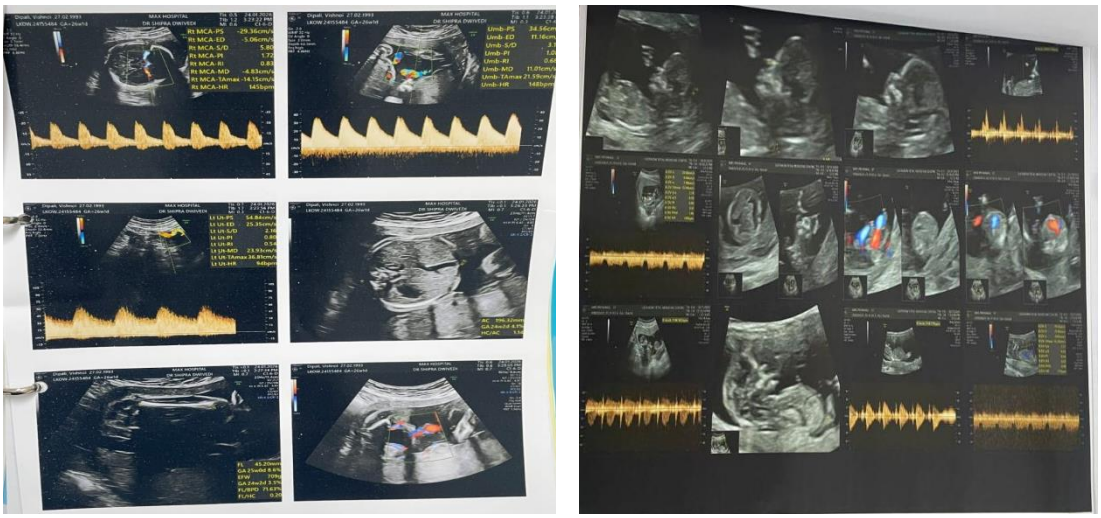

Figure 1 and 2: Obstetric ultrasonography with color Doppler and spectral Doppler assessment

DISCUSSION

FIG4-related disease illustrates how a single gene can produce a spectrum of phenotypes depending on variant severity and residual protein function: complete loss of function causes the lethal Yunis-Varón syndrome, hypomorphic biallelic variants cause the peripheral neuropathy CMT4J, and a distinct subset of families— as in this patient's first child— present with a leukoencephalopathy dominated by central hypomyelination rather than peripheral neuropathy alone.[1–4] Lenk and colleagues, describing four such families, noted that the central white-matter phenotype correlates with the pattern of myelination defects seen in Fig4-null mice and with FIG4's established role in oligodendrocyte maturation, providing a mechanistic basis for the phenotype observed in the proband here.[3] Because the disorder is autosomal recessive and the familial variants were fully

characterized in the first affected child, targeted testing in this pregnancy could offer a high degree of reassurance once the fetus was shown to be heterozygous rather than homozygous— precisely the scenario for which single-gene prenatal testing is most informative.[1]

The incidental 6q27 duplication identified on chromosomal microarray illustrates a separate and increasingly common counselling problem. As genome-wide platforms have become routine in invasive prenatal diagnosis, variants of uncertain significance are recognized as a leading source of counselling difficulty, precisely because they provide molecular information without a clear answer about phenotype.[5,6] A 2025 cross-sectional survey of North American cytogenetics laboratories found substantial inter-laboratory variation in whether and how prenatally identified VUS are reported, driven in part by differing size thresholds, concerns about pregnancy termination decisions, and the absence of national reporting guidelines— variation that has direct bearing on how a finding such as this one is communicated to a family already anxious about a known monogenic risk.[5] A 2026 narrative review of prenatal exome sequencing and microarray similarly emphasises that interpretation of uncertain and incidental findings remains one of the principal limitations of current prenatal genomic testing, underscoring the importance of expert, multidisciplinary counselling— as was provided here— when such a variant is identified.[6]

The fetus's growth trajectory adds a further, more conventional layer of surveillance to this pregnancy. An estimated fetal weight on the 3rd–4th centile with normal umbilical artery, middle cerebral artery, and cerebroplacental ratio Doppler indices is consistent with a fetus that is small but not yet showing haemodynamic evidence of placental insufficiency; contemporary obstetric guidance for this pattern recommends increased-frequency growth and Doppler surveillance, with the interval and delivery timing individualised to severity, rather than either reassurance or immediate delivery.[7] The recommendation recorded in this case— growth re-scan at two weeks— is concordant with that approach. Whether the mildly reduced transferrin saturation and low vitamin D identified on antenatal screening are contributory to the growth pattern cannot be determined from the available records, but both are correctable and were appropriately flagged for follow-up.

Looking beyond this pregnancy, this couple's confirmed carrier status makes preimplantation genetic testing for monogenic disease (PGT-M) a relevant option to discuss for future reproductive planning, allowing embryo selection prior to transfer and avoiding the sequential burden of invasive prenatal testing and, potentially, pregnancy termination seen across this couple's obstetric history.[8]

CONCLUSION

This case demonstrates the reassurance that targeted single-gene prenatal testing can provide to a couple with a well-characterised recessive disorder in a prior child, while also illustrating how genome-wide testing modalities such as chromosomal microarray can introduce new, unresolved uncertainty in the same pregnancy. Comprehensive, expert genetic counselling— extending across the familial variant, the incidental microarray finding, and conventional growth surveillance— was central to the management of this pregnancy, and preimplantation genetic testing merits discussion for future reproductive planning in this carrier couple.

LEARNING POINTS

1- Targeted prenatal diagnosis provides accurate recurrence risk assessment in couples carrying pathogenic FIG4 variants.

2- Chromosomal microarray may identify incidental variants of uncertain significance requiring multidisciplinary counselling.

3- Concurrent fetal growth restriction warrants serial ultrasound and Doppler surveillance despite reassuring molecular testing.

4- Preimplantation genetic testing should be discussed in future pregnancies of carrier couples.

ABBREVIATIONS

- CVS – Chorionic Villus Sampling
- CMA – Chromosomal Microarray Analysis
- VUS – Variant of Uncertain Significance
- QF-PCR – Quantitative Fluorescent Polymerase Chain Reaction
- MCA – Middle Cerebral Artery
- CPR – Cerebroplacental Ratio
- EFW – Estimated Fetal Weight

PATIENT CONSENT STATEMENT

Written informed consent was obtained from the patient for publication of this case report and accompanying clinical images. A copy of the consent is available for review by the Editor on request.

ETHICAL APPROVAL

Ethical committee approval was not required because this manuscript reports a single clinical case managed during routine clinical care.

CONFLICT OF INTEREST

The authors declare that they have no competing interests.

REFERENCES

1. Lenk GM, Berry IR, Stutterd CA, Blyth M, Green L, Vadlamani G, et al. Cerebral hypomyelination associated with biallelic variants of FIG4. Hum Mutat. 2019;40(5):619–630.
2. Campeau PM, Lenk GM, Lu JT, Bae Y, Burrage L, Turnpenny P, et al. Yunis-Varón syndrome is caused by mutations in FIG4, encoding a phosphoinositide phosphatase. Am J Hum Genet. 2013;92:781–791.
3. Chow CY, Zhang Y, Dowling JJ, Jin N, Adamska M, Shiga K, et al. Mutation of FIG4 causes neurodegeneration in the pale tremor mouse and patients with CMT4J. Nature. 2007;448:68–72.

4. Baulac S, Lenk GM, Dufresnois B, Ouled Amar Bencheikh B, Couarch P, Renard J, et al. Role of the phosphoinositide phosphatase FIG4 gene in familial epilepsy with polymicrogyria. Neurology. 2014;82:1068–1075.
5. Shear MA, Wiita AP, Yu J, Wayman B, Sparks TN, Norton ME, Swanson K. Reporting criteria for prenatally identified variants of uncertain significance differ among cytogenetics laboratories in North America. PrenatDiagn. 2025;45(10):1359–1365.
6. Rodriguez-Revenga L, Ardiles-Ruesjas V, Borrell A. Prenatal use of exome sequencing and chromosomal microarray analysis: indications, interpretation, and gene selection strategies. Diagnostics (Basel). 2026;16(2):185.
7. American College of Obstetricians and Gynecologists. Fetal growth restriction: ACOG Practice Bulletin No. 227. Obstet Gynecol. 2021;137(2):e16–e28.
8. Practice Committee of the American Society for Reproductive Medicine. Indications and management of preimplantation genetic testing for monogenic conditions: a committee opinion. Washington (DC): American Society for Reproductive Medicine; 2023.