

Unveiling a Silent Menace: Intentional Lysol Ingestion Masquerading as Throat Pain and Respiratory Distress in a Young Adult

Vivek Mahadevaiah*, Sangamesh, Koushal Sattaru

Department of Emergency Medicine, Vydehi Institute of Medical Sciences and Research Center, Bangalore, India

Citation: Vivek Mahadevaiah, Sangamesh, Koushal Sattaru. Unveiling a Silent Menace: Intentional Lysol Ingestion Masquerading as Throat Pain and Respiratory Distress in a Young Adult. *Int Clin Med Case Rep Jour*. 2024;3(2):1-3.

Received Date: 06 February, 2024; **Accepted Date:** 10 February, 2024; **Published Date:** 12 February, 2024

***Corresponding author:** Vivek Mahadevaiah, Department of Emergency Medicine, Vydehi Institute of Medical Sciences and Research Center, Bangalore, India

Copyright: © Vivek Mahadevaiah, Open Access 2024. This article, published in *Int Clin Med Case Rep Jour* (ICMCRJ) (Attribution 4.0 International), as described by <http://creativecommons.org/licenses/by/4.0/>.

ABSTRACT

Intentional ingestion of household cleaning agents, a life-threatening act with potentially elusive symptoms, demands prompt recognition by healthcare providers. We present a case report detailing a 26-year-old male who initially sought medical attention for throat pain and breathing difficulty, subsequently revealing intentional Lysol consumption.

The patient, initially reticent about the cause of his distress, exhibited symptoms of throat pain, breathing difficulty, and repeated vomiting. Despite limited initial information, diligent probing led to the revelation of deliberate Lysol ingestion. Upon admission, the patient's condition rapidly deteriorated, necessitating urgent medical intervention and airway protection.

Clinical evaluation unveiled Type 2 respiratory failure and electrolyte imbalances, consistent with toxic exposure. The patient's deteriorating respiratory status required intensive respiratory support. The patient also had anaphylactic shock upon presentation. The patient was successfully managed in ER with IV adrenaline and Adrenaline Nebulizations.

This case highlights the deceptive presentation of intentional Lysol ingestion, initially masquerading as benign throat pain and respiratory distress. It underscores the imperative for thorough history-taking, active probing, and heightened vigilance in cases of unexplained symptoms.

Healthcare providers must be equipped to swiftly identify and manage chemical exposures to avert devastating outcomes. The case of intentional Lysol ingestion serves as a poignant reminder of the urgent need for preventive measures, mental health support, and public awareness campaigns to mitigate such perilous incidents.

Keywords: Lysol ingestion; Throat pain; Respiratory distress

INTRODUCTION

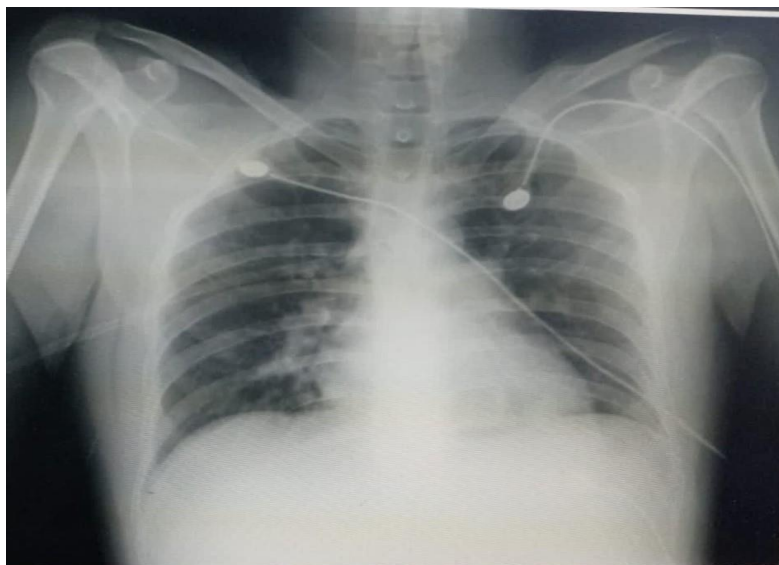
According to the report of the American Association of Poison Control there are about 200,000 caustic poisonings annually, most frequently with acid and alkaline agents that are used as cleansing substances in the households.

[1,2] Corrosive ingestion remains a common problem in developing countries, such as India due to the lack of strict laws that regulate the sale of caustics. While appropriate treatment of the acute phase can mitigate tissue damage improper management of the acute corrosive injury is widely prevalent due to the limited experience of the individual physicians in managing this condition.[3] Lysol is a commonly used household disinfectant and cleaning product that contains various chemicals designed to kill bacteria, viruses, and other germs. While effective when used as directed, improper use of Lysol can lead to poisoning and adverse health effects. This poster presentation aims to provide an overview of Lysol poisoning, its causes, symptoms, and preventive measures.

CASE REPORT

A 26 years old male brought to ER with c/o progressive difficulty in breathing and vomiting, throat pain and repeated vomiting patient has visited a nearby clinic where antacids and antibiotics were prescribed and sent home, on examination patient was found to be drowsy and in respiratory distress, tachycardia and hypotension was also noted on auscultation bilateral reduced air entry on basal regions with rhonchi and stridor. ABG was suggestive of respiratory acidosis with elevated lactates, there was no relief of symptoms with levosalbutamol nebulization. Chest x ray showed STEEPLER SIGN. On repeated probing, patient confessed to have consumed Lysol liquid with suicidal intension. Adrenaline IV infusion and nebulization was given following which breathlessness reduced, however patient was intubated in view of worsening respiratory distress and managed conservatively in ICU. Endoscopy revealed Zanker's stage 2B esophageal ulcers which was managed conservatively.

Chest X ray- AP view



DISCUSSION

Lysol poisoning can result from ingestion, inhalation, skin contact, or eye exposure to the product's chemicals. Recognizing the causes, symptoms, and preventive measures associated with Lysol poisoning is crucial for

ensuring the safety and well-being of individuals using cleaning products. By adhering to proper usage guidelines and taking appropriate precautions, the risks of Lysol poisoning can be significantly minimized.

REFERENCES

1. Bronstein AC, Spyker DA, Cantilena LR, Jr, Green J, Rumack BH, Heard SE. 2006 Annual Report of the American Association of Poison Control Centers 'National Poison Data System (NPDS). Clin Toxicol (Phila). 2007;45:815–917.
2. T L Litovitz , W Klein-Schwartz, S White, D J Cobaugh, J Youniss, J C Omslaer, et al. 2000 Annual report of the American Association of Poison Control Centers. Am J Emerg Med. 2001;19:337-395.
3. Kalayarasan R, Ananthkrishnan N, Kate V. Corrosive Ingestion. Indian J Crit Care Med. 2019;23(Suppl 4):S282-S286.