

Radiation Therapy in the Treatment of a Bleeding Pseudotumor

Rakhi Kaila, Steven Miller*, Ahmad Hammoud, Ramesh Boggula, Nitin Vaishampayan

Department of Oncology, Wayne State University School of Medicine, Detroit, USA

Citation: Rakhi Kaila, Steven Miller, Ahmad Hammoud, Ramesh Boggula, Nitin Vaishampayan. Radiation Therapy in the Treatment of a Bleeding Pseudotumor. *Int Clin Med Case Rep Jour.* 2025;4(1):1-7.

Received Date: 06 January, 2025; **Accepted Date:** 11 January, 2025; **Published Date:** 14 January, 2025

***Corresponding author:** Steven Miller, Department of Oncology, Wayne State University School of Medicine, Detroit, USA

Copyright: © Steven Miller, Open Access 2025. This article, published in *Int Clin Med Case Rep Jour(ICMCRJ)* (Attribution 4.0 International), as described by <http://creativecommons.org/licenses/by/4.0/>.

ABSTRACT

Uncontrollable blood loss from a 'bleeding pseudotumor' in a patient diagnosed with lower-risk myelodysplastic syndrome (MDS) represents a severe medical condition with scarce data on therapeutic options. This case report describes a patient treated with radiation therapy for a "bleeding pseudotumor" and reviews the available literature.

Keywords: Radiation; Bleeding; Blood

INTRODUCTION

Myelodysplastic syndromes (MDS) are characterized by ineffective hematopoiesis, leading to blood cytopenias such as anemia, neutropenia, and thrombocytopenia.^[1,2] As a result, patients with MDS often do not have enough healthy blood cells and platelets and subsequently experience low blood cell counts. Myelodysplastic syndromes can also progress to the development of myeloid neoplasms such as acute myeloid leukemia (AML).^[1,2] These myeloid neoplasms, in turn, can often be challenging to diagnose and treat secondary to various factors, including their pathological and clinical heterogeneity.

Lower-risk MDS is included in the spectrum of MDS and is characterized by low bone marrow blast percentage, low number and depth of cytopenia, and relatively good-risk karyotypic and molecular abnormalities. The absence of excess blasts presents a challenge in differentiating lower-risk MDS from other causes of cytopenia. Diagnosing lower-risk MDS requires integrating information from the peripheral blood, specifically a complete blood count, bone marrow morphology, genetic studies, and interrogation of the clinical records to exclude secondary causes of cytopenia.^[1]

In lower-risk MDS, the main goal of therapy is to treat the underlying cytopenias, particularly anemia, to improve the patient's quality of life and avoid transfusion dependence. Chronic transfusions are, unfortunately, one of the only treatments for anemia of lower-risk MDS due to the limited number of treatments available for this condition. So far, no treatment has shown an improvement in survival. Chronic transfusions have been linked to various medical issues, such as increased morbidity due to heart failure, falls, fatigue, and reduced quality of life. Transfusions are also time-consuming for the patient and increase their "dependence" on the medical system. Hospital beds are frequently necessary for these patients, and their costs, including patient transportation, serum testing, iron chelation, and more, are crucial yet typically less than those associated with

erythropoiesis-stimulating agents (ESAs). Despite some debate, the iron overload resulting from blood transfusions can potentially damage multiple organs.^[2,3] During treatment with ESAs, lower-risk MDS patients did not experience an increase in thrombotic events compared with non-treated patients, which is quite different from what was observed for other hematologic neoplasms.^[4]

It has been documented that metal-on-metal hip arthroplasty can cause adverse reactions to the surrounding tissues due to metal debris.^[5] This reaction can lead to local tissue necrosis, fluid collection, and the formation of inflammatory soft tissue masses known as pseudotumors. A bleeding pseudotumor is an uncommon condition characterized by progressive cystic swelling of muscle and/or bone caused by recurrent bleeding.^[5-7] These pseudotumors are not uncommon, although reported incidences vary with different implants, ranging from 0.6% to 61%.^[5]

Although pseudotumors have been studied extensively,^[6] little is known about their natural history, and controversy exists over their management, especially in asymptomatic patients. Reports in the literature show that pseudotumors can grow in size, remain static, reduce in size, and spontaneously resolve. Because of this varied natural history, it is difficult to decide how best to manage them in the short and long term.^[5]

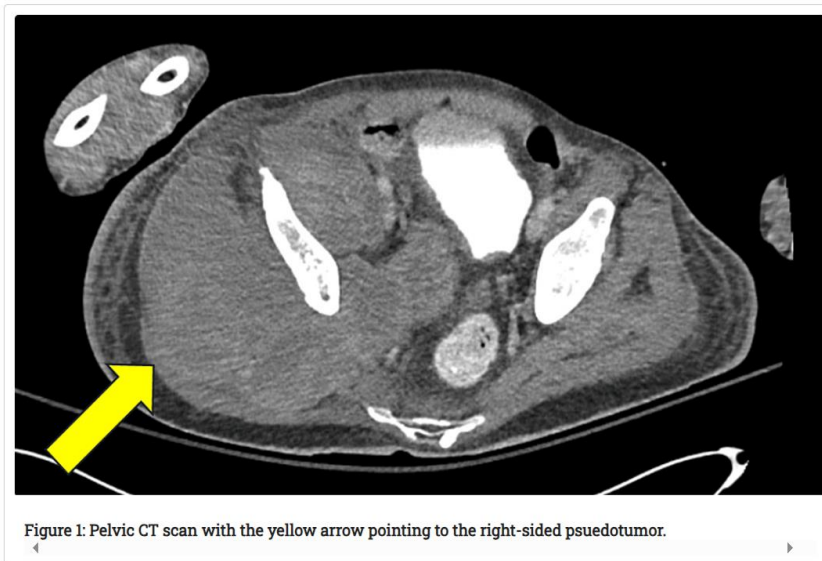
In this case report, we present a patient with a lower-risk MDS and a recent metal on metal hip arthroplasty who developed what was termed a ‘bleeding pseudotumor’ or pseudotumor. The patient subsequently underwent primary radiation therapy as a treatment to manage the bleeding pseudotumor.

CASE HISTORY/EXAMINATION

A male in his late sixties developed a spontaneous atraumatic bleed involving his right hip while at home. He was initially treated at an outside hospital, receiving 14 Units(U) of Packed Red Blood Cells (PRBC) and being transferred to an academic hospital. He was admitted with a diagnosis of impending compartment syndrome involving the right thigh with a history of a metal-on-metal hip replacement.

The patient states he does not remember when the total hip was placed. However, previous records state that the total hip was likely done in the 1990s. The patient states that the pain was likely present up to 5 years ago and was significant enough that he currently walks with a walker or a cane at baseline; however, he has not walked recently since he has been in the hospital. The pain is rated 10/10 in intensity and guards upon any movement around the right hip.

A CT scan of the pelvis on admission revealed a large right-sided pelvic mass causing posterior lateral urinary bladder compression with a hyperdense fluid collection in the right quadriceps muscle without definite extravasation. (Figure 1)



He underwent surgical evacuation of the hematoma in the right thigh, and intraoperatively, approximately 1500cc of the hematoma was removed, with an estimated acute blood loss of approximately 300cc. The hematoma site was explored, and no source of active bleeding was identified. The bleeding was best described intra-operatively as diffuse oozing. He received 6U PRBCs and 2U fresh frozen plasma due to concern for hypotension following the significant fluid shift from the evacuation of the hematoma. He tolerated the procedure well and was transferred to the PACU in stable condition. Post-operatively, he went into hypovolemic shock and was transferred to the surgical intensive care unit. The bleeding persisted, and a CT scan of the pelvis showed a fluid collection in the right gluteal region, which had slightly increased in size. There was also a larger, low-density area within the anterior compartment of the thigh. The overall length of the anterior compartment was unchanged. Interventional radiology was consulted, but the patient was not deemed a candidate for an interventional procedure since a bleeding vessel could not be identified on CT angiography.

Surgery was not recommended due to the concerns of massive bleeding, and medical oncology was also asked to evaluate the patient. Laboratory values at that time revealed a hemoglobin of 7.5 g/dl and a platelet count of 110. A Prothrombin time (PT) was 11.5 seconds (normal 9.4-11.7), an Activated Partial Thromboplastin time (APTT) was 25.5 seconds (normal 23 - 33), and an INR was 1.08 normal (0.87-1.1). A previous bone marrow biopsy was consistent with a lower-risk MDS, but the myelodysplasia was not considered severe enough to account for the current clinical presentation. During the patient's hospital course, he underwent extensive blood transfusions, receiving over 50 units of packed red blood cells (PRBCs) during a 43-day hospitalization.

Following this, a repeated bone marrow biopsy was performed, demonstrating that 50 to 55% of the marrow had been supplanted by hypercellular marrow with mid-erythroid and myeloid hyperplasia. There was no increase in blast cells, and the differential diagnosis included infection, effects of medication, peripheral destruction, and low-risk MDS.

A CT scan of the chest, abdomen, and pelvis revealed a significantly enlarged complex cystic mass within the musculature surrounding the right hip. Additionally, several lobulated low-density or cystic regions were observed in the left gluteus medius muscle, possibly indicative of a resolving hematoma.

A consultation was requested with the radiation oncology team to determine if it was possible to use radiation therapy as the primary treatment for the bleeding pseudotumor in the patient's right thigh. The patient was dependent on transfusions and couldn't be moved out of the ICU. Therefore, radiation therapy was proposed as a potential treatment, referencing prior documented cases.^[7-10] Upon initial review, the patient was clinically stable hemodynamically, with surgical drains already in place (Figure 2).

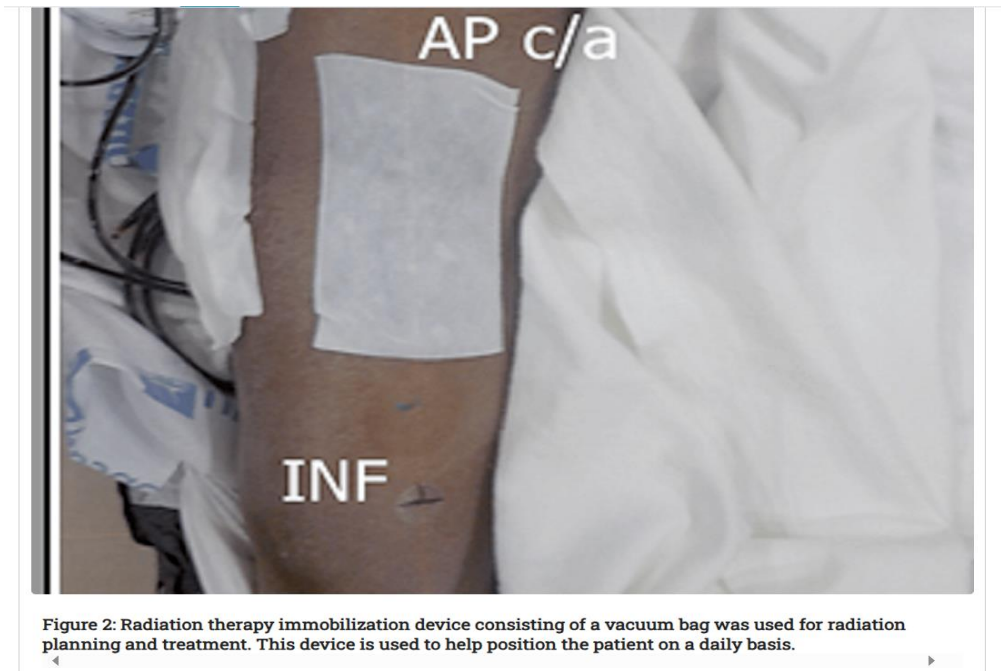
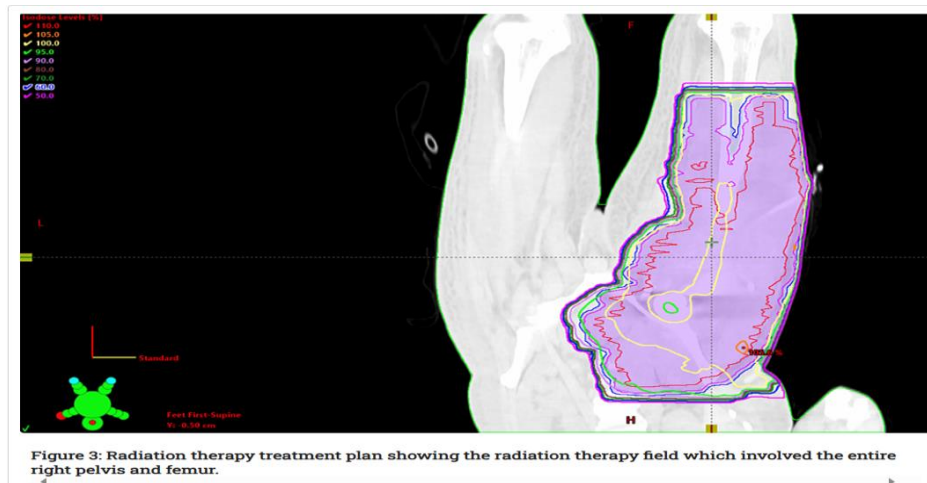


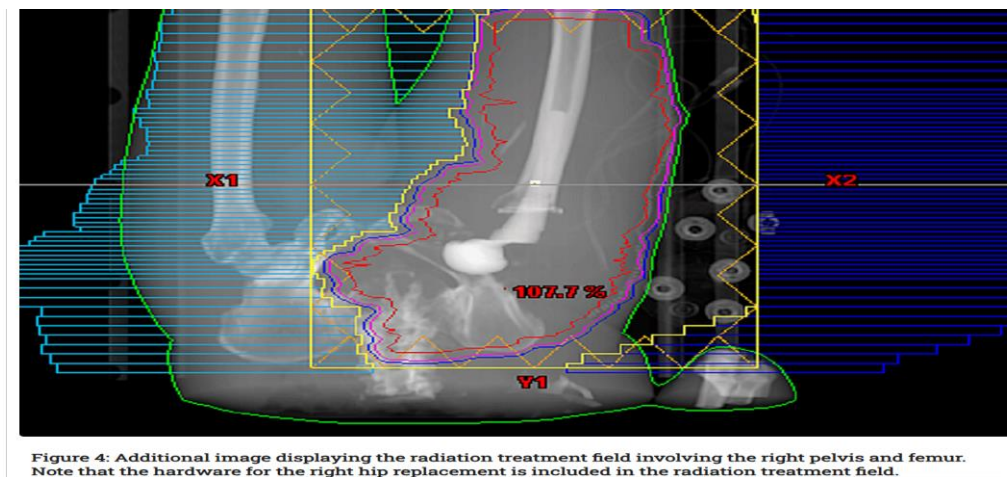
Figure 2: Radiation therapy immobilization device consisting of a vacuum bag was used for radiation planning and treatment. This device is used to help position the patient on a daily basis.

The patient underwent a course of primary radiation therapy to the right thigh encompassing the bleeding pseudotumor and received a total dose of 2000 cGy in 10 fractions prescribed to the 100% isodose line. The gross tumor volume (GTV) consisted of the pseudotumor covering the right hemipelvis from the superior aspect of the iliac bone to just superior to the femoral condyles. The clinical target volume (CTV), which accounts for setup errors and patient motion and ensures coverage for any setup variability, was a 1 cm margin around the GTV. The planning target volume (PTV), which accounts for planning or treatment delivery uncertainties, consisted of a 0.5 cm expansion beyond the CTV.

He was treated using a two-field technique consisting of an anterior and posterior field. The length of the PTV in the craniocaudal direction, which was over 46 cm, required the use of an extended source skin distance (SSD) technique utilizing two isocenters with an SSD of 120 cm for both the anterior (AP) and posterior (PA) fields. The maximum collimator setting for most linear accelerators is 40 cm x 40 cm, and extending the SSD allows the field to project larger so that a 46 cm field can be treated. A multi-leaf collimator (MLC) was used to shape the treatment field to ensure adequate target coverage. Medially, a strip of tissue was avoided to prevent circumferential radiation treatment of an extremity and subsequently decrease the risk of compartment syndrome and lymphedema. (Figure 3)



Ten megavoltage photons were chosen to obtain a homogenous dose distribution. A field-in-field technique was used further to improve the treatment plan's homogeneity and PTV coverage. (Figure 4).



After five days of treatment, a reduced amount of output from the surgical drains was observed. One week after the initiation of radiation therapy, the drains were noted to have minimal drainage and were subsequently removed. The patient's hemoglobin had been stable at around eight g/dL since the initiation of radiation therapy, and he had not received any PRBC units since that day. A few days after the completion of radiation therapy, the medical team described several episodes in which the wound dressing was saturated with blood. One week after treatment, the patient developed a dehiscence of the proximal portion of his right thigh fasciotomy wound, with the pseudotumor capsule penetrating through the skin. The patient's wound was eventually stabilized, and he was discharged from the hospital. He did not require any further blood transfusions, and he was discharged to rehabilitation and underwent continued dressing changes and wound checks twice daily. He was evaluated in the orthopedic clinic approximately a week after the completion of the radiation therapy and was doing well with no significant bleeding. A six-week follow-up was recommended to assess the impact of radiation therapy on the management of bleeding.

Approximately one month after treatment, the patient was readmitted with swelling and bleeding from the right hip. A CT of the pelvis revealed an extensive necrotizing gas-forming infection and abscess formations

involving almost the entire musculature in the right hemipelvis and multiple regions in the upper and mid-thigh with underlying hematoma components and myositis. The ICU team was consulted because of the patient's severe anemia and treatment for the necrotizing wound. The patient decided to pursue comfort care measures and not pursue surgical management, so he was discharged to hospice care.

Differential Diagnosis

1) Scute muscle hematoma, 2) Organizing hematoma-myositis ossificans 3) Vascular Malformations-Hemangiomas 4) Aneurysms-Pseudoaneurysms 5) Lymph nodes 6) Tumoral calcinosis

DISCUSSION

Currently, there are very few articles that have examined the role of radiation therapy as a definitive treatment option for pseudotumors, especially bleeding pseudotumors. Most studies have focused on managing pseudotumors, particularly highlighting radiotherapy and arterial embolization as treatment options. Pseudotumors are a rare but recognized complication in hemophilia, occurring in 1-2% of patients, and treatment for these tumors has included external beam radiation therapy.^[8] The suggested mechanism for pseudotumors' response to radiation therapy includes inflammation and fibrinogenesis within the microvasculature of the pseudotumor, which leads to thrombus formation, narrowing of the vessel lumen, and eventually fibrosis, resulting in the cessation of bleeding.^[7] The most common symptoms described in relation to pseudotumors of the pelvis were hip pain, a palpable mass, or paresthesia.^[11]

A study by Wiley et al. systematically reviewed the peer-reviewed literature to determine a pooled estimate of the incidence of pseudotumor and acute lymphocytic vasculitis-associated lesions (ALVAL) in adult patients with primary metal-on-metal (MoM) total hip arthroplasty or resurfacing. Fourteen eligible articles were identified, with a total of 13,898 MoM hips. The incidence of pseudotumor/ALVAL ranged from 0% to 6.5% of hips with a mean follow-up ranging from 1.7 to 12.3 years across the studies. The pooled estimated incidence of pseudotumor/ALVAL was 0.6%. The rate of revision for any reason ranged from 0% to 14.3%.^[12] Peri-articular soft-tissue masses or pseudotumors can also occur after large-diameter metal-on-metal (MoM) resurfacing of the hip and conventional total hip replacement (THR).^[13]

In a study by Bosker, 119 patients who underwent 120 MoM THRs with large-diameter femoral heads between January 2005 and November 2007 were evaluated. Outcome scores, serum metal ion levels, radiographs, and CT scans were obtained. Patients with symptoms or an identified pseudotumour were offered MRI and an ultrasound-guided biopsy.^[13] There were 108 patients (109 hips) eligible for evaluation by CT scan at a mean follow-up of 3.6 years (2.5 to 4.5); 42 patients (39%) were diagnosed with a pseudotumour. The hips of 13 patients (12%) were revised to a polyethylene acetabular component with small-diameter metal head. Patients with elevated serum metal ion levels had four times increased risk of developing pseudotumor.^[12] Pseudotumour diagnosis is not easy as patients remain asymptomatic for a long time. As it is a well-known complication, screening with images must be performed on all prosthesis with a metal-bearing surface.^[14] Also, delays in diagnosis contribute to an increased size of the pseudotumour, leading to more bone and soft tissue damage.^[11]

An article by Espander et al. reviewed the literature on pseudotumor cases and identified 28 patients who had been treated with radiation therapy. Sixteen patients (57.1%) underwent radiation therapy as the sole treatment

for a pseudotumor, while the remaining twelve (42.9%) received factor replacement therapy in addition to radiotherapy.^[7] Patients treated with factor replacement therapy and radiation therapy had fewer treatment failures than those patients treated with radiation therapy alone. Only one out of seven (14.3%) treatment failures occurred in patients who received both factor replacement and radiation therapy, while the rest (85.7%) received only radiotherapy.^[7] Radiotherapy, in conjunction with replacement therapy, typically factor VIII, appears to be especially effective for treating pseudotumors in certain regions. These include the lower limb and masses near the pelvis, where most treatment failures have been observed. Conversely, pseudotumors in the distal lower limb, upper limbs, or skull are generally more responsive to radiotherapy alone.^[7]

The preferred treatment for pseudotumors is typically surgical excision. When complete removal is not possible, alternative options, such as arterial embolization and, more recently, radiation therapy, should be considered.^[8]

The outcomes of radiotherapy for pseudotumors, as reported in the literature, differ based on the treatment approach used, the lesion's location, and the pseudotumor's size.

A broad range of radiation doses and various fractionation schemes have been used to treat pseudotumors. A dose-response relationship has yet to be studied.^[7] A literature review indicates significant heterogeneity in studies concerning radiotherapy dosage. Dosages ranging from as low as 500 cGy to as high as 3000 cGy, with or without factor VIII replacement therapy, have effectively treated patients with pseudo-tumors, resulting in the complete resolution of lesions.^[7,9] Additionally, the size of the pseudotumor affects the response to treatment, with lesions smaller than 10 cm typically obtaining a complete response to treatment, while two-thirds of lesions larger than 10 cm failed to respond to treatment.^[7]

In this case study, the patient was not diagnosed with factor VIII deficiency, but rather with a lower-risk myelodysplastic syndrome and a metal-on-metal left hip replacement. Currently, there is limited published data or case studies on the radiation treatment of pseudotumors in patients with lower-risk MDS and metal-on-metal hip replacements. Although the patient ultimately passed away due to bleeding from the pseudotumor, radiation therapy may have helped slow down the bleeding process, allowing the patient to be discharged from the hospital and possibly spend some quality time with his family.

CONCLUSION AND RESULTS

The literature offers limited information on managing pseudotumors, especially 'bleeding pseudotumors' that are not associated with factor deficiencies and after a metal-on-metal hip replacement. The case discussed illustrates an innovative approach to managing bleeding pseudotumors, which initially showed a positive response with stabilization of bleeding and a temporary cessation of transfusions during radiation therapy. This case highlights the efficacy of radiation therapy in addressing persistent bleeding from a pseudotumor, as it halted the bleeding and eliminated the need for continuous transfusions, thus enabling the patient's transition to hospice care. The patient did though ultimately expire secondary to the bleeding pseudotumour. Further research is necessary concerning the management and treatment of pseudotumors, especially 'bleeding pseudotumors', to aid clinicians in managing this condition.

REFERENCES

1. Amer M Zeidan, Uwe Platzbecker, Jan Philipp Bewersdorf, Maximilian Stahl, Lionel Adès, Uma Borate, et al. Consensus proposal for revised International Working Group 2023 response criteria for higher risk myelodysplastic syndromes. Blood. 2023;141(17):2047-2061.
2. Juan Jose Rodriguez-Sevilla, Vera Adema, Guillermo Garcia-Manero, Simona Colla. Emerging treatments for myelodysplastic syndromes: Biological rationales and clinical translation. Cell Rep Med. 2023;4(2):100940.
3. Aristoteles Giagoumidis. Current treatment algorithm for the management of lower-risk MDS. Hematology Am Soc Hematol Educ Program. 2017;2017(1):453-459.
4. Santini V. Treatment of low-risk myelodysplastic syndromes. Hematology Am Soc Hematol Educ Program. 2016;2016(1):462-469.
5. Filer JL, Berstock J, Hughes-Roberts Y, et al. Haemorrhagic Pseudotumour Following Metal-on-Metal Hip Replacement. Cureus. 2021;13(6):15541.
6. Sassoon AA, Barrack RL. Pseudotumour formation and subsequent resolution in metal-on-metal total hip arthroplasty following revision: instructional review and an illustrative case report with revision using a dual mobility design. Bone Joint J. 2016;98-B(6):736-740.
7. C Smekkes, B J M Schouten, M Nix, B F Ongkiehong, R Wolterbeek, B C H van der Wal, et al. Pseudotumor in metal-on-metal hip arthroplasty: a comparison study of three grading systems with MRI. Skeletal Radiol. 2018;47(8):1099-1109.
8. Espandar R, Heidari P, Rodriguez-Merchan EC. Management of haemophilic pseudotumours with special emphasis on radiotherapy and arterial embolization. Haemophilia. 2009;15(2):448-57.
9. Javier Lopez-Gomez ET. Management of the hemophilic pseudotumor of the abdomen: A rare pathological entity. Int J Surg Case Rep. 2014;5(11):789-92.
10. Rodriguez-Merchan EC. Hemophilic Pseudotumors: Diagnosis and Management. Arch Bone Jt Surg. 2020;8(2):121-130.
11. Barrientos C, Brañes J, Llanos JL, Martinez A, Barahona M. Surgical Treatment of Intrapelvic Pseudotumour after Hip Resurfacing Arthroplasty: Case Report and Literature Review. Case Rep Orthop. 2018; 2018:3808362.
12. Wiley KF, Ding K, Stoner JA, Teague DC, Yousuf KM. Incidence of pseudotumor and acute lymphocytic vasculitis associated lesion (ALVAL) reactions in metal-on-metal hip articulations: a meta-analysis. J Arthroplasty. 2013;28(7):1238-45.
13. Bosker BH, Ettema HB, Boomsma MF, Kollen BJ, Maas M, Verheyen CCPM. High incidence of pseudotumour formation after large-diameter metal-on-metal total hip replacement. J Bone Joint Surg Br. 2012;94(6):755-761.
14. Henry Wynn-Jones I, Rory Macnair, James Wimhurst, Nish Chirodian, Brian Derbyshire, Andoni Toms, et al. Silent soft tissue pathology is common with a modern metal-on-metal hip arthroplasty. Acta Orthop. 2011;82(3):301-7.