

## Pregnancy Affected By the Branch Retinal Artery Thrombosis: A Case Report

Saima Najam<sup>1\*</sup>, Syeda Ifra Hassan<sup>2</sup>, Syed Mohammad Oan Ul Hassan<sup>3</sup>, Essra Eltayeb Izzeldin<sup>4</sup>, Charbel BOU Chachra<sup>5</sup>

<sup>1</sup>Obgyn Consultant, Dr. Sulaiman Al Habib Hospital, Sweidi, Riyadh, Saudi Arabia

<sup>2</sup>Third Year Mbbs Student, Almaarifa University, Riyadh, Saudi Arabia

<sup>3</sup>Syed Mohammad Oan Ul Hassan, First Year Mbbs Student, Alfaisal University Riyadh, Saudi Arabia

<sup>4</sup>Obgyn Trainee, Dr. Sulaiman Al Habib Hospital, Sweidi Riyadh, Saudi Arabia

<sup>5</sup>FRSC Glasgow Consultant Ophthalmologist, Dr. Sulaiman Al Habib Hospital, Sweidi Riyadh, Saudi Arabia

---

**Citation:** Saima Najam, Syeda Ifra Hassan, Syed Mohammad Oan Ul Hassan, Essra Eltayeb Izzeldin, Charbel BOU Chachra. Pregnancy Affected By the Branch Retinal Artery Thrombosis: A Case Report. *Int Clin Med Case Rep Jour.* 2026;5(7):1-6.

**Received Date:** 04 July 2026; **Accepted Date:** 05 July 2026; **Published Date:** 06 July 2026

**\*Corresponding author:** Saima Najam, Obgyn Consultant, Dr. Sulaiman Al Habib Hospital, Sweidi, Riyadh, Saudi Arabia

**Copyright:** © Saima Najam, Open Access 2026. This article, published in *Int Clin Med Case Rep Jour (ICMCRJ)* (Attribution 4.0 International), as described by <http://creativecommons.org/licenses/by/4.0/>

---

### ABSTRACT

Pregnancy is associated with multiple changes in the maternal body to meet the growing needs of carrying the baby. Alterations in the coagulation system during pregnancy produce a hypercoagulable state to ensure haemostasis after delivery. Branch retinal artery occlusion (RAO) in pregnancy is rare but potentially vision threatening emergency.

We report a 38-year-old multigravida who was having idiopathic intra uterine growth restriction for which her induction of labour was planned. She presented at 37 weeks in the ophthalmology clinic with sudden decrease in the left eye vision. Her optic coherence tomography (OCT) was done, and inferio-temporal peripheral retinal artery occlusion was diagnosed. She was admitted in the intensive care unit (ICU) for thorough evaluation and was started on heparin infusion as her induction was planned on the same day.

However, her evaluation revealed no identifiable cause after complete cardiac, vascular and haematological work up. After 24 hours of initiation of heparin, 6 hours break was given and once PT and aPTT was normal, she was induced and delivered an IUGR female baby with good Apgar score normally. After 6 hours of the delivery prophylactic dose of enoxaparin sodium was given which was shifted to therapeutic dose after 24 hours. After the heparin the clinical improvement was noted which was confirmed by OCT after 8 days of the delivery. However oral anticoagulants were continued for 3 months.

**Keywords:** Pregnancy; Branch retinal artery occlusion; Thrombus; Anticoagulants; Optical coherence tomography

## INTRODUCTION

Pregnancy is known to be a hypercoagulable state due to increased concentration of factor VII, VIII, X and von Willebrand factors and significant increase in the fibrinogen. These changes are meant to protect the woman from the excessive bleeding after the childbirth. These changes may not completely return to baseline till 8 weeks postpartum.<sup>[1,2]</sup>

In pregnancy, due to these significant alterations in the haemostatic system, the pregnant woman is exposed to the risk of the thromboembolic event like DVT and pulmonary embolism and very rarely to the thrombosis of the ocular circulation.<sup>[4]</sup> Retinal artery occlusion is very rare in people younger than 30 years.<sup>[3]</sup> however, many females who were affected were found to be the carrier of the hereditary and acquired thrombophilia.<sup>[5,7,11]</sup> Other causes found were pre-eclampsia,<sup>[8]</sup> patent foramen ovale (PFO)<sup>[10]</sup> hemodynamic blockade secondary to the central retinal vein occlusion,<sup>[9]</sup> However, in the case study under discussion no other risk factor except the pregnancy was found like Baher et al.<sup>[6]</sup>

## CASE REPORT

We report a 38-year-old Saudi female who was married for 24 years, gravida 6 para 5, having 4 females and a male baby. All her babies were delivered at term, spontaneously and no antenatal, intra partum or post-natal complication was experienced earlier.

This pregnancy was spontaneously conceived, her anomaly scan was normal and her whole pregnancy was uneventful till 32 weeks. The growth scan at 32 weeks revealed the growth restriction manifested by weight which was at 9<sup>th</sup> centile and the head circumference (HC) and the abdominal circumference (AC) which was below 5<sup>th</sup> centile, as the amniotic fluid index and doppler was normal so she was put on surveillance after complete evaluation. Her blood pressure was normal, and she did not have protein Uria. Her platelets and liver function tests (LFTs) and renal function tests (RFTs) were also normal. She was diagnosed of having idiopathic intra uterine growth restriction (IUGR) due and her induction of labour was planned at 37 weeks.

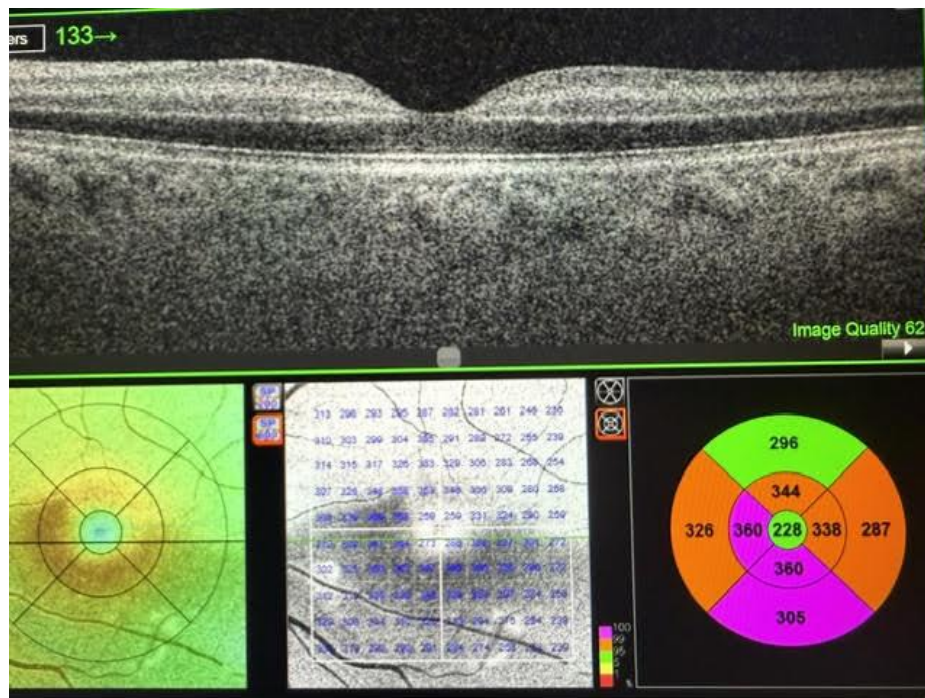
She presented at 37 weeks and 3 days with sudden reduced vision from the left eye in ophthalmology clinic. Her visual acuity was 20/40 in left eye as compared to 20/28 in the right eye. She was referred for urgent retinal examination. The exam was done on the dilated retina. Optic coherence tomography (OCT) radial and Optic coherence Tomo angiography (OCTA) was done. The examination revealed that Intra ocular pressure was within the normal range. No afferent papillary defect (APD) was found.

Confrontation visual field (CVF) revealed supero nasal visual field defect in left eye, anterior segment examination showed clear cornea. Anterior chamber was deep and quiet means no sign of inflammation, lens was clear, retina oculus sinister shows normal retina.

Impression was inferio temporal peripheral branch retinal artery occlusion.

Emboli seen at arterial bifurcation suggestive of cholesterol emboli.

OCT shows paracentral acute middle maculopathy (PAMM os), in the left eye, as shown in [Figure 1](#).



**Figure 1:** Optic coherence tomography on the day of presentation

She was admitted in intensive care, multi-disciplinary team (MDT) was involved. The team included: obstetrician, ophthalmologist, cardiologist, neurologist and immunologist.

After the agreement of the MDT the heparin infusion was started immediately and was continued for 24 hours. Urgent referrals were made for magnetic resonance imaging (MRI) and magnetic resonance angiography (MRA) to rule out the silent stroke.

Cardiac echocardiography was done.

Carotid doppler, and hyper coagulopathy work up was planned

The magnetic resonance angiography (MRA) demonstrates possible short segment occlusion/ flow limiting stenosis at cavernous sinus. Ophthalmic artery and anterior circulation cannot be evaluated due to the artifacts, no other intracranial abnormality was detected.

The doppler of the bilateral carotids also revealed no abnormality.

Her echo and later transoesophageal echo were done which was also found normal.

Doppler of both legs revealed no abnormality.

Her low-density lipoproteins (LDL) 5.51(2.59<) and triglycerides 2.28(1.7<) were elevated. However high-density lipoproteins (HDL) were within the normal range. Anti-cardiolipin antibodies, IGG and IGM, both were negative, anti-thrombin iii activity, and anti C was also found within the normal range.

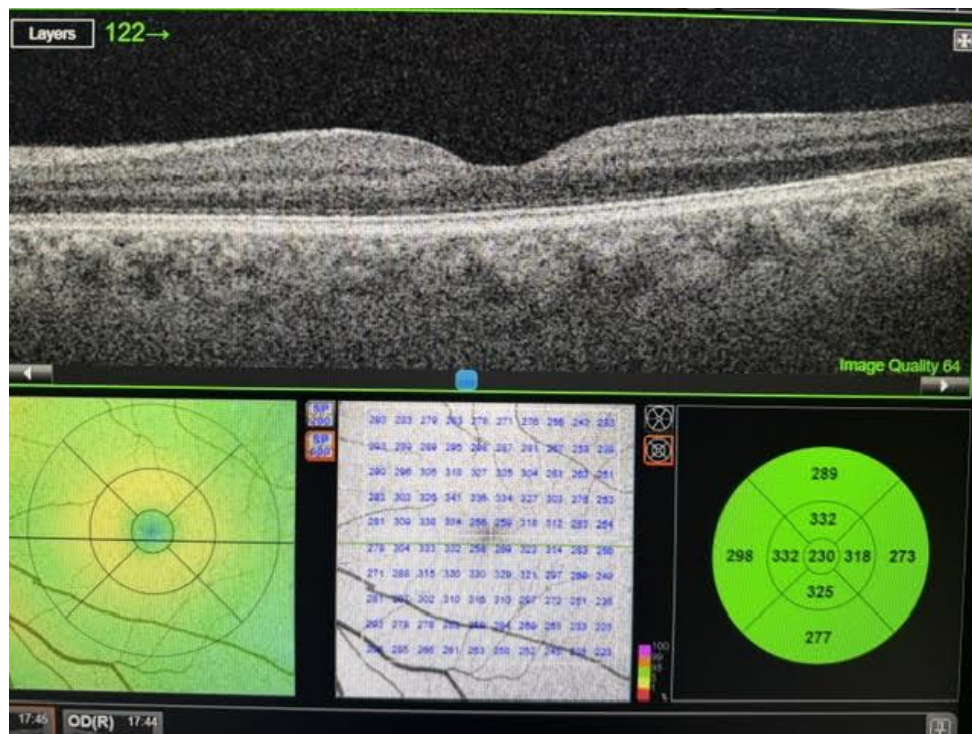
After 6 hours of initiation of the heparin infusion prothrombin time (PT) and activated partial thromboplastin time (aPTT) was done and after consultation with the team patient was planned to go for the induction.

Her bishop was 6 so was induced with Propess (dinoprostone, which is a synthetic prostaglandin E2) she went in labour after 6 hours of induction, within 90 minutes from 4 cm she was fully dilated and delivered with in next 20 minutes as occipito-posterior. It was a baby girl, 2280 grams and Apgar score was 7/10 and 9/10, after one and five minutes respectively. After 6 hours of the delivery, she was started with prophylactic dose of enoxaparin sodium, and which was converted to therapeutic dose after 24 hours. Her delivery and immediate post-natal recovery were uneventful. She was discharged on therapeutic dose of the enoxaparin sodium.

She was seen on 8<sup>th</sup> post-natal day and was found to be recovering well was having marked improvement in the vision, uterus was involuting normally and no excessive bleeding was noted, she was referred to the ophthalmology for the evaluation.

Her visual acuity was 20/28 in the left eye as compared to 20/40 earlier.

Her OCT after 8 days reported to be significantly improved as shown in **Figure 2**.



**Figure 2:** OCT on day 8 of the delivery

Oral anticoagulant (edoxaban 60 mg) was started and after 2 days of overlapping the enoxaparin sodium was stopped.

The oral anticoagulants were continued for 3 months and were stopped thereafter.

She was seen after 2 weeks of cessation of the anticoagulants and no residual defect was noted.

## DISCUSSION

Retinal artery occlusion is the vision threatening emergency as can lead to the permanent vision loss and therefore requires prompt assessment. The blockade can be central or in one of its branches. The risk factors for

the BRAO are pre-eclampsia, hypercholesterolemia, obesity, thrombophilia and diabetes mellitus. The main cause of the thrombus found in the epidemiological studies is secondary to the cardiac valvular disease, atrial fibrillation and the carotid artery was found to be the most common source of the endogenous emboli.<sup>[10]</sup>

The patient under discussion had only hypercholesterolemia as a risk factor and no other cause was found. The patient in the study was 38 years of age, the same age group was reported by Bahar MM and in one of the cases by Kurtz WS.<sup>[6,7]</sup> while Kurtz, in another case, Katerina torsi, Jurgens and Pipolo found it in women of 32,29, 30, 32 and 28 years of age respectively.<sup>[7,8,9,10]</sup> However, Chewa raja found it in woman of 40 years of age.<sup>[11]</sup> Retinal artery occlusion was mostly found in first half of the pregnancy i.e. less than 20 weeks<sup>[7,9,10,11]</sup> which is contrary to what we found in the case study under discussion however in one case report it was found at 31 weeks and 5 days<sup>[8]</sup> and in another at 36 weeks<sup>[6]</sup> which is closer to the gestational age of the women under study. We could not find any reason for the branch retinal artery occlusion in the patient after complete evaluation. Similar case was reported by BAHAR and colleagues<sup>[6]</sup> who also could not find any other reason except pregnancy. The Ocular vascular occlusion is very rare and its extremely rare to have it without any other additional cause with pregnancy.

As most of the cases were reported by the ophthalmology department so very few are followed up till delivery. We found only one case followed till the delivery and that patient had emergency caesarean section<sup>[6]</sup> contrary to our patient who though having IUGR baby, responded well to the induction and delivered vaginally.

## **CONCLUSION**

BRAO is one of the causes of the visual loss in pregnancy, however early recognition of the correct diagnosis is the integral part which can help to initiate thorough evaluation and treatment of the patient with the help of the multidisciplinary team. This is pivotal to ensure the safety of both the mother and the baby.

## **ACKNOWLEDGEMENT**

The authors would like to express their special gratitude to the intensive care team, ophthalmologist, cardiologist, neurologist, haematologists and the whole Obgyn team for their prompt response, un wavering support and exceptional multidisciplinary care.

Their dedication to providing outstanding care to all patients and especially to the patient described in this study is deeply appreciated.

## **CONFLICT OF INTEREST**

None to declare

## **FINANCIAL DISCLOSURE**

None to disclose

## REFERENCES

1. Bremme KA. Haemostatic changes in pregnancy. Best Pract Res Clin Haematol. 2003;16:153-68.
2. James AH. Venous thromboembolism in pregnancy. Arterioscler Thromb Vasc Biol. 2009;29:326-31.
3. Chung YR, Kim JB, Lee K, Lew HM. Retinal artery occlusion in a healthy pregnant patient. Korean J Ophthalmol. 2008;22(1):70-1.
4. Nolan TE, Smith RP, Devoe LD. Maternal plasma D-dimer levels in normal and complicated pregnancies. Obstet Gynecol. 1993;81:235-8.
5. James AH. Thrombosis in pregnancy and maternal outcomes. Birth Defects Res C Embryo Today. 2015;105:159-66.
6. Bahar MM, Ghalandarpoor-Attar SN, Shabani A, et al. Idiopathic combined retinal vessels occlusion in a pregnant woman: a case report. J Med Case Rep. 2022;16:191.
7. Kurtz W, Glueck C, Hutchins R, Sisk R, Wang P. Retinal artery and vein thrombotic occlusion during pregnancy: markers for familial thrombophilia and adverse pregnancy outcomes. Clin Ophthalmol. 2016; 10:935-38.
8. ScB KT, Wirostko W, Palatnik A, Klatt T. Pre-eclampsia and branch retinal artery occlusion in a 29-year-old primigravida with type 1 diabetes: A case report. Case Rep Womens Health. 2024;43: e00643.
9. Jürgens L, Yaici R, Schnitzler CM, Fleitmann AK, Roth M, Schröder K, Guthoff R. Retinal vascular occlusion in pregnancy: three case reports and a review of the literature. J Med Case Rep. 2022;16(1):167.
10. PipoloGR, Neto CAM, Pereira PIR, Torres R, Barreto G, Moreira CA. OCT Angiography Use in Pregnancy: Branch Retinal Artery Occlusion Associated with Patent Foramen Ovale – A Case Report and Multimodal Analysis. Case Rep Ophthalmol 2023;14:29-33.
11. Chewa Raja JS, Redzuan MA, Rafique Ali AA. Branch Retinal Artery Occlusion as a Presentation of Seronegative Antiphospholipid Syndrome in Pregnancy. Cureus. 2024;16(11): e74198.