

A Case of Invasive Aspergilloma Masquerading as Ethmoidal Sinus Tumour in a Patient in Tertiary Cancer Centre in North India

Vijeta Bajpai^{1*}, Rahul Sarode¹, Sujit Bharti¹, Ipsita Dhal², Swagnik Chakrabarti³

¹Department of Microbiology, MPMCC and HBCH, Varanasi, Uttar Pradesh, India

²Department of Oncopathology, MPMCC and HBCH, Varanasi, Uttar Pradesh, India

³Department of Head and Neck cancer, MPMCC and HBCH, Varanasi, Uttar Pradesh, India

Citation: Vijeta Bajpai, Rahul Sarode, Sujit Bharti, Ipsita Dhal, Swagnik Chakrabarti. A Case of Invasive Aspergilloma Masquerading as Ethmoidal Sinus Tumour in a Patient in Tertiary Cancer Centre in North India. *Int Clin Med Case Rep Jour.*2023;2(13):1-5.

Received Date: 24 July, 2023; **Accepted Date:** 26 July, 2023; **Published Date:** 28 July, 2023

***Corresponding author:** Vijeta Bajpai, Department of Microbiology, Mahamana Pandit Madan Mohan Malviya cancer Centre/Homi Bhabha Cancer Hospital, (A unit of Tata Memorial Centre, Mumbai), Varanasi, Varanasi – 221 005, Uttar Pradesh, India

Copyright: © Vijeta Bajpai, Open Access 2023. This article, published in *Int Clin Med Case Rep Jour* (ICMCRJ) (Attribution 4.0 International), as described by <http://creativecommons.org/licenses/by/4.0/>.

ABSTRACT

Invasive aspergillosis of the paranasal sinuses is an uncommon entity and often misdiagnosed with tumour or other malignancy. We report a rare case of aspergilloma mimicking as paranasal sinus tumour in a patient referred from a hospital in rural India. Patient was initially diagnosed as paranasal sinus tumour in other hospital and referred to our hospital which is a tertiary cancer centre. Finally, identification of *Aspergillus flavus* infection referred was done by the histopathological A newly established ,tertiary cancer centre examination and growth in fungal culture from the biopsy done from paranasal sinus. The patient was treated with intravenous voriconazole for 2 weeks and recovered completely after follow up.

Keywords: Tumour; Cancer; North India

CASE REPORT

A 55-year-old male referred from a rural area to Out-Patient-Department of Homi-Bhabha- Cancer-Hospital (a unit of Tata Memorial Centre, Mumbai), Varanasi with complaints of pain in the right eye for 6 months. There was no history of fever, headache, loss of vision and cranial nerve symptoms mainly the optic nerve and ocular motor nerves. Patient is a chronic tobacco chewer and known case of hypertension, currently on antihypertensive medication (Amlodipine 5mg BD). There was no history of diabetes, anorexia and significant weight loss. On ophthalmic examination lateral movement of right eye was restricted. No obvious growth seen outside and around the right eye. The findings of his lab data were unremarkable except few biochemistry parameters (Borderline decreased serum sodium 131mmol/l, serum chloride 95 mmol/l and serum uric acid 2.5 mg/dl) In view of suspicion of malignancy, Magnetic Resonance Imaging (MRI) brain was done which showed heterogenous enhancing extra axial predominantly solid T2 hypointense mass in the sphenoid and parasellar region, invading the right cavernous sinus and completely encasing the cavernous part of right internal carotid artery, erosion of greater wing of sphenoid, posterior aspect of lamina, anterior wall of carotid canal and clivus

on the right side. A mass lesion was seen into right orbital apex in the inferior and medial aspect. Mass noted in the extraconal compartment with no invasion into intraconal compartment, mild compression of inferior rectus muscle medially extending into middle cranial fossa with invasion of right temporal fossa.

To rule out malignancy, further endoscopic examination of nasal cavity and paranasal sinuses was done by head and neck surgical team. A mass lesion was found behind posterior ethmoidal sinus on right side from which multiple punch biopsies were taken, also surgical excision in form of right bullectomy and posterior ethmoidectomy was done at the time of endoscopy. The punch biopsy samples were sent to laboratory for histopathological and microbiological examination.

Histopathology of tissue sample was suggestive of granulomatous inflammation with fibro-collagenous tissue infiltrated by lympho-plasmocytic infiltrates and extensive foreign body giant cells. A few of the giant cells contained broken up fungal hyphae in the cytoplasm. Areas of necrosis were identified. No evidence of malignancy was seen. In microbiology, KOH mount of tissue sample showed, plenty of pus cells, plenty of RBC with hyaline and fragment thin septate filaments. On culture in Sabouraud's Dextrose Agar showed growth of yellow green, velvet to cotton growth in obverse surface after 24 incubation in 37^o c temperature. Further identification was done in LPCB and the diagnosis of *Aspergillus flavus* was made on the basis of septate hyphae with uniseriate and biseriante phialides over the vesicle with long conidiophore especially at the apex of vesicle. (Figure 1) The anti-fungal medication, intravenous voriconazole, was administered immediately. Patient symptom recovered after two weeks of therapy and patient discharged with oral therapy of Posaconazole for next 3 weeks days. Postoperative follow-up showed no recurrence of aspergilloma mass and the pain of right eye also improved, also the vision was lateral aspect improved.

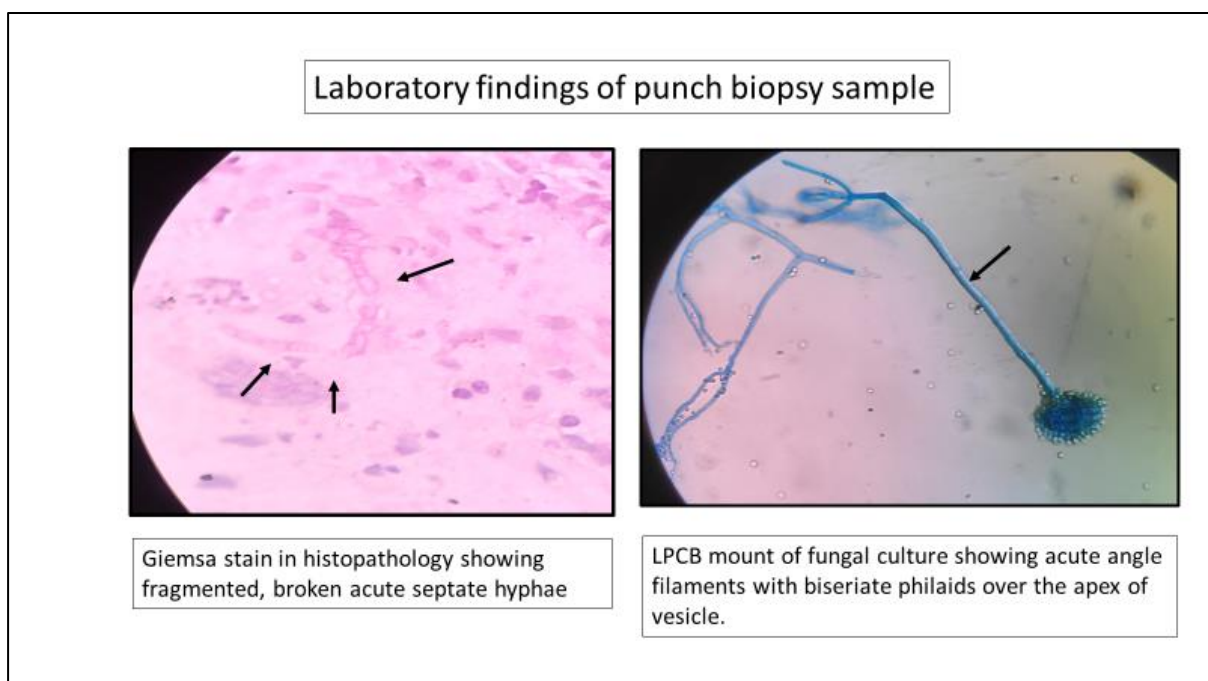


Figure.1

DISCUSSION

Paranasal sinus aspergillosis as an aggressive disease with high invasive patterns and may be misdiagnosed as benign tumours. Extension of aspergilloma into the cavernous sinus and completely encasing the internal carotid artery has only been described in a few reports in the literature.^[1,2] Though this entity is more common in immunocompromised patients; however, immunocompetent patients may also suffer from this condition. Here in, we presented a case of ethmoid sinus aspergilloma with erosion of para-sellar floor and right cavernous sinus with lateral restricted visual symptoms in a patient which was misdiagnosed as the tumour and referred to our cancer centre. Therefore, to achieve better prognosis and survival of these patients, clinicians must aware of this distinct manifestation to rule out between malignancy and fungal infection.

Aspergillus species is a commensal flora of respiratory tract and external auditory canal which involves brain through contiguous or hematogenous spread. The most of the patients getting infected are immune-compromised hosts (those with organ transplant/AIDS/long-term steroids).^[3,4,5] However, an increasing number of cases are identified in immune-competent population.^[6] Clinical characteristics of patients with paranasal sinus tumour caused by aspergilloma is summarized in (Table-1). Classically, patients of paranasal sinus aspergillosis present with signs and symptoms of space occupying lesion with/without a history of loss of visual acuity in setting of an immune-compromised patient. The common presenting symptoms are nasal congestion, headache, periorbital pain, seizures, and cranial nerve deficits.^[7,8,9] Granulomatous lesion of aspergilloma poses a diagnostic challenge to clinicians because of their maximum resemblance to a benign lesion, or even malignancy. this is associated with having high rates of mortality and morbidity, but early diagnosis and prompt treatment with surgery and antifungal drugs may cure a significant proportion of patients. Advanced radio imaging offers an opportunity for early diagnosis, but findings are minimal and can be indistinctive. On the basis of radiological appearance, meningioma or tuberculoma is considered in differential earlier than fungal granuloma. Therefore, it is very essential to keep the differential diagnosis of invasive aspergilloma in mind before giving any immunocompromised therapy to the patient.

There are no specific guidelines for management of para nasal sinus aspergilloma, the commonly recommended regimen is surgical excision followed by antifungal treatment. Intravenous Voriconazole is recommended as monotherapy for invasive aspergillosis as per the recommendation given by Infectious Diseases Society of America and American Thoracic Society.^[10,11] Patients who had shown adverse reactions to this drug may be managed with liposomal amphotericin B.^[11] Early diagnosis and treatment may help in limiting mortality and morbidity.

Review of literature: Clinical characteristics of patients with paranasal sinus tumour caused by aspergilloma.

Ref	Age	Initial visual acuity	Symptom	Administration of steroid	Administration of antifungal agents	Surgical excision or resection	Final visual acuity	Outcome	Systemic disease
Our case	46/M	lateral movement of eye was restricted	Pain in right eye	Yes	voriconazole	yes	Recovered	Alive	Hypertension
2019 (15 cases)	Median age 40.2 ± 15.97 (1–79)	Visual disturbance (38.9%),	Headache (60%), Fever (23.3%), Limb weakness, (14.4%), Seizure (10%), Altered sensorium (6.7%), Nasal discharge (2.2%), Loss of smell (1.1%), Wound discharge (1.1%), Hearing loss (1.1%)	NO	AMB, voriconazole, fluconazole, or flucytosine as monotherapy or in combination	Yes (>50%)	unremarkable	Death in 12	No
2018	61/F	Counting finger/20	Ptosis, Proptosis, Headache, Periorbital pain, Frozen eye movement	No	Voriconazole	Yes	No light perception Alive	Alive	Type 2 DM
2016	43/M	No light perception	Weakness of vision, Ptosis, Proptosis, Impaired eye movement	No	AMB, Caspofungin	Yes	No light perception	Alive	No
2016	57/M	Unremarkable	Double vision, Ophthalmoplegia, Visual disturbance	Yes	AMB	Yes	Unremarkable	Alive	Cutaneous lymphoma
2009	64/M	Counting finger/50 cm	Rhinorrhea, diplopia, headache, ptosis, ophthalmoplegia	Yes	AMB	Yes	20/63	Alive	Type 2 diabetes mellitus
2006	52/M	No light perception	Pain, watering, frequent bleeding with discharge, rapidly increasing mass	Unremarkable	NO	Yes	Unremarkable	Unremarkable	HIV
1991	65/M	20/25	Retro-orbital pain, diplopia, headache, impaired eye movement, Blepharoptosis	Yes	AMB	No	Unremarkable	Death	No

CONCLUSION

A high index of suspicion for invasive aspergilloma should exist for patients with space occupying lesions in paranasal sinus. Early diagnosis, aggressive surgical excision, and a course of promptly initiated antifungal therapy are associated with a better prognosis.

REFERENCES

1. [Chang YM, Chang YH, Chien KH, Liang CM, Tai MC, Nieh S, et al. Orbital apex syndrome secondary to aspergilloma masquerading as a paranasal sinus tumor: A case report and literature review. *Medicine \(Baltimore\)*. 2018;97\(30\):e11650.](#)
2. [Mishra A, Prabhuraj AR, Shukla DP, Nandeesh BN, Chandrashekar N, Ramalingaiah A, et al. Intracranial fungal granuloma: a single-institute study of 90 cases over 18 years. *Neurosurg Focus*. 2019 01;47\(2\):E14.](#)
3. [Innate immunity to Aspergillus species. - PubMed - NCBI. 2020](#)
4. [Aspergillus Infections in Transplant and Non-Transplant Surgical Patients. 2020](#)
5. [Silva RF e. Fungal infections in immunocompromised patients. *J Bras Pneumol*. 2010;36\(1\):142–147.](#)
6. [Invasive aspergillosis in an immunocompetent host. 2020.](#)

7. Sharma P, Bhaisora KS, Pandey S, Srivastava AK, Pani KC, Sardhara J, et al. Aspergilloma Mimicking Olfactory Groove Meningioma. Asian J Neurosurg. 2018;13(2):436–439.
8. Plewa MC, Tadi P, Gupta M. Cavernous Sinus Thrombosis. In: StatPearls [Internet]. Treasure Island (FL): StatPearls Publishing; 2020
9. Shamim MS, Siddiqui AA, Enam SA, Shah AA, Jooma R, Anwar S. Craniocerebral aspergillosis in immunocompetent hosts: Surgical perspective. Neurol India. 2007;55(3):274.
10. IDSA Updates Guidelines for Invasive Aspergillosis - Infectious Disease Advisor . 2020
11. New ATS Clinical Practice Guideline: Diagnosing Fungal Infections. 2020