

A Double Whammy-Stent Fracture and Dislodgement during PCI

Punish Sadana* and Preeti Sharma

Director of Cardiology, Max Superspeciality Hospital, India

Abstract

Coronary stent fracture is a rare complication of stent implantation. The reported incidence of stent fracture among present drug-eluting stents from various studies ranges from 1% to 8%. Coronary stent dislodgement and embolization is also a rare complication in the current era of percutaneous coronary angioplasties. The incidence of stent loss has significantly reduced as stents were pre-crimped in factory itself. It is often benign and managed conservatively by retrieval by smaller balloon or snare, deployment at appropriate location or crushing of the stent, rarely requiring surgical intervention. We present a case of Elderly female with both the complications during PCI managed effectively.

Keywords: Stent loss/Dislodgement; Stent embolization; PCI (Percutaneous coronary intervention); In-stent restenosis; Stent fracture (SF), Stent thrombosis

Introduction

Coronary stent fracture is a relatively rare complication of stent implantation. The reported incidence of stent fracture among present drug-eluting stents from various data ranges from 1% to 8%. Literature shows that the risk for stent fracture was higher in right coronary artery location, increased vessel tortuosity severe angulation prior to stenting, use of overlapping stents, and use of longer stents. It can cause thrombosis, ISR, aneurysm. The incidence of stent loss has significantly reduced as stents were pre-crimped in factory itself. It is often benign and managed conservatively by retrieval by smaller balloon or snare, deployment at appropriate location or crushing of the stent, rarely requiring surgical intervention. However, dreaded complications can occur if the stent embolizes into the vital organs.

Case Report

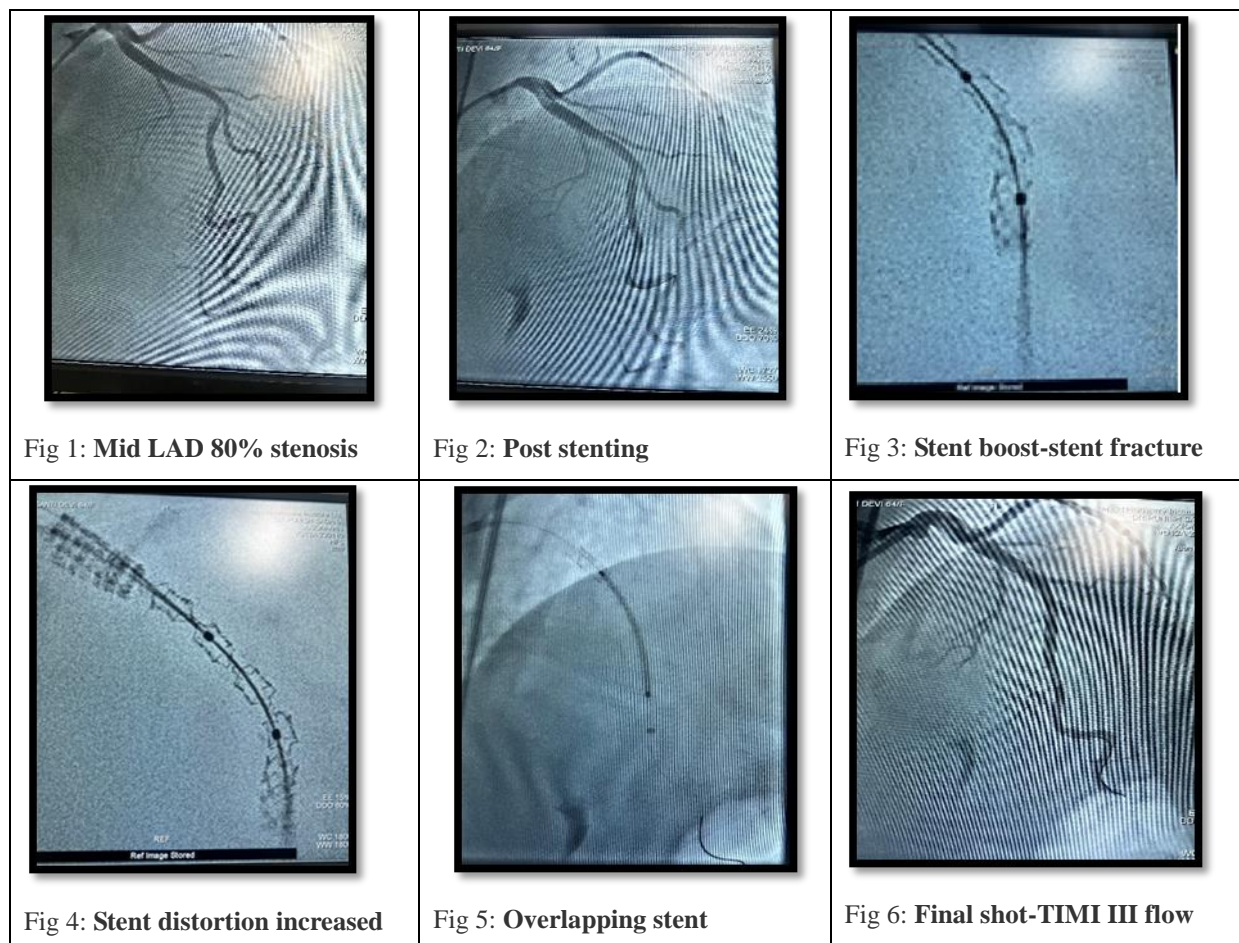
A 64 year old female a known case of Diabetes Mellitus, hypertension and hypothyroidism presented with chest pain on exertion for two months for two hours duration. On Evaluation her vitals were stable, systemic examination doesn't showed any abnormality. ECG showed sinus rhythm with no significant st-t changes and echo showed EF of 55%.

Citation: Punish Sadana, Preeti Sharma. A Double Whammy-Stent Fracture and Dislodgement during PCI. *Int Case Rep Jour.* 2025;4(1):1-4.

Received Date: 10 July, 2025; **Accepted Date:** 12 July, 2025; **Published Date:** 14 July, 2025

***Corresponding author:** Punish Sadana, Director of Cardiology, Max Superspeciality hospital, Dehradun, India, Tel: +91 8171517788

CAG done which revealed single vessel disease with mid LAD 80% stenosis (Figure 1). Patient was taken for PTCA to LAD. Stenting was done with 3 mm × 24 mm DES. Post dilation done with 3 mm balloon upto 18 atm. Check shot revealed some haziness and stent boost and IVUS revealed stent fracture (Figure 2,3,4). Then 3 mm × 12 mm DES was taken to cover the fractured part but it was small in length, while taking it out it got dislodged in distal left main and prox LAD so deployed there itself. In the next angio shot 3 mm × 12 mm DES dislodged slight distally, it was post dilated with 3.5 mm × 8 mm balloon and fixed there itself (Figure 5). There was severe spasm in radial artery and during maneuvering whole of the system including guiding catheter and wire came out. Right femoral puncture done and Left coronary artery was hooked using 6F EBU catheter. Several attempt were made to cross guide wire but failed so double lumen catheter taken to cross the distorted stent. With the help of guide liner another 3 mm × 33 mm DES deployed from proximal to mid LAD with TIMI III flow (Figure 5,6).



Discussion

Coronary stent fracture is a relatively uncommon and rare complication of stent implantation. The reported incidence of stent fracture among drug-eluting stents ranges from 1% to 8%. Literature shows that the risk for stent fracture was higher in right coronary artery location, increased vessel tortuosity, angulation prior to stenting, use of overlapping stents, and use of longer stents, higher post dilation pressure. Stent fracture does not happen equally among different stents, and more frequent stent fracture was seen with stainless steel stents comparing with cobalt-chromium platform stents signaling less sturdiness with stainless stents, which should somewhat explain why cobalt-chromium stents are associated with improvement of clinical outcomes. There is

no consensus on the best diagnostic imaging modality for detection of stent fractures, but conventional angiography is not sufficiently sensitive for this purpose. Other imaging modalities can be used, including IVUS, stent boost, MDCT, and OCT. Depending on the diagnostic tool that is used, numerous classifications of SF have been suggested. As per Allie *et al.* there are four types of SF- type I - single strut fracture, type II - multiple strut fractures at different sites, type III - complete transverse linear fracture without displacement and type IV –complete stent displacement. There is an additional type V with formation of a gap between stent fragments by Jaff *et al.* It may be asymptomatic, can cause acute vessel closure due to thrombosis, ISR, aneurysm formation and TLR. Treatment includes conservative management, re-stenting, DEB (Drug Eluting Balloon) or surgery.

Among coronary devices, Coronary stents are most commonly embolized, with an incidence of approximately 0.9%-8.3%, during Percutaneous Coronary Interventions (PCI). Stent dislodgement was more frequent in old times when stents were crimped manually onto the balloon but now a days they were pre-crimped in factory itself and dislodgement rates are drastically reduced. Although rare, stent dislodgment can cause cerebral embolism or intracoronary thrombosis and lead to life threatening complications like Cerebrovascular Accident (CVA) and Myocardial Infarction (MI). Angulated, severely calcified lesion, inadequate lesion preparation, non-coaxial guide catheter, forceful pushing or pulling of the stents are the common causes of stent dislodgement. It can be partial or complete stent loss with or without guide wire in situ. Position of dislodged stent also is very important. Management varies from retrieval using small balloon, multiple wire technique or snare or surgical, crushing the stent along the vessel wall, sequential dilation and deploying the stent there itself.

Conclusion

Coronary artery stent dislodgement and fracture are rare but sometimes fatal complications during PCI. Stent fracture treatment includes conservative treatment, DEB or re-stenting and in rare case bypass surgery. Treatment of stent dislodgement includes retrieval by various available techniques, deploying it there itself or crushing against the vessel wall.

References

1. [Shaikh F, Maddikunta R, Djelmami-Hani M, Solis J, Allaqaband S, Bajwa T. Stent fracture, an incidental finding or a significant marker of clinical in-stent restenosis? Catheter Cardiovasc Interv. 2008;71\(5\):614-8.](#)
2. [Betriu A, Masotti M, Serra A, Alonso J, Fernández-Avilés F, Gimeno F, et al. Randomized comparison of coronary stent implantation and balloon angioplasty in the treatment of de novo coronary artery lesions \(START\): A four-year follow-up. J Am Coll Cardiol. 1999;34\(5\):1498-506.](#)
3. [Al Suwaidi J, Holmes DR, Salam AM, Lennon R, Berger PB. Impact of coronary artery stents on mortality and nonfatal myocardial infarction: meta-analysis of randomized trials comparing a strategy of routine stenting with that of balloon angioplasty. Am Heart J. 2004;147\(5\):815-22.](#)
4. [Bae JH, Hyun DW, Kim KY, Yoon HJ, Nakamura S. Drug-eluting stent strut fracture as a cause of restenosis. Korean Circ J. 2005;35:787-9.](#)
5. [Alexopoulos D, Xanthopoulou I. Coronary stent fracture: how frequent it is? Does it matter? Hellenic J Cardiol. 2011;52\(1\):1-5.](#)

6. [Brilakis ES, Maniu C, Wahl M, Barsness G. Unstable angina due to stent fracture. J Invasive Cardiol. 2004;16\(9\):545.](#)
7. [Alomar ME, Michael TT, Patel VG, Altomare CG, Rangan BV, Cipher D, et al. Stent loss and retrieval during percutaneous coronary interventions: a systematic review and meta-analysis. J Invasive Cardiol. 2013;25\(12\):637-41.](#)
8. [Nikolsky E, Gruberg L, Pechersky S, Kapeliovich M, Grenadier E, Amikam S, et al. Stent deployment failure: reasons, implications, and short- and long-term outcomes. Catheter Cardiovasc Interv. 2003;59\(3\):324-8.](#)
9. [Laarman G, Muthusamy TS, Swart H, Westendorp I, Kiemeneij F, Slagboom T, et al. Direct coronary stent implantation: safety, feasibility, and predictors of success of the strategy of direct coronary stent implantation. Catheter Cardiovasc Interv. 2001;52\(4\):443-8.](#)
10. [Hussain F, Moussa T. Migration of an embolized deployed stent from the left main with subsequent crushing: a new use for the IVUS catheter? J Invasive Cardiol. 2010;22\(2\):E19-22.](#)
11. [Soon CY, Chong E, Sangiorgi GM. A challenging case of dislodged stent retrieval with the use of Goose neck snare kit. Catheter Cardiovasc Interv. 2010;75\(4\):630-3.](#)