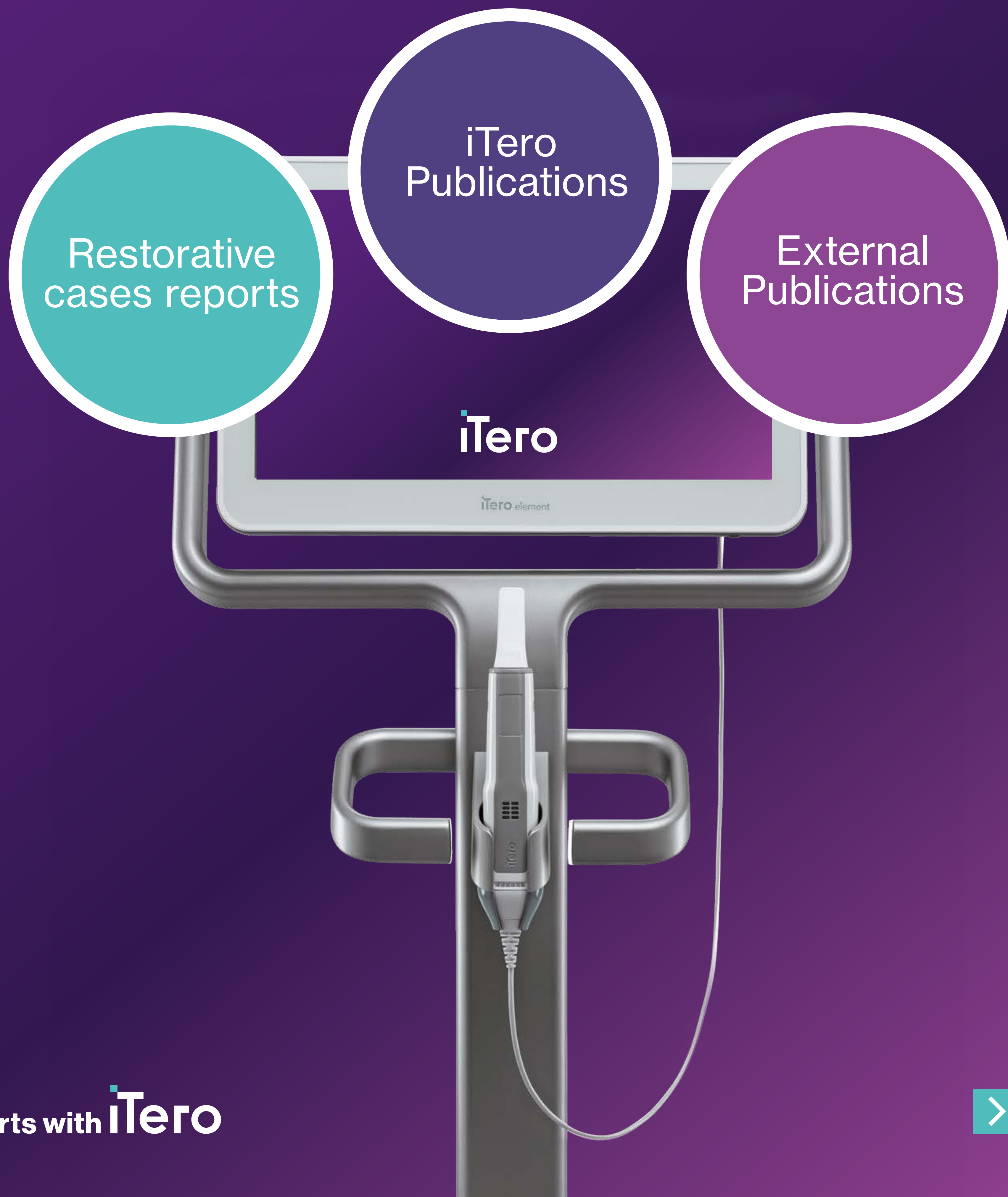

iTero Compendium



it starts with iTero



click on the below to be redirected to the associated category

- Restorative cases reports >
- iTero Publications >
- External Publications >

click on the below to be redirected to the associated section

Restorative cases reports

- Implant supported edentulous rehabilitation

Dr. Andrea Agnini
- 3 unit Bridge - #25 - #27

Dr. Gianluca Plotino
- Implant-supported bridge - #14 - #16

Dr. Gianluca Plotino and Dr. Ferruccio Torsello
- Single Crown - #25 / Implant-supported crown - #26

Dr. Gianluca Plotino and Dr. Ferruccio Torsello

iTero Publications

External Publications

click on the below to be redirected to the associated section

Restorative cases reports >

iTero Publications >

- A Fully Integrated Diagnostic Process Through Advances in Scanning Technology >
- Near infrared imaging (NIRI) technology in dentistry - iTero Element 5D >
- Best practices - Restorative dentistry and digital scanning with the iTero Element Intraoral Scanner. >

External Publications >

click on the below to be redirected to the associated section

Restorative cases reports >

iTero Publications >

External Publications >

- Digital vs. conventional implant prosthetic workflows: a cost/time analysis >
- Patient-centered outcomes comparing digital and conventional implant impression procedures >
- Time-Efficiency Analysis Comparing Digital and Conventional workflows for Implant Crowns >
- External publications evaluating iTero and it's accuracy under different conditions >

Implant supported edentulous rehabilitation

Dr. Andrea Agnini and Dr. Alessandro Agnini

Chief Complaint :

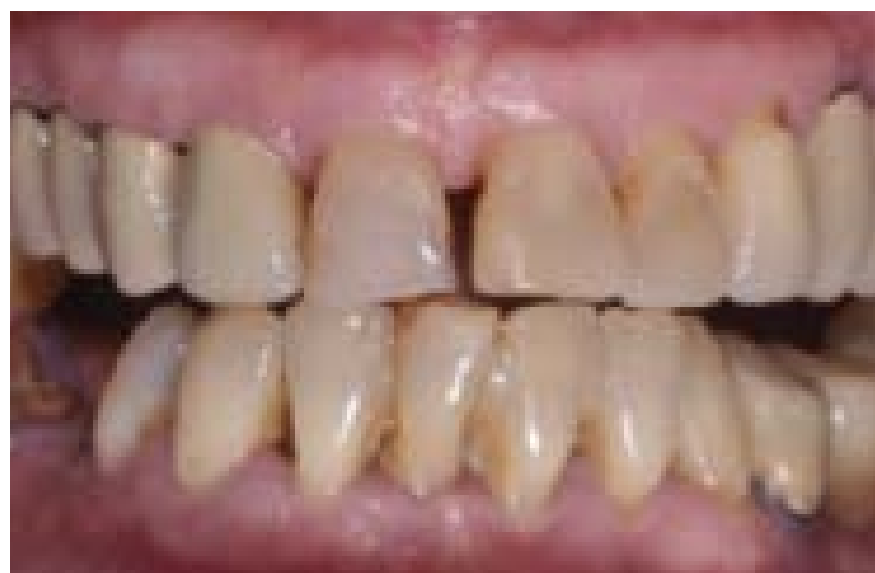- Advanced periodontitis, with generalized tooth mobility and patient discomfort
- Patient didn't want any removable prosthesis, not even as temporary solution



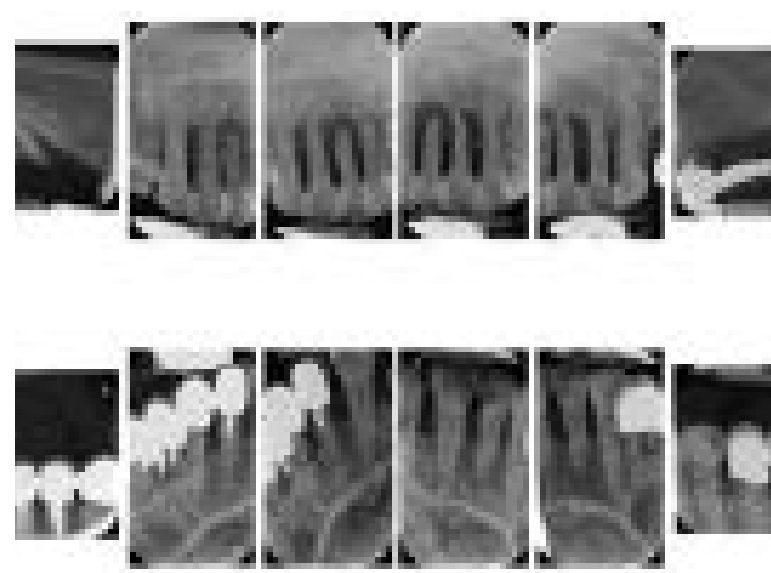
Initial clinical status and treatment outcome

Before restoration:

Intraoral photograph

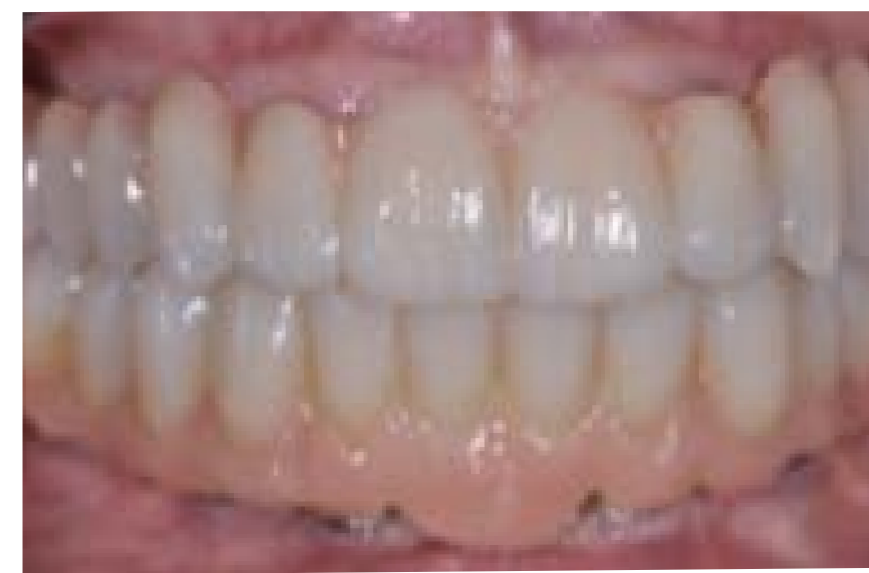

X-Ray

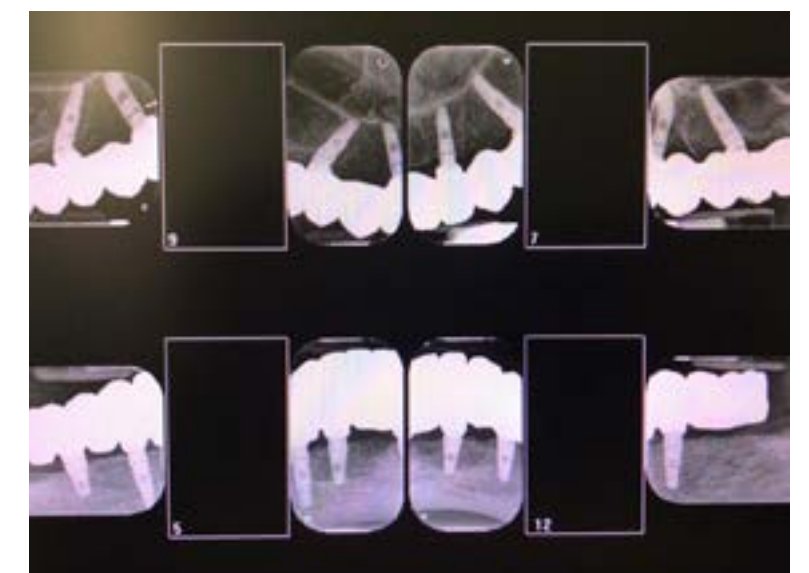

After restoration:

Intraoral photograph




X-Ray

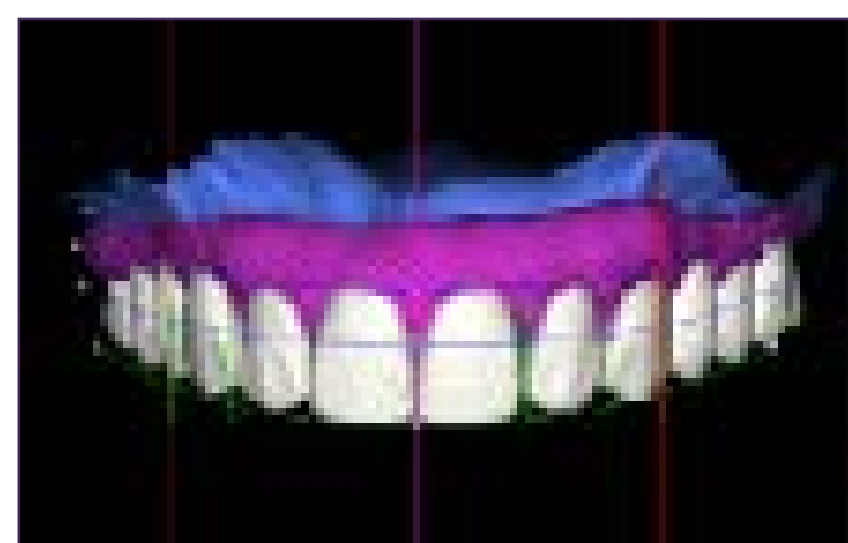


Treatment progress images

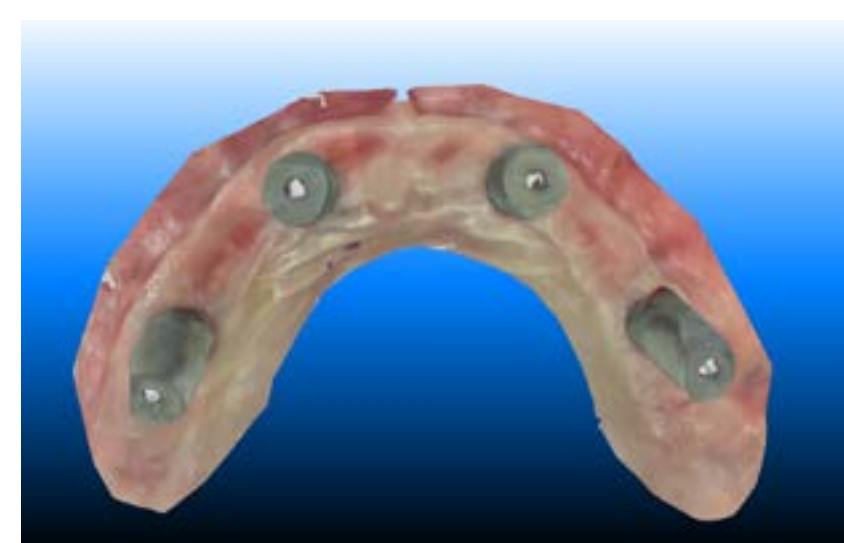CBCT pre-op



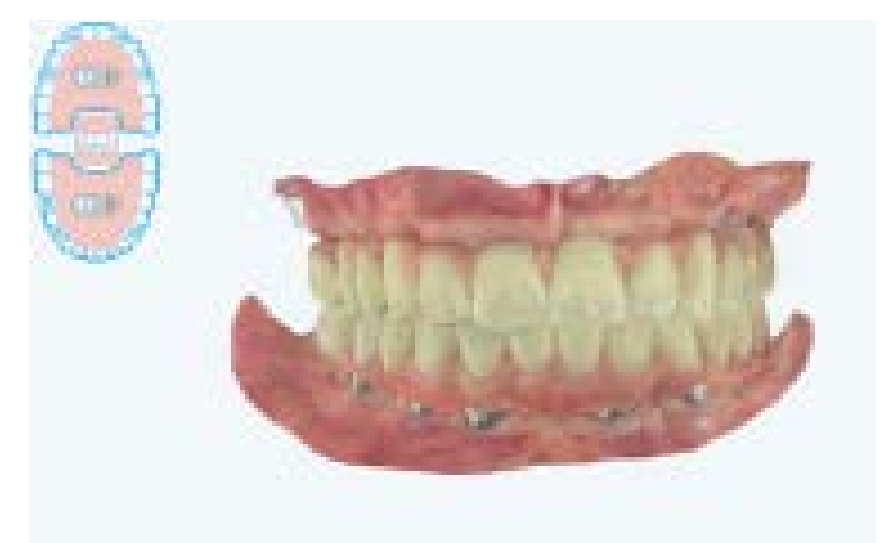DSD planning



Scan body Scan



Provisional restoration in occlusion scan



Materials and Method

- Teeth were extracted
- Implants were placed following the digital planning done with the DSD Evaluation and an immediate loading protocol.
- The Provisional restoration was reinforced with a titanium bar. The restorative material chosen was a combination of acrylic resin and composite.
- After the healing and osseointegration period, the final restoration was fabricated based on the iTero scans.
- The material chosen for the final restorations was titanium bar and monolithic zirconia teeth

Discussion & Conclusion

Succeeding in Full Mouth Restorations requires a multidisciplinary treatment plan. iTero Element 5D scanner and its versatility, together with DSD, helped clinicians in communicating with the patients.

Workflow, strategic treatment planning of implant proper positioning and final restorations are all completed using a completely digital environment.

3 unit Bridge - #25 - #27

iTero

Dr. Gianluca Plotino

Chief Complaint :

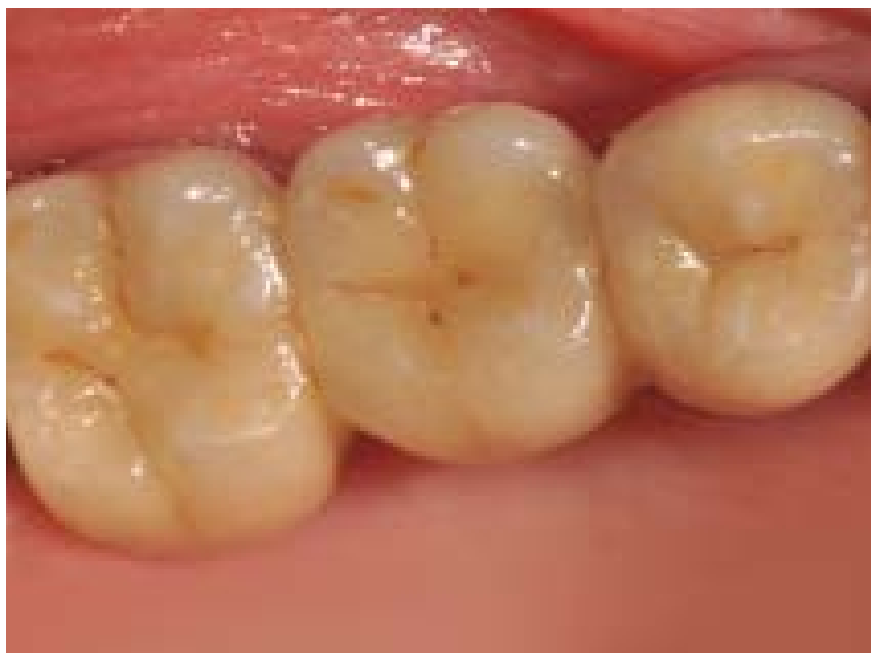The patient complained of pulp sensitivity on both teeth 25 and 27 under the old bridge.



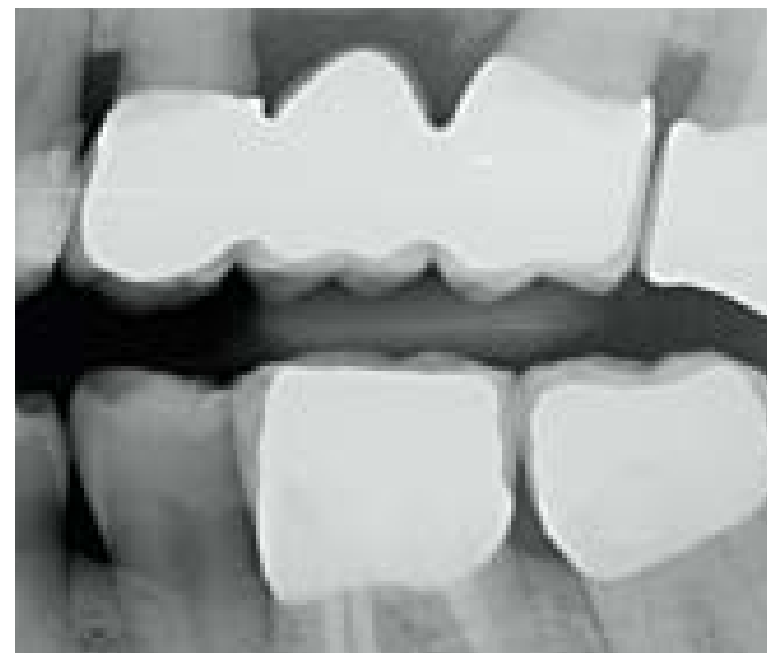Initial clinical status and treatment outcome

Before restoration:

Intraoral photograph

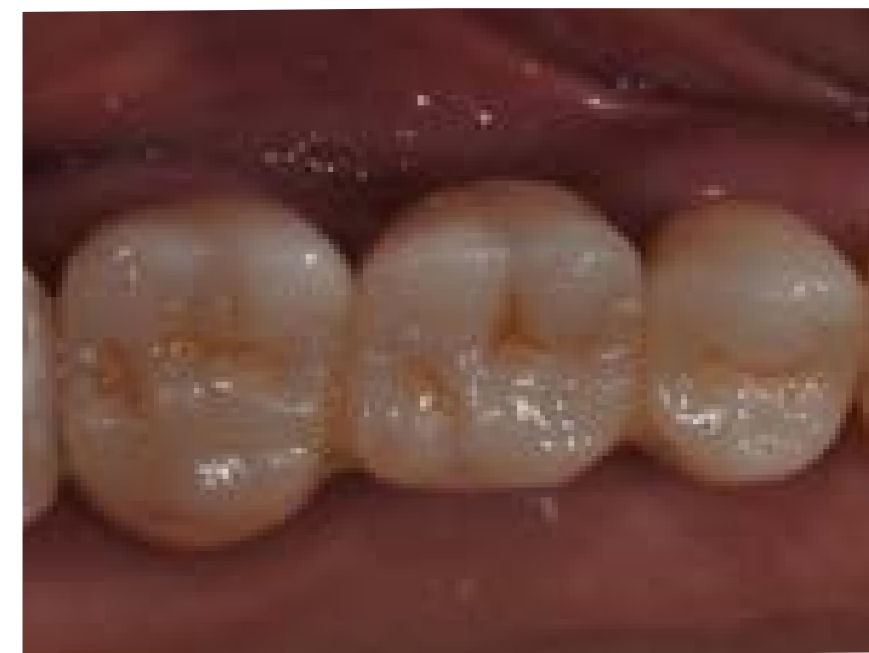

X-Ray

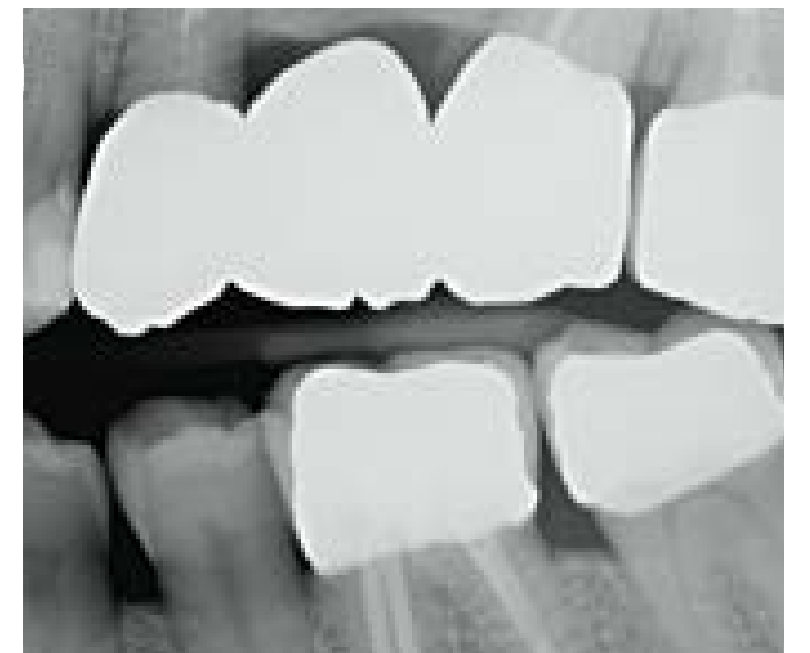


After restoration:

Intraoral photograph



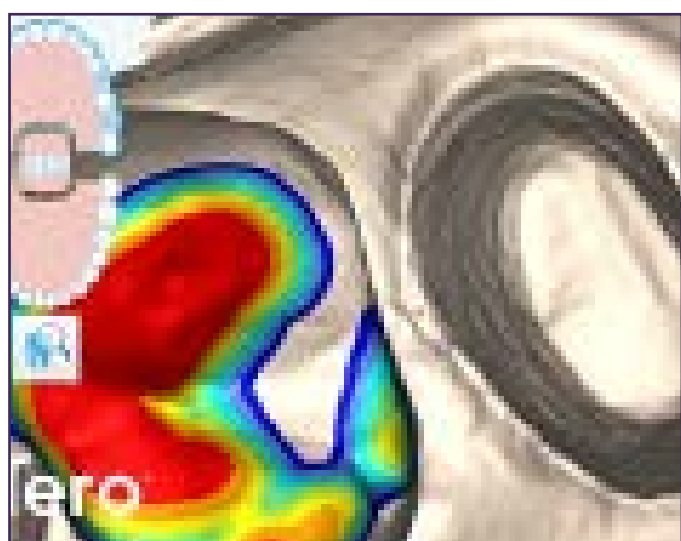
X-Ray



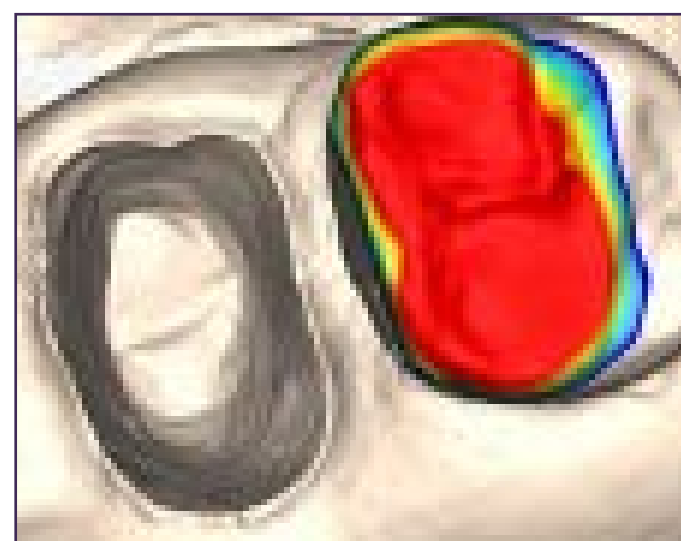
iTero diagnostic tools

Treatment progress images

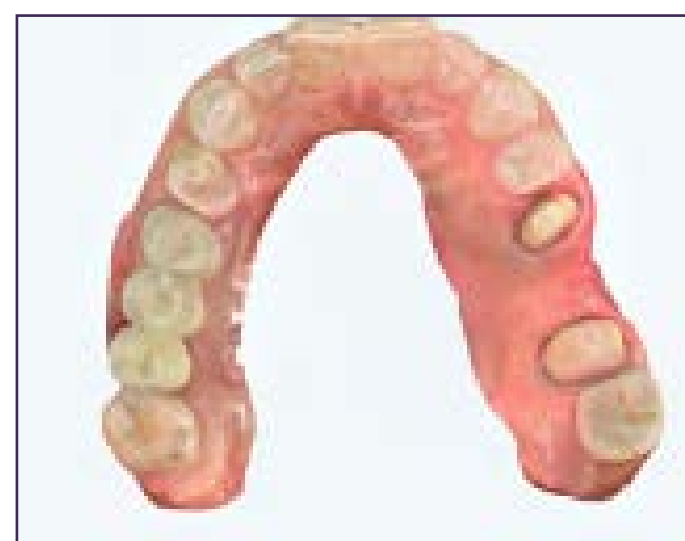Occlusogram



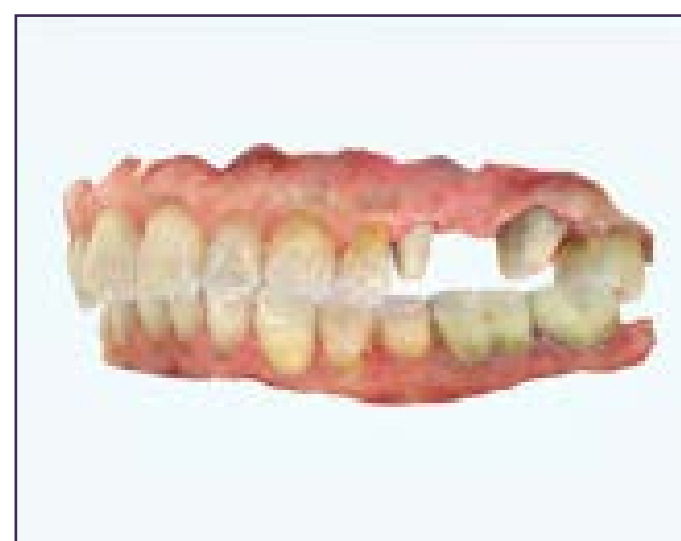Occlusogram



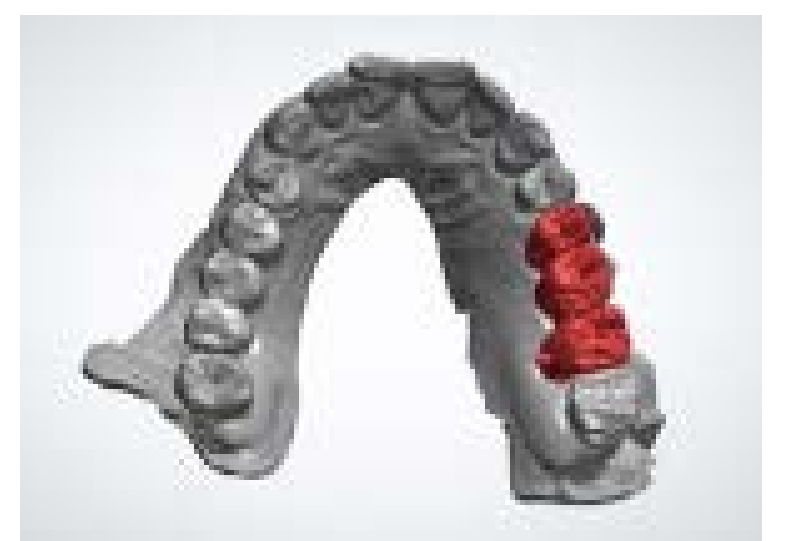Prep scan



Bite



CAD/CAM design



Materials and Method

- After the endodontic treatment of teeth 25 and 27, the doctor proceeded with a vertical edgeless preparation on both teeth.
- The two cords technique was used to retract the gingival tissue using a 00 cord deep in the sulcus and a 0 cord coronally to open the sulcus. The 0 cord was removed immediately before the scan. The second cord was removed upon the completion of the scan.
- The material chosen for the bridge was monolithic zirconia.

Discussion & Conclusion

Devitalised teeth with their natural fragility to fractures require a perfectly balanced occlusion to ensure the long-term clinical stability. The iTero 5D Occlusogram was the key tool in two trivial treatment steps:

- To ensure the adequate space for the restorative material.
- To check the final occlusion balance.



Implant-supported bridge - #14 - #16

Dr. Gianluca Plotino and Dr. Ferruccio Torsello

Chief Complaint :

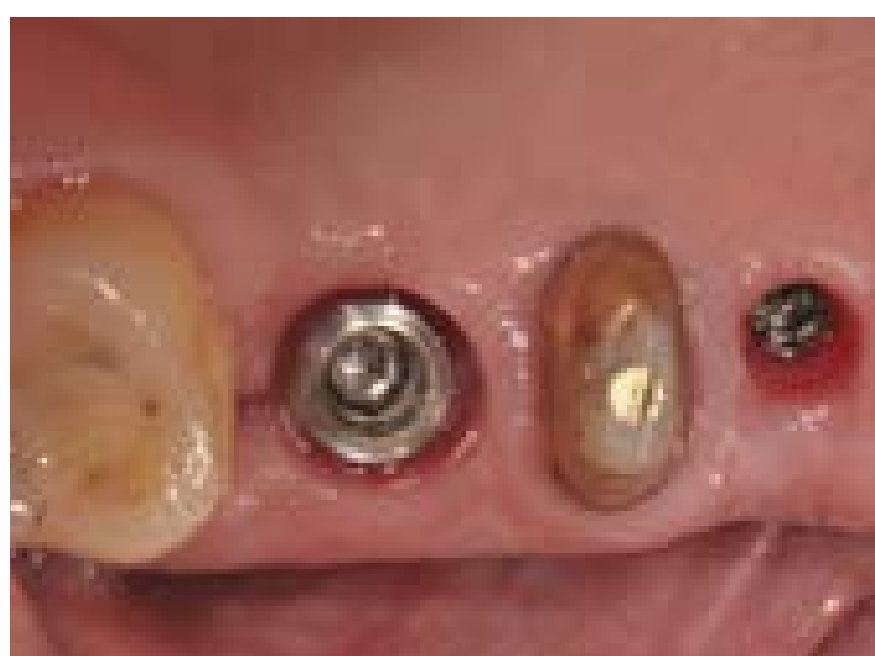- Patient presented to the doctor with an old bridge on 16-15 and a crown on 14.
- Teeth 16 and 14 were fractured
- Tooth 15 had not enough coronal structure to retain a crown



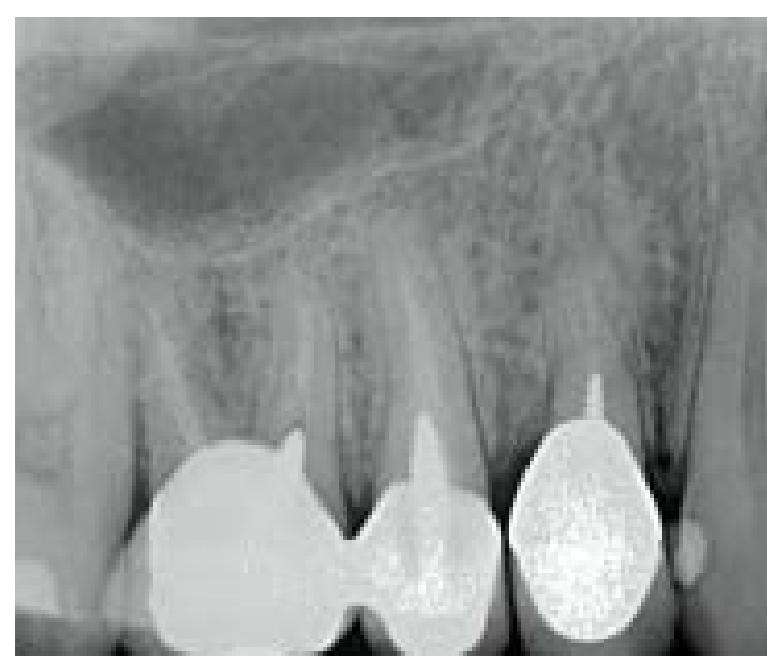Initial clinical status and treatment outcome

Before restoration:

Intraoral photograph

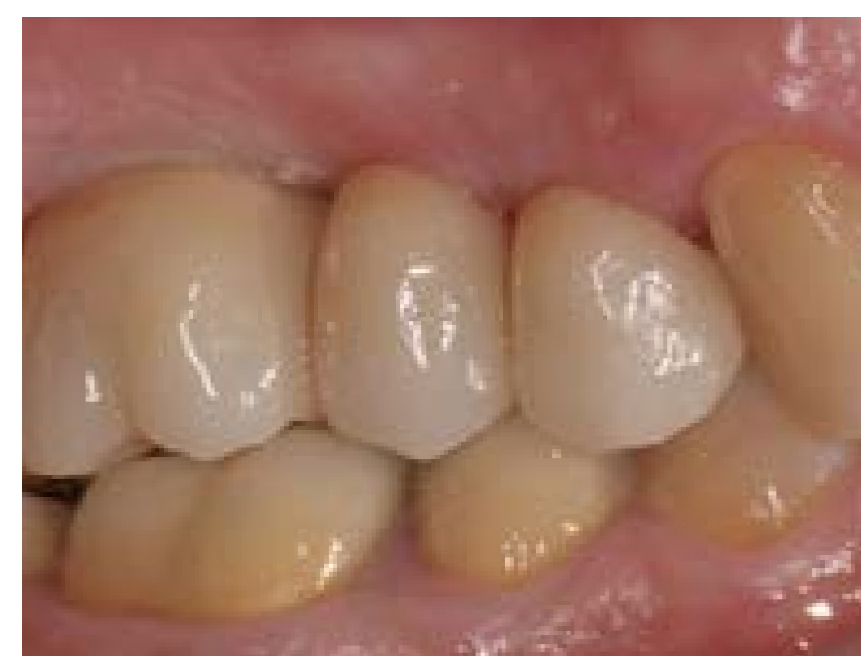

X-Ray

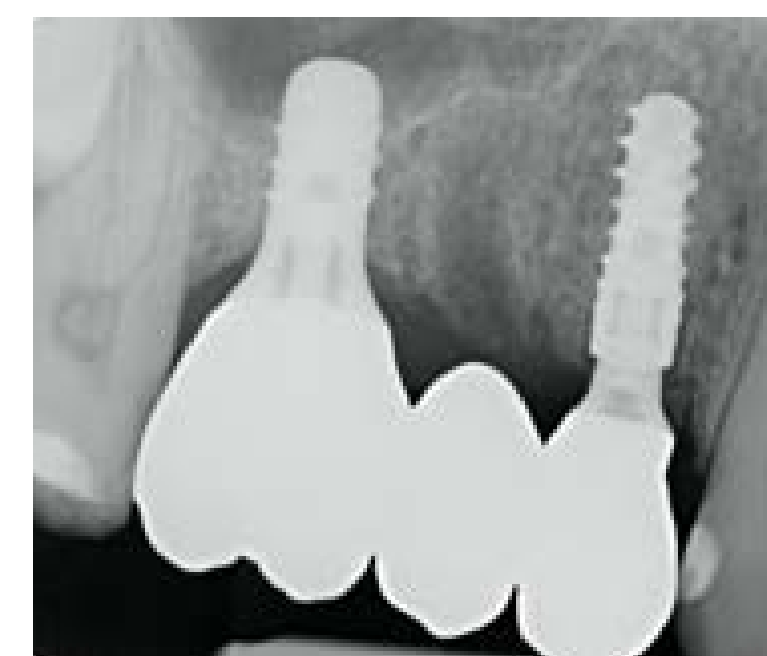

After restoration:

Intraoral photograph

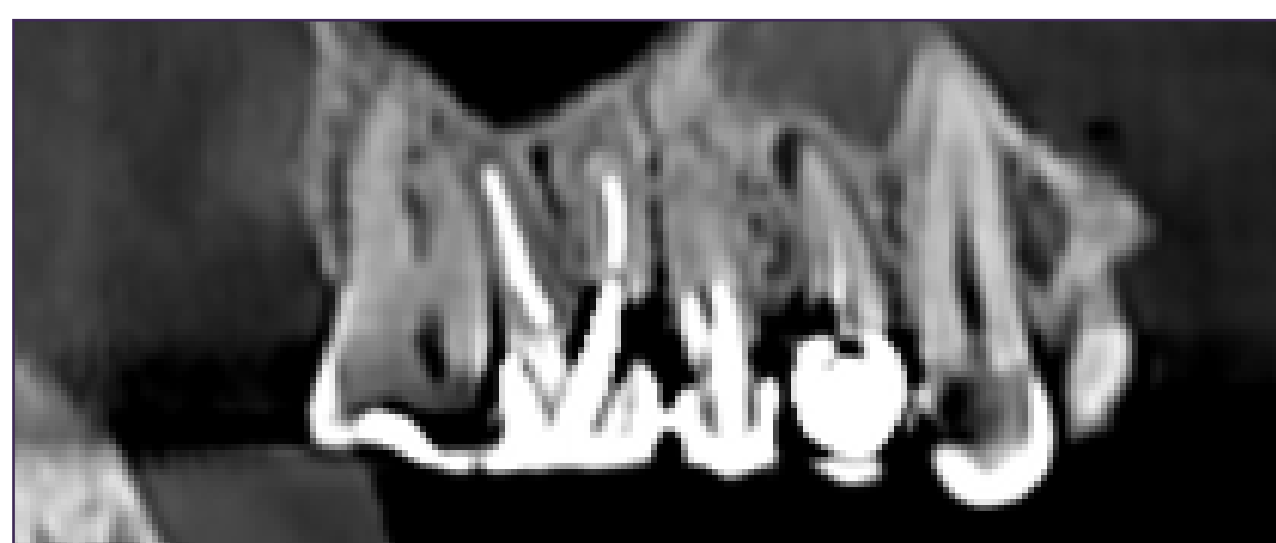

X-Ray




Treatment progress images

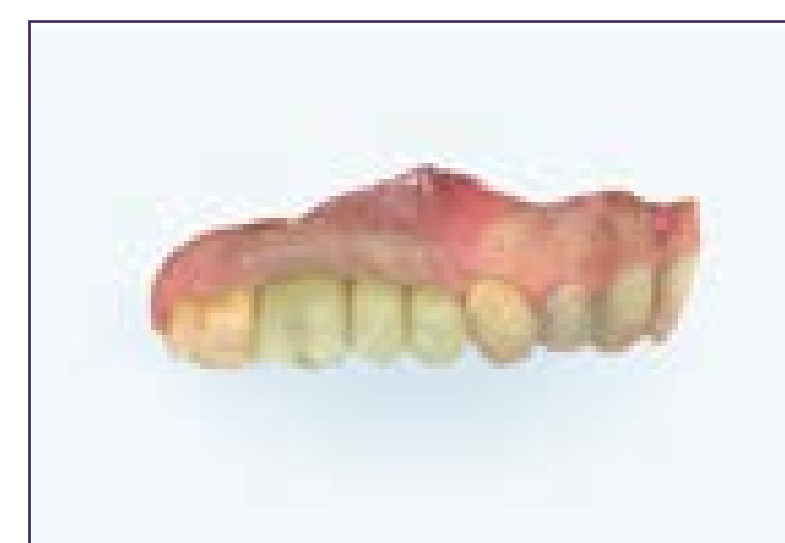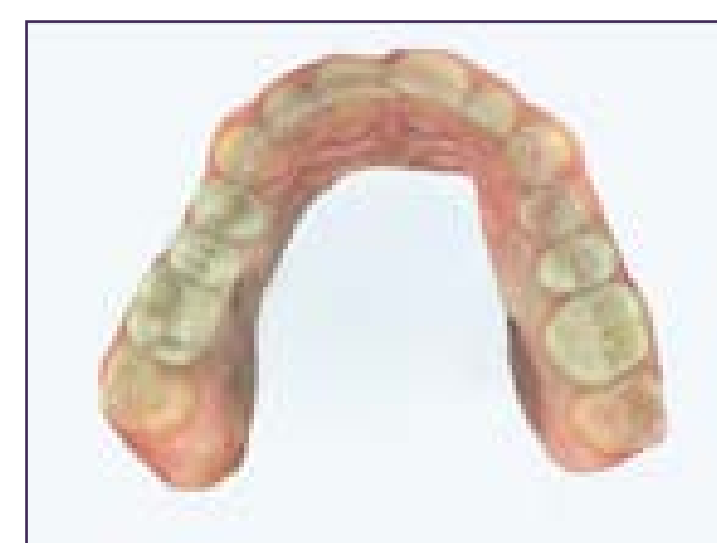Pre operatory CBCT



Prosthetic design



Final Restoration scans



Treatment steps

Phase 1:

- Teeth #16 and #14 were extracted
- Implants were placed on #16 and #14 areas
- iTero Element 5D was used for the digital impression to produce the provisional restoration
- A temporary screw-retained bridge was used supported by tooth #15, in order to reduce the loading forces on the recent placed implants.

Phase 2:

- After 4 months, the implants indicated osseointegration
- Tooth #15 was extracted
- iTero Element 5D was used for the final digital impression
- A final screw-retained monolithic zircona implant-supported bridge was fabricated and delivered.

Discussion & Conclusion

The loading of the implants in the provisionalization phase must allow for the osseointegration process. In the final restoration, the slight underload will ensure the long-term stability.

The accuracy of scanner, allowed the delivery of both steps without the need of adjustments.

Single Crown #25 / implant-supported crown #26

iTero

Dr. Gianluca Plotino and Dr. Ferruccio Torsello

Chief Complaint :

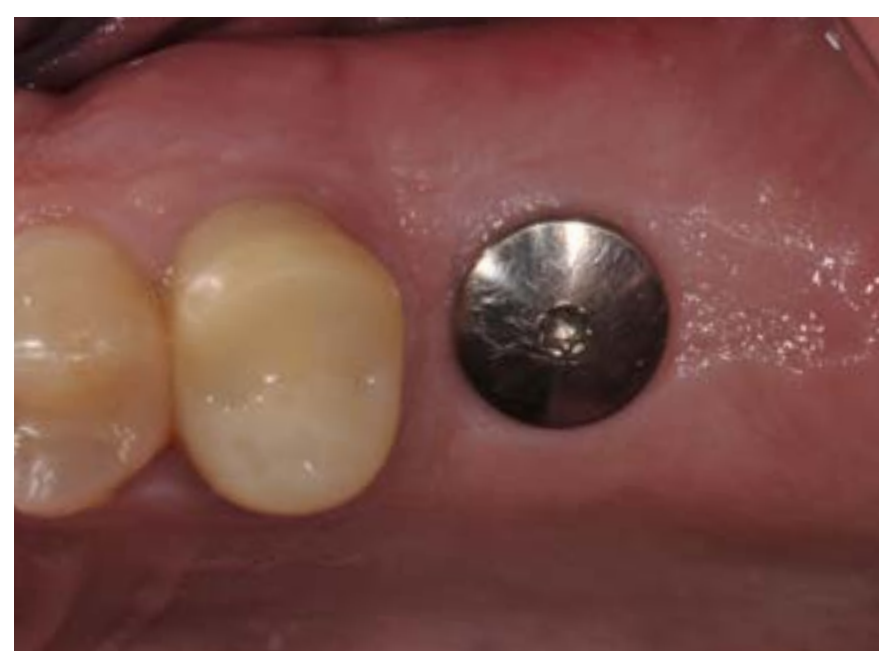- Lost tooth supported crown #27
- Edentulous space #26
- Non aesthetic crown #25



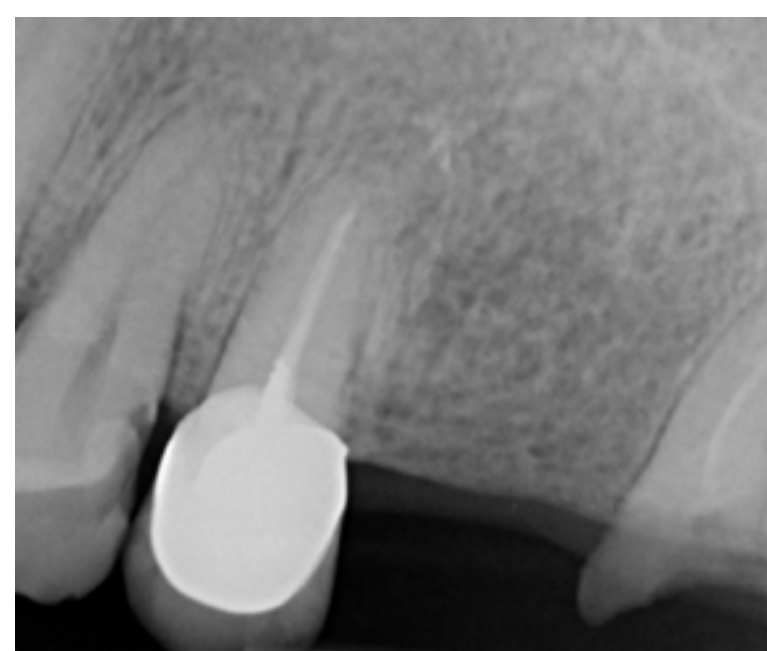Initial clinical status and treatment outcome

Before restoration:

Intraoral photograph

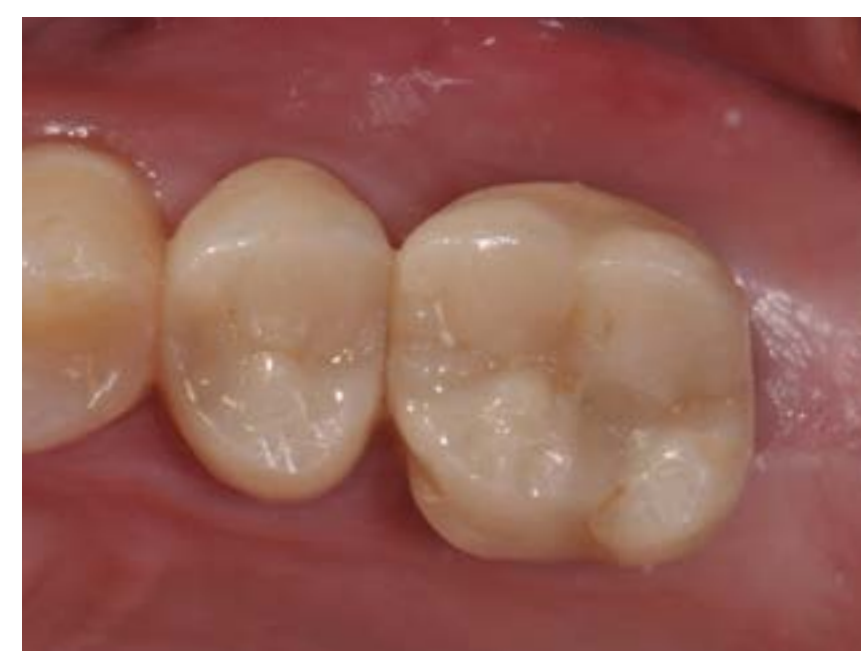

X-Ray

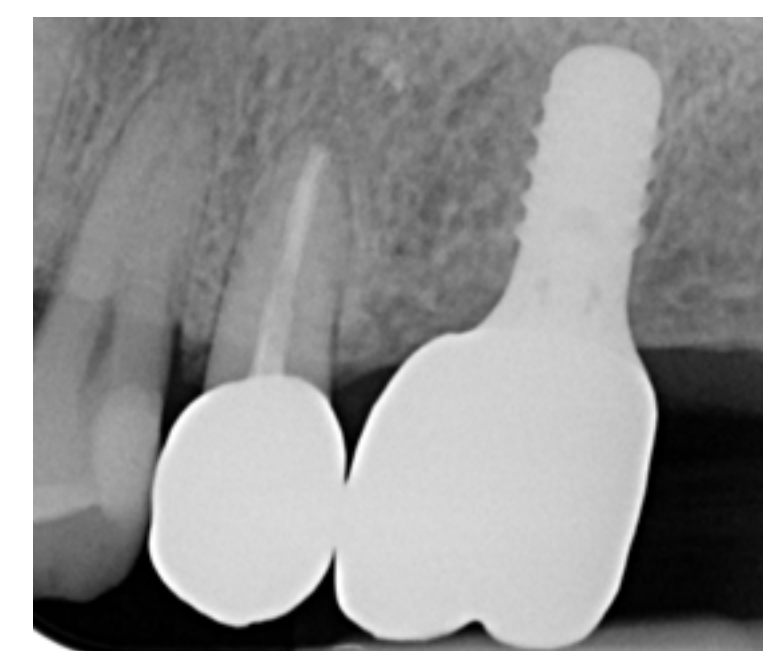


After restoration:

Intraoral photograph

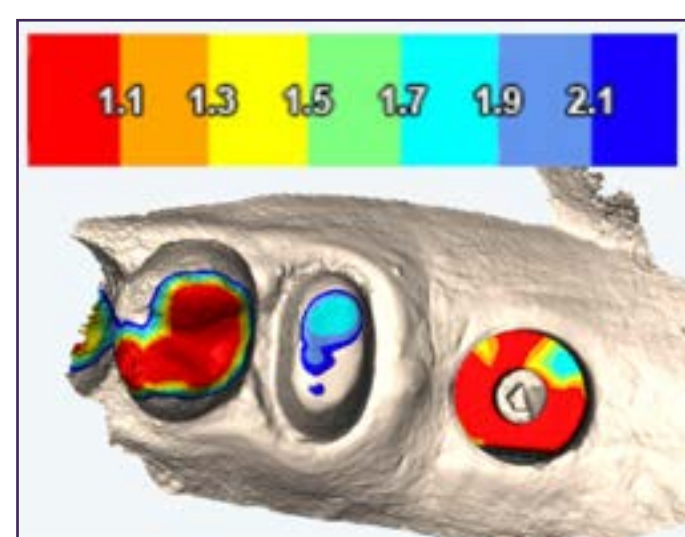


X-Ray

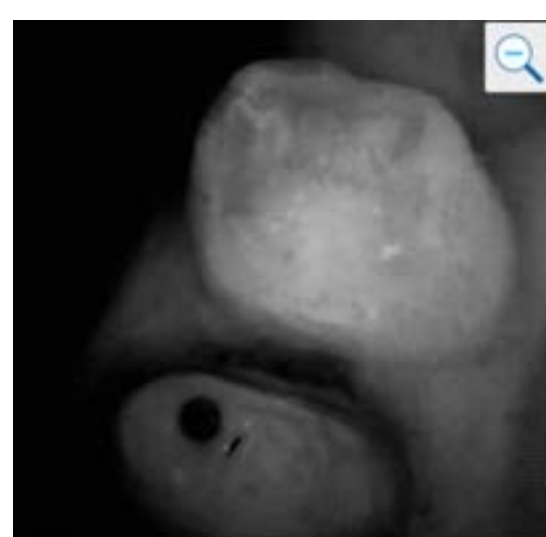

iTero diagnostic tools

Occlusogram

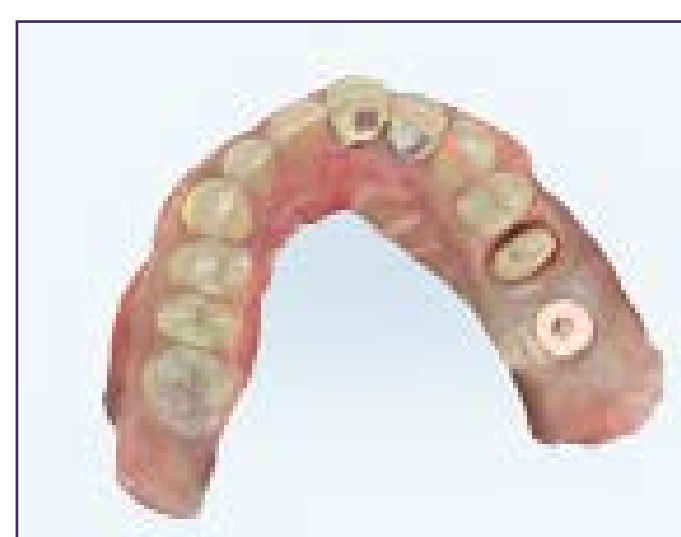

NIRI

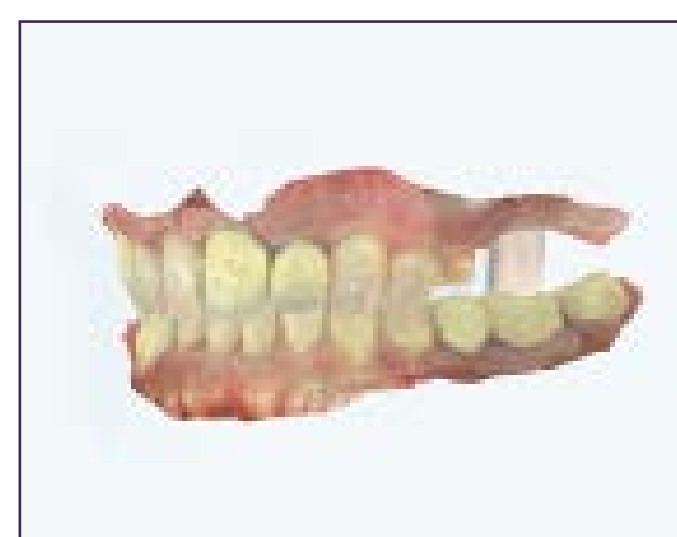

Treatment progress images

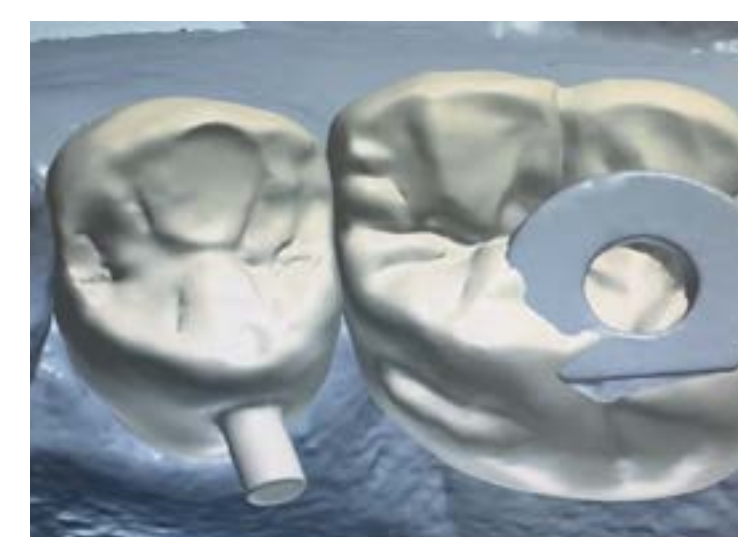
Prep scan



Bite



CAD/CAM design



Materials and Method

- Tooth 25 was prepared with a vertical edgeless margin
- The two cords technique was used to scan tooth 25 using a 00 cord deep in the sulcus and a 0 cord coronally to open the sulcus
- 0 cord was removed immediately before the scan, cord 00 was removed after the completion of the scan
- A scan body was used on implant on 26
- iTero Element 5D was used for the final digital impression
- Tooth #25 was restored with a cemented monolithic zirconia single crown
- Implant #26 was restored with a screw-retained monolithic zirconia crown

Discussion & Conclusion

A comprehensive diagnosis and precise treatment planning are key factors for the clinical success.

In this case, iTero 5D tools like NIRI and Occlusogram, acted as an aid in caries lesion detection and ensuring proper occlusion, which consequently guaranteed the appropriate loading distribution between the teeth and the implant.



A Fully Integrated Diagnostic Process Through Advances in Scanning Technology

by Tim Nolting, Dr MSc, Frédéric Poirier, DDS, and Thomas Giblin, BSc, BDent(Hons)

Abstract

The iTero Element 5D imaging system is the first intraoral 3D scanner integrated with near-infrared imaging (NIRI) technology. NIRI has the potential to revolutionize patient treatment and the overall workflow in dental offices. This technology provides practitioners with an aid for early detection of interproximal caries above the gingiva, which is one of the gravest threats to oral health (equal in seriousness to periodontal disease) per the World Health Organization (WHO).

In the near-infrared electromagnetic spectrum range of 0.7 to 2.0 μm , the iTero Element 5D Imaging System uses light of wavelength (= 850 nm), which interacts with the hard tissue to provide additional data of the tooth structure. The dentin will appear bright, with areas of pathology or demineralization appearing as white spots on the display. The iTero Element 5D imaging system, the latest incarnation of NIRI technology, is an

“innovative, integrated optical diagnostic aid,” using a class 1 laser, as Keshav stated in the iTero Element 5D Clinical Guide (Near-infrared imaging technology in dentistry — iTero Element 5D). It gives practitioners the ability to view multiple dimensions of data, as well as to virtually manipulate the model for a comprehensive view. It is the logical next step in digital diagnostic technology and is quickly replacing both conventional impressions and first-generation intraoral scanners. Advanced scanning technology together with artificial intelligence (AI), streamline the treatment and diagnosis process into the future of dentistry.

Keywords

iTero Element 5D imaging system, patient education, near-infrared imaging (NIRI) technology, dental diagnostics, interproximal caries, restorations, technology adoption, office workflow, practice growth, artificial intelligence (AI)

This white paper has been co-written by 3 dentists who have been using the iTero Element 5D for at least 6 months and refers to a survey of 15 dentists practicing in Germany, Italy, United Kingdom, France, Hong Kong, Australia, and Canada.



WWW.DENTALLEARNING.NET

Introduction: Impact of Technology Adoption for Practice Growth

In this paper, the ways that adoption and integration of new technologies [particularly, NIRI, the iTero Element 5D imaging system, and artificial intelligence (AI)] will overhaul dental office workflow, optimize diagnosis and treatment planning, and improve practice efficiency are highlighted. Conventional methods of diagnosing dental caries and other oral pathologies rely on visual and tactile methods coupled with radiography (X-ray). These methods can have significant drawbacks based on visibility, accessibility, and subjective judgment, equal in seriousness to periodontal disease.¹

First-generation intraoral scanners (IOS) required the application of powder to the teeth for opacification; this could be clumsy and messy for the practitioner or dental assistant, as well as the patient. Moreover, these early intraoral scanners functioned as little more than digital impression systems. Since then, advances in laser technology and scanning speed, as well as enhanced displays featuring in-color 3D models of the dental arches, like the iTero Element 5D imaging system, have broadened the appeal and functionality of IOS technology for use in general dentistry.¹

The most cutting edge of these is the use of NIRI for diagnostic imaging, which works by emitting infrared light into the surface of the tooth. The light diffuses through the highly scattering dentin, reflecting off the enamel of the crowns and creating an image of the occlusal surfaces. While much new decay occurs in pits and fissures, and therefore cannot be detected with conventional X-rays because of the overlapping topography of the tooth surface of posterior teeth,^{2,3} dentists can check for this type of caries with a probe. NIRI scanning is especially useful for detecting interproximal caries above the gingiva that is difficult to see with the naked eye or X-rays, and impossible to detect by probing. In a survey of practitioners who use the iTero Element 5D scanner as part of their

diagnostic protocol, 87% of surveyed participants indicated they increased the number of diagnosed interproximal caries above the gingiva by 56% on average. Near-infrared imaging has the potential to allow for superior diagnostic efficiency, particularly when synced with emerging dental AI technologies for enhanced diagnostics and restoration design.

Patient Experience During the Visit

Unlike conventional dental X-rays, NIRI does not expose the patient or the practitioner to ionizing radiation and its potentially harmful effects, and is therefore safe to use whenever a clinician suspects the presence of dental caries or other pathology that may be hidden by enamel.¹ A scan can provide more nuanced information and serve as an adjunct to traditional radiographs and intraoral photos, and in some cases even replace conventional diagnostic methods. This a clear advantage, improving patient education and dental office workflow, and reducing risk associated with diagnostic X-rays.

IOS has the broadest indications for clinical use; virtual impressions created with NIRI technology are used in a wide range of procedures in general dentistry and across specialist disciplines, including prosthodontics, implantology, and orthodontics.⁴ The images can be worked with easily to give a comprehensive view of the oral anatomy. Dental researchers, including those who conducted a 2017 Massachusetts Institute of Technology study of 10 subjects with varying dental conditions, agree that quality of near-infrared images is superior to that of conventional radiographs; they are a better diagnostic aid.^{3,1,5,6} Likewise, a 2018 study compared NIRI to digital bitewing (DBW) radiography for both intra- and interexaminer reliability, using 12 examiners and 100 images. Reliability on both counts was significantly better with the near-infrared images when used for caries detection.⁶

A Fully Integrated Diagnostic Process Through Advances in Scanning Technology

Better Patient Communication and Comfort

Patients today are more educated and better informed about their health than ever before. Most want to understand the diagnosis process and be proactive in treatment. However, in a 2013 study on patient understanding and recall by Misra et al., the authors strongly concluded that “patients do not recall as much advice and agreed actions about future dental care as dentists believe they have discussed. These results have implications for patient adherence with oral health instructions.”⁷

It is reasonable to assume that the disconnect between the information doctors provide and what patients can recall could be improved by utilizing visual aids, including scans. The ability to show patients a picture of their oral health, as opposed to, or as an aid to, merely explaining it to them verbally, is a powerful educational tool with the potential to improve patient compliance. As an example of the power of harnessing technology, a 2018 study of 291 adolescent dental patients showed that the influence of a mobile app for oral health education increased users’ knowledge and produced a measurably better standard of oral hygiene.⁸ Overall, this indicated that patients respond positively to technological and visual aids.

The iTero Element 5D imaging system has a larger display screen and is built to capture data faster than the previous generations of the Element scanners. These features enable the doctor to evaluate the patient scan chairside and direct a patient’s attention to particular areas shown on the screen as a diagnosis is delivered. As we like to say, a picture is worth a thousand words, and indeed, patients show more confidence and greater understanding in interpreting scanned images alongside their doctors than they do

when being shown a dental radiograph. Images produced by the iTero Element 5D imaging system look familiar to the layperson; they closely resemble digital photos and other common computer images that have become ubiquitous in everyday life. This can be helpful in the education of patients and help them to better understand treatment. In fact, out of practitioners surveyed, 100% of users agree that the iTero Element 5D scanner enables better patient education and understanding of their oral health. This, in turn, can translate into increased patient acceptance of treatment. For instance, the same survey found agreement among users that the imaging and visualization capabilities of iTero Element 5D scanner lead to increased patient acceptance of recommended caries treatment.

Patient experience is also augmented due to the fact that the process of taking the scan is often more comfortable than traditional impressions and radiographs. The speed and ability of discussing their images chairside with their doctor also please the patient. Engaging them in this process encourages them to ask questions, thereby allowing the dentist to address any concerns. This ultimately empowers the patients to make well-informed decisions on treatment.

In particular, the time lapse feature distinctly highlights any change over time, whether the topic of concern is tooth wear or movement. The outcome simulator gives a 60-second demonstration of the potential outcome, along with time lapse, which compares scans over time to infer progress.³ Patients can therefore see and easily understand the changes occurring in their mouth. They are much more likely to proceed with treatment when they fully comprehend the situation and the implications of choosing not to treat. With a scan, they can fully visualize what is going on.



WWW.DENTALLEARNING.NET

Time saved by using an advanced scanning diagnostic aid such as the iTero Element 5D imaging system allows doctors and technicians to dedicate attention to patients' personal experience and increases their acceptance of recommended treatment. The presence of cutting-edge technology in the dental office fosters patient confidence, as they can see that their doctor uses the most up-to-date diagnostics. This added confidence can further lead to increased acceptance of treatment. For example, a survey of practitioners who incorporated the iTero Element 5D scanner into their diagnostic protocol found that 79% of participants reported an average increase in patient acceptance of interproximal caries treatment by 71%. In the final analysis, more advanced diagnostics fosters better communication and happier, healthier patients. The combination of patient satisfaction and higher rates of recommended treatment acceptance due to better diagnostics, along with the timesaving efficiency of NIRI scanning, is an equation for boosting practice incomes.

Increased Restorative Cases with Better Clinical Outcomes

The iTero Element 5D imaging system's overall efficiency creates a more streamlined workflow in the dental office. With the iTero Element 5D, a scan is taken at the beginning of every visit. Other diagnostic methods may or may not be necessary, as the scan does not replace the physical intraoral or extraoral examination. However, it is our experience that an initial scan often eliminates the need for cumbersome, time-consuming X-rays, which would also mean that patients are not subjected to the emission of ionizing radiation.

In his practice, Dr. Nolting found that by using the iTero Element 5D imaging system, approximately 5% more caries was detected than with conventional diagnostics. This is partly attributable to the streamlining effect on office workflow — now doctors using advanced scanners can see more

patients because of the reduced time involved, but they can also detect pathologies that might previously have been overlooked. Compared to conventional radiographs, a 3D scan provides a more comprehensive approach that enables the doctor to view all surfaces of every tooth. Thus, scanning is more efficient for revealing interproximal caries decay above the gingiva.

In a survey of practitioners incorporating the iTero Element 5D scanner into their current diagnostic protocol, 79% of survey participants reported an average increase of 32% in the number of treated restorative cases, while reporting an average increase of 57% in the number of treated interproximal caries. These increases resulted in an average hike in business revenue of 25% and 34% for the practice, respectively. Also, in treatment, being able to see into the tooth's internal anatomy allows dentists to be more conservative with the tooth structure, based on the quality of enamel that is preserved. This leads to increased patient health, preventative efficacy, well-documented practice volume and growth, as well as improved retention of patients. In a survey of iTero Element 5D scanner users, 93% of those surveyed agreed that with the improved communication capabilities of the iTero Element 5D scanner, they expect to improve practice patients' retention rate. By starting every appointment with a scan, practitioners will have the upper hand in detecting interproximal caries above the gingiva in its earliest stages, even before it shows up on a bitewing radiograph.

Creating Efficiency for Restorative Workflows and Labs

In the past, many dentists have felt pressured to invest in maintaining in-house laboratories for creating accurate restorations. Now, scanning can replace the time-consuming process of creating a model and then using wax to build the teeth back up in the laboratory, which can take a significant amount of time per tooth.

A Fully Integrated Diagnostic Process Through Advances in Scanning Technology

With the iTero Element 5D imaging system, the dental assistant, hygienist, or the dentist performs the scan and hits “send” — it’s that simple.

Models can be delivered to the office within 2–3 days using a lab workflow or fabricated chairside within 1–2 hours using a 3D printer. This replaces the traditional processes that required having a full-time technician on staff and the additional physical space for a lab. A streamlined practice resulting from adopting new digital technologies will need fewer employees and less space, thus positioning NIRI scanning as the default method of monitoring and diagnostics.

In terms of restorations, for example, a major implication is the time savings that can be achieved per crown. Digital impressions have been shown to be a satisfactory alternative to conventional methods for creating impressions.

A 2013 study by Seelbach et al. concluded that digital impression systems allow the fabrication of fixed prosthetic restorations with similar accuracy to that of conventional impression methods.⁹ Thus, scanning saves precious office time, enabling dentists to outsource many of the tedious steps associated with restorations, and to focus their own efforts on design and finishing. It is also a useful method of documenting ongoing problems and treatment.

Not only useful for crown and bridge work and diagnostics, scanning can be seamlessly incorporated into everyday practice to help practitioners monitor patient oral health. The iTero Element 5D imaging system is more versatile than older generations of scanners, and it is expressly compatible with Invisalign. With Invisalign’s solid comparability behind the iTero, there is a drive to continue to improve design and functionality, to make it more than just a scanner, but a more comprehensive diagnostic aid.

Ease of Use and Accuracy

The iTero Element 5D imaging system offers a light and sleek scanning wand. It is user-friendly; scanning at a rate of 6,000 frames per second, 20 times faster than the earlier models of the iTero scanner with little to no learning curve.¹⁰ This system offers screenshot capability as well as various views including intraoral camera, NIRI, and monochrome. A comprehensive archive of instructional videos is available on iTero’s Support website,¹¹ making it simple and easy for technicians to get questions answered and get quick training on how to use the technology in every diagnostic context. The system’s website (myitero.com) also provides the clinician with the ability to store cases, a feature that affords the practitioner the luxury of reviewing cases at their own discretion.

Scanning is noninvasive. When compared to conventional impressions, the use of an intraoral scanner has the ability to improve the patient experience with regard to comfort, gagging, breathability, tastes, and smells. It is easier, cleaner, safer, and more patient-friendly than other diagnostic aids and methods.

Prevention of Harmful Radiation Associated with Radiographs

The advantages of NIRI imaging over X-rays cannot be overstated. Beside the practical advantages — overall time efficiency, labor (and, thus money)-saving, files that are easy to delete and redo, ease of storing files in digital form, and transfer of images between practitioners via electronic transfer,⁴ the most obvious desirable outcome is eliminating the risk of irradiation for both patient and practitioner. In 2018, Hwang et al. published a review of 2,158 studies to summarize the results of studies of the association between exposure to dental X-rays and health risk. Although



WWW.DENTALLEARNING.NET

the level of exposure from dental diagnostic X-rays is lower than that of medical radiation, there is an innate risk from radiation exposure.¹² Therefore, for certain categories of patients, notably those at low risk of developing caries, and also pregnant women, regular bitewing radiographs are neither indicated nor advisable.^{13,6} Any diagnostic aid or technology that helps eliminate the need for X-rays marks an advance in treatment approach.

Moreover, NIRI technology is shown to be as effective in detecting interproximal caries above the gingiva as radiography,¹ perhaps even better — a University of California School of Dentistry study found that with traditional radiography, interproximal caries above the gingiva are undiagnosed up to 40% of the time.¹⁴ For conventional X-rays to reliably detect a carious

lesion, there must be a certain amount of decay present. A near-infrared image can help the dentist to detect interproximal caries above the gingiva weeks or months before it is severe enough to show up on a conventional radiograph. Starting every appointment with a scan will reduce the number of X-rays taken, and thus reduce exposure to radiation, while increasing diagnostic accuracy. Even in ambiguous cases, where the doctor feels an X-ray is required to be more confident in diagnosis, an initial scan is always an effective aid to rule out an unnecessary step and increase patient confidence.

Evolution of Dental Office Technology

As has been true in other professions, technological advances are streamlining the dental workplace and

Case Reviews Supporting Efficiency and Better Clinical Outcomes with Scanning

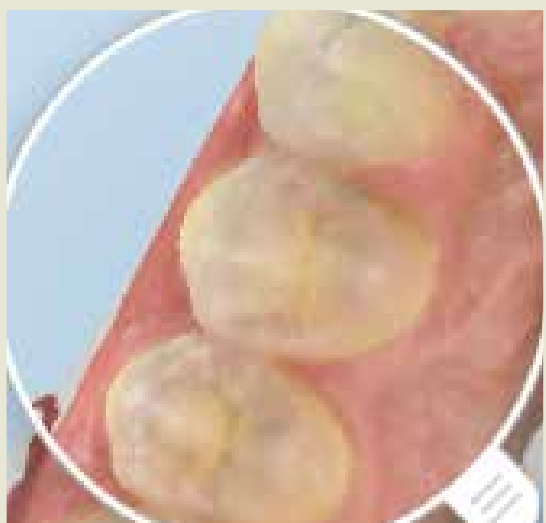

Figure 1. iTero Element 5D scan

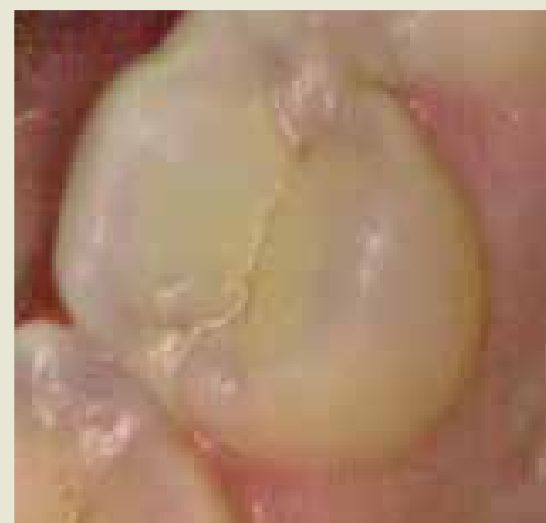

Figure 2. Intraoral photo

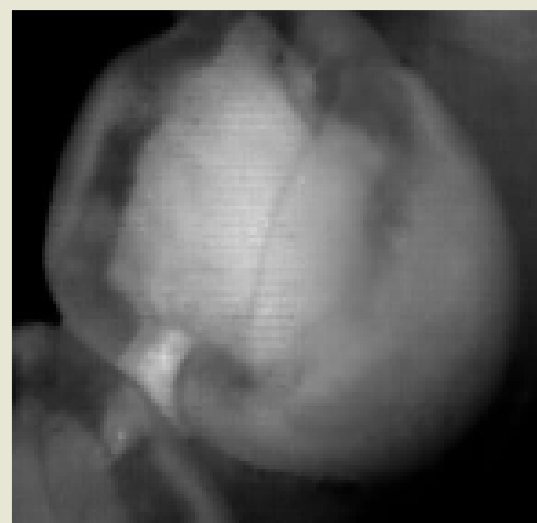


Figure 3. NIRI image

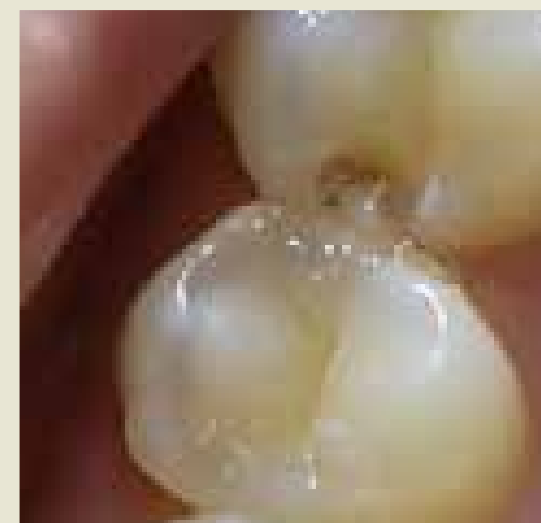

Figure 4. Affected teeth, ready for treatment

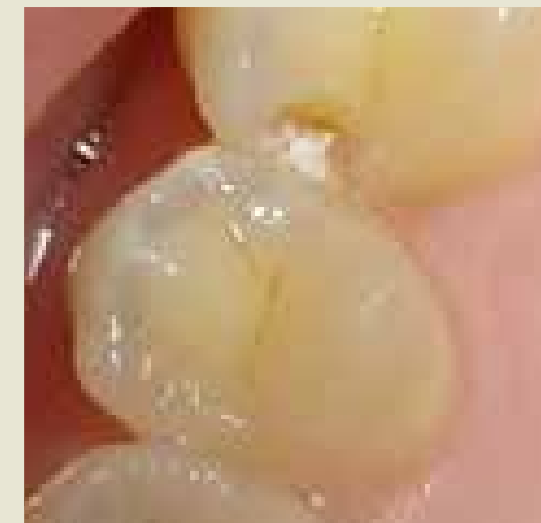

Figure 5. Decayed carious lesion found

FIRST CASE REVIEW — Proximal Carious Lesion

In a routine dental checkup, the patient exhibited neither symptoms nor clearly visible signs of caries; however, a scan revealed a proximal carious lesion. The iTero Element 5D scan (Figure 1) produced the same information as that gleaned from intraoral photos (Figure 2) — small white surface spots on #5.¹

While periapical X-rays showed no

significant pathology, the iTero color scan and NIRI findings (bright spots in the distal area) (Figure 3) prompted removal of the superficial tooth structure to reveal an advanced carious lesion (Figure 4), which was then treated.¹ Figure 5 shows the decayed carious lesion. Periapical X-rays were prescribed as a part of routine check-up. The radiograph suggested no significant findings (Figure 6).

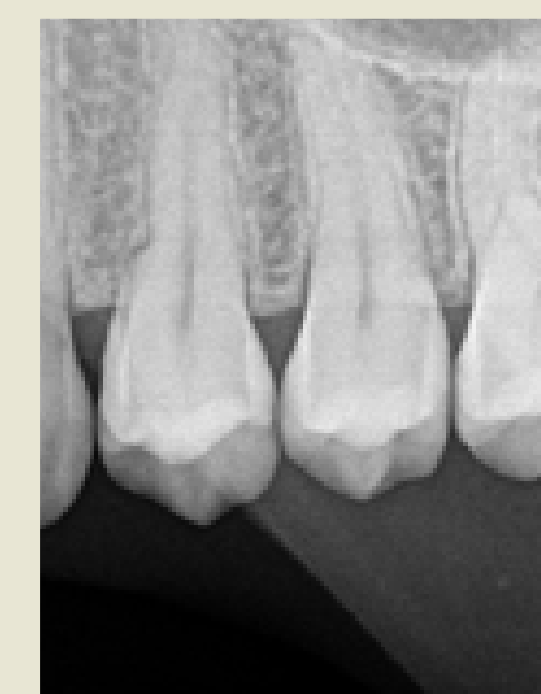

Figure 6. Periapical radiograph

A Fully Integrated Diagnostic Process Through Advances in Scanning Technology

helping reduce health risks to clinicians and patients alike. NIRI technology fits in well with the prevailing mode of comprehensive dentistry, as it is a way for clinicians to include the patient, clearly showing them, with easy-to-understand images, the intricate relationship between good oral health and overall well-being. It seems reasonable to extrapolate that NIRI technology should be a useful aid for underscoring the implications of forgoing treatment.

For practices that were already on the way to digitizing much of the paper workflow and daily management (scheduling, communications, etc.), using digital diagnostics actually speeds up the integration

of new technology. The trend toward turning practices digital is saving time, energy, and money and preserving the best possible oral health for patients.

In a current dental practice, every visit should begin with a scan. Whereas a full set of intraoral photos is recommended for new patients, a 3D scan combined with 2D high-quality image capturing eliminates this need. The more ubiquitous NIRI technology becomes, the greater the comfort and familiarity it will have for both patients and office staff. Office staff prefer the ease and efficiency of scanning to old-school methods like impressions and X-rays.

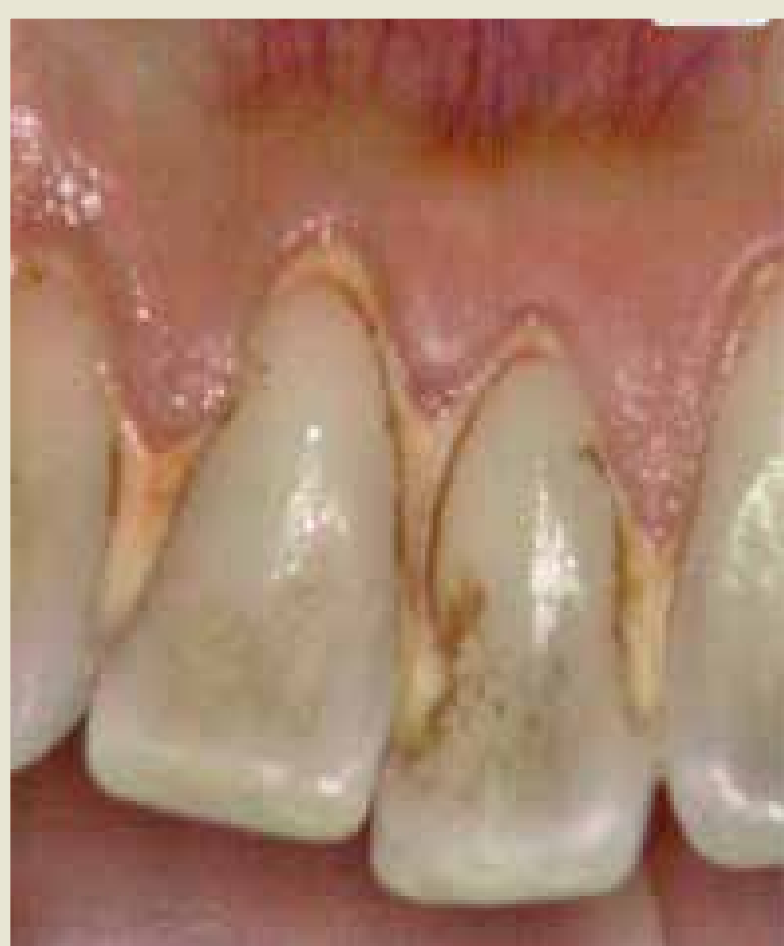

Figure 7. Intraoral photo showing calculus

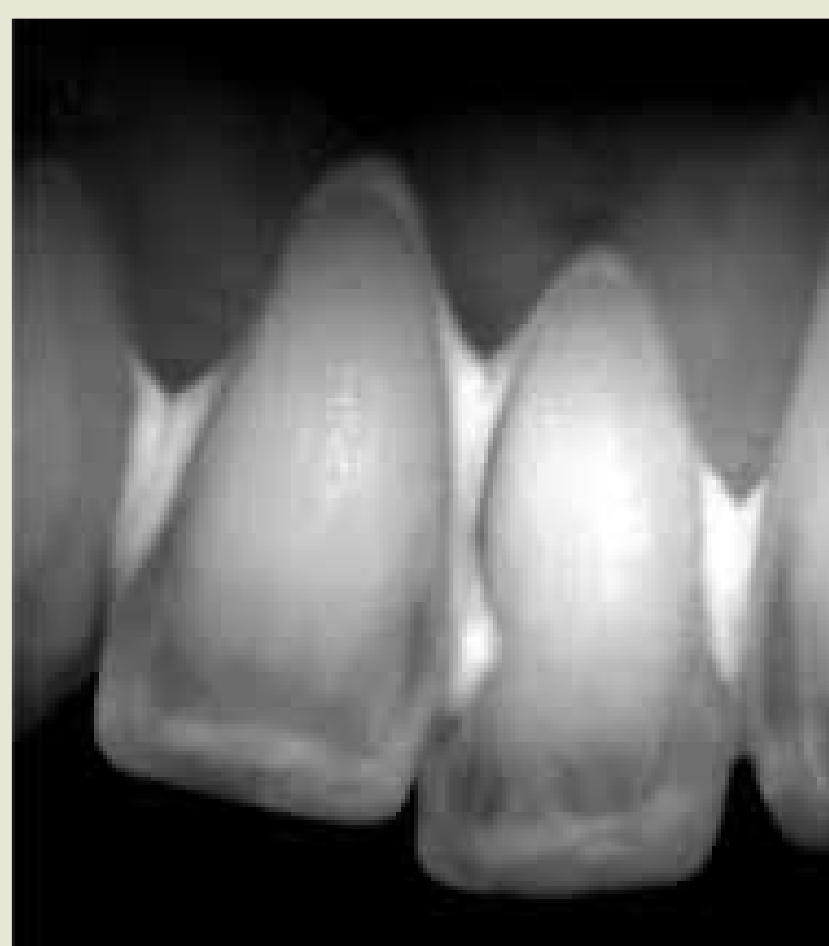

Figure 8. NIRI image showing calculus

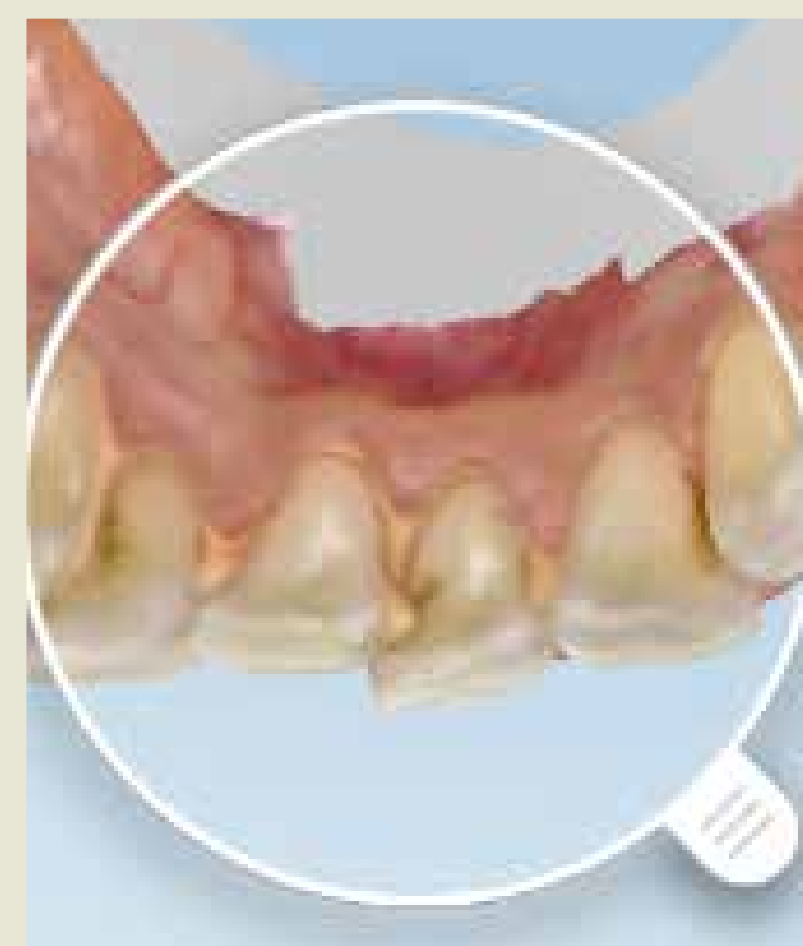

Figure 9. Color scan showing calculus

SECOND CASE REVIEW — *Calculus*

In this case, calculus is clearly visible in the intraoral photos (Figure 7). The same area of calculus appears in the NIRI

image (Figure 8) as brightened areas around the tooth. The scanned color view shown in Figure 9 closely matches what

can be seen from the intraoral photo. Also, the presence of calculus does not interfere with the quality of the scan.¹



WWW.DENTALLEARNING.NET

THIRD CASE REVIEW — *Dental Fluorosis*

These images show a common enamel disorder — dental fluorosis. Fluorosis, resulting from excess fluoride exposure during tooth formation, can give teeth a white, opaque appearance. In more severe cases, pitting and enamel loss can occur, leading to brown stains that

can mimic the appearance of dental caries.¹⁵ Fluorosis can affect the structural anatomy of the tooth. This case highlights NIRI's advantage in detecting changes in the structural integrity of the enamel.

Figure 10 shows a color scan of the affected area. Note the opaque

white coloration at the top of the cuspid. Intraoral photo (Figure 11) of the same area looks much the same, with the affected tooth showing the same discoloration. Finally, the NIRI image (Figure 12) shows dental fluorosis on the mandibular left canine #22.

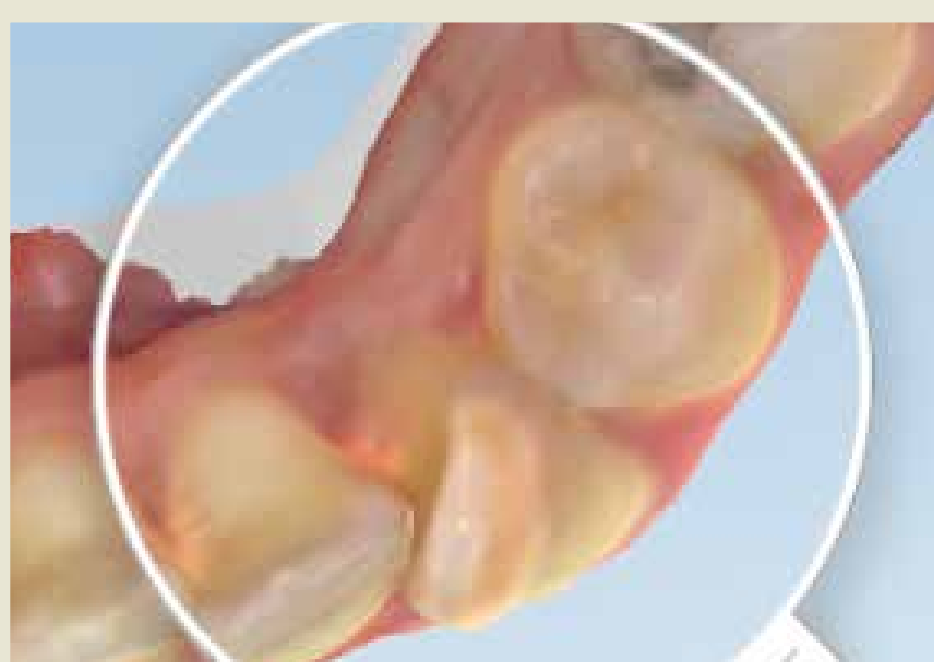

Figure 10. Color scan of the affected area

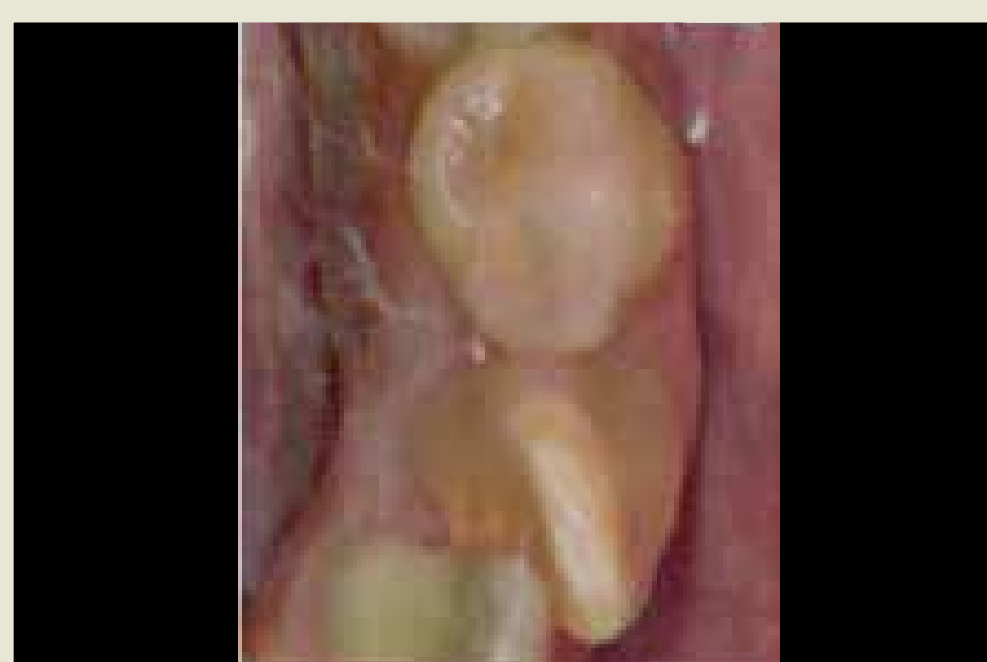

Figure 11. Intraoral photo of affected tooth

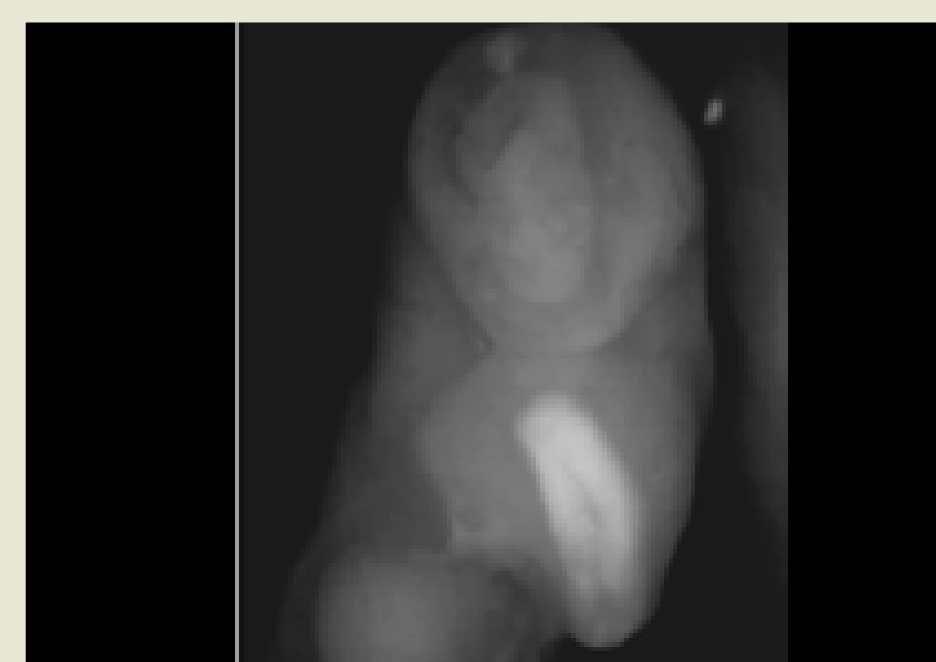

Figure 12. NIRI image of the internal anatomy shows dental fluorosis on the mandibular left canine #22.

AI in Practice

The use of AI in mainstream medical and dental practices is now possible and becoming more common every day. What is AI, and how will it be integrated into modern dental practice? Generally, the term AI is used colloquially to refer to “smart” machines, those that can learn, communicate, or otherwise display cognitive features and functions that we associate with human beings. However, this is a misnomer — AI is not really “artificial,” but, in fact, is just another aspect of human intelligence and creativity. The intelligence behind the novel technologies associated with AI is human intelligence. These machines are created by humans to perform some of the tasks we do, in the same way that we do them, but often more efficiently.¹⁵ As in many other professions, and indeed, in our everyday lives, some argue that AI will soon become an integral player in diagnosis and treatment in the dental

field, especially as dental medicine is becoming more tied in with the medical community in general. Dental care is now recognized as an important aspect of overall healthcare. Just as AI is already being utilized in medicine and medical research, it will inevitably pervade dental practice.

Many dentists today do not fully realize the impact AI could soon have on their potential production.¹⁵ The advent of cloud computing has given intelligent technologies and intelligent machines a foothold in medical and dental practices, and it is likely here to stay. AI is an aid for quick diagnosis and treatment planning.¹⁶ This is particularly true in radiology, where deep convolutional neural networks (CNNs), a computational tool that enables computers to map images in layers, and thus to rapidly scan for certain features, enable computers to identify caries and other oral pathology, often as accurately as a human

A Fully Integrated Diagnostic Process Through Advances in Scanning Technology

examiner — sometimes more so. CNNs are one of the tools in facial recognition technology that has become so familiar with the use of smartphones.^{17,15} The combination of AI with near-infrared scanning technology confers distinct advantages for diagnosis and treatment in general dentistry.

Machines can work longer and harder than humans in intensive detail-oriented tasks like reading and comparing scans and X-rays. They can rapidly access and sort through massive bodies of archived data for comparisons. In a new study published in July 2019, Hung et al. encourage the use of these kinds of machine-learning methods in diagnosis, particularly for predicting root caries, in older patients. In their study, the algorithms produced had high accuracy in early intervention and treatment in the aging population of the United States.¹⁸

In use for some time in orthodontic treatment and monitoring, AI is now also coming to the forefront in restorative and prosthetic dentistry.¹⁹ Using AI for design and manufacturing helps to maximize comfortable fit, correct function, and create pleasing esthetics. Designers are already working to make AI user-friendly, with features like voice command and conversational interface, much like the ubiquitous Siri or Alexa. One seemingly mundane, but clever, use of this technology will include smart treatment chairs that can sense the patient's weight, vitals, and emotional state, and adjust for maximum comfort, safety, and information to the clinician. No longer a futuristic myth, AI dentistry is the new reality.

In short, advances in scanning technology and their integration with smart computing platforms will facilitate production and a higher degree of accuracy.

A Roundup of the Benefits

The iTero Element 5D imaging system is leaps and bounds ahead of earlier generation

intraoral scanners because of NIRI technology. It is the first integrated dental imaging system to simultaneously record 3D, intraoral color, and NIRI images. Three-dimensional scanning and virtual models are already rapidly replacing plaster models in orthodontia, prompted by the enormous popularity of clear aligners like Invisalign. In that field, the more steps between impressions and the fitting of a final appliance, the more opportunities for information to be lost or blurred. Therefore, appliances from a digital impression tend to fit better and are more likely to fit as intended. Scanning is noninvasive and can be used as often as desired to provide the best patient outcomes for early detection of interproximal caries above the gingiva. Case studies have shown that it takes approximately 4 years before an interproximal lesion is clinically visible,¹ whereas the same lesions are potentially discoverable much earlier on a NIRI image. This saves time and money and helps prevent further damage to the teeth.

The iTero Element 5D imaging system is an ideal vehicle for chairside education, allowing patients to participate more fully and understand all aspects of their oral health. It is fast and streamlined, comfortable for the patient, and easy for users to master. In addition, the advent of new modes of AI will maximize information gleaned from scans by reliably finding hidden or interproximal caries above the gingiva.

AI can then communicate with vast databases known as big data for the most up-to-date treatment options and comparisons, including advanced restorations and prosthetics. All of this can be done rapidly and efficiently, greatly reducing the practice workload while increasing overall productivity. With the ease of just a single scan, the practitioner, the practice, and the patient are awarded all of these benefits.



WWW.DENTALLEARNING.NET

References

1. Keshav, P. Near infrared imaging technology in dentistry– iTerro Element 5D. <https://storagy-itero-production-eu.s3.amazonaws.com/download/en/iTerro-Element-5D-Clinical-Guide.pdf>
2. Bühler C, Ngaotheppitak P, Fried D. Imaging of occlusal dental caries (decay) with near-IR light at 1310-nm. *Opt Express*. 2005;13(2):573–582.
3. Neel Shyam VK, Dharshini TP, Raghavi D, et al. IR imaging for dental caries. *Int J Trends in Eng Technol*. 2018;28(1):15–19.
4. Mangano F, Gandolfi A, Luongo G, Logozzo S. Intraoral scanners in dentistry: A review of the current literature. *BMC Oral Health*. 2017;17(1):149.
5. Angelino K, Edlund D, Shah P. Near-infrared imaging for detecting caries and structural deformities in teeth. *IEEE J Transl Eng Health Med*. 2017;5: 2300107. Published online Apr 19, 2017. doi: 10.1109/JTEHM.2017.2695194.
6. Litzenburger F, Heck K, Pitchika V, et al. Inter- and intraexaminer reliability of bitewing radiography and near-infrared light transillumination for proximal caries detection and assessment. *Dentomaxillofac Radiol*. 2018;47(3): 20170292. Published online Feb 7, 2018. doi: 10.1259/dmfr.20170292.
7. Misra S, Daly B, Dunne S, et al. Dentist-patient communication: What do dentists and patients remember following a consultation? Implications for patient compliance. *Patient Prefer Adher*. 2013;(7):543–549.
8. Marchetti G, Fraiz FC, Nascimento WMD, Soares GMS, Assuncao LRDS. Improving adolescents' periodontal health: Evaluation of a mobile oral health app associated with conventional educational methods: A cluster randomized trial. *Int J Paediatr Dent*. 2018;28(4):410–419.
9. Seelbach P, Brueckel C, Wöstmann B. Accuracy of digital and conventional impression techniques and workflow. *Clin Oral Investig*. 2013;17(7):1759–1764.
10. <http://storagy-itero-production-us.s3.amazonaws.com/download/en-us/iTerro-Element-Brochure-For-General-Practitioners.pdf>. Sept 12, 2019.
11. Digital Smile Design promotion video. YouTube. <https://www.youtube.com/watch?v=8qxCelFNyA>. Mar 16, 2019.
12. Hwang SY, Choi ES, Kim YS, et al. Health effects from exposure to dental diagnostic X-rays. *Environ Health Toxicol*. 2018;22(4).e2018017. doi: 10.5620/eh.t.e2018017.
13. Jablonski-Momeni A, Jablonski B, Lippe N. Clinical performance of near-infrared imaging system VistaCam iX Proxi for detection of approximal enamel lesions. *BDJ Open*. 2017;3:17012. June 30, 2017. <https://www.nature.com/articles/bdjopen201712>.
14. DenBesten P, Li W. Chronic fluoride toxicity: Dental fluorosis. *Monogr Oral Sci*. 2011;22:81–96. doi: 10.1159/000327028.
15. Deshmukh SV. Artificial intelligence in dentistry. *J Int Clin Dent Res Organ* 2018;10:47–48.
16. Cooper M. Why artificial intelligence is the future of dentistry. <http://practicemanagement.dentalproductsreport.com/article/why-artificial-intelligence-future-dentistry>. Nov 2, 2017.
17. Masakazu M, Katsuhiko M, Yusuke M, Yuji K. Subject independent facial expression recognition with robust face detection using a convolutional neural network. *Neural Netw*. 2003;16:555–559.
18. Hung M, Voss MW, Rosales MN, et al. Application of machine learning for diagnostic prediction of root caries. *Gerodontology*. 2019 Jul 5. doi: 10.1111/ger.12432. [Epub ahead of print].
19. Allareddy V, Rengasamy Venugopalan S, Nalliah RP, et al. Orthodontics in the era of big data analytics. *Orthod Craniofac Res*. May 2019;22 Suppl 1:8–13. doi: 10.1111/ocr.12279.

These claims are based on a survey conducted in May 2019 of n = 15 practitioners who participated in a global limited market release, working with iTerro Element 5D for an average period of 6 months, representing both GPs and Orthos in CAN, EU, and APAC, who were presented with a level of agreement scale from strongly agree to strongly disagree with the following statement: "Incorporating the iTerro Element 5D scanner into my current diagnostic protocol, I've diagnosed a higher number of interproximal caries above the gingiva, on my patients at my practice," and then asked to estimate the average increase.

About the Authors



Tim Nolting, Dr MSc

Dr. Nolting received the Master of Science degree in implantology. He specializes in many fields, including oral surgery, periodontology, and laser dentistry. He is certified by the German Society for Ultrasound in Medicine (DEGUM), one of the largest medical and scientific societies in Germany and one of the largest ultrasound societies worldwide, in head and neck ultrasound applications. Dr. Nolting is also certified to perform Botox and filler treatment procedures. He is an Investigator in clinical studies.



Frédéric Poirier, DDS

Dr. Poirier received the dental degree from the University of Montreal in 1992, after also receiving a degree in microbiology from the same institution. He opened his private practice in Montreal after graduating in 1996. Dr. Poirier expanded into orthodontics through the Institut Dentaire International (IDI) in Quebec in 1999, an organization affiliated with IAO, where he has successfully treated more than 2000 orthodontic patients in his practice. His professional interests include complete and interceptive orthodontic treatments

using functional appliances, braces, and Invisalign, mechanical endodontics, CEREC, esthetics, and occlusion.

Dr. Poirier is a member of l'Ordre des Dentistes du Québec, the Canadian Dental Association, and the International Association for Orthodontics. He is also an active member of Gnathos, whose main focus is to offer high-quality continuing education on orthodontics. Dr. Poirier has attended a number of CE classes on orthodontics and has many public speaking experiences to his credit, mostly centered on Invisalign.



Thomas Giblin, BSc, BDent(Hons)

Dr. Giblin, a Specialist Prosthodontist, received the degree in dentistry from Sydney University with honors in 2004. In 2007, after a stint in private practice, Dr. Giblin was accepted into a 3-year Advanced Prosthodontics Residency at the University of Texas Health Science Center in San Antonio, regarded as the top program in the USA. While there, he gained a broad education in all aspects of dentistry, including implant, fixed and removable prosthodontics, as well as sleep dentistry, occlusion, and TMD. Since returning to Australia, he worked in several locations before establishing his current practice, Northern Dental Specialties, Northern Beaches.

Near infrared imaging (NIRI) technology in dentistry - iTero Element 5D.

This clinical guide presents the promising features of the iTero Element 5D Imaging System designed with NIRI technology and its application into every day dentistry. NIRI technology of the iTero Element 5D aids in detection and monitoring of interproximal caries lesions above the gingiva without using harmful radiation.

Author: Dr. Priyanka Keshav BDS, iTero Global Education

Background

In 2001, the National Institutes of Health Consensus Conference on the Diagnosis and Management of Dental Caries throughout life stated that “Dental caries is an infectious, communicable disease resulting in destruction of tooth structure by acid-forming bacteria found in dental plaque, an intraoral biofilm, in the presence of sugar. The infection results in the loss of tooth minerals that begins with the outer surface of the tooth and can progress through the dentin to the pulp, ultimately compromising the vitality of the tooth”¹.

Although largely preventable, dental caries is one of the two biggest threats to oral health and is amongst the most common chronic diseases in the United States. Dental caries is the most common chronic disease in children; it is about five times as common as asthma and seven times as common as hay fever². Majorities of adults today live with untreated tooth decay in their permanent teeth; this makes the early detection of caries vital to identify and combat these pathological lesions in the early stages. The World Health Organization estimates that 60-90% of school children and nearly 100% of adults have or have had caries³.

The concept of dental caries has changed significantly over the last decade. While the only way of managing caries used to be the complete removal of the demineralized tissues, today, caries is considered a dynamic process, which, if diagnosed in time, could be reversed. The current treatment philosophy is to prevent and detect dental disease at the earliest stage in order to avoid invasive treatment. With the current understanding of the nature of dental disease and its process, the treatment philosophy is now changing to a more conservative approach and the concept of minimal intervention is gaining popularity in modern dentistry throughout the world. Early caries detection is essential for minimal intervention dentistry because it could give the opportunity to reverse the process and eliminate or at least postpone the surgical treatment. The ideal caries detection device should be able to detect the caries from the earliest stages, when the organic matrix is still not damaged, to the latest stages of cavitated lesion⁴. Current conventional diagnostic methods rely mainly on visual, tactile methods paired with radiographs. Each of these methods have significant drawbacks; Visual examination is highly technique sensitive and subjective, and tactile methods of examination are unreliable for examining proximal areas due to lack of eye contact with the proximal surface itself and some studies have indicated that the tip of the probe may cause micro abrasions of the enamel or damage to areas of remineralization if present.

Additionally, radiographs are known to expose the patient to harmful ionizing radiation present with technique sensitivity cannot be used frequently. New imaging technologies are in demand for the early

detection of such lesions. Moreover, the treatment for early dental decay or caries is shifting away from aggressive cavity preparations that attempt aggressive removal of demineralized tooth structure toward non-surgical or minimally invasive restorative techniques⁵.

Near infrared imaging technology

Near Infrared Imaging serves as a valuable diagnostic aid in the early detection of interproximal caries. The near infrared (NIR) is the region of the electromagnetic spectrum between 0.7 to 2.0 micrometers (μm)⁶. The iTero Element 5D Imaging System uses light of wavelength ($\approx 850\text{nm}$) in the electromagnetic spectrum which on interaction with the hard tissue of the tooth provides additional data of its structure. Enamel is transparent to NIRI due to the reduced scattering co-efficient of light, allowing it to pass through its entire thickness and present as a dark area, whereas the dentin appears bright due to the scattering effect of light caused by the orientation of the dentinal tubules, any interferences/pathological lesions/ areas of demineralization appear as bright areas in a NIRI image due to the increased scattering within the region.

iTero Element 5D Imaging System is an innovative integrated optical diagnostic aid (uses class 1 laser) and is the first 3D intraoral scanner with NIRI technology. With one scan, it is possible to view multiple layers of data: 3D model, 2D color images and NIRI images mapped to the 3D model. The user can rotate a 3D model of the teeth on the computer monitor and without looking at the patient to evaluate it from different angles and review the corresponding color and NIRI images at the same time to gather a comprehensive view of the situation. The system digitally captures the 3D geometry and color of the patient's intraoral dental structures using a proprietary optical, non-contact, focus detection technique.

The device also includes capabilities of NIRI function that captures data beneath the tooth surface using NIRI illumination during routine scanning. Incorporating both the NIRI images and the color images captured by the system can aid in the detection of caries. Images are available in real time on the screen, can be enlarged, and contrasts can be adjusted based on preference. Additionally, scans can be saved and viewed later as desired or paired with tools such as TimeLapse to monitor areas of interest.

Optical methods have the advantage that they do not use ionizing radiation. For this reason, these procedures can be used as often as desired to monitor caries. Several clinical studies have showed NIRI sensitivity to be as potent as radiographic examinations and are well suited for the detection and imaging of interproximal caries⁷.

*iTero Element 5D is not yet available for sale in the US.*iTero Element 5D is currently available in European Union countries with exception in Switzerland and Norway.

To download the full PDF please [click here](#)

Literature

Numerous studies have been conducted concerning near infrared imaging that can be traced back to the early 1990s. Some noteworthy articles have been mentioned as follows:

1. Fried D, Glena RE, Featherstone JD, Seka W. Nature of light scattering in dental enamel and dentin at visible and nearinfrared wavelengths. *Applied Optics*. 1995;34(7):12781286⁸

Objective: In this study, Fried et al. measured the optical properties of fully index-matched samples of enamel and dentin as a step in calculating the distribution of deposited energy in teeth. The light-scattering properties of dental enamel and dentin were measured at 543, 632, and 1053 nm between 0° and 180° in appropriate index-matching baths. From the measured distributions and comparison with Monte Carlo 1MC2 simulations of light scattering in these tissues, the optical coefficients, the nature of the phase function, and the scattering anisotropy were derived for dentin and enamel at these wavelengths.

Results: In the visible and NIR wavelengths, dentin and enamel weakly absorb light, and light scattering plays an important role in determining the deposited energy distribution in the tissue. The scattering and absorption coefficients of enamel compare favorably with literature values measured using an integrating sphere. The measured scattering and absorption coefficients of dentin are both almost an order of magnitude larger than for enamel. Preliminary, two-dimensional, spatially resolved MC simulations using the optical parameters determined in this study indicate that the use of visible and NIR laser beams of, 1-mm diameter on the enamel surface may lead to preferential energy deposition near the dentin–enamel interface. This may have negative consequences such as subsurface heating and cracking.

Relevance: Use of NIRI has been studied in enamel, which shows high transparency. There is published data available regarding this technology in teeth, and more specifically in enamel and dentin. There is substantial evidence dating from 1990 for the potential use of NIR light for detecting caries in enamel, due to its high transparency when illuminated by Near Infra-Red light.

2. Comparison of diagnostic methods for early interproximal caries detection with near-infrared light transillumination: an in vivo study Ismail Hakki Baltacioglu and Kaan Orhan⁹

Background: Although numerous studies have used digital intraoral imaging, only a few studies have used photo-optical methods for the diagnosis of caries. Moreover, several limitations exist in terms of observers (experience and specialty) and the caries lesion itself. Hence, the aims of this study were to evaluate the diagnostic capability of near-infrared light transillumination

(NILT) and PSP-Bitewing radiographs and to compare the interobserver and intraobserver differences in addition to observers' experience level to detect early interproximal caries lesions in vivo

Methods: A total of 52 untreated posterior teeth with and without varying degrees of early interproximal carious lesions were included. Bitewing radiographs using digital phosphor plates (PSP-Bitewing) and NILT were used to clarify the diagnosis. An oral and maxillofacial radiologist and a restorative dentistry consultant evaluated the images twice. A separate appointment for clinical validation and restoration was made. Kappa coefficients were calculated to assess both intraobserver and interobserver agreements for each evaluation method. Scores obtained from PSP-Bitewing and NILT were compared with the clinical validation via receiver operating characteristic (ROC) analysis.

Results: No significant differences were found between PSP-Bitewing radiography and NILT for detecting early interproximal carious lesions with high average Az results. Both intraobserver and interobserver agreement values were relatively higher for NILT evaluation. The Az values increased at second evaluations for both caries detection methods.

Conclusion: NILT examination has an appropriate sensitivity and diagnostic accuracy for detecting early interproximal caries lesions and can be considered as a method of choice for detecting caries without the use of ionizing radiation.

3. Evaluation of two imaging techniques: near-infrared transillumination and dental radiographs for the detection of early approximal enamel caries. Maia AM, Karlsson L, Margulis W, Gomes AS.¹⁰

Objective: The aim of this paper was to evaluate a transillumination (TI) system using near-infrared (NIR) light and bitewing radiographs for the detection of early approximal enamel caries lesions.

Methods: Mesiodistal sections of teeth (n = 14) were cut with various thicknesses from 1.5 mm to 4.75 mm. Both sides of each section were included, 17 approximal surfaces with natural enamel caries and 11 surfaces considered intact. The approximal surfaces were illuminated by NIR light and X-ray. Captured images were analysed by two calibrated specialists in radiology, and re-analysed after 6 months using stereomicroscope images as a gold standard.

Results: The interexaminer reliability (Kappa test statistic) for the NIR TI technique showed moderate agreement on first (0.55) and second (0.48) evaluation, and low agreement for bitewing radiographs on first (0.26) and second (0.32) evaluation. In terms of accuracy, the sensitivity for the NIR TI system was 0.88 and the specificity was 0.72. For the bitewing radiographs the sensitivity ranged from 0.35 to 0.53 and the specificity ranged from 0.50 to 0.72.

*iTerro Element 5D is not yet available for sale in the US.*iTerro Element 5D is currently available in European Union countries with exception in Switzerland and Norway.

Conclusion: In the same samples and conditions tested, NIR TI images showed reliability and the enamel caries surfaces were better identified than on dental radiographs.

4. Russotto, F, Tirone, F, Salzano, S, Borga, FC, Paolino, D, Ferraro, A, Botasso, S. Clinical evaluation of near-infrared light transillumination (NIRT) as an interproximal caries detection tool in a large sample of patients in a private practice. J Radiol Imaging. 2016;1(1):1-5¹¹

Background: A study has been carried out in order to evaluate in vivo the diagnostic performance of near-infrared light transillumination (NIRT) compared to digital radiographic examination (RE) in the detection of class II carious lesions.

Methods: A total of 114 patients were included, and 2957 proximal surfaces were considered. Surfaces were imaged by means of NIRT and radiographed with a photostimulable phosphor system. NIRT and radiographic images were observed by two blinded operators. Their diagnoses were compared with those made while visiting the patients, when visual-tactile, radiographic and NIRT data were matched by expert operators to obtain the reference diagnoses. Sensitivity, specificity and inter-observer consistency were calculated.

Results: Throughout the visits, 395 caries were detected. When investigating without clinical information and in a blind manner, RE performed significantly better than NIRT regarding sensitivity analysis (0.591 vs. 0.456, $p < 0.001$), and NIRT performed significantly better than Radiographic examination (RE) regarding specificity analysis (0.980 vs 0.933, $p < 0.001$). However, NIRT showed sensitivity similar to RE when only enamel caries were concerned. With regard to no agreement between the two positives for enamel caries (95% from 0.699 to 0.791) was observed in RE. NIRT was very likely to detect and correct the erroneous positive diagnosis of enamel carious lesions obtained using RE (95% CI for probability from 0.938 to 0.979).

Conclusions: NIRT should be used in caries diagnosis in combination with radiographic images. In fact, NIRT can help to correct a false positive diagnosis of enamel caries. Furthermore, NIRT could be used to detect caries in patients for whom non-urgent radiographic exposition is contraindicated and to monitor caries in medically treated patients.

5. Caries Detecion and Diagnostics with near – infrared light transillumination : Clinical experiences .Friederike Sochtig, DDS/Reinhard Hickel,DDS./Jan Kuhnisch,DDS,MDS¹²

The aim of the study was to present the function and potential of diagnosing caries lesions using a recently introduced near-infrared(NIR) transillumination technique (DIAGNOcam, KaVO).

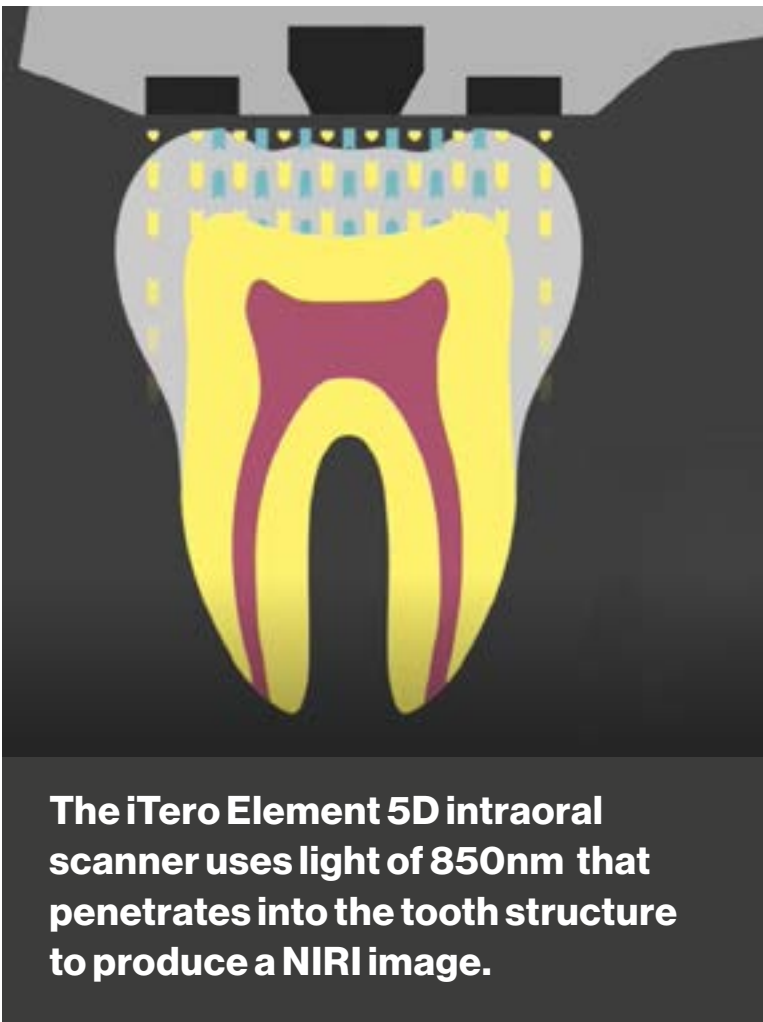
Materials and Methods: The study included 130 adolescents and adults with complete permanent dentition (age >12). All patients underwent visual examination and, if necessary, bitewing radiographs. Proximal and occlusal surfaces, which had not yet been restored, were photographed by a NIR transillumination camera system using light of 780nm rather than ionizing radiation. OF the study patients.85 showed 127 proximal dentin caries lesions that were treated operatively.

Results: Based on the practical experiences to date by the authors, a possible classification of diagnosis was introduced. The main result of the study was that NIR light was able to visualize caries lesions on proximal and occlusal surfaces.

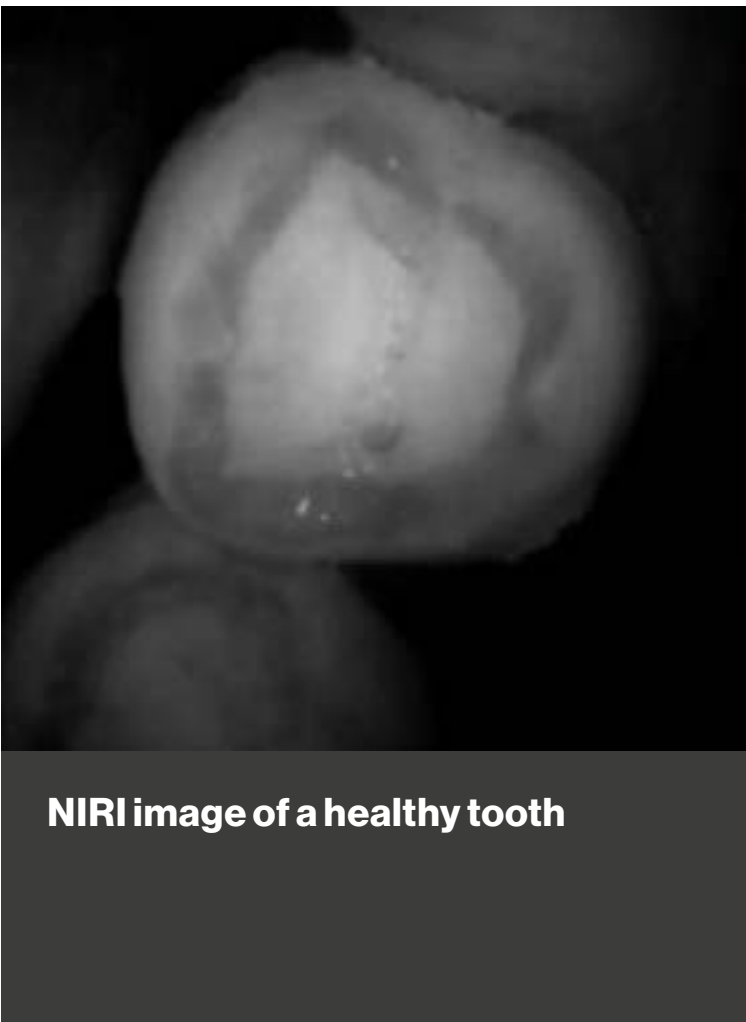
Conclusion: The study suggests that NIR Trans illumination is a method that may help to avoid bitewing radiographs for diagnosis of caries in everyday clinical practice.

*iTero Element 5D is not yet available for sale in the US.*iTero Element 5D is currently available in European Union countries with exception in Switzerland and Norway.

NIRI - A reflective concept of light and its mechanism of action



The iTero Element 5D intraoral scanner uses light of 850nm that penetrates into the tooth structure to produce a NIRI image.



NIRI image of a healthy tooth

NIRI as a diagnostic aid for interproximal caries detection above the gingiva without use of radiation:

Interproximal carious lesions are clinically apparent as a chalky white discoloration. It is estimated that it takes about 4 years for an initial proximal lesion to be seen clinically¹³. Effective diagnosis of interproximal carious lesions is affected by the natural anatomy of the tooth, alignment within the arch and technique sensitivity involved with radiographs.

A study conducted at the University of California (UCLA) School of Dentistry found that when using traditional film radiographs, caries presence and depth are misdiagnosed up to 40% of the time. In addition, healthy teeth are misdiagnosed as having caries up to 20% of the time.

Hence, using effective tools that aid in confirming the presence of a lesion at its earliest stage can prove to be a major advantage while treating patients.

Image interpretation - Healthy tooth

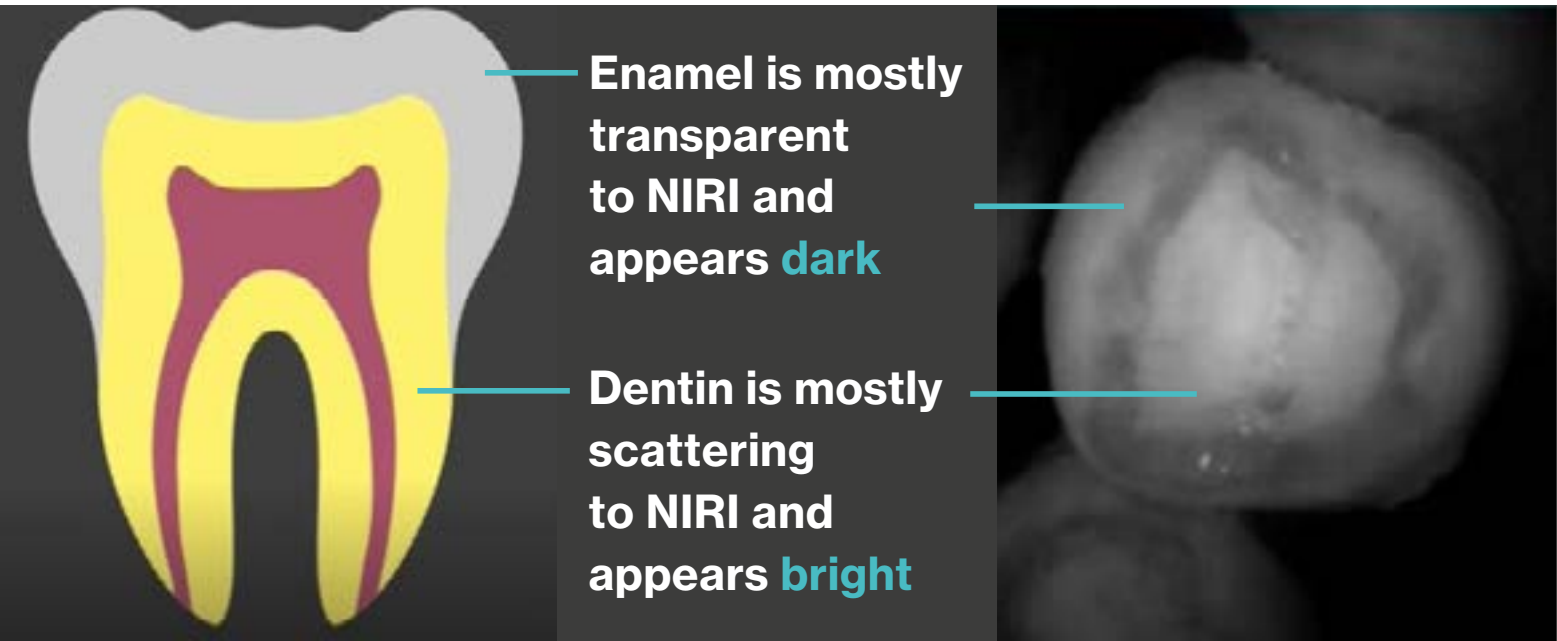
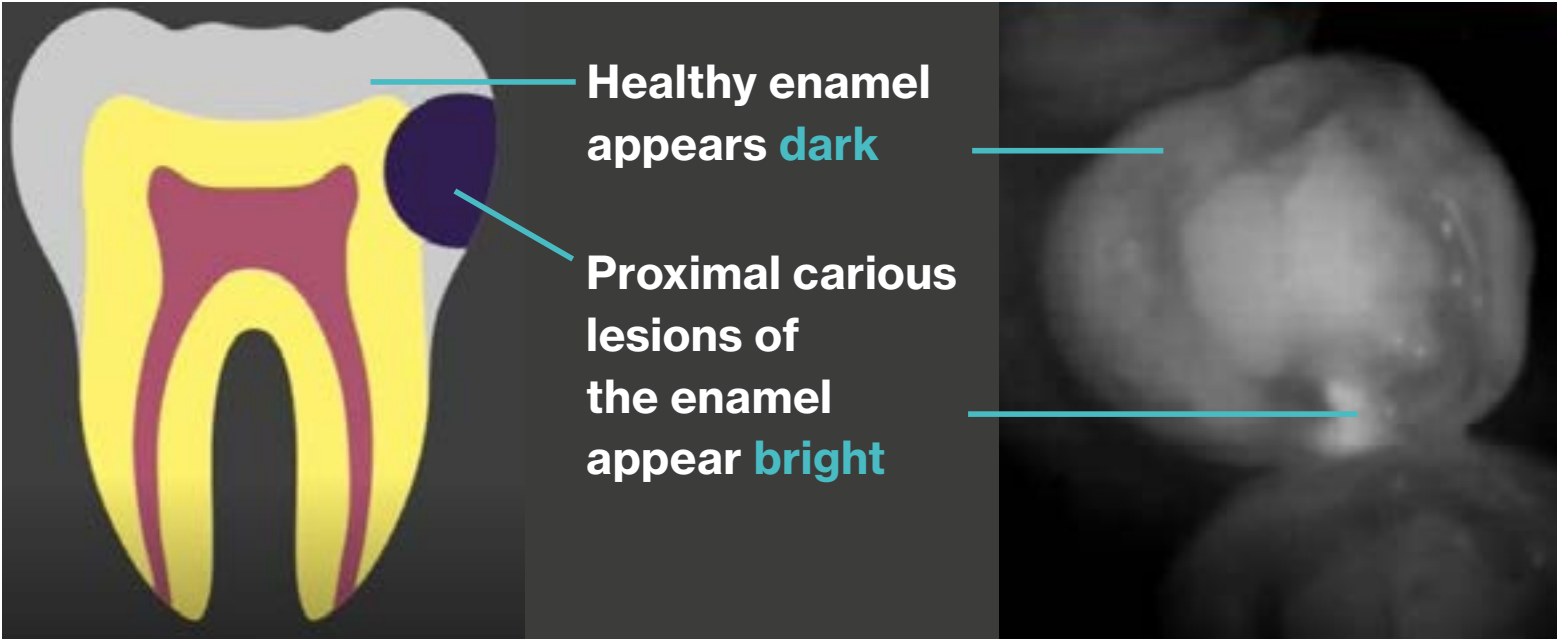


Image interpretation - Tooth with caries



*iTero Element 5D is not yet available for sale in the US.*iTero Element 5D is currently available in European Union countries with exception in Switzerland and Norway.



Case presentation 1:
Healthy tooth structure (maxillary premolar #12)

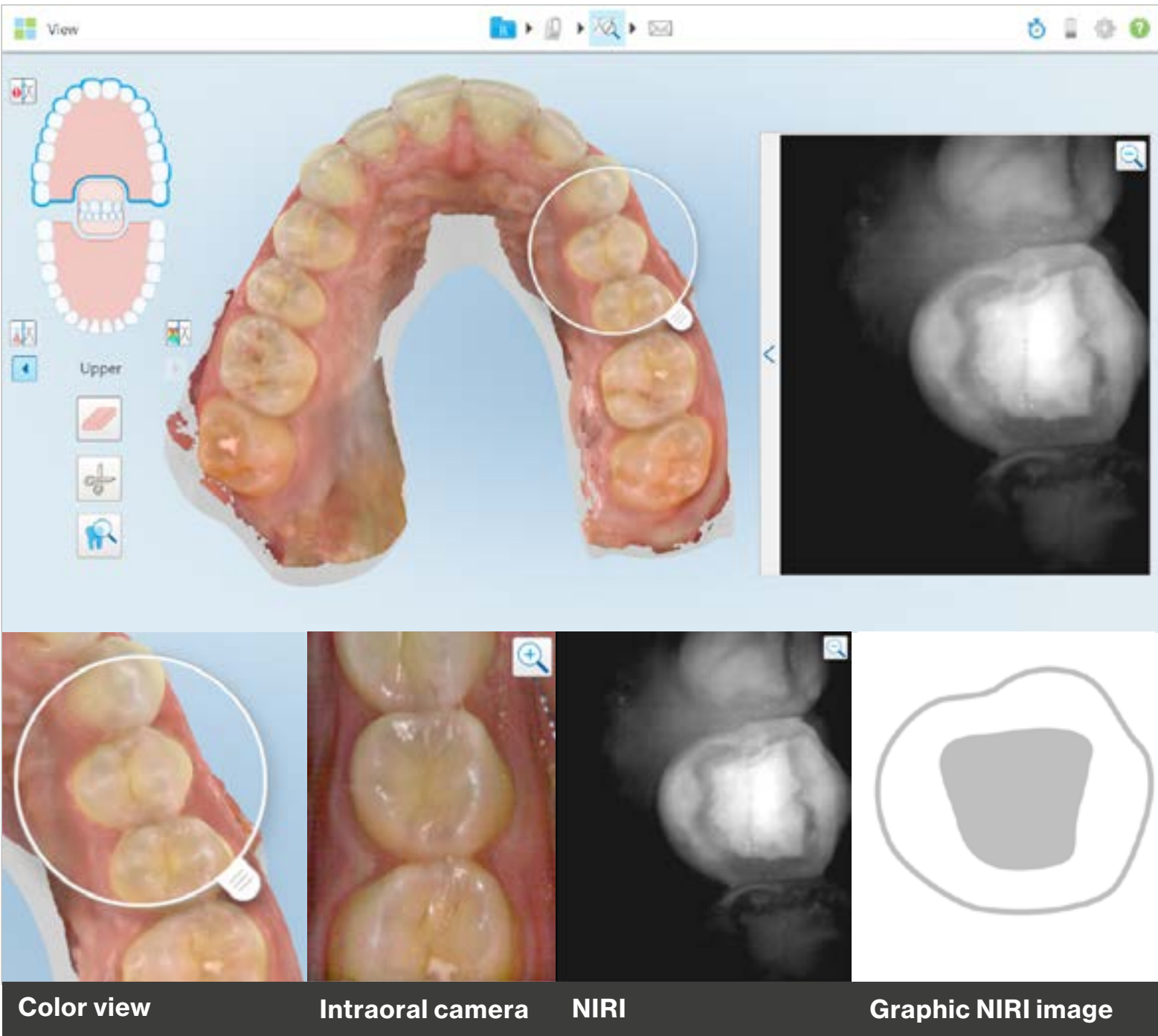


Fig. 1

Figure 1: Image demonstrating the left maxillary premolar #12 as seen in NIRI. A uniformly dark outer enamel layer with a bright center indicating the dentin is a classic example of a healthy tooth structure with no apparent lesions, note the contrast between the enamel-dentin provides a clear, appreciable demaraction between the two.

When examined in multiple modes (color view, intraoral camera view and NIRI) comparisons can be made to aid in differential diagnosis; in this case, uniform color of the tooth with no apparent discoloration or loss of structural integrity indicates the presence of a healthy tooth.

Case presentation 2:
Healthy tooth #10 with an Invisalign attachment

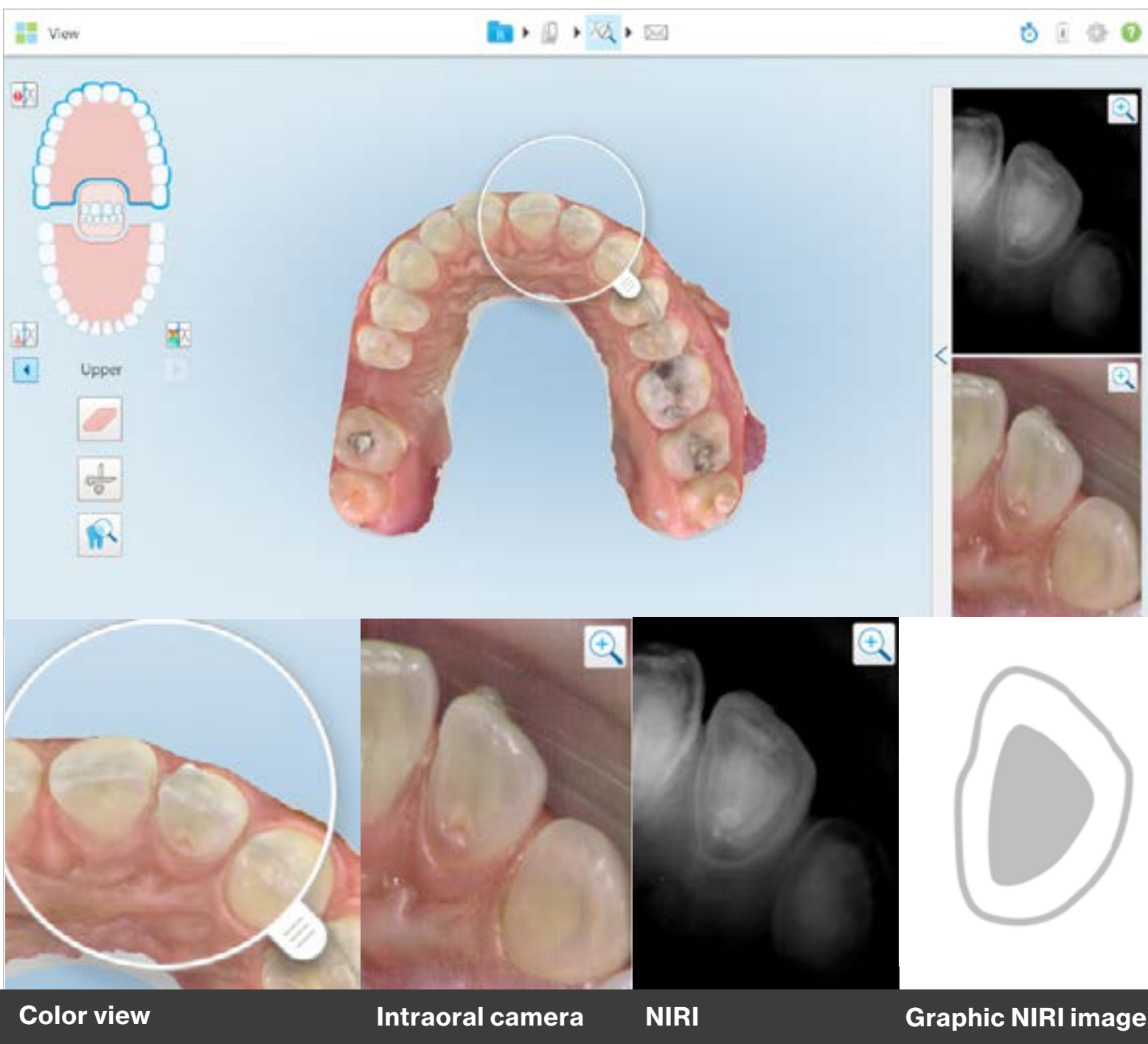


Fig. 2

Figure 2: Image showing (#10) left maxillary lateral incisor with an Invisalign attachment on the buccal. Inspection of the occlusal surface under NIRI suggests a healthy tooth structure with no evidence of carious lesions or enamel demineralization.

Note: The presence of attachments in this case does not have any negative effect on the NIRI image.

*iTero Element 5D is not yet available for sale in the US.*iTero Element 5D is currently available in European Union countries with exception in Switzerland and Norway.



Case presentation 3:
Proximal carious lesion (maxillary premolar #13)

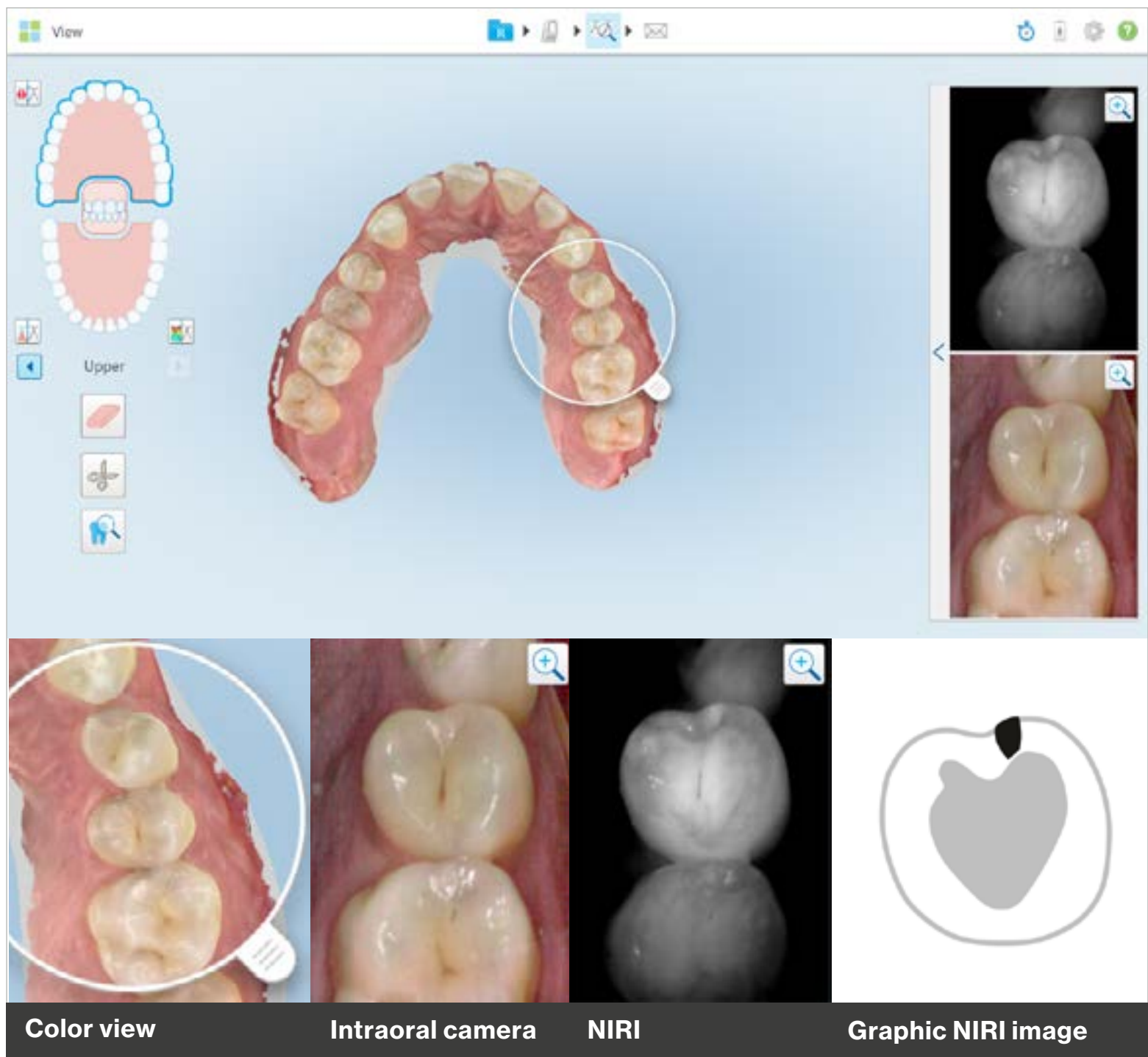


Fig.3

Figure 3: A bright spot in the mesial aspect of the left maxillary premolar indicates the presence of a proximal carious lesion. The position of #12 (rotated and inclined) in relation to #13 creates a narrow area which is difficult to clean and may favor accumulation of food and debris over time. Note in the image from the intraoral camera there is no evidence of underlying carious activity.

Case presentation 4:
Proximal carious lesion and composite filling
(Maxillary premolar #13)

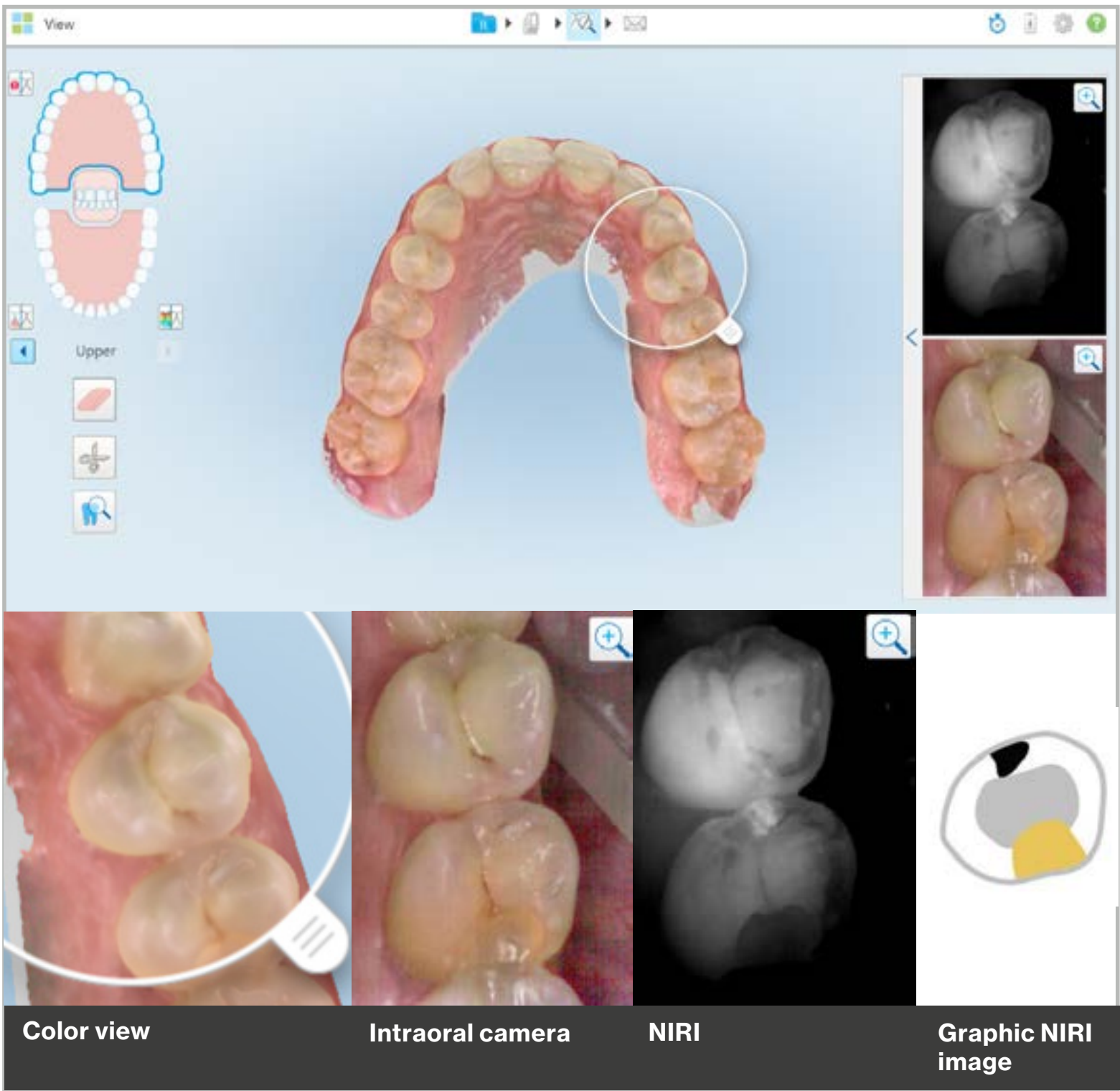


Fig.4

Figure 4: A mesial bright spot in the left maxillary premolar (#13) indicates the presence of a carious lesion. Note the distal of #13 presents with a dark area, on comparison with the color image from the intraoral camera, the presence of an existing composite restoration is confirmed.

*iTero Element 5D is not yet available for sale in the US.*iTero Element 5D is currently available in European Union countries with exception in Switzerland and Norway.

Case presentation 5:
Proximal carious lesion (maxillary premolar #4)

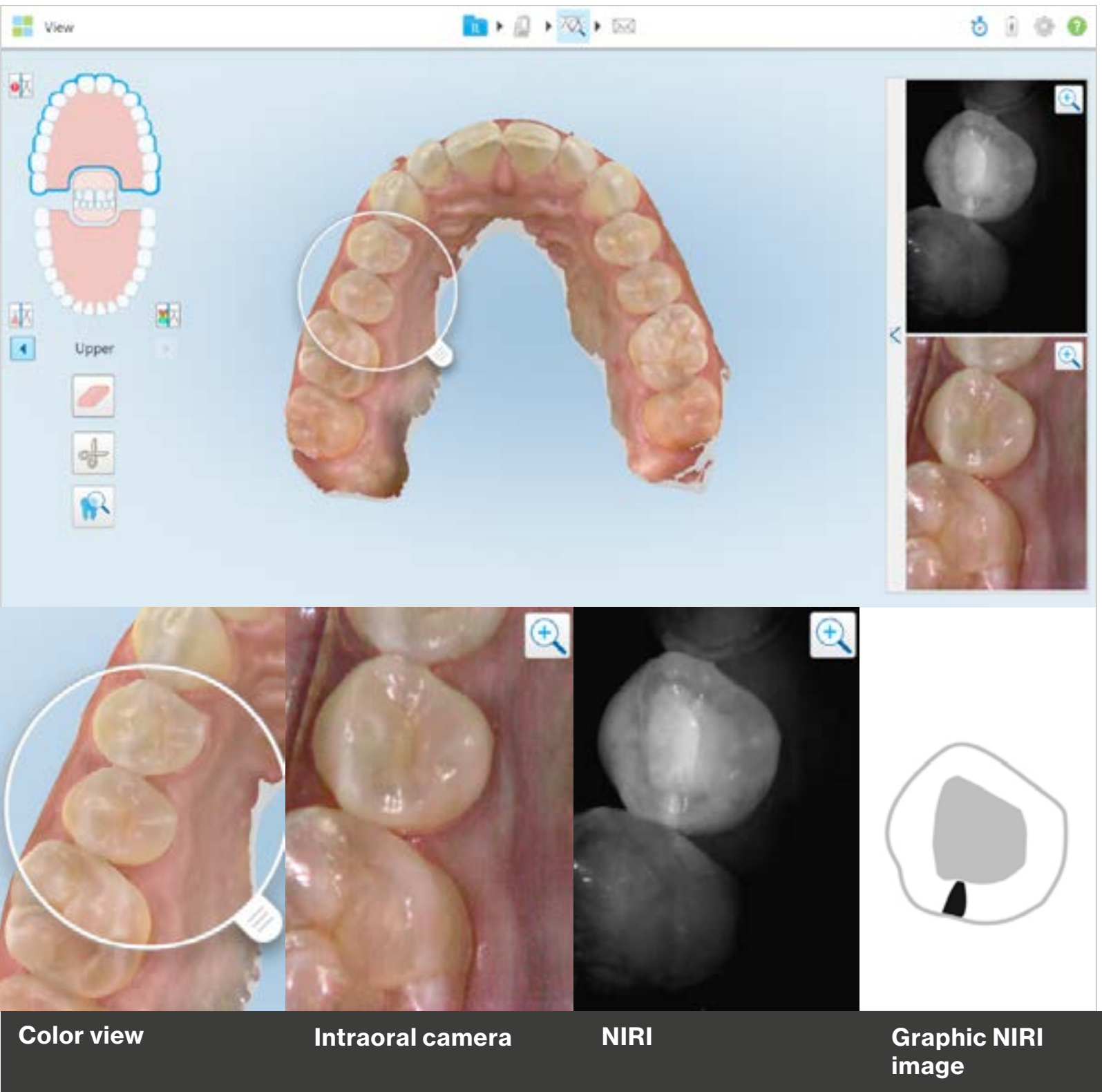


Fig. 5

Figure 5: NIRI image of #4 indicates a bright wedge shaped area advancing towards the DEJ suggesting the presence of carious activity.

Case presentation 6:
Proximal carious lesion (maxillary premolar #12)

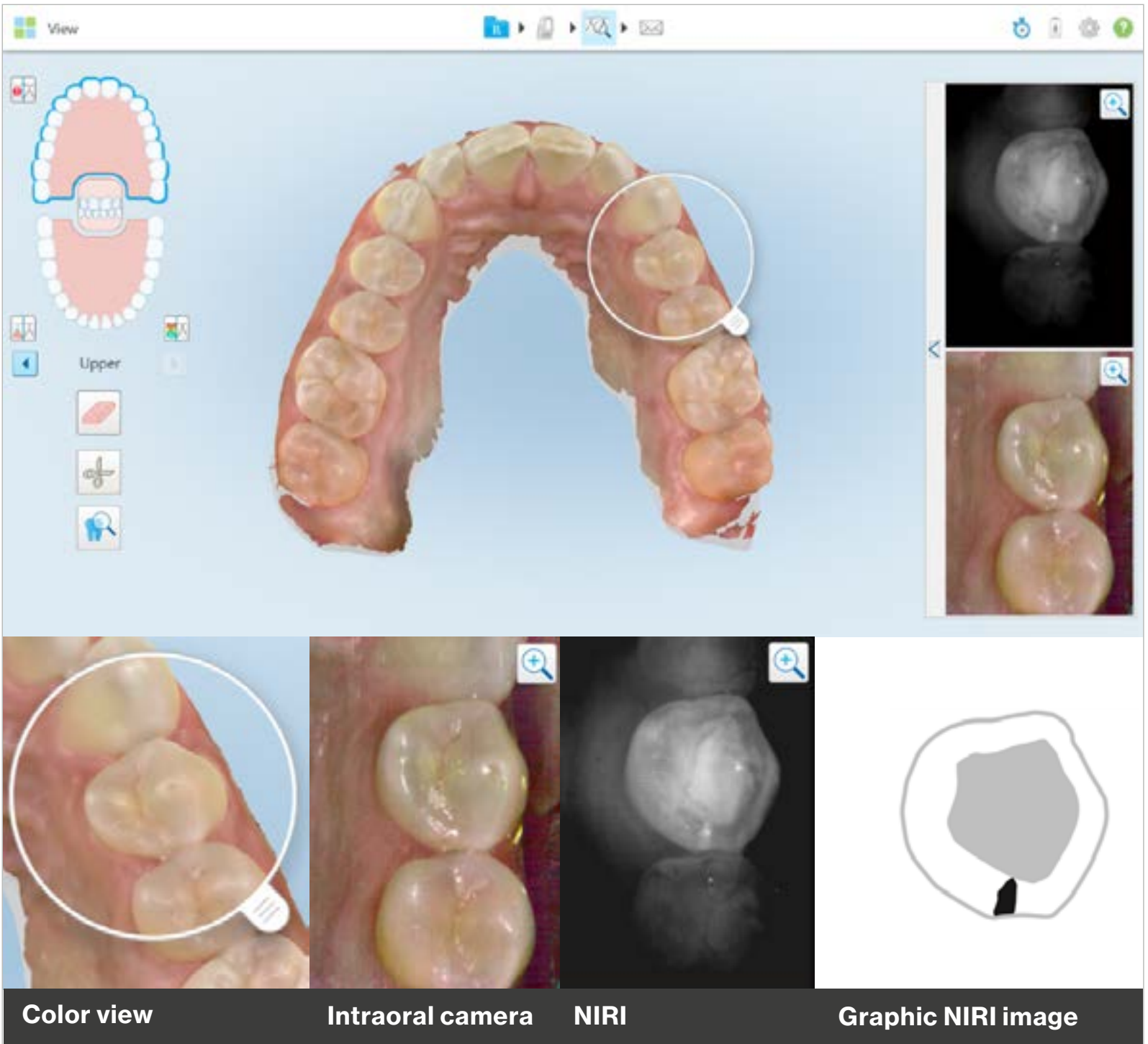


Fig. 6

Figure 6: NIRI image of #12 indicates the presence of a proximal carious lesion (distal).

*iTero Element 5D is not yet available for sale in the US.*iTero Element 5D is currently available in European Union countries with exception in Switzerland and Norway.

Case Presentation 7:
Healthy tooth (maxillary left premolar #12)

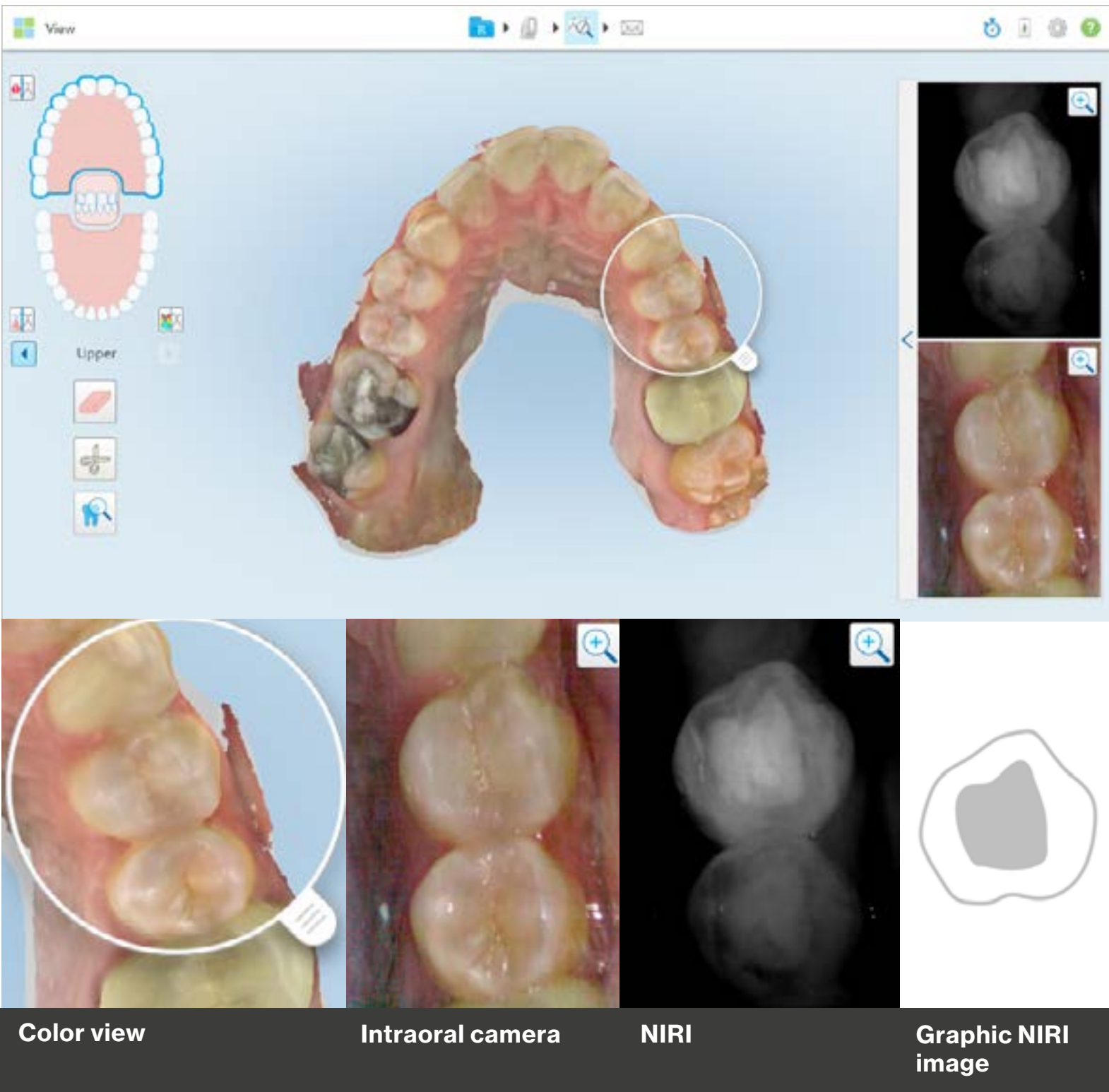


Fig. 7

Figure 7: Image showing (#12) left maxillary premolar, corresponding NIRI image suggests a healthy tooth structure with no evidence of carious lesions or enamel demineralization

Case presentation 8:
**Dental fluorosis (mandibular left canine #22),
distal interproximal carious lesion (#21)**

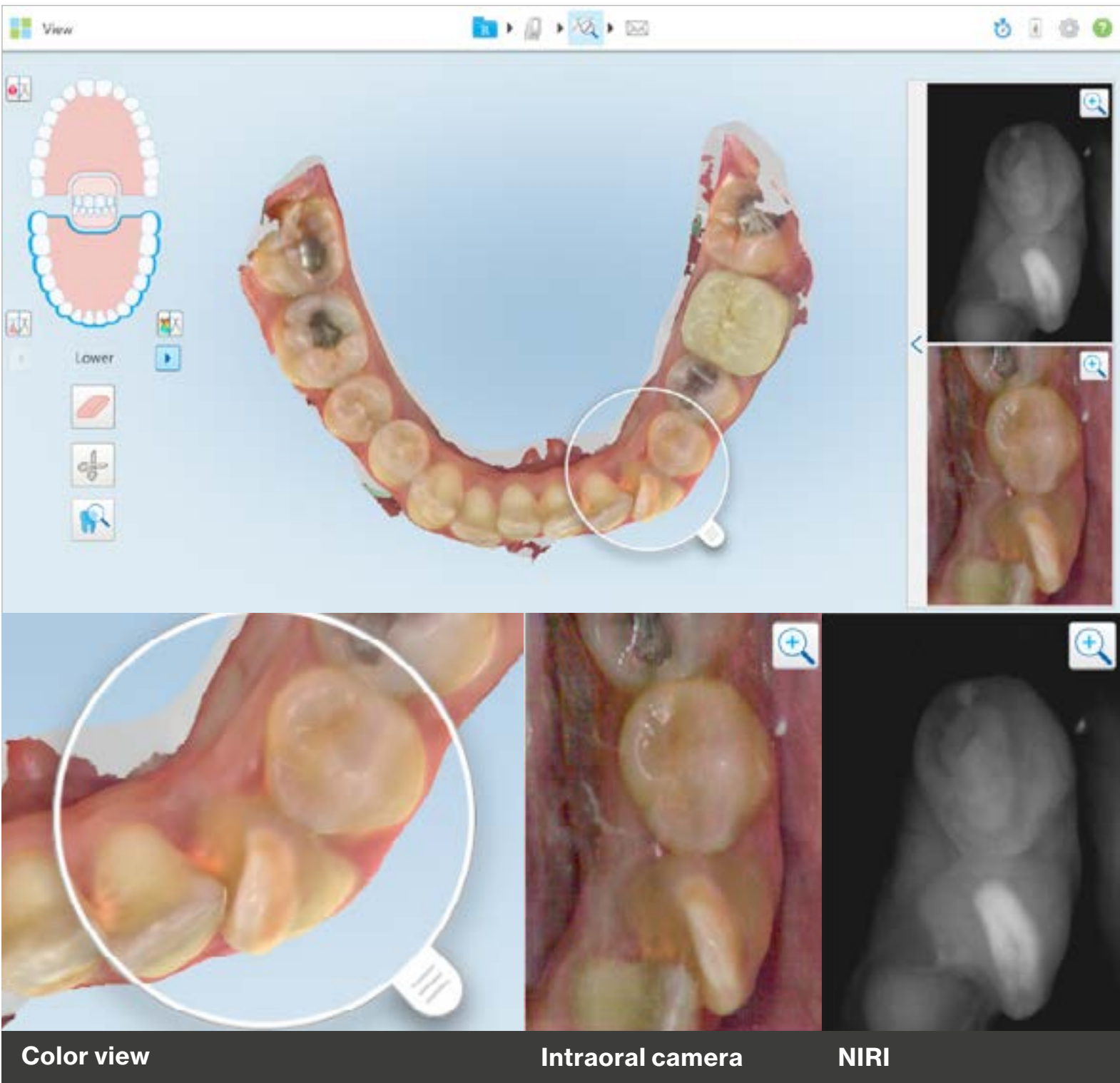


Fig. 8

Figure 8: Dental fluorosis is one of the most common disorders of the enamel presenting with characteristic permanent discoloration. This case is particularly interesting as it shows the ability of NIRI to detect the changes in the structural integrity of enamel. Note: Instances like these may mimic the presence of caries, in such instances it is valueable to make comparisons with color images before arriving at a conclusion. Also seen in this image is a distal interproximal carious lesion on #21.

*iTero Element 5D is not yet available for sale in the US.*iTero Element 5D is currently available in European Union countries with exception in Switzerland and Norway.

Case presentation 9:
Bonded mandibular lingual arch wire

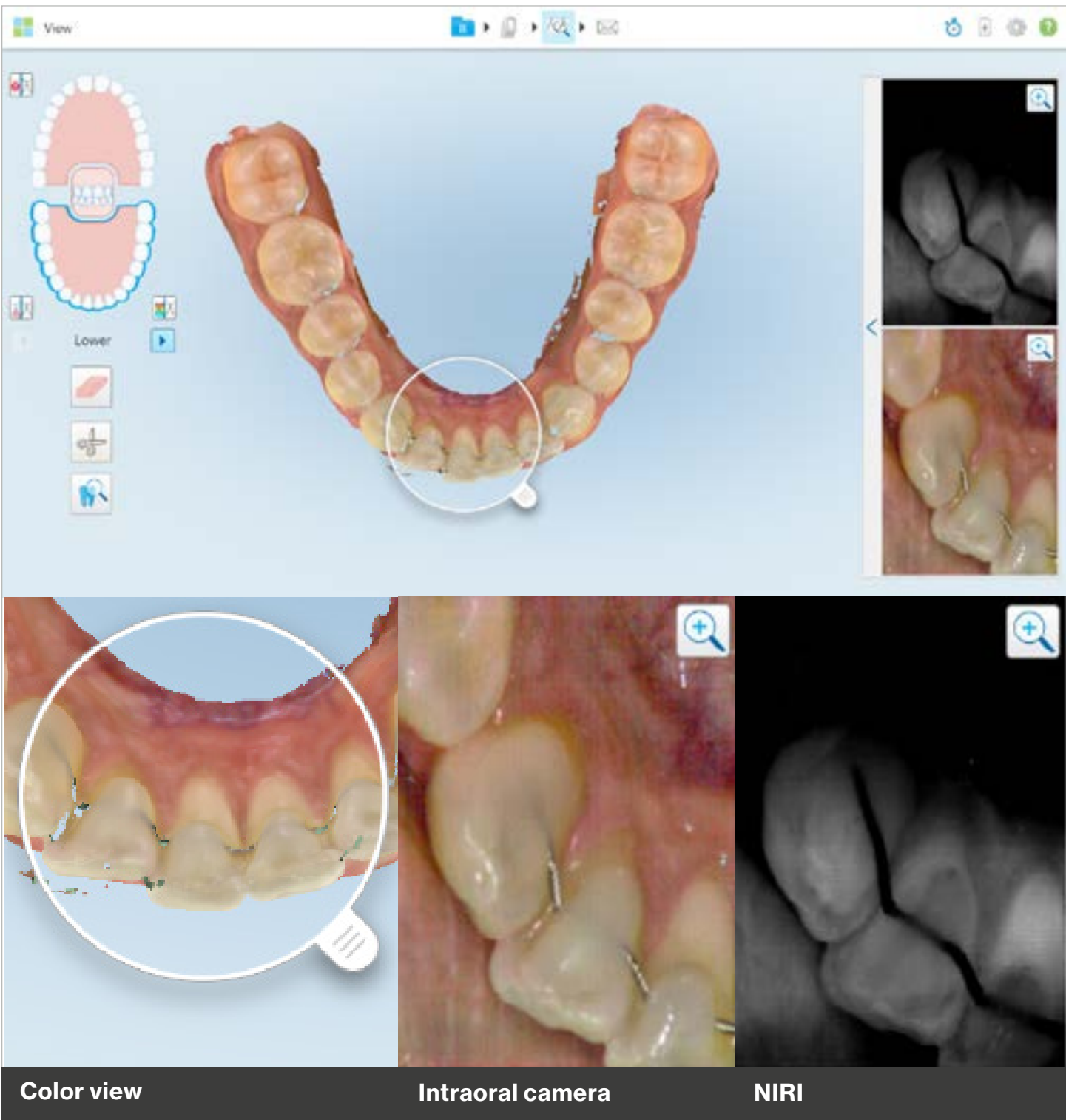


Fig. 9

Figure 9: Image shows a good example of a bonded lingual arch wire in the mandibular anteriors. Note: The NIRI image remains absolutely clear of any obstacles and ready for interpretation.

Case presentation 10:
Stains in the mandibular anteriors (lingual)

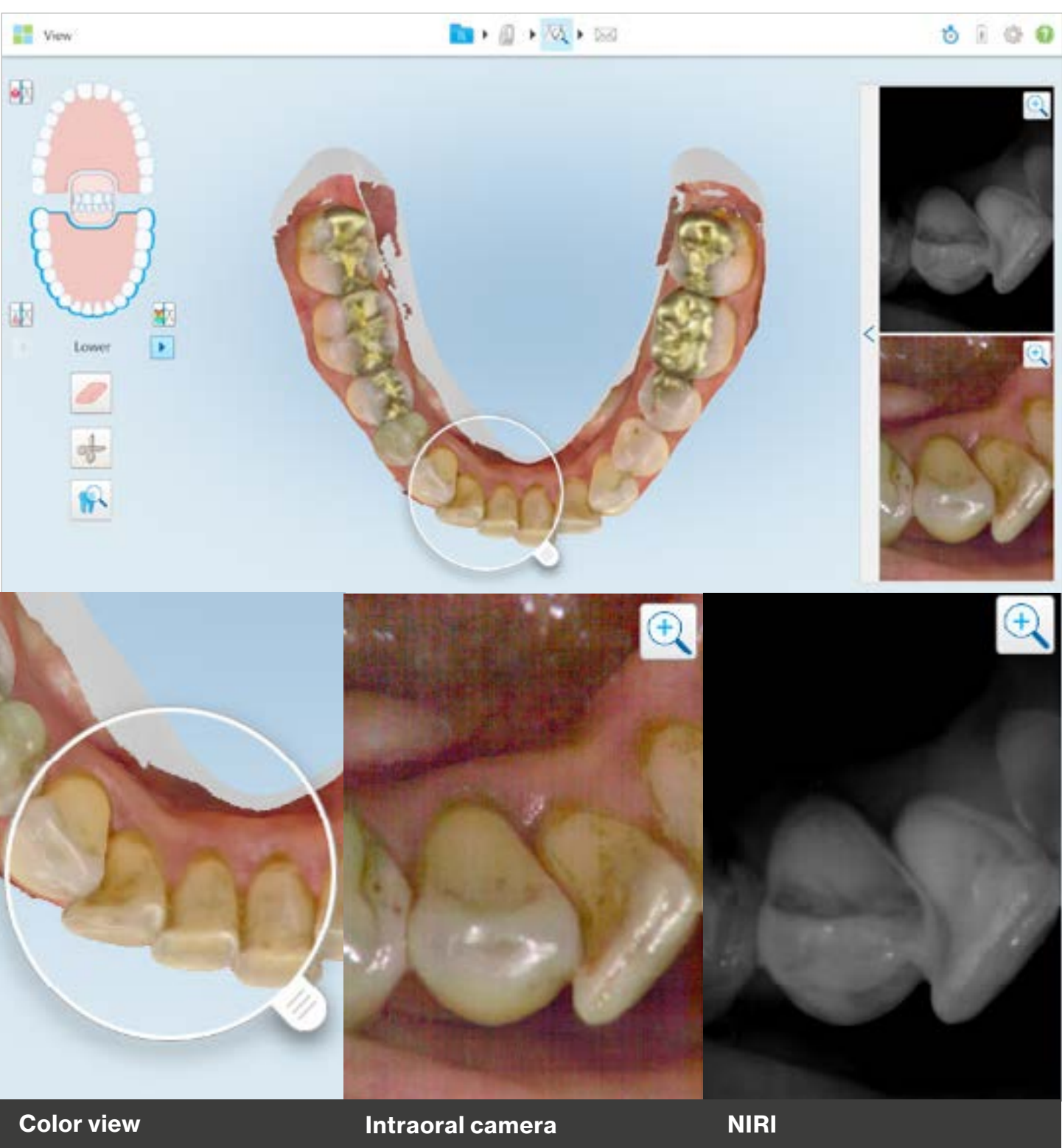


Fig. 10

Figure 10: Stains are commonly seen in the mouth especially in individuals who have a habit of smoking. The above image suggests that stains do not have any significant effect on the resultant NIRI image.

*iTero Element 5D is not yet available for sale in the US.*iTero Element 5D is currently available in European Union countries with exception in Switzerland and Norway.

Case presentation 11:
Proximal carious lesion (mesial#4 and distal #5) with treatment plan

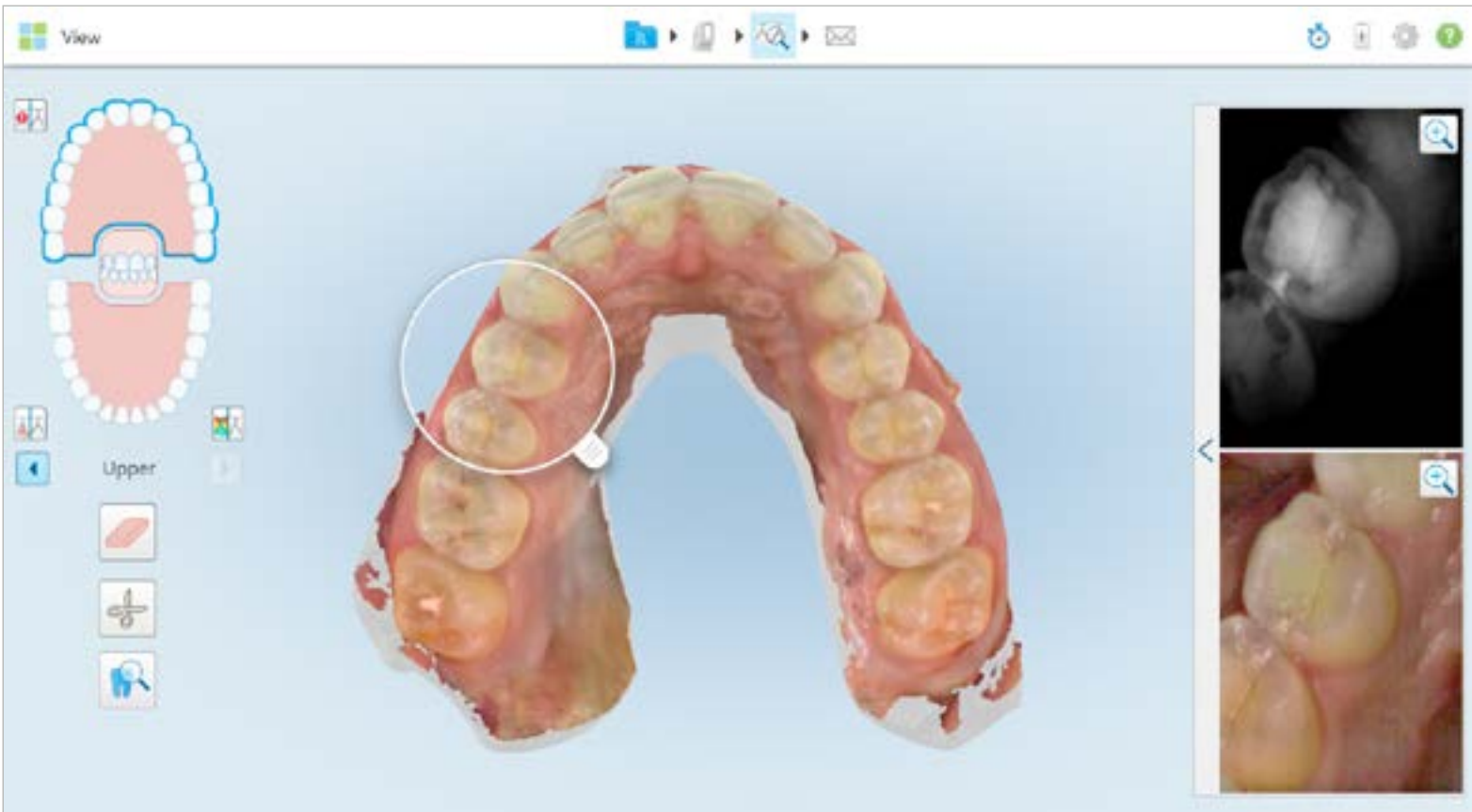


Fig.11

Figure 11: Image on the left shows a patient scan from a routine dental check-up appointment. Patient had no visual intraoral signs of caries or any associated pain. Find below a detailed summary of the steps taken in the diagnosis and treatment planning which lead to successfully restoring a proximal carious lesion in #5 in the early stages completed in a single visit.

01




Image from the intraoral camera

On visual examination, small white surface spots were present on #5.

Patient did not feel any pain associated with #5.

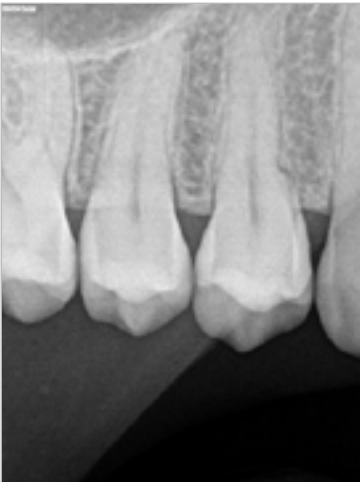
05



Graphic representation

Graphic representation of #5

02




Periapical radiographs

Periapical x-rays were prescribed as a part of routine check-up.

Radiograph suggested no significant findings.


06



Treatment procedure photograph

Based on the findings from NIRI, on removal of superficial tooth structure, brown, decayed carious lesion in the distal aspect was found.


03



iTero scan in colour

Findings from the scan were same as that from the intra oral camera.


07



Post treatment photograph

Based on the findings from NIRI, on removal of superficial tooth structure, brown, decayed carious lesion in the distal aspect was found.

04



NIRI image

The NIRI image of the same area shows bright spots in the distal area of #5 suggesting the presence of a proximal carious lesion advancing towards the DEJ.

*iTero Element 5D is not yet available for sale in the US.*iTero Element 5D is currently available in European Union countries with exception in Switzerland and Norway.



Case presentation 12:
Calculus and stains in the mandibular anterior teeth

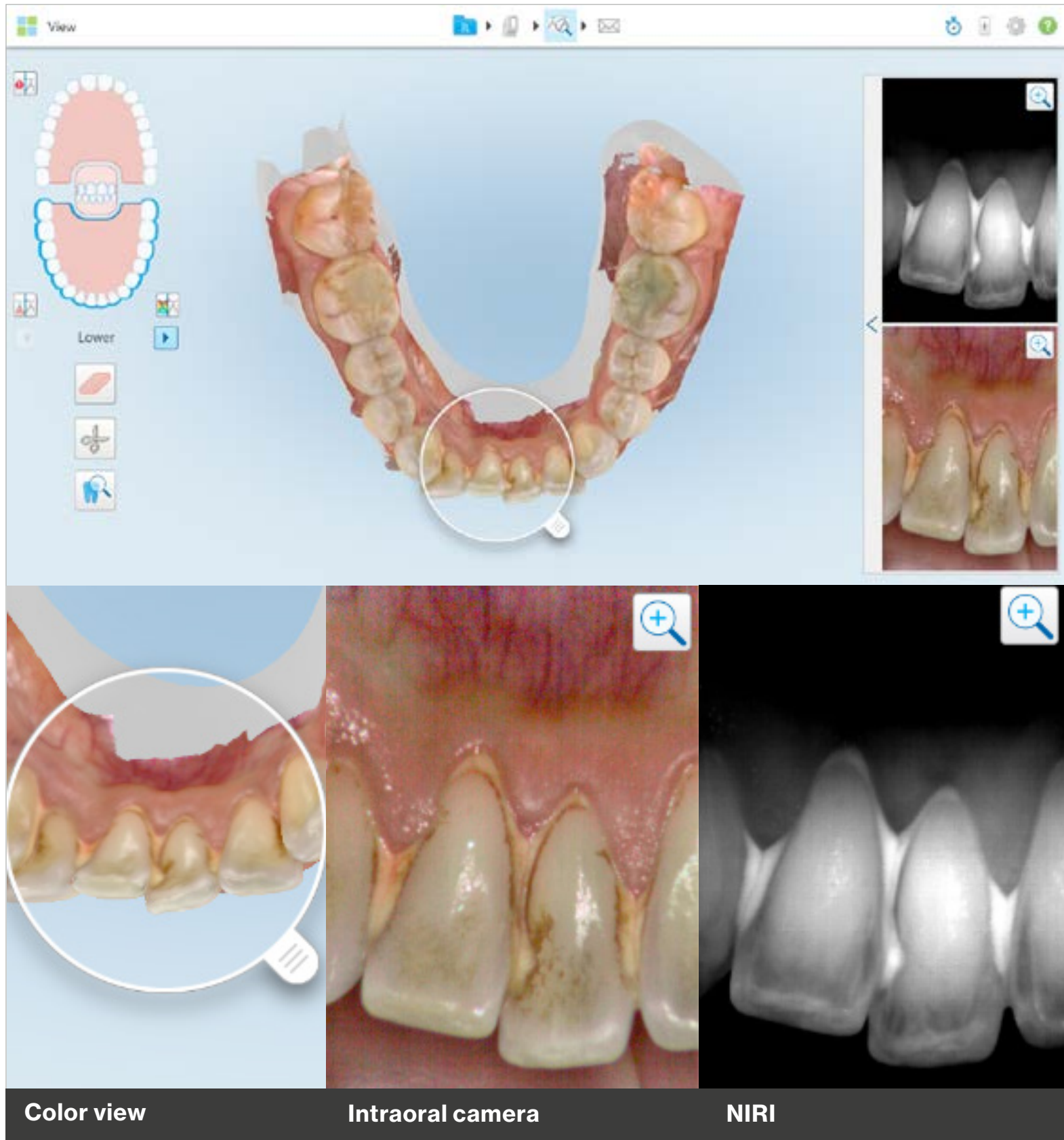


Fig. 12

Figure 12: The formation of calculus can be triggered by multiple factors; most commonly diet, poor oral hygiene, systemic disease or medication. The presence of calculus does not have any significant effect on the tooth in NIRI; Calculus itself presents as areas of brightness in NIRI.

Case presentation 13:
Proximal carious lesion in the mesial of #31 with treatment planning

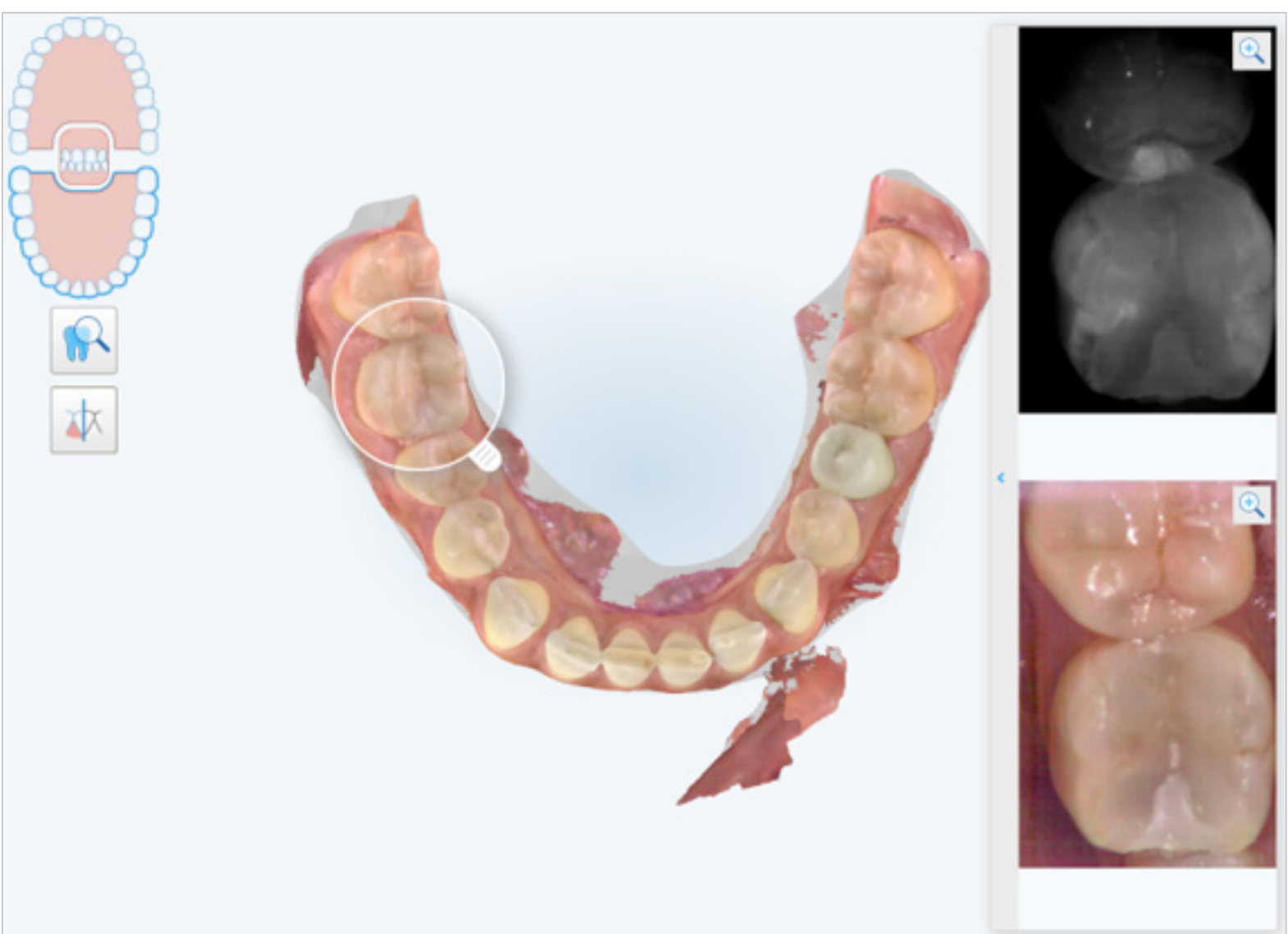
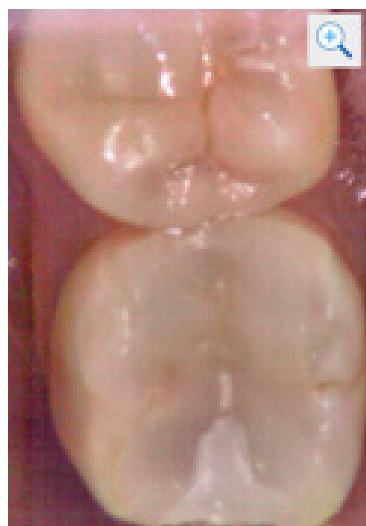


Fig. 13

Figure 13: Image to the left shows a patient scan from a routine dental check up appointment. Patient had no symptoms of caries or any associated pain. Find below a detailed summary of the steps taken to diagnose and plan treatment for a proximal carious lesion in the mesial of tooth #31.

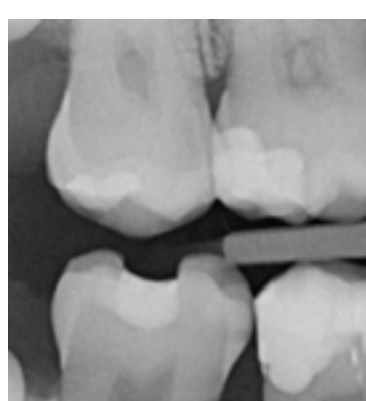
*iTero Element 5D is not yet available for sale in the US.*iTero Element 5D is currently available in European Union countries with exception in Switzerland and Norway.

01

**Image from the Intraoral camera**

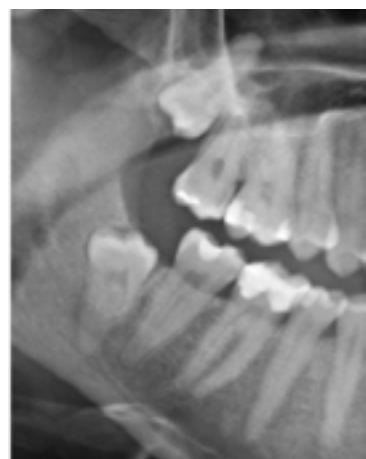On visual examination, mild discoloration with existing composite restorations on tooth #30 and #31 were seen.

02

**Bitewing Radiographs**

Bite wing radiographs were prescribed as a part of the routine check up.

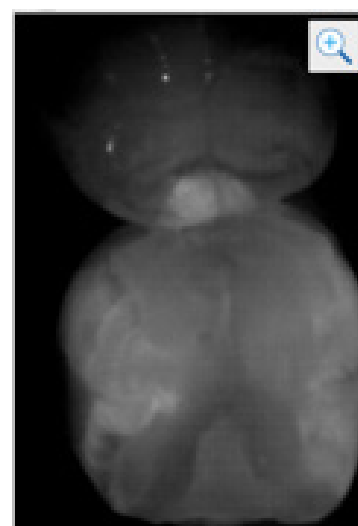03

**OPG**

An OPG was also taken for this case, OPG verifies the existing restorations on tooth #30 and #31.

The radiograph indicates a presence of an interproximal lesion on #31 and an existing restoration on #30

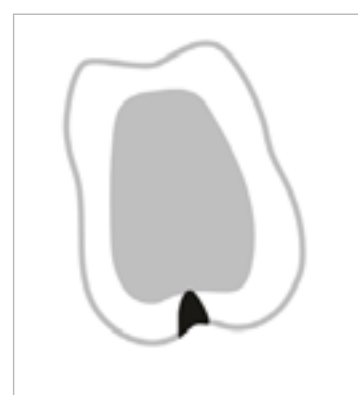04

**NIRI image**

The NIRI image suggests a bright conical lesion with its apex directed towards the dentin suggests the presence of a carious lesion in the mesial of #31.

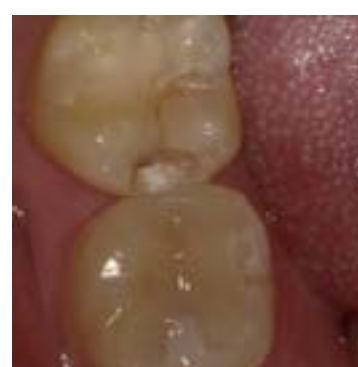Also seen in this image is a dark area in the mesial of #30 suggesting presence of a restoration.

05

**Graphic representation**

Graphic representation of #31.

06

**Restorative procedure**

With the NIRI image used as a reference, the affected tooth structure was removed and was followed by a restorative procedure.

Limitations of the technology: Current limitations of the technology are mostly around existing restorations. In the presence of restorations such as amalgam or composite resins, NIRI is unable to penetrate through the structure of the tooth. The insufficient data from the scan in these scenarios causes a blurry, dark and ill-defined resultant image that is not suitable for examination.

Instances mimicking interproximal caries: Teeth involving enamel demineralization conditions such as tooth wear, enamel hypoplasia and fluorosis (as seen in case 7) may mimic the presence of interproximal caries under NIRI; some dental cements (such as oxides and phosphates) may also exhibit the same behavior on interaction with NIRI, best practices to avoid misinterpretation in such cases would be to compare the NIRI images with the color images from the scan and other applicable examination techniques.

Case presentation 14:
Composite restoration (mandibular right #29#30)

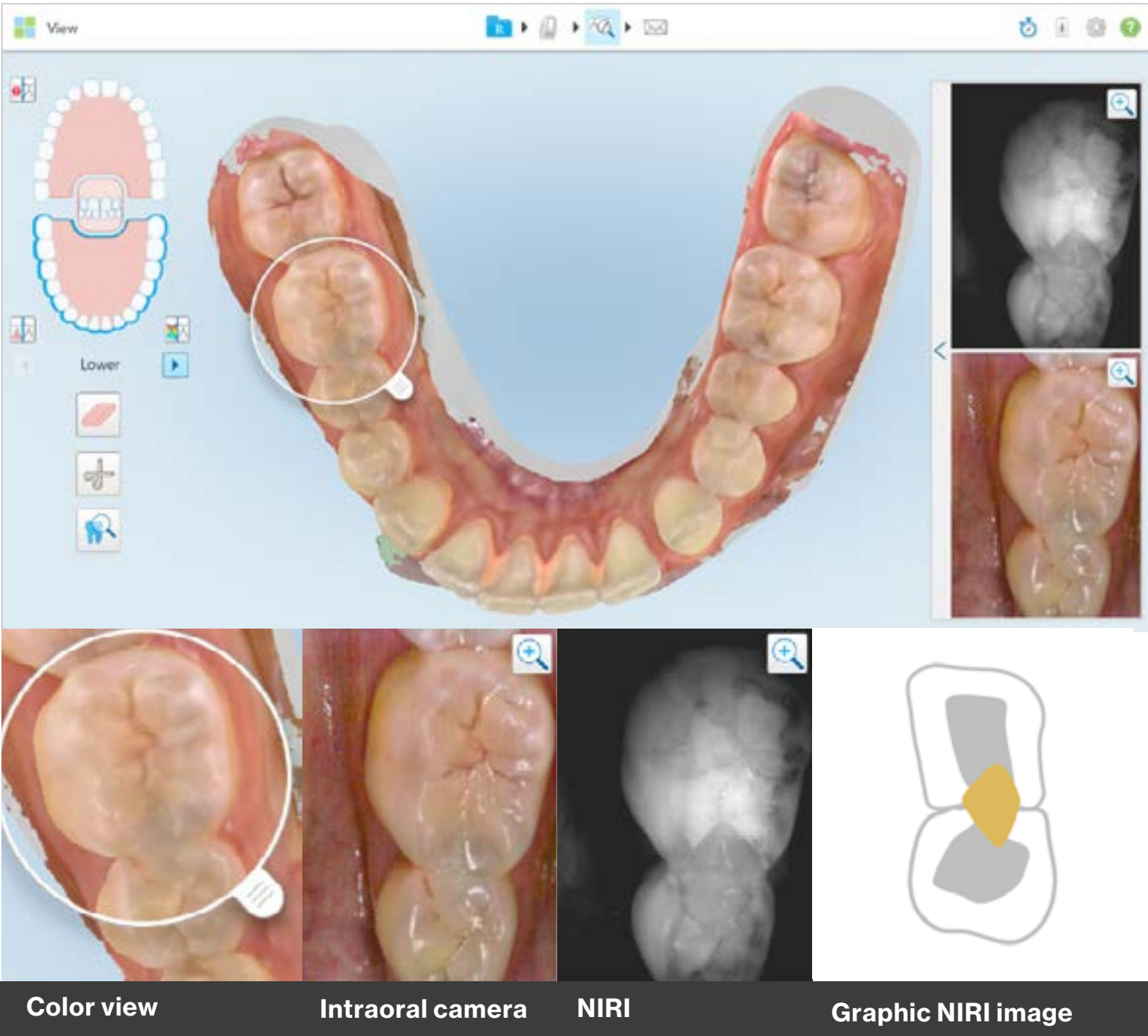

Fig. 14

Figure 14: Composite restoration in the distal of #29 and mesial of #30 presents as a dark area which is comparatively dull in contrast when compared with the adjacent structures. The inability of Near infrared light to pass through existing restoration results in the presentation of a dark area.

Case presentation 15:
Amalgam restoration (maxillary right molar #3)

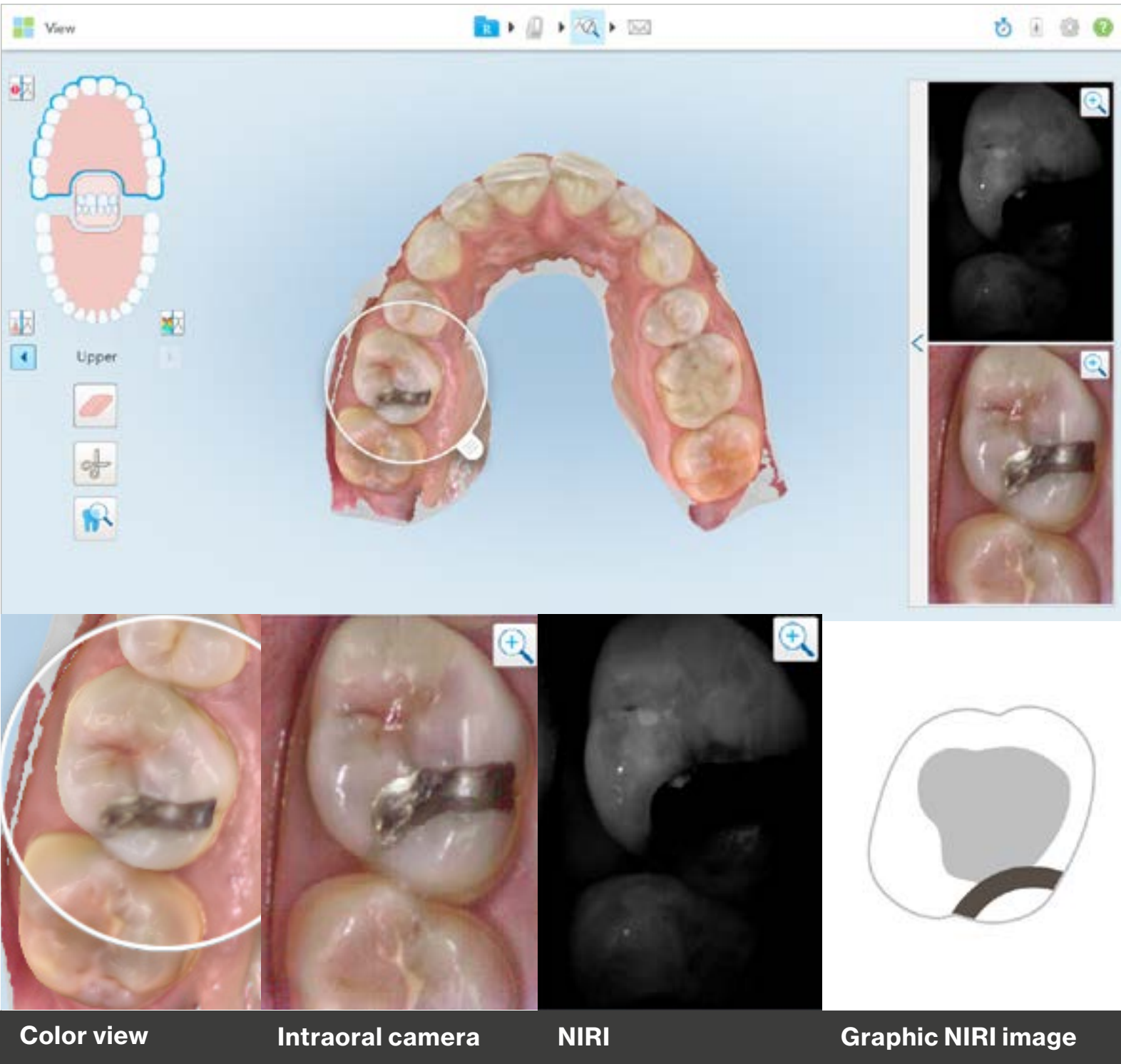


Fig. 15

Figure 15: Existing amalgam restorations (as seen to the left). Amalgam being an alloy creates a highly scattering effect on Near infrared light resulting in a dark image with ill defined anatomical landmarks which makes the image unsuitable for interpretation. In such cases, comparison with other available data is recommended.

*iTero Element 5D is not yet available for sale in the US.*iTero Element 5D is currently available in European Union countries with exception in Switzerland and Norway.



Conclusion: Constant improvements in dental technology are shaping the way clinicians practice across the globe. Interactive technology also serves as an added benefit to patients of all ages who may be apprehensive about their dental visits.

As seen from all the case presentations in this article, NIRI has demonstrated to be an effective tool in aiding the diagnosis and monitoring early stages of interproximal caries above the gingiva in a wide array of clinical scenarios, ultimately leading towards the successful management of caries even in its earliest stages. NIRI, which is non-invasive by nature, can be used as frequently as required to monitor the patient’s oral health and provide the patient with chairside education, which enables patients to appreciate and understand the finer details associated with their oral health.

The iTero Element 5D imaging system helps turn the concept of comprehensive dentistry into a reality in every dental practice.

*iTero Element 5D is not yet available for sale in the US.*iTero Element 5D is currently available in European Union countries with exception in Switzerland and Norway.

References

¹Diagnosis and Management of Dental Caries Throughout Life National Institutes of Health Consensus Development Conference Statement, March 26–28, 2001

²Oral Health: The Silent Epidemic; the Surgeon Generals Perspective

Regina M. Benjamin, MD, MBA, VADM, USPHS

³The Global Burden of Oral Diseases and Risks to Oral Health, W.H.o Policy and Practice

⁴Dalli M, Çolac H, Hamidi MM. Minimal intervention concept: a new paradigm for operative dentistry. J Invest Clin Dent. 2012;3(3):167–175

⁵J. D. B. Featherstone and D. Young, "The need for new caries detection methods," Lasers in Dentistry V, San Jose, CA, Proc. SPIE 3593, 134-140 (1999).

⁶: Near-Infrared Imaging of Dental Decay at 1310 nm Daniel Fried, PhD*, Michal Staninec, DDS, Cynthia L. Darling, PhD University of California San Francisco (UCSF) School of Dentistry, San Francisco, California

⁷Effectiveness of Near-Infrared transillumination in early caries diagnosis

Mirela-Marinova – Tokorova

Clinical Evaluation of Near Infrared light transillumination as an interproximal caries detection tool in a large sample of patients in a private practice – Francesco Russotto,F Tirone,Stepho Salzano, Borga, Ferraro,S.Botasso 2016

DIAGNOcam--a Near Infrared Digital Imaging Transillumination (NIDIT) technology.

Abdelaziz M, Krejci I

⁸Fried D, Glena RE, Featherstone JD, Seka W. Nature of light scattering in dental enamel and dentin at visible and nearinfrared wavelengths. Applied Optics. 1995;34(7):12781286.

⁹Comparison of diagnostic methods for early interproximal caries detection with near-infrared light transillumination: an in vivo study Ismail Hakki Baltacioglu and Kaan Orhan

¹⁰Evaluation of two imaging techniques: near-infrared transillumination and dental radiographs for the detection of early approximal enamel caries. Maia AM1, Karlsson L, Margulis W, Gomes AS.

¹¹Clinical evaluation of near-infrared light transillumination (NIRT) as an interproximal caries detection tool in a large sample of patients in a private practice Francesco Russotto1 , Federico Tirone1,*, Stefano Salzano1 , Francesco Coero Borga1,*, Davide Paolino2 , Alberto Ferraro1 , and Samanta Botasso3

Journal of Radiology and Imaging

¹²Caries Detecion and Diagnostics with near – infrared light transillumination : Clinical experiences

Friederike Sochtig,DDS/Reinhard Hickel,DDS./Jan Kuhnisch,DDS,MDS

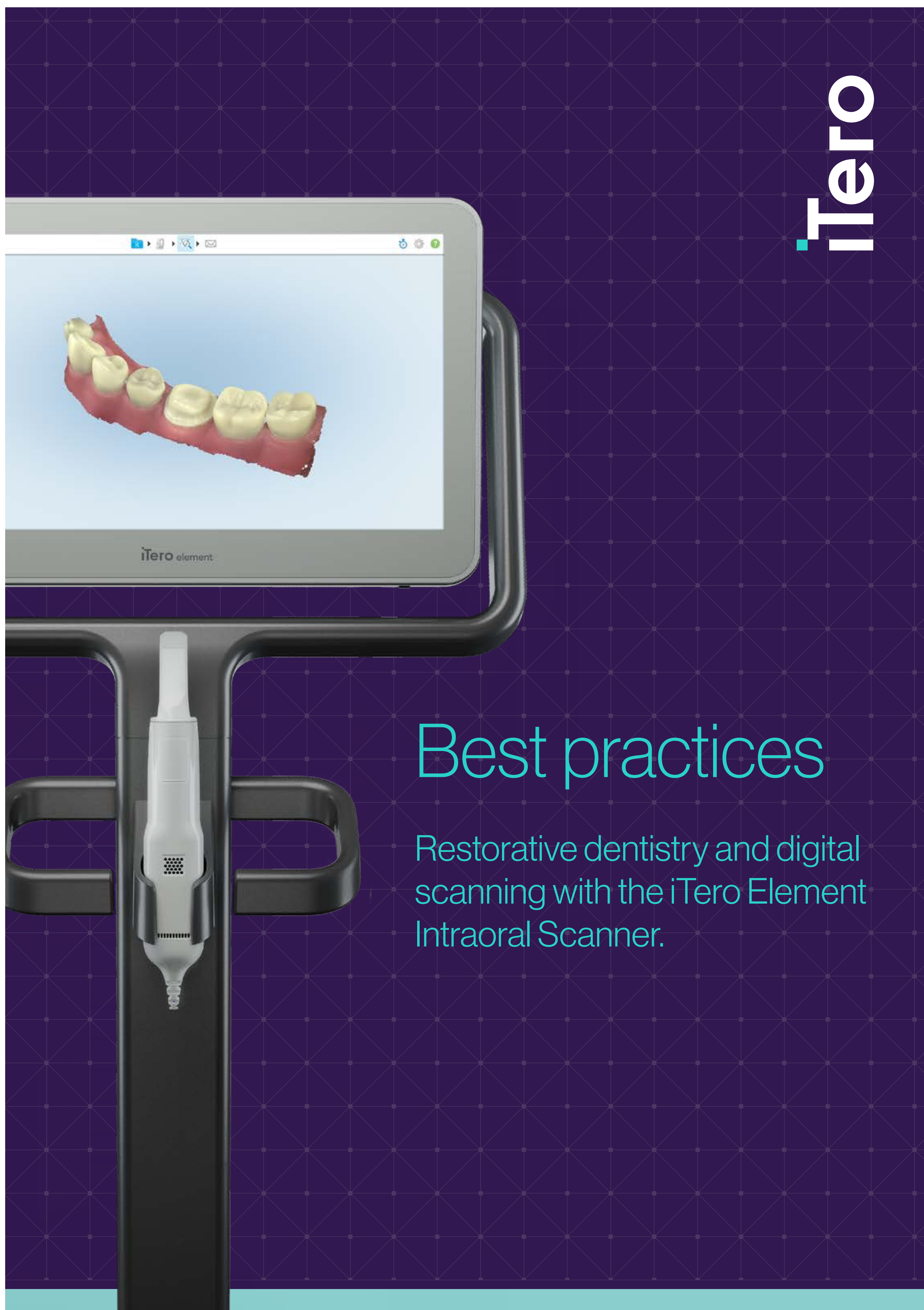
¹³Elsevier Textbook of Oral Medicine Oral diagnosis and Oral radiology edition 2, Editions Ravikiran Ongole BDS,MDS,Praveen BN, BDS,MDS

¹⁴White SC, Hollender L, Gratt BM. Comparison of xeroradiographs and film for detection of proximal surface caries. J Am Dent Assoc. 1984;108:755-759.

Special acknowledgement: Align would like to thank Dr. Ingo Baresel, Dr.Olivier Boujenah, Dr. Timo Weihard for their contribution to this article.

© 2019 Align Technology, Inc. All rights reserved. Invisalign, iTero, iTero Element, iTero element 5D, the iTero logo, among others, are trademarks and/or service marks of Align Technology, Inc. or one of its subsidiaries or affiliated companies and may be registered in the U.S. and/or other countries. www.iTero.com | MKT-0003041 Rev B

*iTero Element 5D is not yet available for sale in the US.*iTero Element 5D is currently available in European Union countries with exception in Switzerland and Norway.



Best practices

Restorative dentistry and digital scanning with the iTero Element Intraoral Scanner.

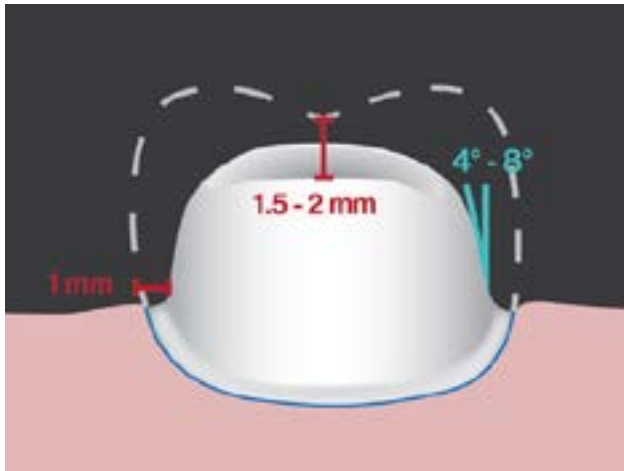

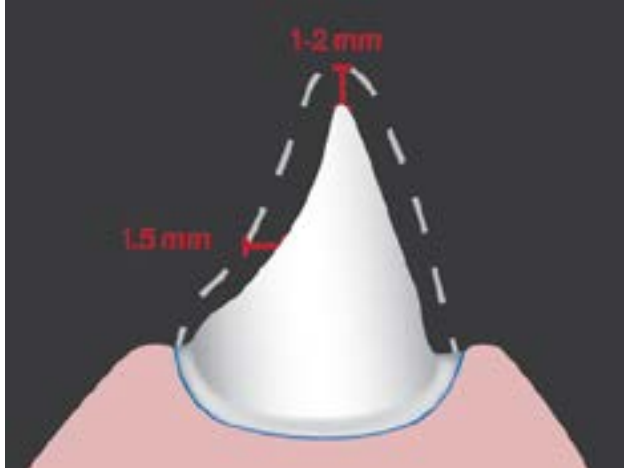

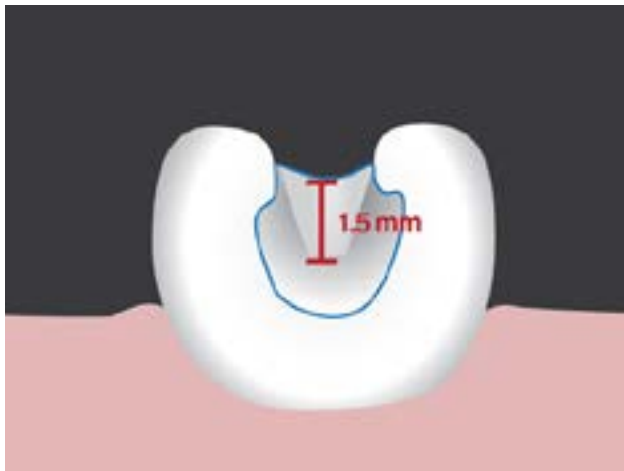

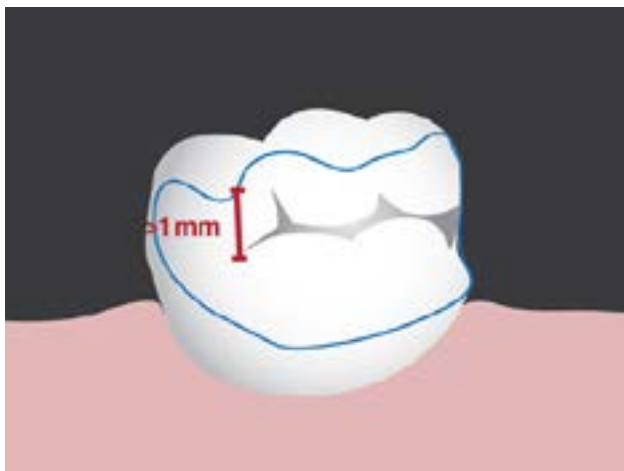

To download the full PDF please [click here](#)

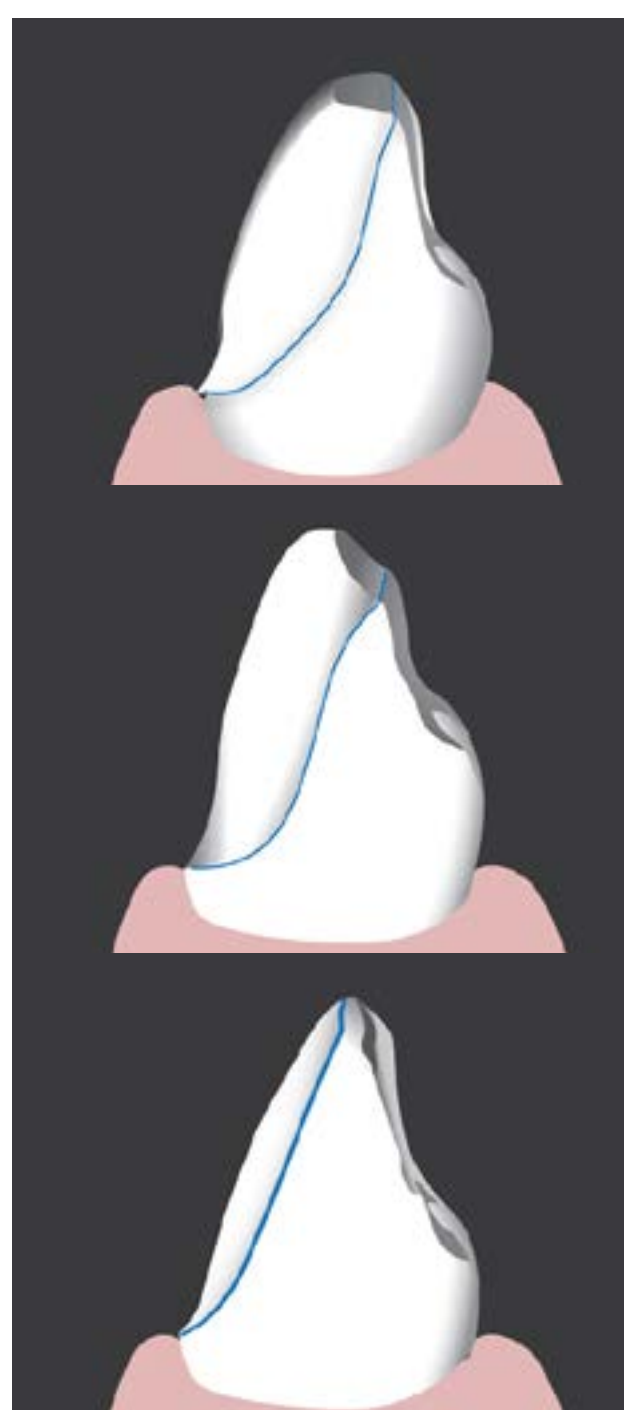
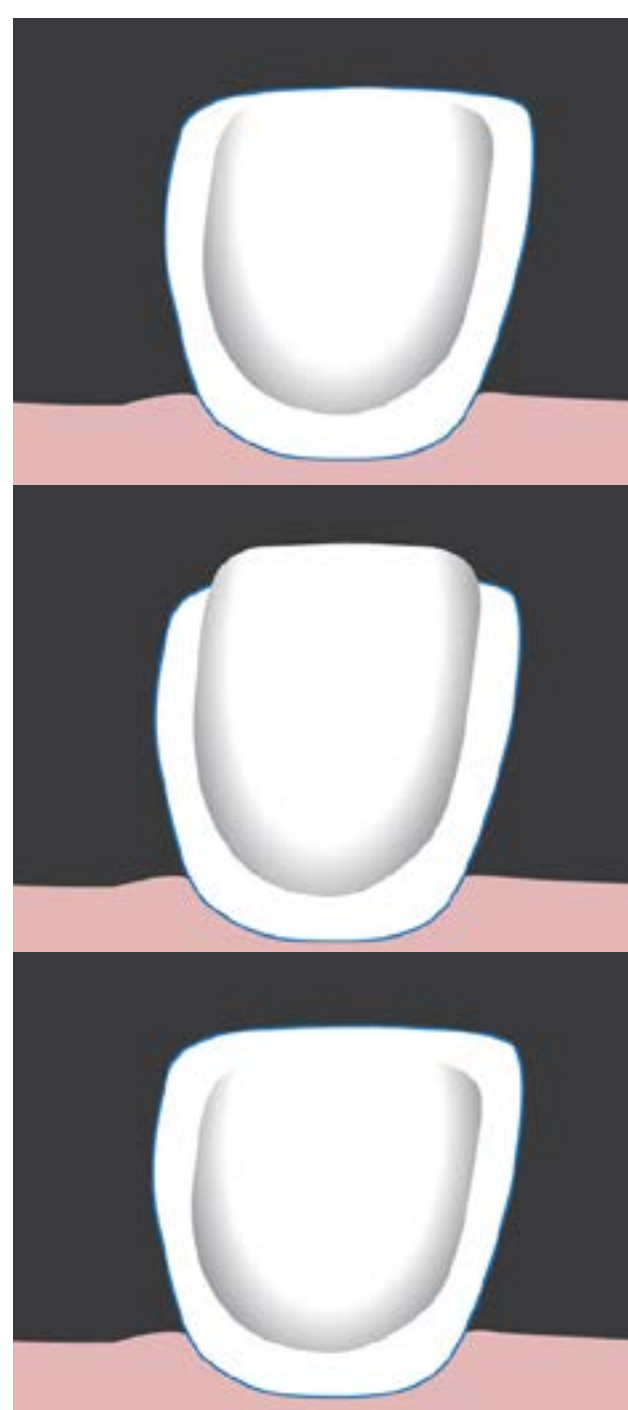
Dental restorations are designed to help maintain the form, function, and aesthetics of teeth. The accuracy of the final restoration depends on the accuracy of the recorded dimensions of the preparation. Margin placement and margin design are known to be the two main factors that govern the future health of a restored tooth. Therefore, careful step by step planning and clear communication with your lab is vital to achieving a successful result.

A few preliminary considerations in operative dentistry

Zirconia is a popular material of choice in contemporary restorative dentistry for crowns, dental bridges, and implants with characteristic properties such as compatibility, high fracture resistance, radiopacity, and super aesthetics. The following guidelines apply to Zirconia restorations and materials with similar properties.^{1,2}

Preparation guidelines

		Posterior crowns <ul style="list-style-type: none">• Sufficient room for wall thickness with a minimum of 0.5mm and between 1-1.5mm or 1.5 to 2mm occlusal reduction• Prep taper to be in between an angle of 4-8 degrees• Visible and continuous circumferential chamfer• Well rounded occlusal edges
		Anterior restorations <ul style="list-style-type: none">• Sufficient room for wall thickness with a minimum of 0.3mm and between 1-1.5mm or 1.8 to 2mm incisal reduction• Visible and continuous circumferential chamfer with at least 0.5mm reduction at the gingival margin• Vertical and horizontal prep of the tooth should have an angle of approximately 5 degrees• Well rounded incisal edges
		Inlay restorations <ul style="list-style-type: none">• Rounded internal line angles• Butt joint margin• 1 to 1.5mm wide gingival floor• 1.5-2mm isthmus width• 1.5mm isthmus depth
		Onlay restorations <ul style="list-style-type: none">• Rounded internal line angles• Butt joint margin• 1 to 1.5mm wide gingival floor• 1.5-2mm isthmus width



Veneers

- A circumferential, continuous clear visible chamfer margin
- Provide the horizontal and vertical preparation with an angle of at least 5 degrees - avoid beveling
- Incisal reduction between 1.5-2mm
- All occlusal and incisal edges should be rounded
- Correct preparation of the chamfer margins interproximally allows the appropriate bulk of ceramic

Factors to consider while evaluating the tooth preparation for a crown (extracoronary restoration)



Feather edge

- While Knife edge/Feather edge margins provide conservation of tooth structure and acute margins in some cases, it may also create complications in milling with material limitations. Feather-edged margins on full coverage restorations should be avoided as they may result in:
 - Axial reduction fading out
 - Over-contouring
 - Susceptibility to distortion



Angled preps

- Angled and inconsistency in tooth preparations leads to compromised retention and presents challenges for milling



Sharp incisal or occlusal edges

- Sharp incisal or occlusal edges may cause minor/major fit problems or in some cases, premature fractures of the restoration



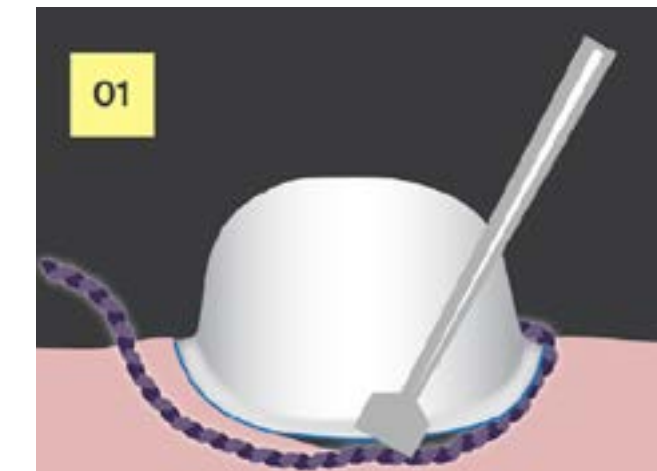
Undercuts

- Undercuts may be present where two axial walls face in opposite directions. In some cases, the presence of undercuts cause failure of seating the restoration

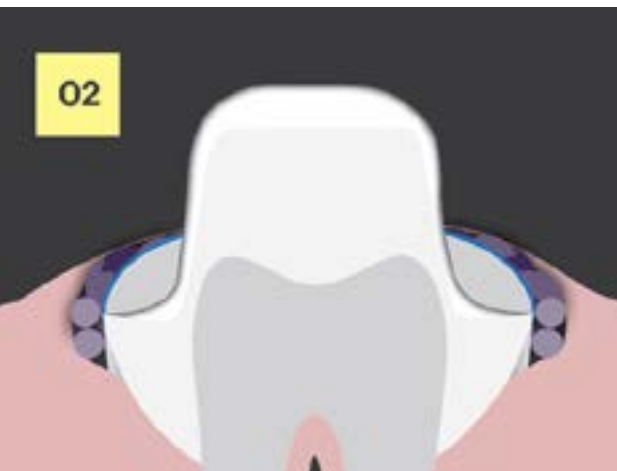
iTero restorative scan plan

Best practices to achieve a high quality digital scan

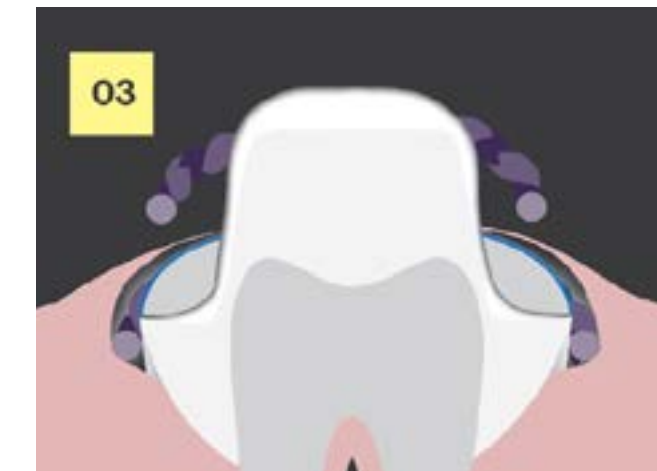
01



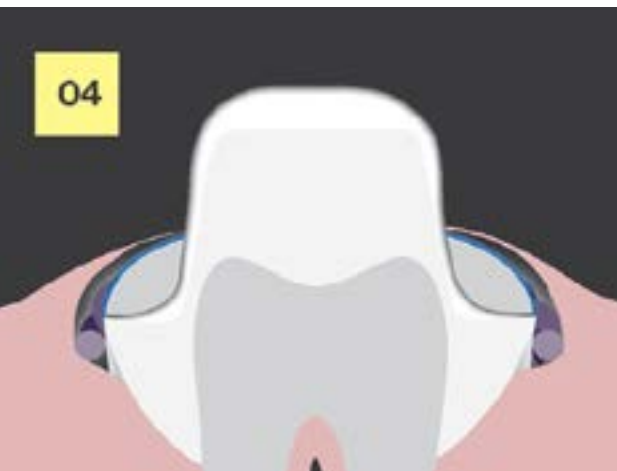
02



03



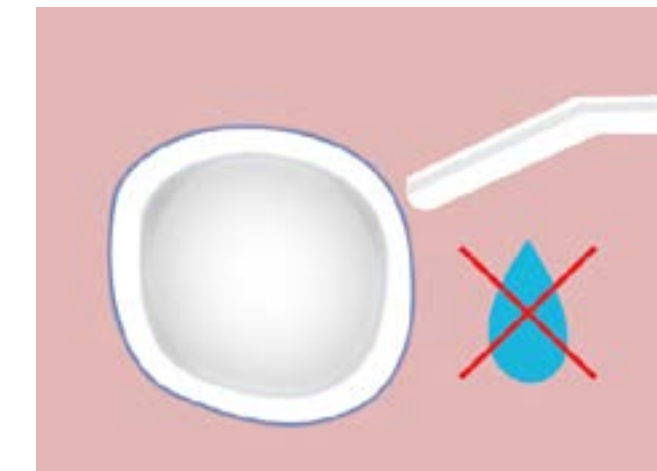
04



Ensure clear and visible margins

Soft tissue retraction: Double cord technique


- A double cord gingival retraction method is recommended with one cord left in the sulcus during the scanning procedure in order to record clear and concise margins



Isolation of the operative field

Goals of isolation:

- Moisture control (saliva, blood and/or GCF, retraction and access, safe and aseptic operating field)
- Commonly used isolation methods:
Rubber dam, gingival retraction cord, cotton rolls, air syringe, and medications as needed



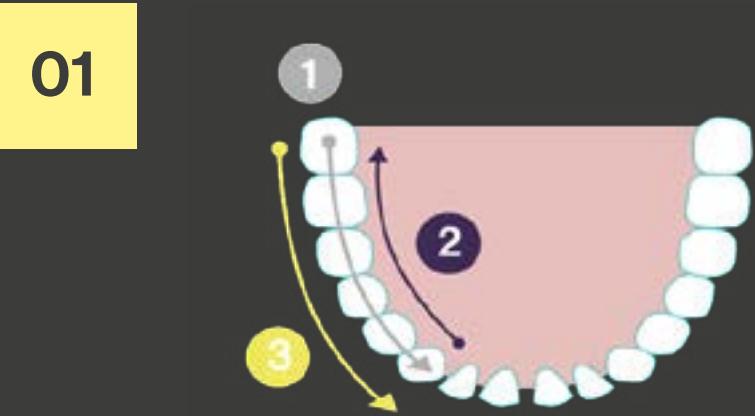
Utilise the dental chair light as needed

- Arrangements for alternative sources of light during scanning is not required as the iTero Element Intraoral Scanner has its own source of light

iTero restorative scanning protocol

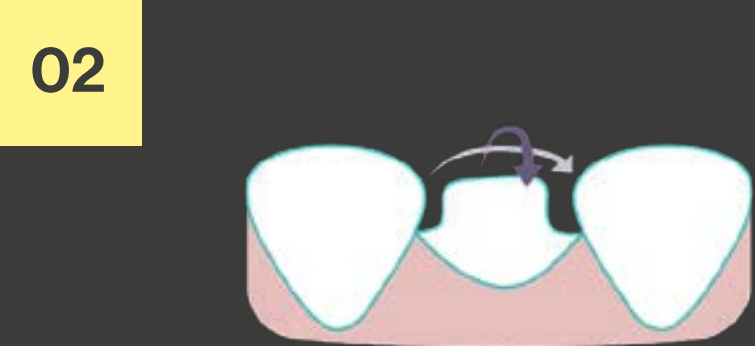To begin scanning: Light will be emitted from the wand when activated. Wait 10 seconds to allow for defogging of the lens. Place the wand in the patient’s mouth at the starting point before pressing and releasing a side button to start scanning.

STEPS

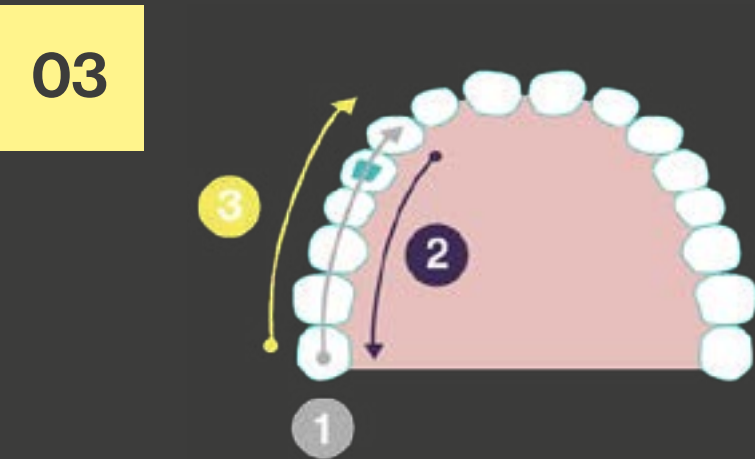


- Step 1: Scanning the opposing arch**
- Begin by placing the wand flat on the occlusal surface. Once the starting location in the viewfinder is confirmed, press and release either of the side buttons to begin scanning
 - After scanning the occlusal anatomy, roll to the lingual, and finish with the buccal

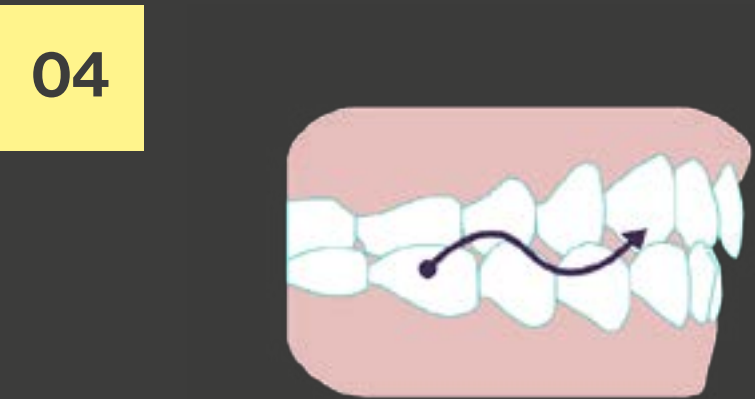
Note: Full arch scan is not necessary if prepping one tooth



- Step 2: Scanning the prep tooth**
- Ensure that the prepped tooth is dry
 - Center the prep within the viewfinder crosshair
 - Begin scanning with an occlusal view of the prep to visualise the margin
 - Roll from the lingual to the buccal of the prep
 - Roll from the distal to the mesial of the prep
 - Immediately review and fill any significant voids

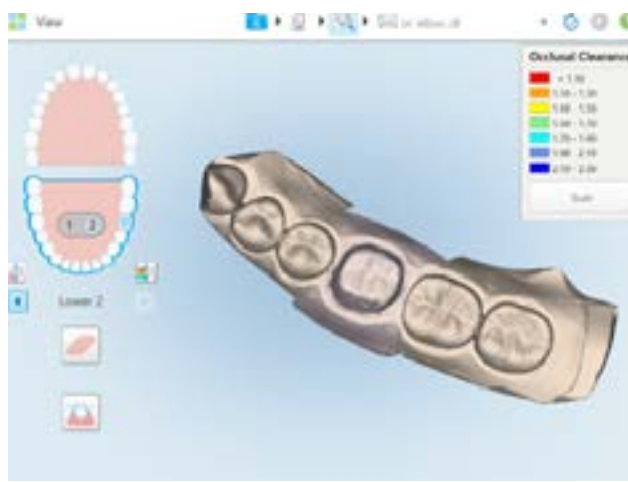


- Step 3: Scanning the prep arch**
- Scan the occlusal surface for the desired area
 - Roll to the lingual to scan the lingual surfaces
 - Roll to the buccal to scan the buccal surfaces
 - To capture the adjacent contacts lay the wand tip flat on the occlusal surface and angle the wand tip to capture desired areas, or place the wand tip on the side of the prep and rotate the wand tip to capture the contacts

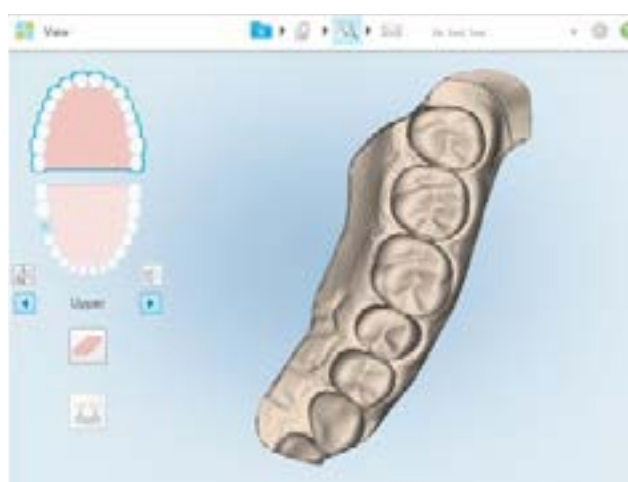

- Step 4: Scanning the bite**
- Scan the patient while biting in centric occlusion
 - Be sure to scan the bite in a previously captured area
 - Center the wand between the upper and lower arches and slowly move the wand in a wave-like motion to ensure sufficient capture of the occlusion

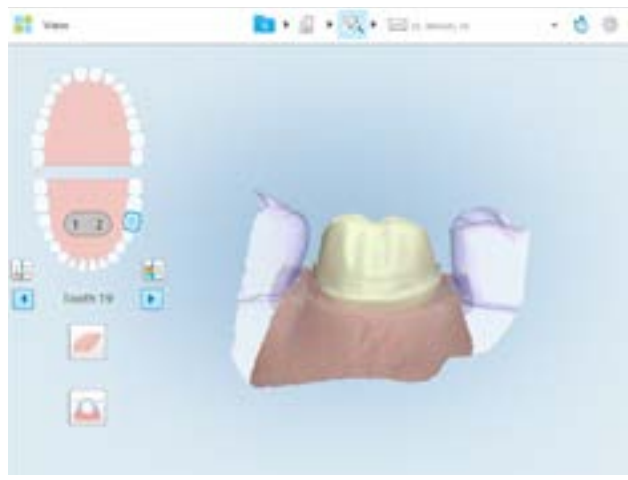
Evaluating the digital model



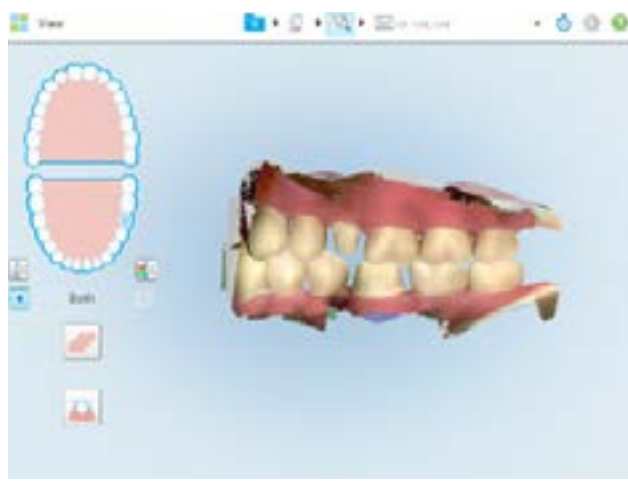
- Rotate the model to evaluate occlusal, lingual, buccal, mesial, and distal surfaces of the adjacent teeth



- Once the segments have been scanned, tap the view icon at the top of the touchscreen display to view the digital model in high resolution. After the case has been processed, evaluate the model to ensure that it is accurate and complete (i.e., check for any missing areas of anatomy)

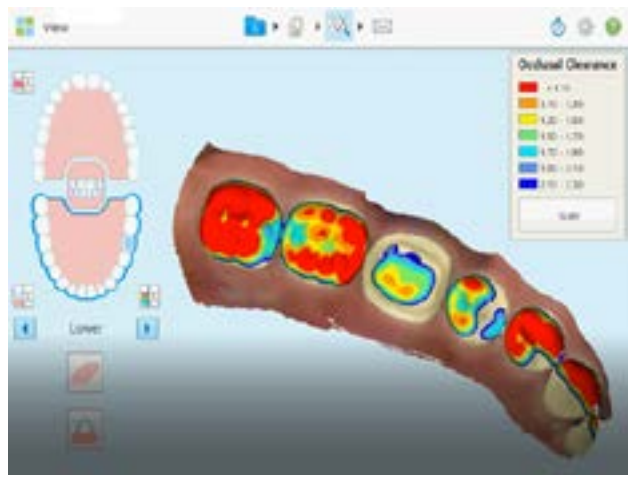


- Prep review checklist:
Margin is clearly visible, prep is fully captured, prep is clear of overlapping tissue or other obstructions that affect the margin



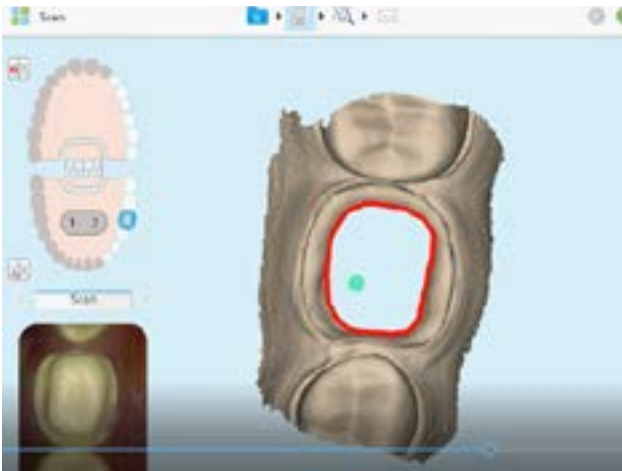
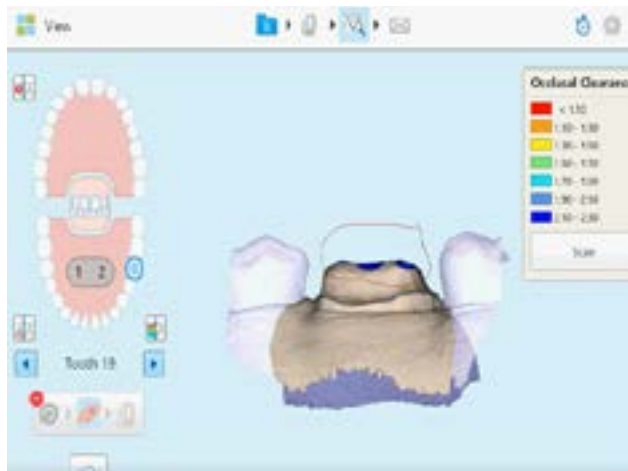- Verify that the patient's bite is in centric occlusion

Additional tools



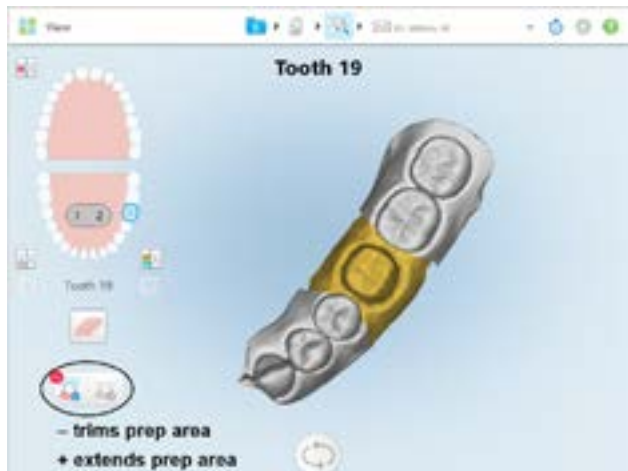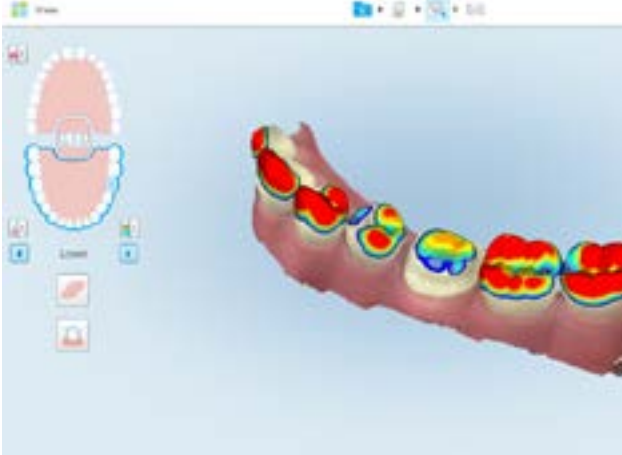
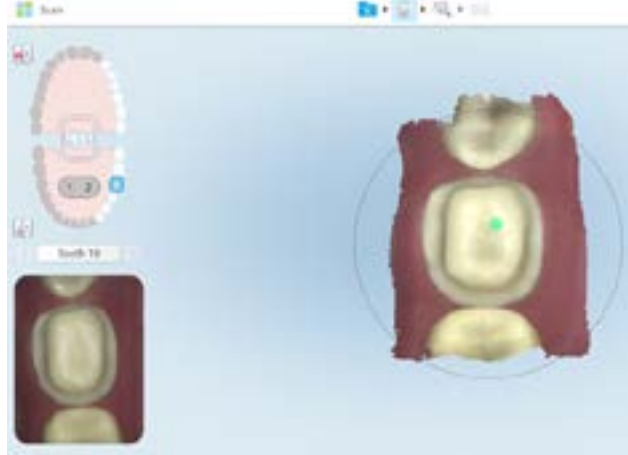Occlusal Clearance Tool

- The Occlusal Clearance Tool ensures that the prep has sufficient reduction for the material chosen in the Rx



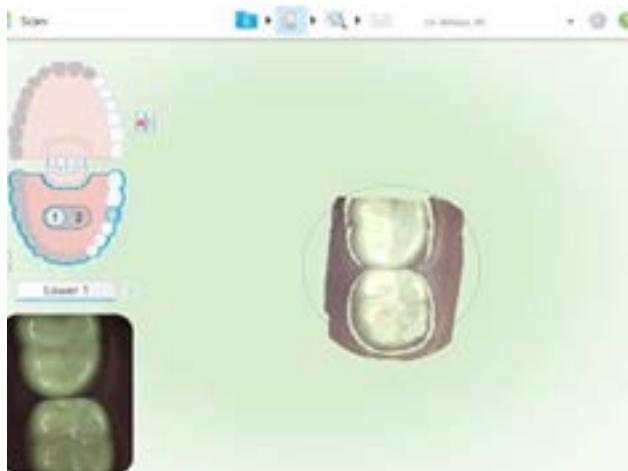Occlusal Clearance Legend

- Utilise the Occlusal Clearance Legend to determine the distance between opposing teeth
- Red areas on the prep indicate areas of inadequate occlusal clearance for the restoration, reduce the prep as required and rescan using the Eraser Tool
- To make any adjustments ensure that you are in the buccal view, then select the Eraser Tool
- Circle the area that will be modified on the model
- Adjust the clearance on patient's tooth
- Select Scan Tool to scan the modified circled area
- Activate View Tool
- Confirm the reduction was adequate

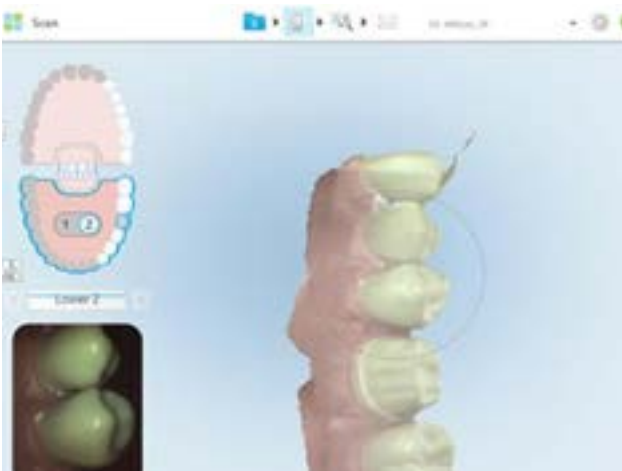

Prep Separation Tool

- The Prep Separation Tool is used to analyse the tooth prep and surrounding areas in high resolution



“1” Pre-treatment, indicated by the green background



“2” Post-treatment, indicated by the blue background

Pre-treatment scan

- Allows recording the tooth anatomy before the tooth preparation
- Enables the lab to copy the original anatomy to the new restoration
- Data will be available on the following CAD-CAM System: 3 Shape and Exocad

Learn more at iTero.com



¹ Strudevant's Art and Science of Operative dentistry, Seventh edition – Andre V. Ritter, Lee Q. Boushell, Ricardo Walter
² Phillip's science of dental materials, Anusavice – Eleventh edition

ITERO, ITERO ELEMENT, the iTero logo among others, are trademarks and/or service marks of Align Technology, Inc. or one of its subsidiaries or affiliated companies and may be registered in the U.S. and/or other countries.
Non-authorized use, copy or imitation without permission are not allowed.

Published June 2019
MKT-0003191 Rev A

© 2019 Align Technology, Inc.

Article Summary of:

“Digital vs. conventional implant prosthetic workflows: a cost/time analysis”



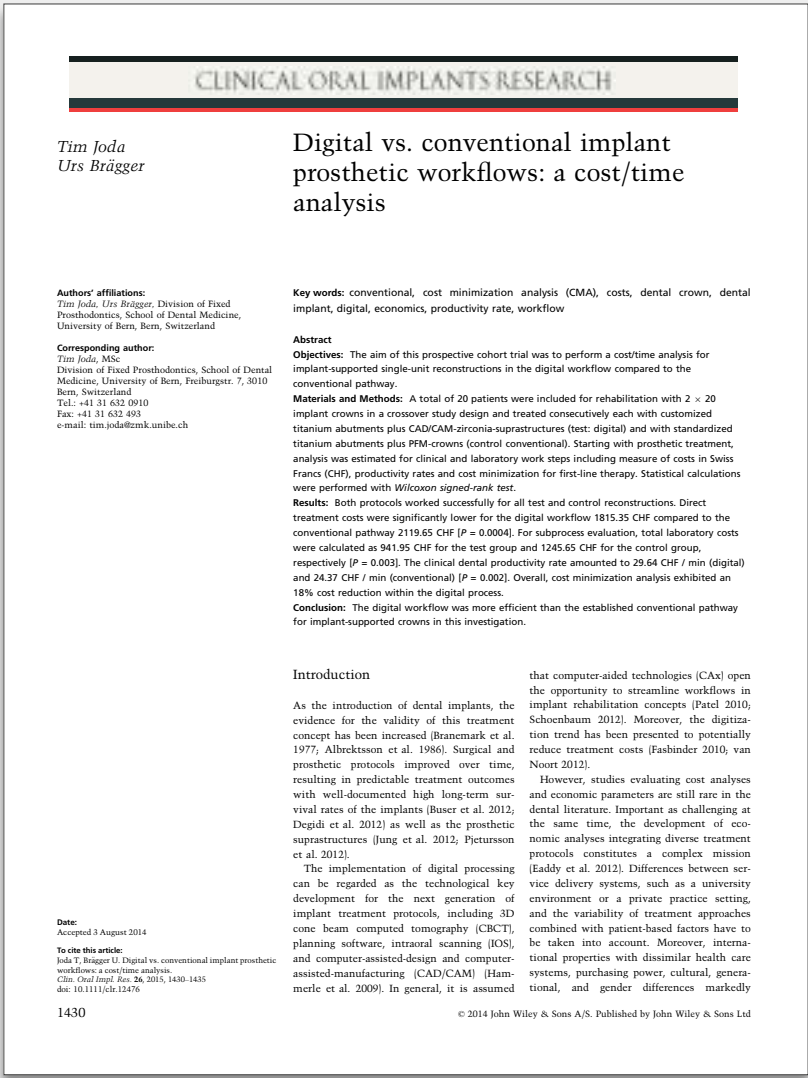Objectives:

Prospective cohort trial to perform a cost/time analysis for implant-supported single-unit reconstructions in the digital workflow compared to the conventional pathway.

Materials and Methods:

- 20 patients
- Rehabilitation with 2 x 20 implant crowns
- Crossover study design
- Test: customized titanium abutments plus CAD/CAM-zirconia-suprastructures
- Control: standardized titanium abutments plus PFM-crowns
- Starting with prosthetic treatment, analysis was estimated for clinical and laboratory work steps including measure of costs in Swiss Francs (CHF), productivity rates and cost minimization for first-line therapy.
- Statistical calculations with Wilcoxon signed-rank test

Article:



Author:
Tim Joda, Urs Brägger

Reference:
Clin. Oral Impl. Res. 26, 2015, 1430–1435 doi: 10.1111/clr.12476

This text is lifted from the article.
To purchase and read the full article please
[click here](#) ➤

Article Summary of:

“Digital vs. conventional implant prosthetic workflows: a cost/time analysis”



Results:

Overall, cost minimization analysis exhibited an 18% cost reduction within the digital process.

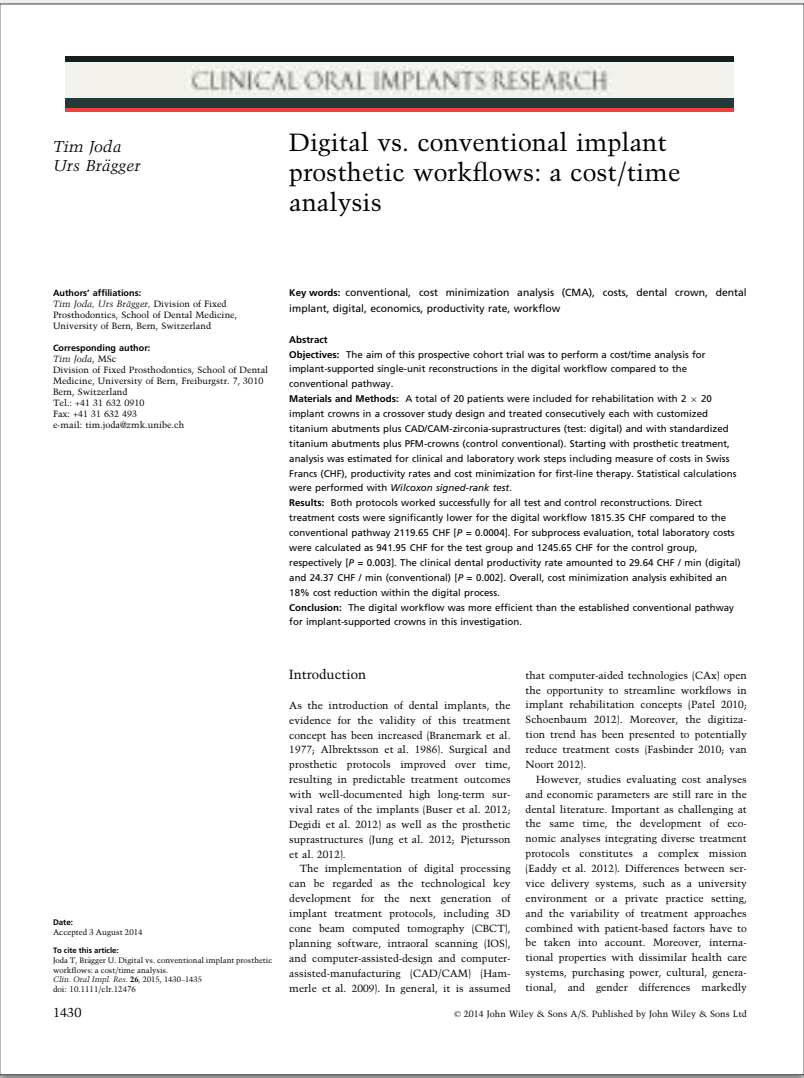Both protocols worked successfully for all test and control reconstructions.

	Digital Workflow	Conventional Workflow	Statistic
Direct treatment costs	1815.35 CHF	2119.65 CHF	Significant [P = 0.0004]
Total laboratory costs	941.95 CHF	1245.65 CHF	Significant [P = 0.0003]
The clinical dental productivity rate	29.64 CHF / min	24.37 CHF / min	[P = 0.0002]

Conclusion:

The digital workflow was more efficient than the well-established conventional pathway.

Article:



Author:
Tim Joda, Urs Brägger

Reference:
Clin. Oral Impl. Res. 26, 2015, 1430–1435 doi: 10.1111/clr.12476

This text is lifted from the article.
To purchase and read the full article please [click here](#) ➤

Article Summary of:

“Patient-centered outcomes comparing digital and conventional implant impression procedures: a randomized crossover trial”



Objectives:

The aim of this randomized controlled trial was to compare patient-centered outcomes during digital and conventional implant impressions.

Materials and Methods:

Intraoral scanning (IOS) [test] as well as classical polyether impressions [control] were both performed on

- 20 patients
- single-tooth replacement with implant-supported crowns
- Crossover study design
- Test: Patients’ perception and satisfaction on the level of convenience-related factors were assessed with visual analogue scale (VAS) questionnaires.

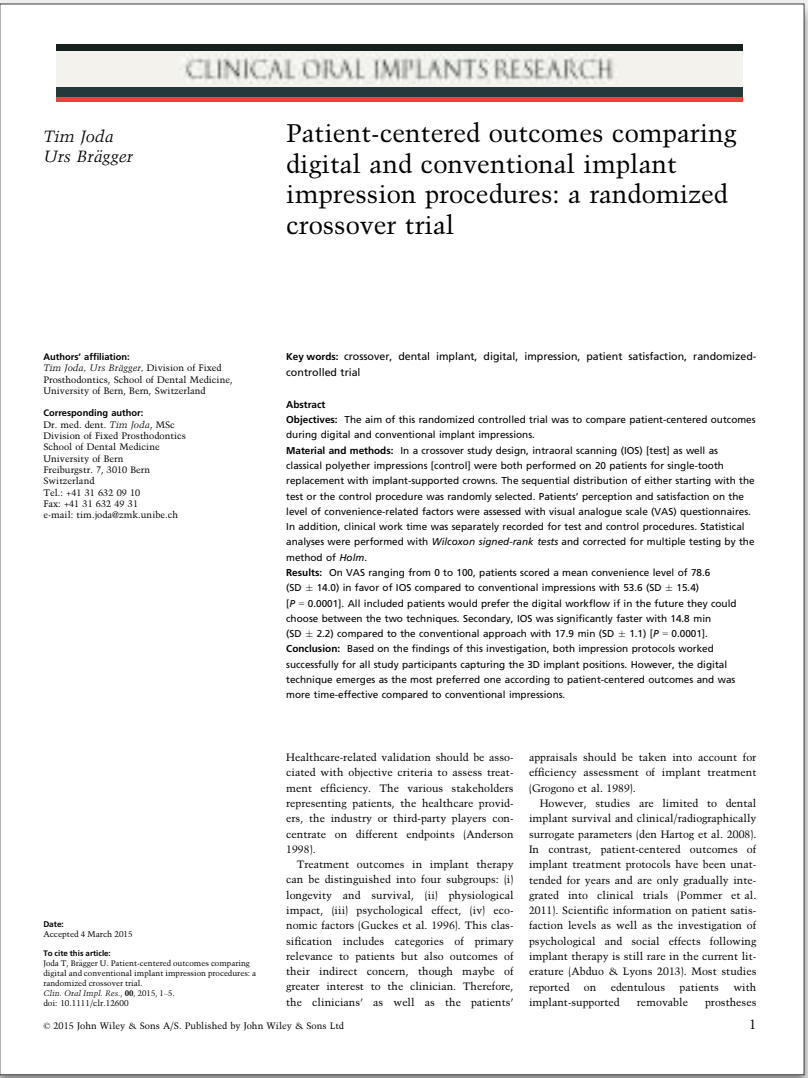In addition, clinical work time was separately recorded for test and control procedures.

- Statistical analyses with Wilcoxon signed-rank tests and corrected for multiple testing by the method of Holm.

Results:

On VAS (visual analogue scale) ranging from 0 to 100, patients scored a mean convenience level of 78.6 (SD ± 14.0) in favor of IOS compared to conventional impressions with 53.6(SD ± 15.4) [P = 0.0001]. All included patients would prefer the digital workflow if in the future they could choose between the two techniques. Secondary, IOS was significantly faster with 14.8 min (SD ± 2.2) compared to the conventional approach with 17.9 min (SD ± 1.1) [P = 0.0001].

Article:



Author:
Tim Joda, Urs Brägger

Reference:
Clin. Oral Impl. Res., 00, 2015, 1–5. doi: 10.1111/clr.12600

This text is lifted from the article.
To purchase and read the full article please [click here](#) ➤

Article Summary of:
“Patient-centered outcomes comparing digital and conventional implant impression procedures: a randomized crossover trial”



Questions on patient satisfaction with digital and conventional impression procedures and mean scores of the results.

VAS (visual analogue scale): unsatisfactory 0 – 100 excellent

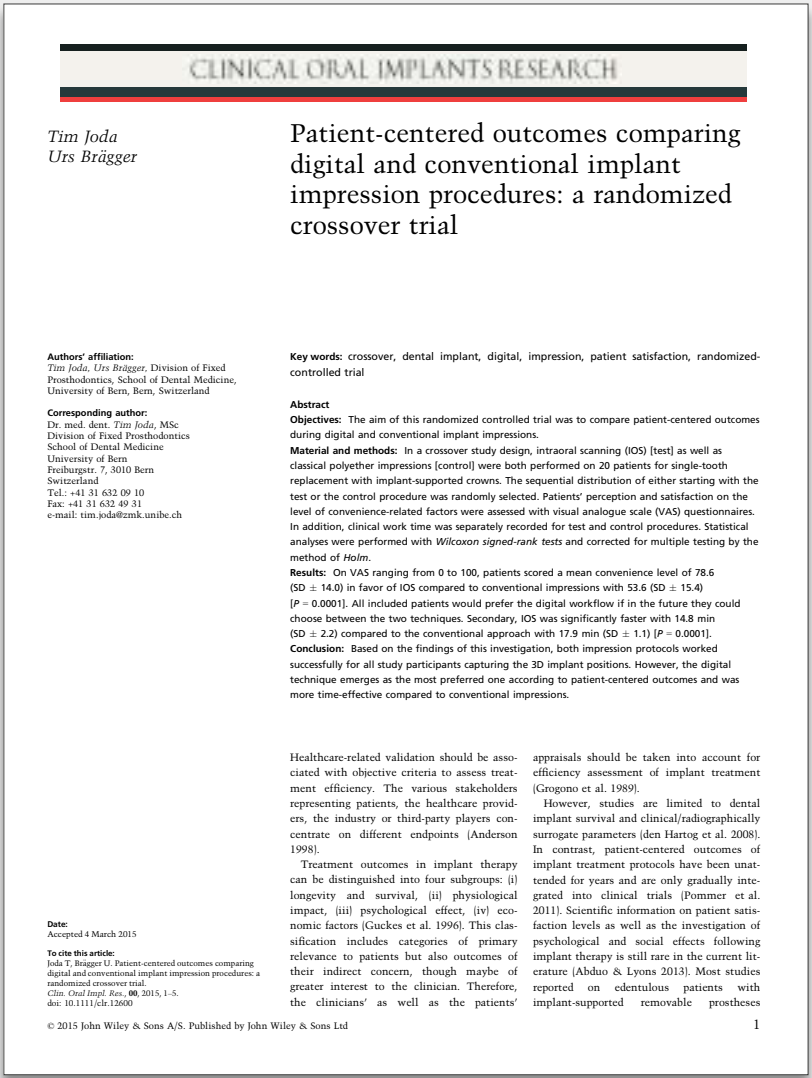12 Questions (2 x 6)	Digital Impression	Conventional impression
What is your opinion on the treatment time required for the impression procedure?	Mean 79.2; SD ± 12.1 median 83.0; range 50–95	Mean 57.6; SD ± 15.6 median 59.5; range 17–95
How convenient was the impression procedure for you?	Mean 78.6; SD ± 14.0median 84.0; range 35–90	Mean 53.6; SD ± 15.4 median 53.5; range 15–85
Was there a bad oral taste present and/or after the impression procedure?	Mean 10.9; SD ± 9.5 median 6.5; range 0–36	Mean 71.3; SD ± 15.7 median 77.5; range 25–87
Was there a bad oral taste present and/or after the impression procedure?	Mean 10.9; SD ± 9.5 median 6.5; range 0–36	Mean 71.3; SD ± 15.7 median 77.5; range 25–87
Did you experience a nausea sensation during impression procedure?	Mean 12.2; SD ± 11.4 median 7.0; range 0–51	Mean 68.7; SD ± 18.0 median 74.0; range 10–93
Did you experience pain during impression procedure?	Mean 13.9; SD ± 10.3median 13.0; range 0–36	Mean 44.6; SD ± 20.7 median 45.0; range 5–77

Conclusion:

The digital technique emerges as the most preferred one according to patient-centered outcomes and was more time-effective compared to conventional impressions. Within the limitations of this clinical crossover study, the following conclusions can be summarized:

- The digital workflow was significantly accepted as the most preferred and time effective implant impression procedure compared to the conventional technique with regard to the patients’ perception and satisfaction.
- With regard to treatment comfort, the digital impression protocol with IOS was more patient-friendly than the conventional approach when it was performed by an experienced team of dentist/dental assistance.
- Both workflows worked clinically successful restoring single-tooth gaps with implant-supported crowns.

Article:



Author:
Tim Joda, Urs Brägger

Reference:
Clin. Oral Impl. Res., 00, 2015, 1–5. doi: 10.1111/ clr.12600

This text is lifted from the article.
To purchase and read the full article please [click here](#) ➤

Article Summary of:

“Time-Efficiency Analysis Comparing Digital and Conventional Workflows for Implant Crowns: A Prospective Clinical Crossover Trial”

iTero

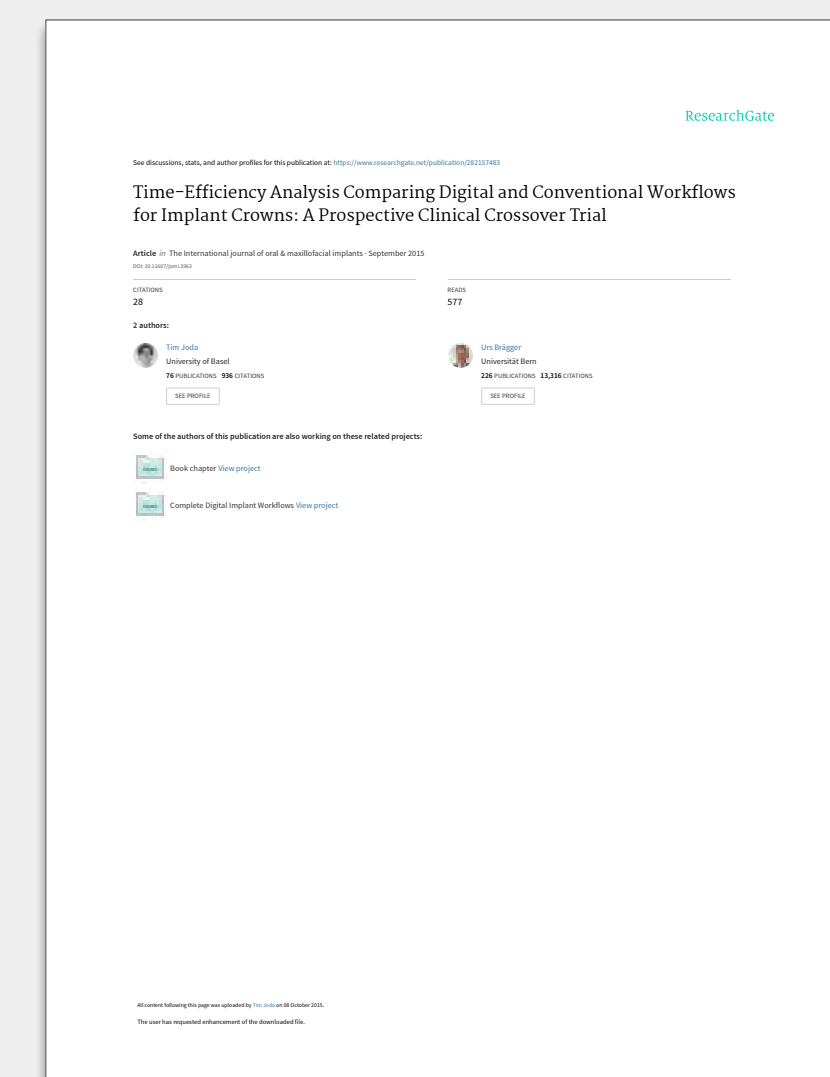
Objectives:

To compare time-efficiency in the production of implant crowns using a digital workflow versus the conventional pathway.

Materials and Methods:

- 20 patients
- single-tooth replacements in posterior sites
- Crossover study design
- Test: Each patient received
 - for those in the test group, using digital workflow: a customized titanium abutment plus a computer-aided design/computer-assisted manufacture (CAD/CAM) zirconia suprastructure
 - for those in the control group, using a conventional pathway: a standardized titanium abutment plus a porcelain- fused- to-metal crown
- The start of the implant prosthetic treatment was established as the baseline.
- Time-efficiency analysis was defined as the primary outcome, and was measured for every single clinical and laboratory work step in minutes.
- Statistical calculations with Wilcoxon rank sum test

Article:



Author:

Tim Joda, Urs Brägger

Reference:

The International journal of oral & maxillofacial implants. 30. 1047-1053. DOI :10.11607/jomi.3963.

This text is lifted from the article.

To purchase and read the full article please [click here](#) ➤

Article Summary of:

“Time-Efficiency Analysis Comparing Digital and Conventional Workflows for Implant Crowns: A Prospective Clinical Crossover Trial”



Results:

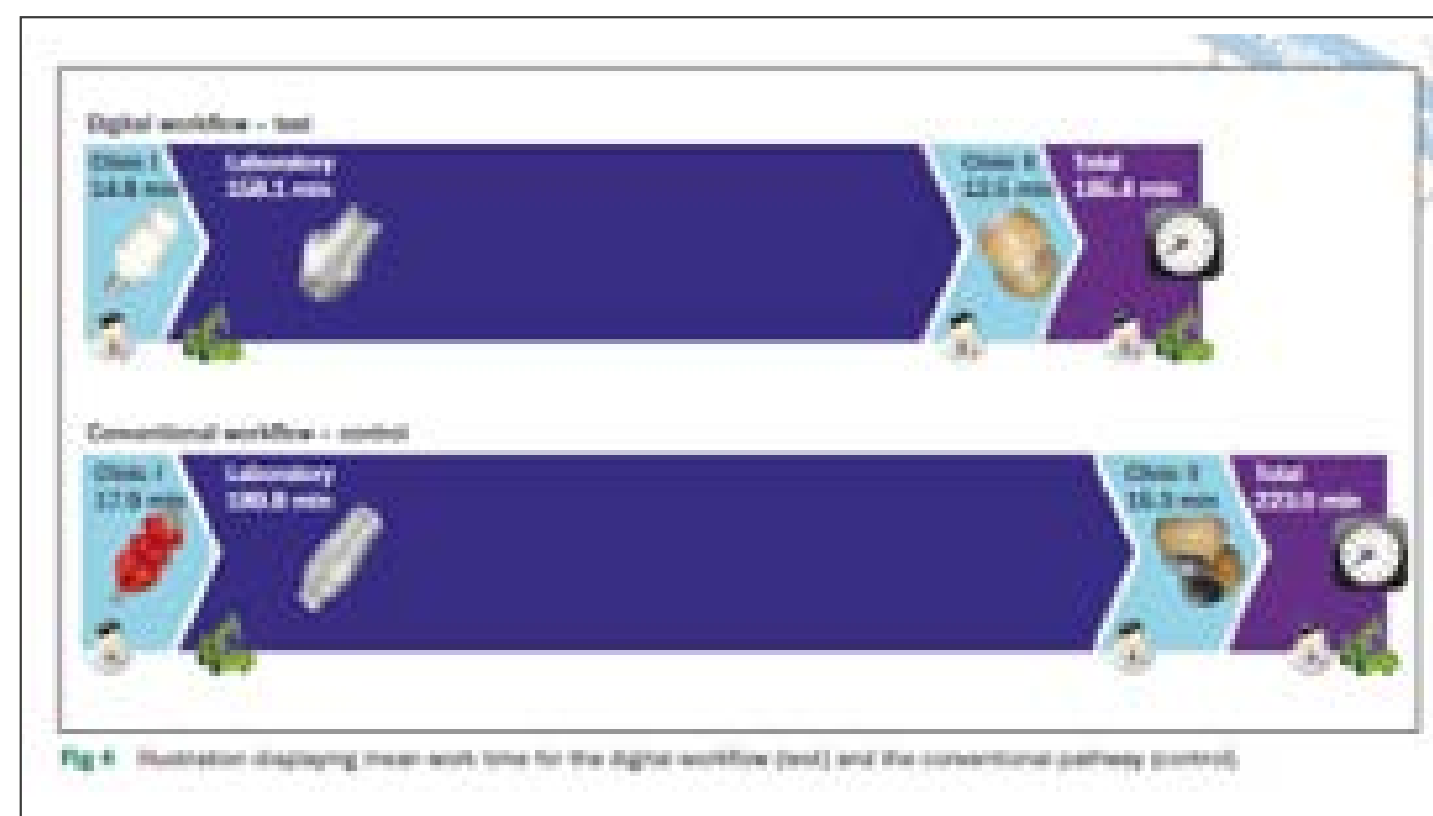
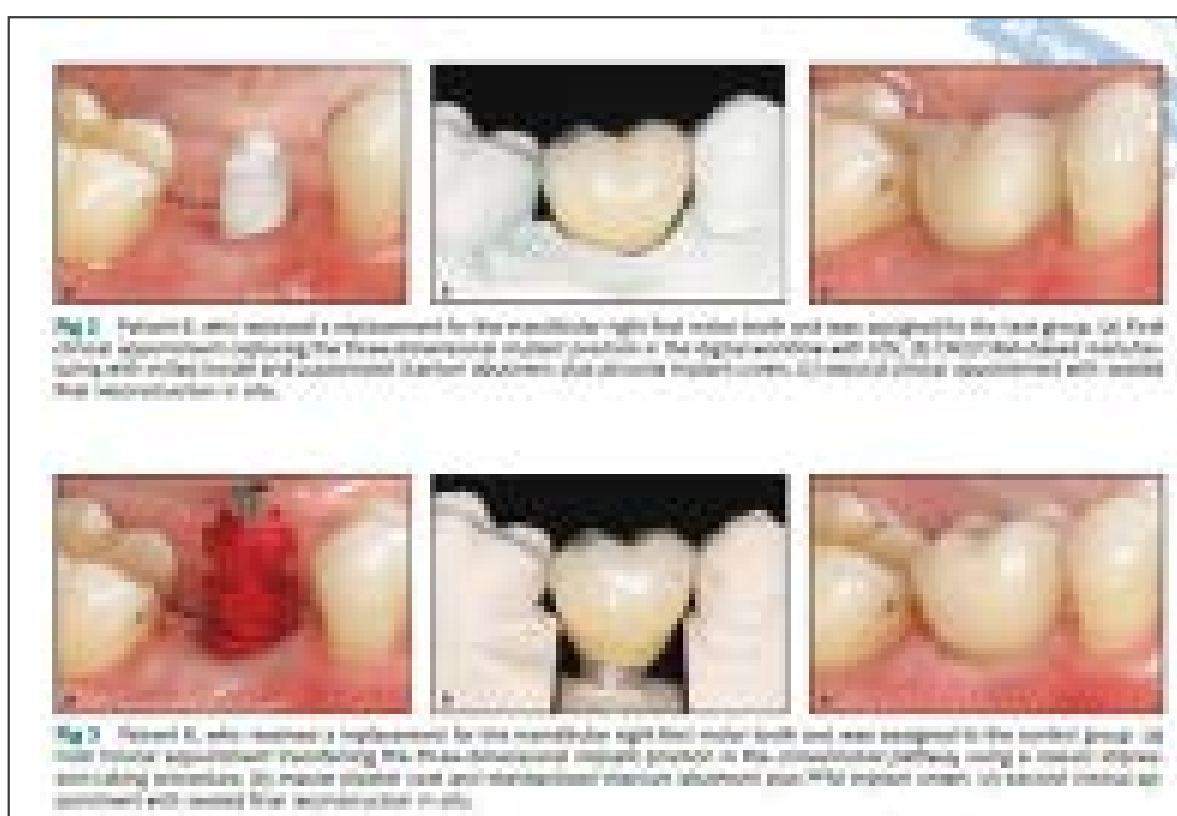
All crowns could be provided within two clinical appointments, independent of the manufacturing process.

The mean total production time, as the sum of clinical plus laboratory work steps, was significantly different.

The mean \pm standard deviation (SD) time was 185.4 ± 17.9 minutes for the digital workflow process and 223.0 ± 26.2 minutes for the conventional pathway ($P = .0001$).

Therefore, digital processing for overall treatment was 16% faster.

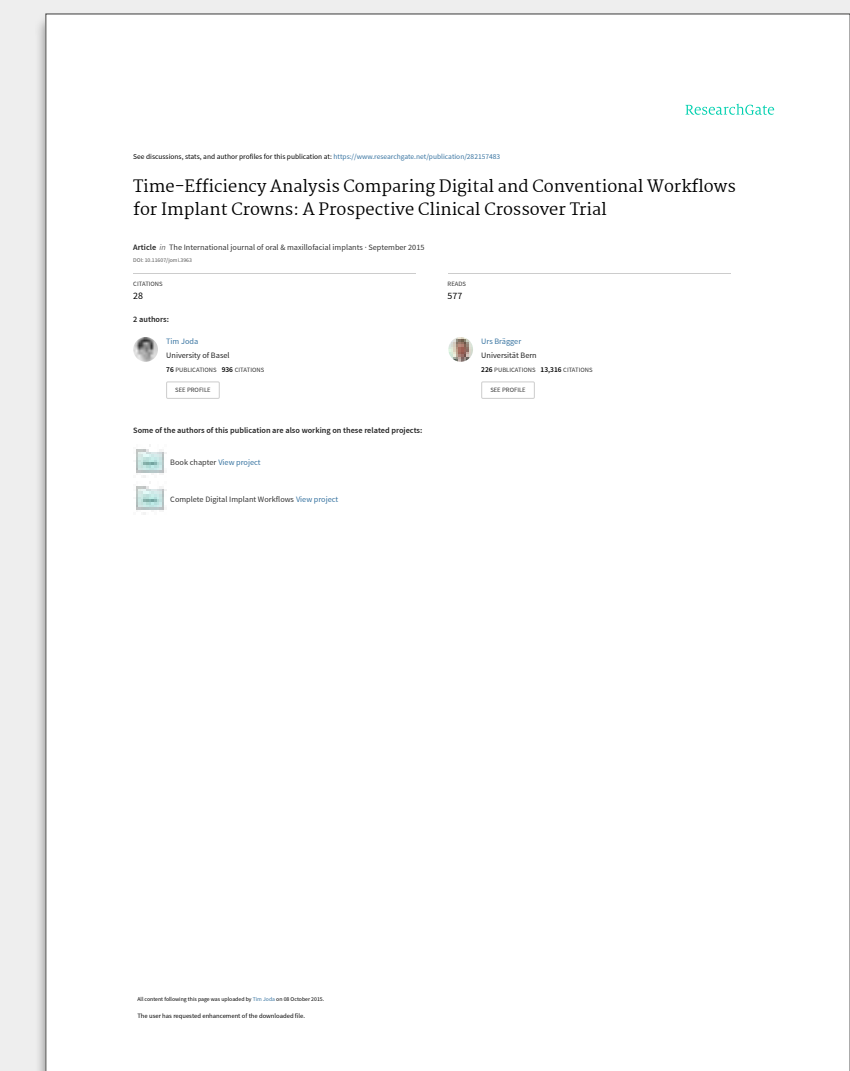
Detailed analysis for the clinical treatment revealed a significantly reduced mean \pm SD chair time of 27.3 ± 3.4 minutes for the test group compared with 33.2 ± 4.9 minutes for the control group ($P = .0001$). Similar results were found for the mean laboratory work time, with a significant decrease of 158.1 ± 17.2 minutes for the test group vs 189.8 ± 25.3 minutes for the control group ($P = .0001$).



Conclusion:

This investigation shows that the digital workflow seems to be more time-efficient than the established conventional production pathway for fixed implant-supported crowns. Both clinical chair time and laboratory manufacturing steps could be effectively shortened with the digital process of intraoral scanning plus CAD/CAM technology.

Article:



Author:

Tim Joda, Urs Brägger

Reference:

The International journal of oral & maxillofacial implants. 30. 1047-1053. DOI :10.11607/jomi.3963.

This text is lifted from the article.

To purchase and read the full article please [click here](#) ➡

List of External publications evaluating iTero and it’s accuracy under different conditions.



Below is a list of external articles evaluating iTero, the following pages focus on the 4 articles highlighted below.

	Publication	Accuracy Tested	iTero scanner tested	Author	Reference	Conclusion
1	Accuracy of full-arch digital impressions: an in vitro and in vivo comparison.	Full-arch	iTero Element	Keul C, et al.	Clin Oral Investig. 2019 May 27.	Within the limitations of this study, the iTero-scan seems to be a valid alternative to conventional impressions for full arches
2	A new method to measure the accuracy of intraoral scanners along the complete dental arch: A pilot study.	Full-arch	iTero Element	Iturrate M, et al.	J Adv Prosthodont. 2019 Dec;11(6):331-340.	iTero Element 1 was more accurate than the current versions of Trios 3 and True Definition. Importantly, the proposed methodology is considered reliable for analyzing accuracy in any dental arch length and valid for assessing both trueness and precision in an in vivo study.
3	Randomized controlled clinical trial of digital and conventional workflows for the fabrication of zirconia-ceramic fixed partial dentures. Part III: Marginal and internal fit.	Marginal fit	iTero Element 2	Benic GI, et al.	J Prosthet Dent. 2019 Mar;121(3):426-431.	In terms of frameworks presented similar or better fit than the conventionally fabricated metal frameworks. In the occlusal regions, the conventionally fabricated metal frameworks achieved a more favorable fit than the CAD-CAM zirconia frameworks.
4	Trueness of 12 intraoral scanners in the full-arch implant impression: a comparative in vitro study	Full-arch	iTero Element 5D	Francesco Guido et al.	BMC Oral Health. 2020; 20 (1): 263	Different levels of trueness were found among the IOSs evaluated in this study. Further studies are needed to confirm these results.
5	The effect different substrates have on the trueness and precision of eight different intraoral scanners.	Substrates	iTero Element iTero Element 2	Dutton E, et al.	J Esthet Restor Dent. 2019 Sep 30.	Substrate type affects the trueness and precision of a scan. Active Triangulation scanners are more sensitive to substrate differences than their parallel confocal counterparts. Some scanners scan certain substrates better, but in general the new generation of scanners outperforms the old, across all substrates.
6	Comparison of two intraoral scanners based on three-dimensional surface analysis.		iTero Element	Lee KM, et al.	Prog Orthod. 2018 Feb 12;19(1):6.	Although there were some deviations in visible inspection, there was no statistical significance between the two intraoral scanners.
7	Intraoral digital scans-Part 1: Influence of ambient scanning light conditions on the accuracy (trueness and precision) of different intraoral scanners.	Light conditions	iTero Element	Revilla-León M, et al.	J Prosthet Dent. 2019 Dec 18.	Ambient lighting conditions influenced the accuracy (trueness and precision) of the IOSs tested. The recommended lighting conditions depend on the IOS selected. For iTero Element, chair and room light conditions resulted in better accuracy mean values. For CEREC Omnicam, zero light resulted in better accuracy, and for TRIOS 3, room light resulted in better accuracy.
8	Trueness of digital intraoral impression in reproducing multiple implant position.	Implant	iTero Element	Kim RJ, et al.	PLoS One. 2019 Nov 19;14(11):e0222070.	Within the limitations of the present study, all the IOSs exhibited increasing deviation with an increasing distance from the start position of scanning. The direction and magnitude of deviation differed among jaw regions and IOSs. All the IOSs were similar for unilateral arch scanning, while i500, and TRIOS 3 outperformed the other IOSs for partially edentulous scanning. The accuracy of IOS requires additional improvement.
9	Trueness and precision of 5 intraoral scanners for scanning edentulous and dentate complete-arch mandibular casts: A comparative in vitro study.	Edentulous	iTero Element	Braian M, et al.	J Prosthet Dent. 2019 Aug;122(2):129-136.e2.	Significant differences were found in scanning edentulous and dentate scans for short arches and complete arches. Trueness for complete-arch scans were <193 µm for edentulous scans and <150 µm for dentate scans. Trueness for short-arch scans were <103 µm for edentulous scans and <56 µm for dentate scans.
10	Trueness and Precision of Three-Dimensional Digitizing Intraoral Devices.	Edentulous	iTero Element	Mutwalli H, et al	Int J Dent. 2018 Nov 26;2018:5189761.	Within the limitations of this in vitro study, the results suggest significant differences between IOS devices when scanning fully edentulous arch with multiple implants. ,e main observation was the low precision for all intraoral scanners, suggesting that the intraoral scanning devices are unreliable for scanning fully edentulous arch with multiple implants. Two scanners, however, Trios 3 mono and ltero element showed fair trueness.
11	Local accuracy of actual intraoral scanning systems for single-tooth preparations in vitro.	Single tooth prep	iTero Element 2	Zimmermann M, et al.	J Am Dent Assoc. 2020 Feb;151(2):127-135.	IOS systems use different behaviors in terms of local accuracy. Preparation MA shows higher deviations than preparation SU for all test groups. Trueness and precision values for both MA and SU of single-unit preparations are equal or close to CO impressions for several IOS systems

Article Summary of:

“Accuracy of full-arch digital impressions: an in vitro and in vivo comparison.”



Objectives:

Comparison of full-arch digital impressions to conventional impressions in vitro and in vivo.

Materials and Methods:

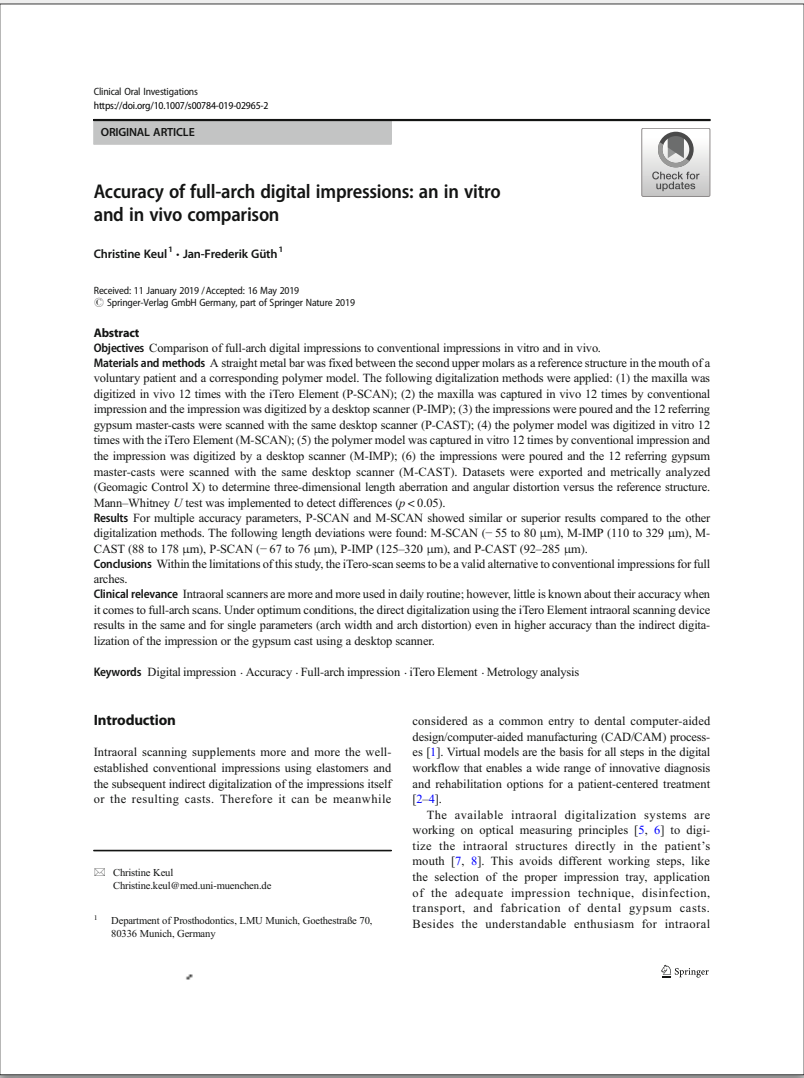Reference structure: A straight metal bar fixed between the second upper molars in the mouth of a voluntary patient and a corresponding polymer model.

The following digitalization methods were applied:

- The maxilla was digitized in vivo 12 times with the iTero Element (P-SCAN);
- The maxilla was captured in vivo 12 times by conventional impression and the impression was digitized by a desktop scanner (P-IMP);
- The impressions were poured and the 12 referring gypsum master-casts were scanned with the same desktop scanner (P-CAST)
- The polymer model was digitized in vitro 12 times with the iTero Element (M-SCAN);
- The polymer model was captured in vitro 2 times by conventional impression and the impression was digitized by a desktop scanner (M-IMP);
- The impressions were poured and the 12 referring gypsum master-casts were scanned with the same desktop scanner (M-CAST).

Datasets were exported and metrically analyzed (Geomagic Control X) to determine three dimensional length aberration and angular distortion versus the reference structure Mann-Whitney U test was implemented to detect differences ($p < 0.05$).

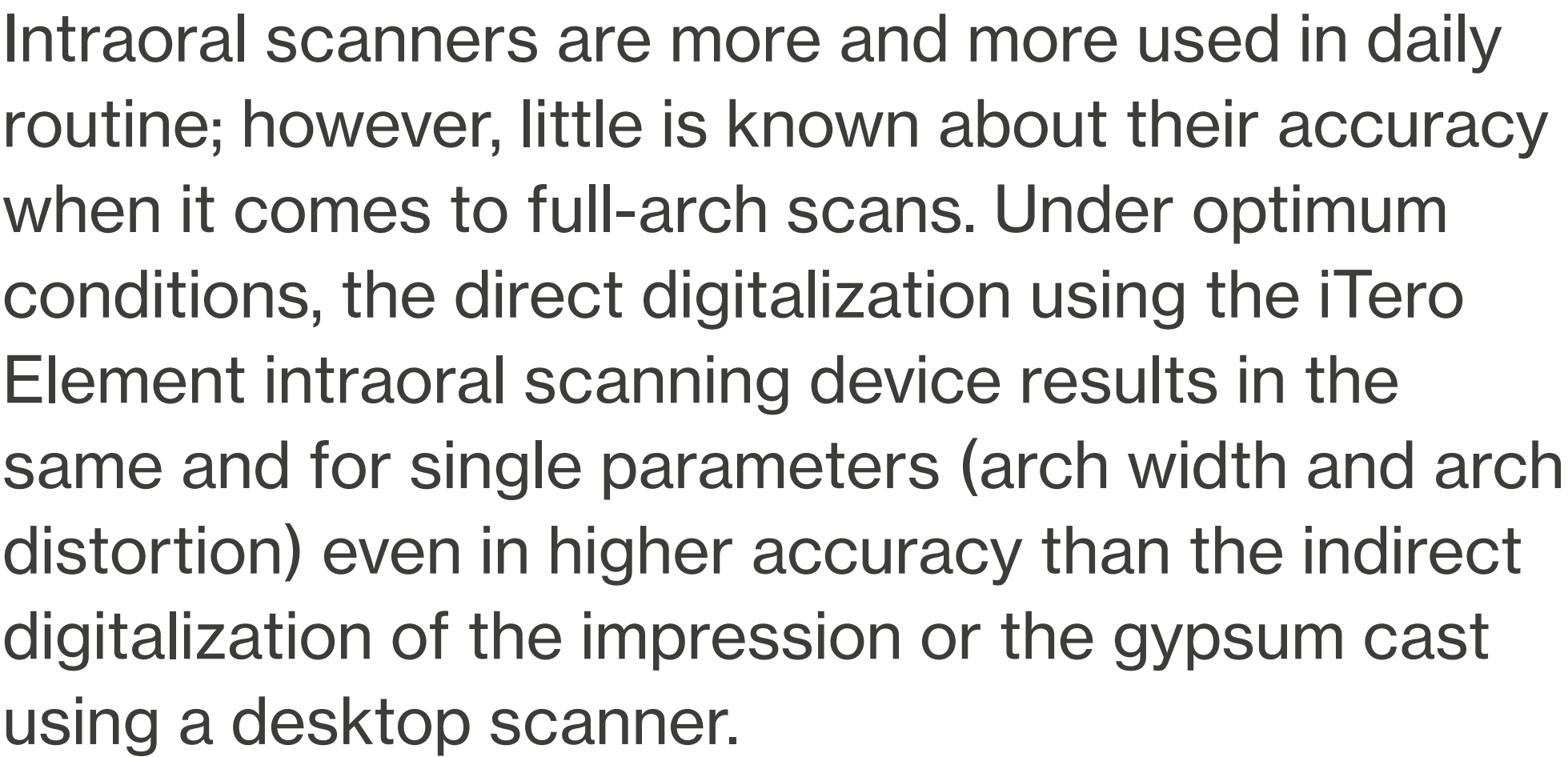
Article:



Author:
Christine Keul,
Jan-Frederik Güth

Reference:
Clin Oral Investig. 2019
May 27

This text is lifted from the article. To purchase and read the full article please [click here](#) ➤



	Substrate	Captured with	Digitized with	
M-SCAN	Polymer model	iTero	N/A	-55 to 80 μm
M-IMP	Polymer model	Conventional impression	Desktop scanner	110 to 329 μm
M-CAST	Polymer model	Casted conventional impression	Desktop scanner	88 to 178 μm
P-SCAN	Maxilla	iTero	N/A	- 67 to 76 μm
P-IMP	Maxilla	Conventional impression	Desktop scanner	125-320 μm
P-CAST	Maxilla	Casted conventional impression	Desktop scanner	92-285 μm

Within the limitations of this study, the iTero-scan seems to be a valid alternative to conventional impressions for full arches

Reference:
Clin Oral Investig. 2019
May 27

**This text is lifted
from the article.**
**To purchase and read
the full article please
[click here](#) **

Article Summary of:

“A new method to measure the accuracy of intraoral scanners along the complete dental arch: A pilot study.”



Purpose:

The purpose of this study is to assess the accuracy of three intraoral scanners along the complete dental arch and evaluate the feasibility of the assessment methodology for further in vivo analysis.

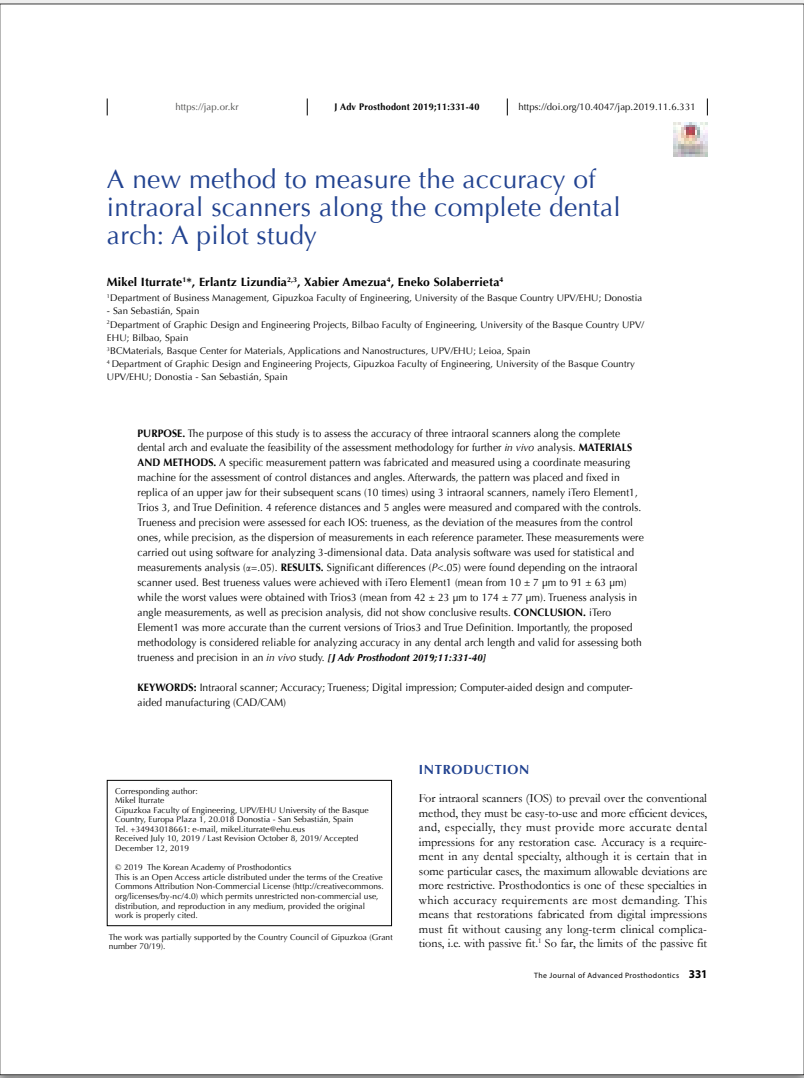Materials and Methods:

A specific measurement pattern was fabricated and measured using a coordinate measuring machine for the assessment of control distances and angles. Afterwards, the pattern was placed and fixed in replica of an upper jaw for their subsequent scans (10 times) using 3 intraoral scanners, namely iTero Element1, Trios 3, and True Definition. 4 reference distances and 5 angles were measured and compared with the controls. Trueness and precision were assessed for each IOS: trueness, as the deviation of the measures from the control ones, while precision, as the dispersion of measurements in each reference parameter. These measurements were carried out using software for analyzing 3-dimensional data. Data analysis software was used for statistical and measurements analysis (a=.05).

Results:

Significant differences (P<.05) were found depending on the intraoral scanner used. Best trueness values were achieved with iTero Element 1 (mean from 10 ± 7 µm to 91 ± 63 µm) while the worst values were obtained with Trios 3 (mean from 42 ± 23 µm to 174 ± 77 µm). Trueness analysis in angle measurements, as well as precision analysis, did not show conclusive results.

Article:



Author:

Mikel Iturrate, Erlantz Lizundia, Xabier Amezua, Eneko Solaberrieta

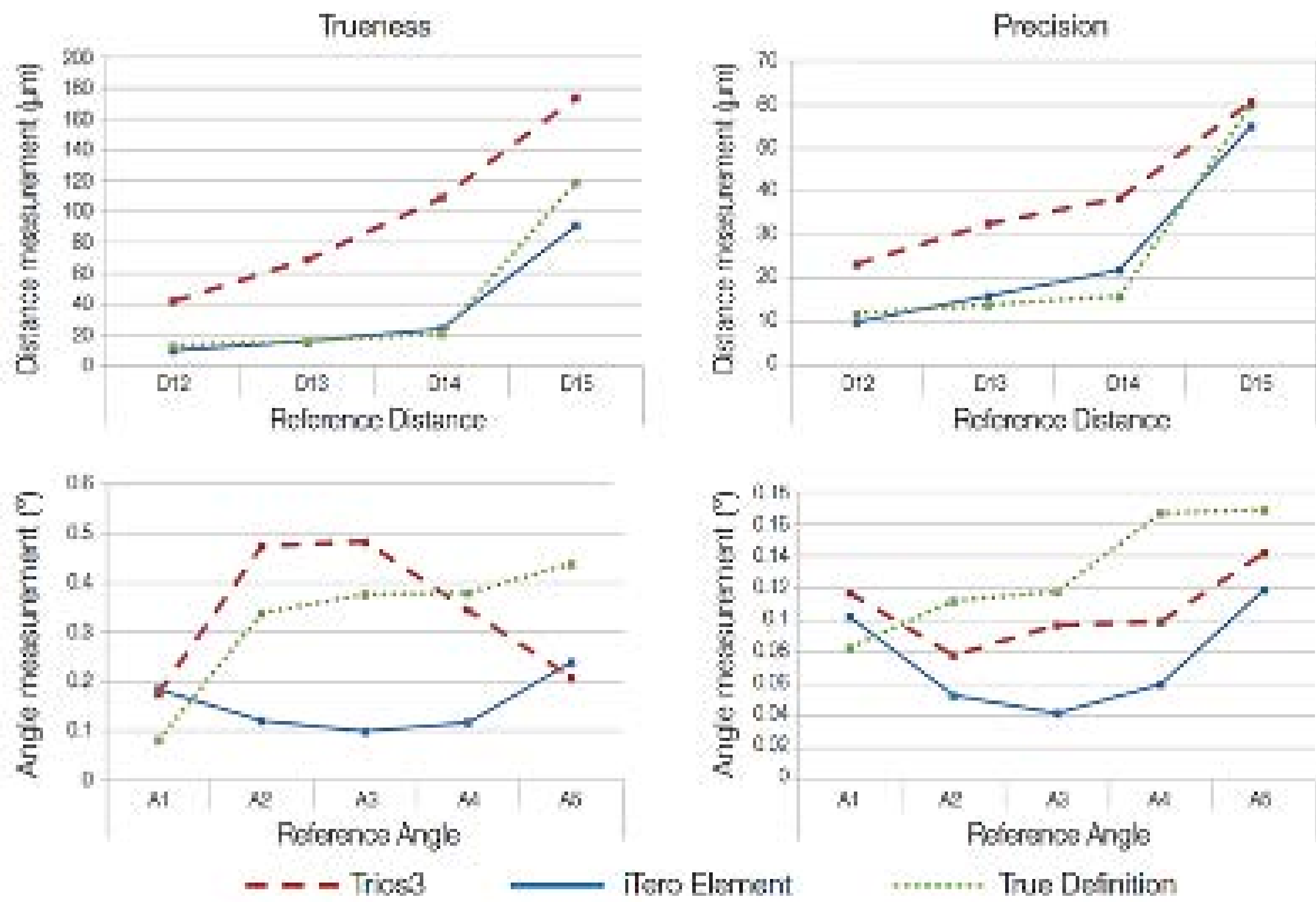
Reference: J Adv Prosthodont. 2019 Dec;11(6):331-340.

This text is lifted from the article.

To purchase and read the full article please [click here](#) ➤

Article Summary of:

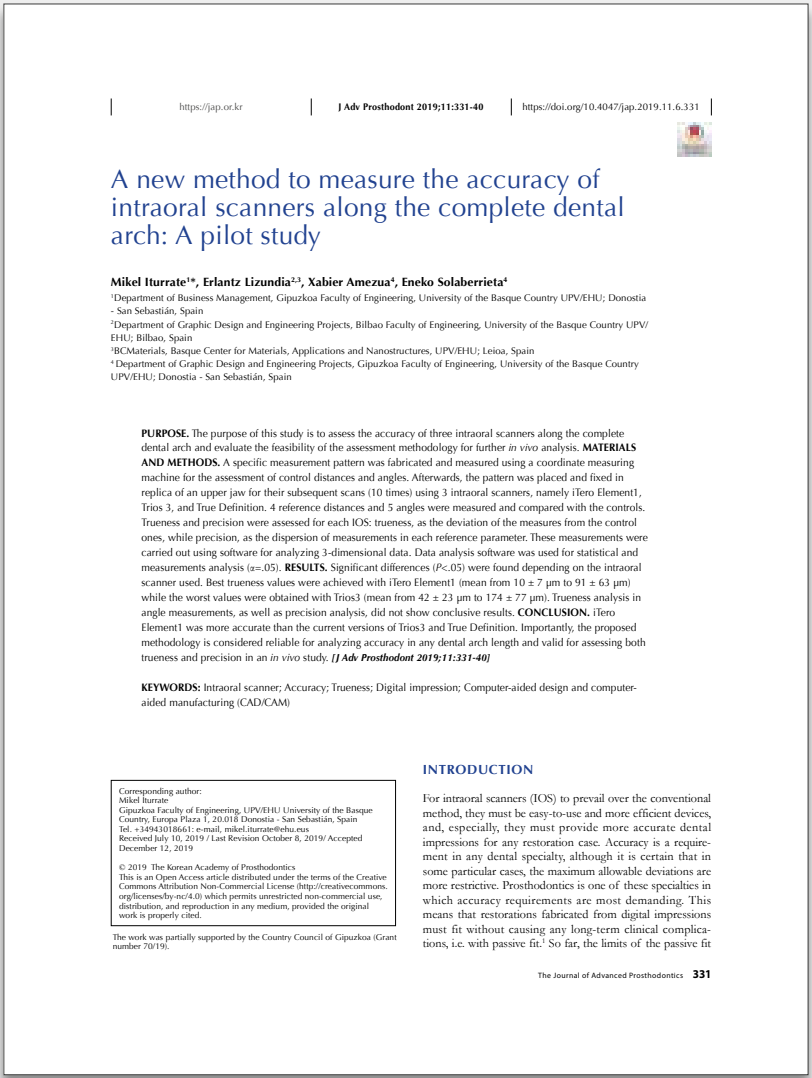“A new method to measure the accuracy of intraoral scanners along the complete dental arch: A pilot study.”



Conclusion:

iTero Element 1 was more accurate than the current versions of Trios 3 and True Definition. Importantly, the proposed methodology is considered reliable for analyzing accuracy in any dental arch length and valid for assessing both trueness and precision in an in vivo study.

Article:



Author:
Mikel Iturrate, Erlantz
Lizundia, Xabier Amezua,
Eneko Solaberrieta

Reference: J Adv
Prosthodont. 2019
Dec;11(6):331-340.

This text is lifted
from the article.
To purchase and read
the full article please
[click here](#) ➤

Article Summary of: “Randomized controlled clinical trial of digital and conventional workflows for the fabrication of zirconia-ceramic fixed partial dentures. Part III: Marginal and internal fit”



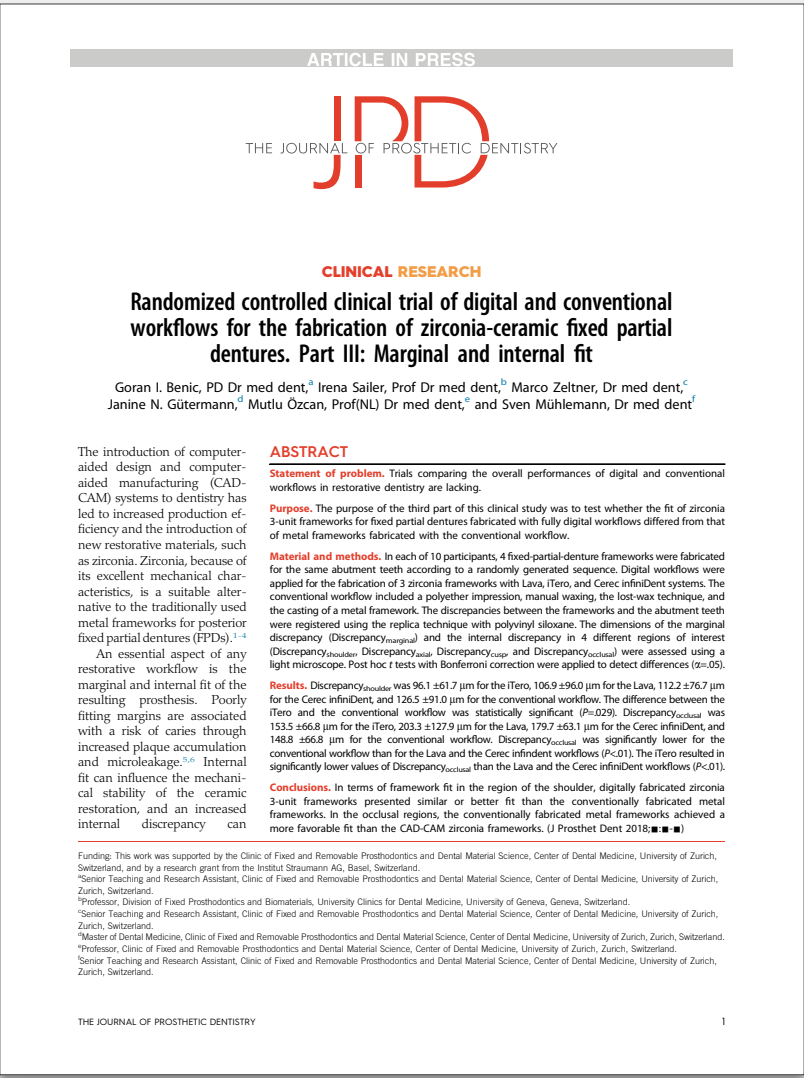Objectives:

The purpose of the third part of this clinical study was to test whether the fit of zirconia 3-unit frameworks for fixed partial dentures fabricated with fully digital workflows differed from that of metal frameworks fabricated with the conventional workflow.

Materials and Methods:

- 10 patients
- 4 fixed-partial-denture frameworks were fabricated for the same abutment teeth
- Digital workflows were applied for the fabrication of 3 zirconia frameworks with Lava, iTero, and Cerec infiniDent systems
- Conventional workflow included a polyether impression, manual waxing, the lost-wax technique, and the casting of a metal framework.
- Test : For each participant
 - 3 FPDs were digitally fabricated, and 1 FPD was conventionally fabricated.
 - The sequence of the FPD assessment was randomly allocated according to a computer-generated list.
 - To reduce operator bias, the investigators generated and evaluated the replicas without being able to distinguish among the digitally fabricated FPDs under investigation.

Article:



Author:
Goran I. Benic, Irena Sailer, Marco Zeltner, Janine N. Gütermann, Mutlu Özcan and Sven Mühlemann

Reference:
J Prosthet Dent. 2019 Mar;121(3):426-431

This text is lifted from the article.
To purchase and read the full article please [click here](#)

Article Summary of: “Randomized controlled clinical trial of digital and conventional workflows for the fabrication of zirconia-ceramic fixed partial dentures. Part III: Marginal and internal fit”



Results:	Conventional	iTero	Lava	CEREC infiniDent
Discrepancy shoulder	126.5 ±91.0 mm	96.1 ±61.7 mm	106.9 ±96.0 mm	112.2 ±76.7 mm

The difference between the iTero and the conventional workflow was statistically significant (P=.029).

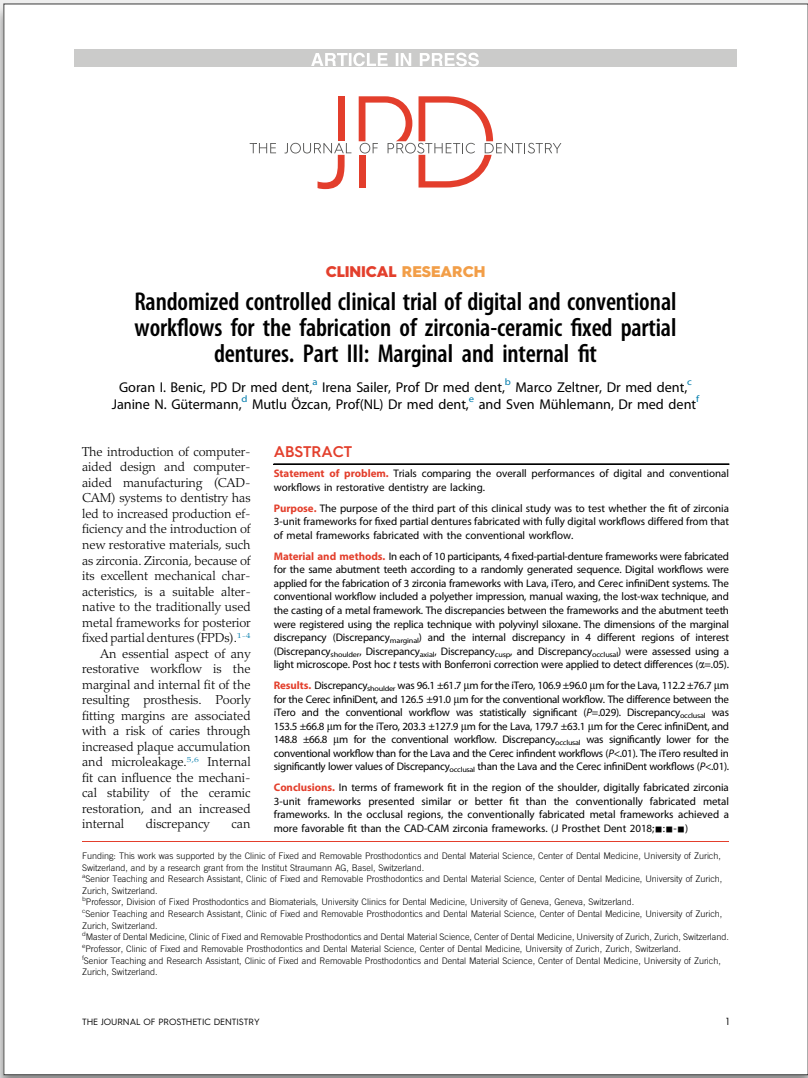Discrepancy occlusal	148.8 ±66.8 mm	153.5 ±66.8 mm	203.3 ±127.9 mm	179.7 ±63.1 mm
----------------------	----------------	----------------	-----------------	----------------

The iTero resulted in significantly lower values of Discrepancy occlusal than the Lava and the Cerec infini Dent workflows (P<.01).The difference between iTero and Conventional was not statistically significant.

Conclusion:

In terms of frameworks presented similar or better fit than the conventionally fabricated metal frameworks. In the occlusal regions, the conventionally fabricated metal frameworks achieved a more favorable fit than the CAD-CAM zirconia frameworks.

Article:



Author:
Goran I. Benic, Irena Sailer, Marco Zeltner, Janine N. Gütermann, Mutlu Özcan and Sven Mühlemann

Reference:
J Prosthet Dent. 2019 Mar;121(3):426-431

This text is lifted from the article.
To purchase and read the full article please [click here](#)

Article Summary of:

“Trueness of 12 intraoral scanners in the full-arch implant impression: a comparative in vitro study”

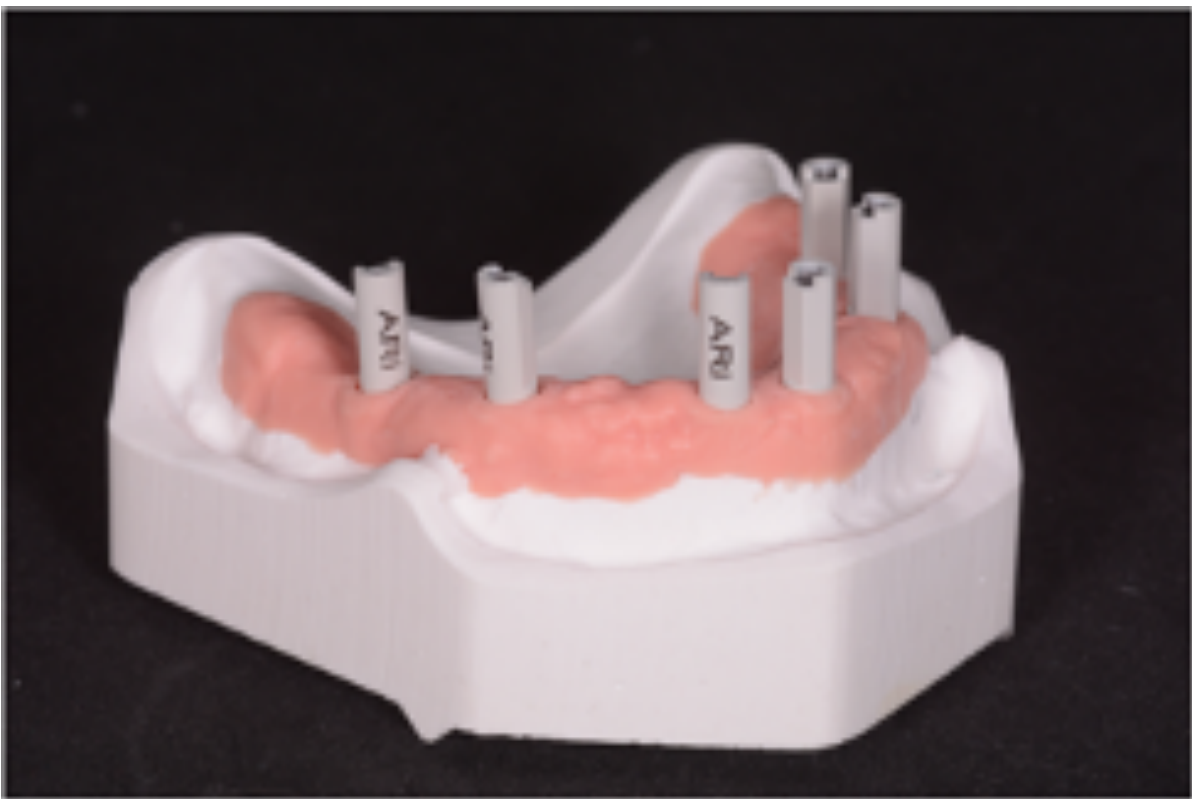


Objectives:

The aim of this in vitro study was to assess and compare the trueness of 12 different IOSs in FA implant impression.

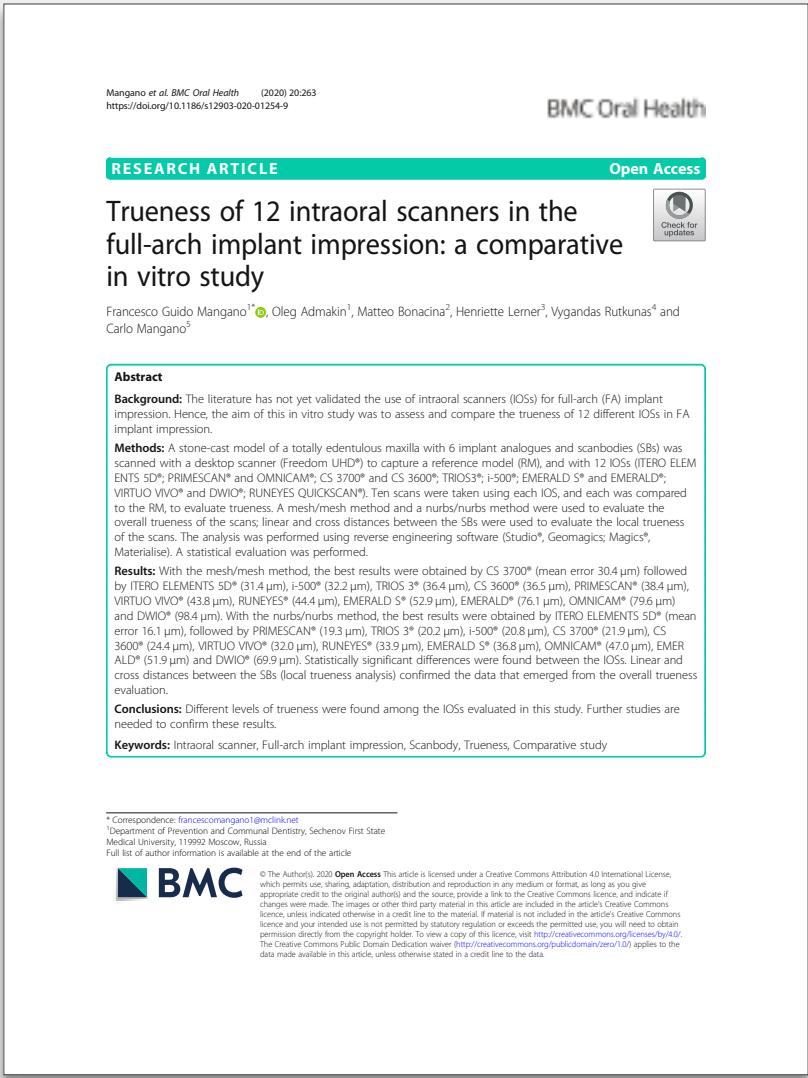
Materials and Methods:

- A stone-cast model of a totally edentulous maxilla with 6 implant analogues and scanbodies (SBs) was scanned with a desktop scanner (Freedom UHD®) to capture a reference model (RM), and with 12 IOSs :
 - ITERO ELEMENTS 5D®;
 - PRIMESCAN® and OMNICAM®;
 - CS 3700® and CS 3600®;
 - TRIOS3®; i-500®;
 - EMERALD S® and EMERALD® VIRTUO VIVO® and DWIO®;
 - RUNEYES QUICKSCAN®.
- Ten scans were taken using each IOS, and each was compared to the RM, to evaluate trueness.
- A mesh/mesh method and a nurbs/nurbs method were used to evaluate the overall trueness of the scans;
- Linear and cross distances between the SBs were used to evaluate the local trueness of the scans.
- The analysis was performed using reverse engineering software (Studio®, Geomagics Magics®,Materialise).
- A statistical evaluation was performed.



In this in vitro study, a type IV gypsum model was used. This model represented a totally edentulous maxilla with 6 implant analogues in positions #11, #14, #16, #21, #24 and #26 (right and left central incisors, first premolars and first molars) and high-precision non-reflective polyether-ether-ketone (PEEK) SBs (Megagen®, Daegu, South Korea) screwed on

Article:



Author:
Francesco Guido Mangano, Oleg Admakin, Matteo Bonacina, Henriette Lerner, Vygandas Rutkunas, Carlo Mangano

Reference:
doi.org/10.1186/s12903-020-01254-9

This text is lifted from the article.
To purchase and read the full article please [click here](#) ➔

Article Summary of:

“Trueness of 12 intraoral scanners in the full-arch implant impression: a comparative in vitro study”



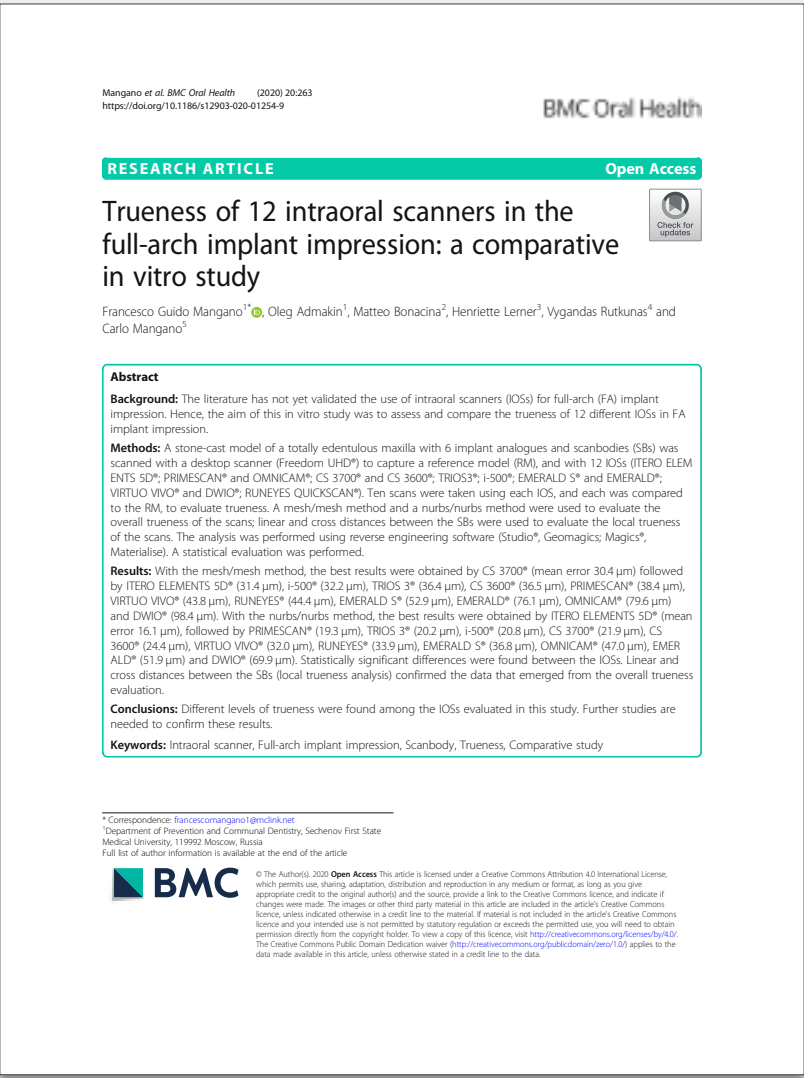
Results:

- Two methods of comparison were used:
- 1 - Mesh/mesh evaluation method
- 2 - Nurbs/nurbs evaluation method

Ranking (starting from best)	Mesh/Mesh Method	Nurbs/Nurbs Method
1	CS 3700® (mean error 30.4 μm)	ITERO ELEMENTS 5D® (mean error 16.1 μm)
2	ITERO ELEMENTS 5D® (31.4 μm),	PRIMESCAN® (19.3 μm),
3	i-500® (32.2 μm),	TRIOS 3® (20.2 μm),
4	TRIOS 3® (36.4 μm),	i-500® (20.8 μm),
5	CS 3600® (36.5 μm),	CS 3700® (21.9 μm),
6	PRIMESCAN® (38.4 μm),	CS3600® (24.4 μm),
7	VIRTUO VIVO® (43.8 μm),	VIRTUO VIVO® (32.0 μm),
8	RUNEYES® (44.4 μm),	RUNEYES® (33.9 μm),
9	EMERALD S® (52.9 μm),	EMERALD S® (36.8 μm),
10	EMERALD® (76.1 μm),	OMNICAM® (47.0 μm),
11	OMNICAM® (79.6 μm)	EMERALD® (51.9 μm)
12	DWIO® (98.4 μm).	DWIO® (69.9 μm).

Statistically significant differences were found between the IOSs. Linear and cross distances between the SBs (local trueness analysis) confirmed the data that emerged from the overall trueness evaluation.

Article:



Author:

Francesco Guido Mangano, Oleg Admakin, Matteo Bonacina, Henriette Lerner, Vygandas Rutkunas, Carlo Mangano

Reference:

doi.org/10.1186/s12903-020-01254-9

This text is lifted from the article.

To purchase and read the full article please [click here](#) ➔

Article Summary of:
“Trueness of 12 intraoral scanners in the full-arch implant impression: a comparative in vitro study”

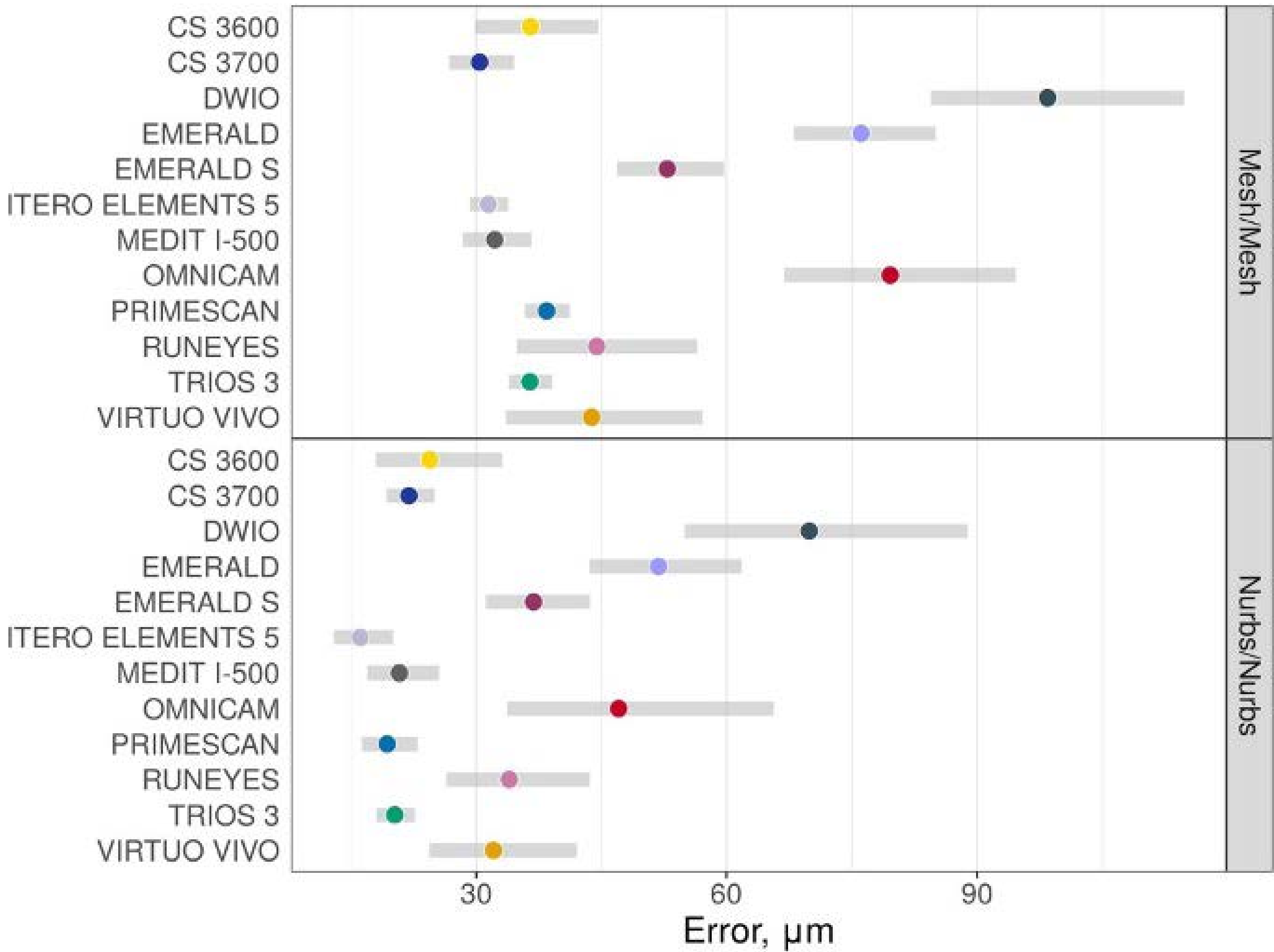
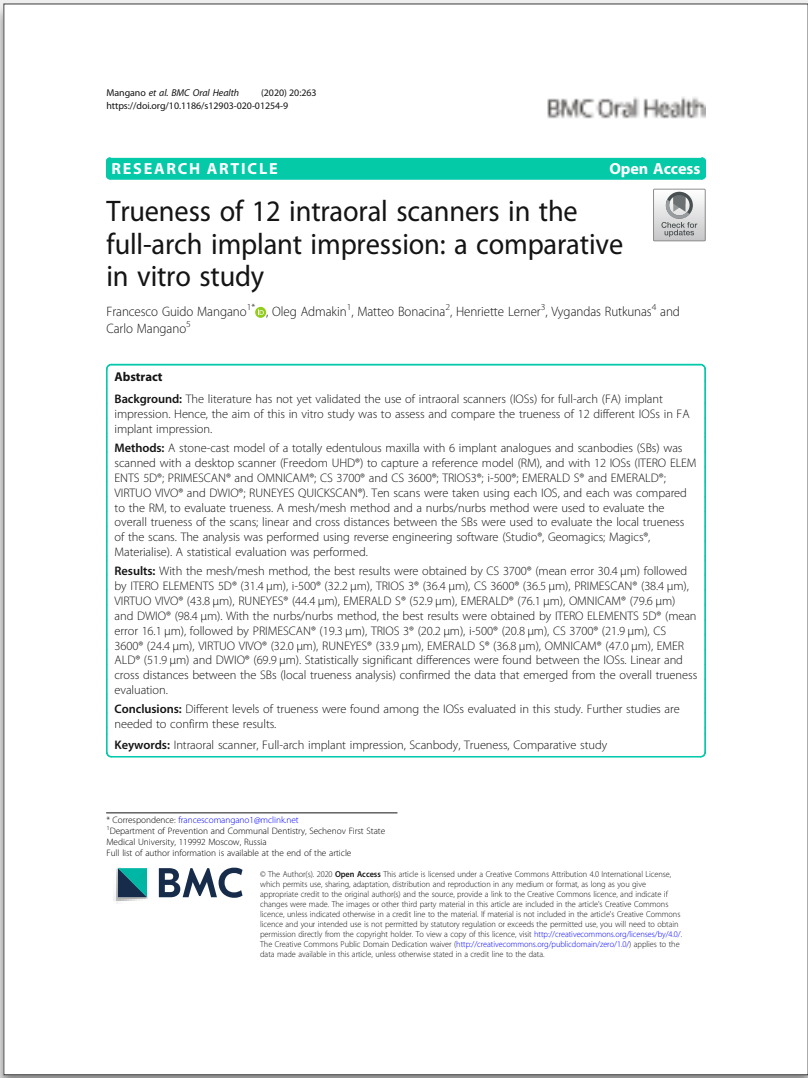


Fig. 3 Estimated mean errors (in µm, with 95% CIs) for mesh/mesh and nurbs/nurbs evaluations

Article:



Author:
Francesco Guido Mangano, Oleg Admakin, Matteo Bonacina, Henriette Lerner, Vyngandas Rutkunus, Carlo Mangano

Reference:
doi.org/10.1186/s12903-020-01254-9

This text is lifted from the article.
To purchase and read the full article please [click here](#)

Conclusion:
Different levels of trueness were found among the IOSs evaluated in this study. Further studies are needed to confirm these results.