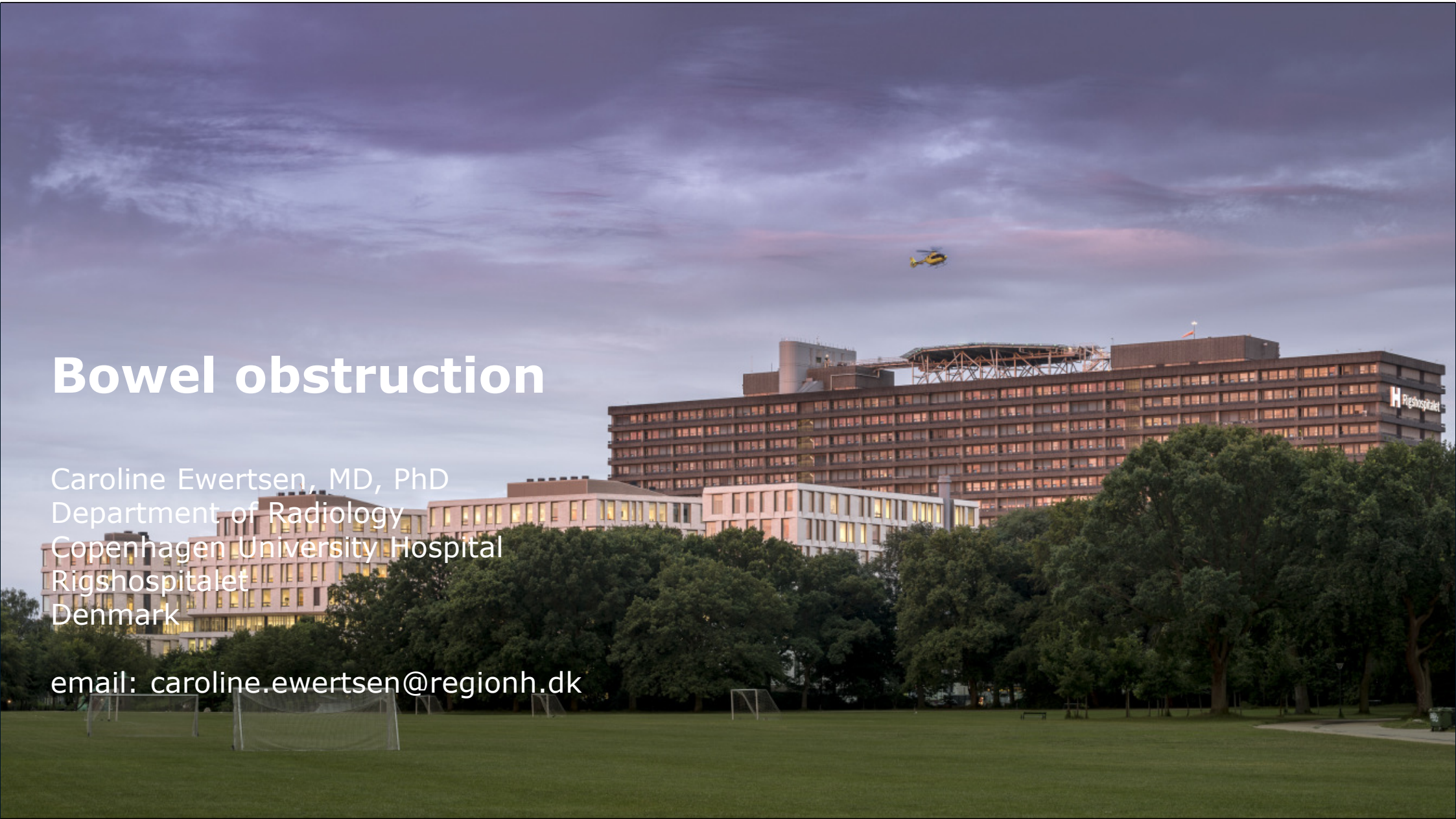


Bowel obstruction

Caroline Ewertsen, MD, PhD
Department of Radiology
Copenhagen University Hospital
Rigshospitalet
Denmark

email: caroline.ewertsen@regionh.dk

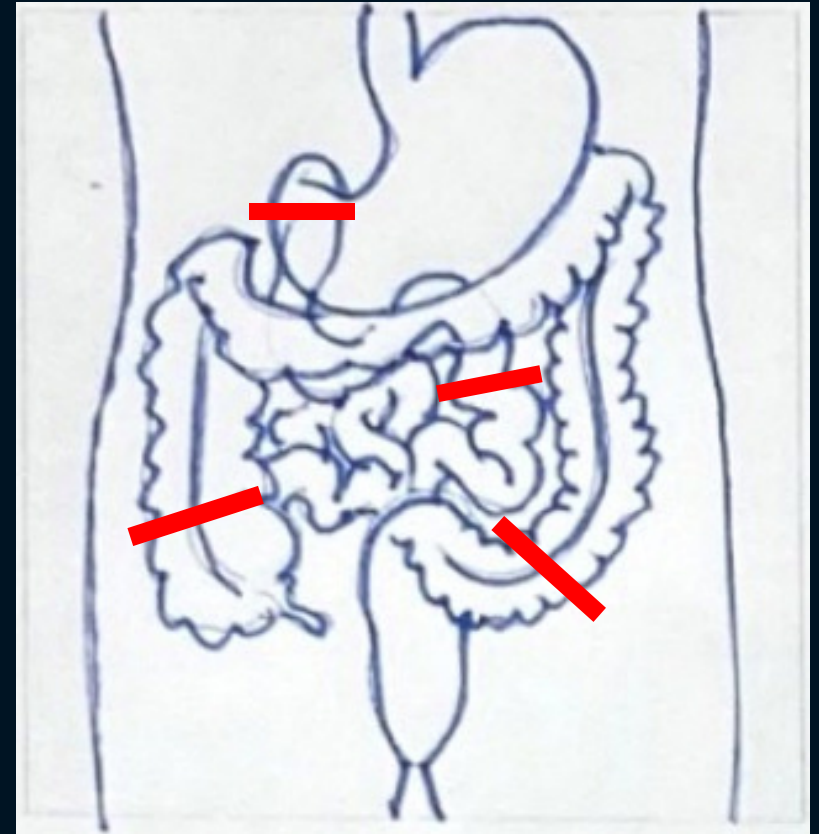


Disclosures

- Nothing to disclose

Bowel obstruction - locations

- High vs low
 - \cong 80% small bowel, 20% large bowel
- Partial vs complete
- Simple vs strangulated



Bowel obstruction – symptoms and signs

- Crampy abdominal pain (on palpation)
- Nausea
- Vomiting – relief of symptoms
- Feeling gassy
- Constipation
- Metallic bowel sounds

Bowel obstruction - reasons

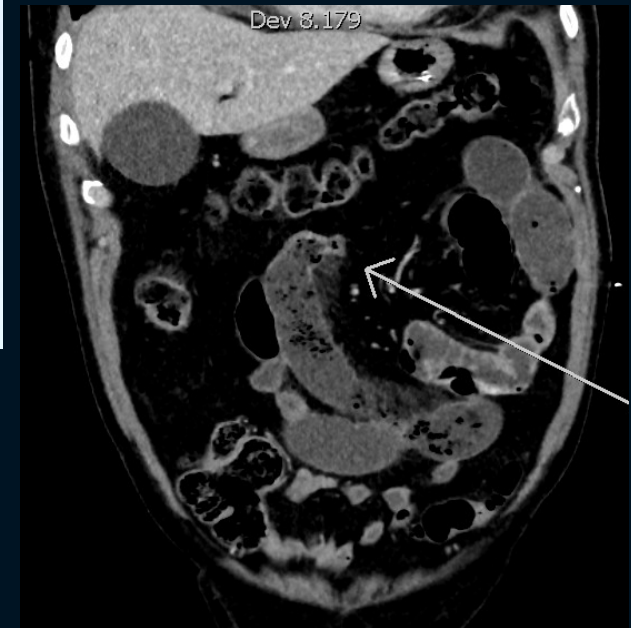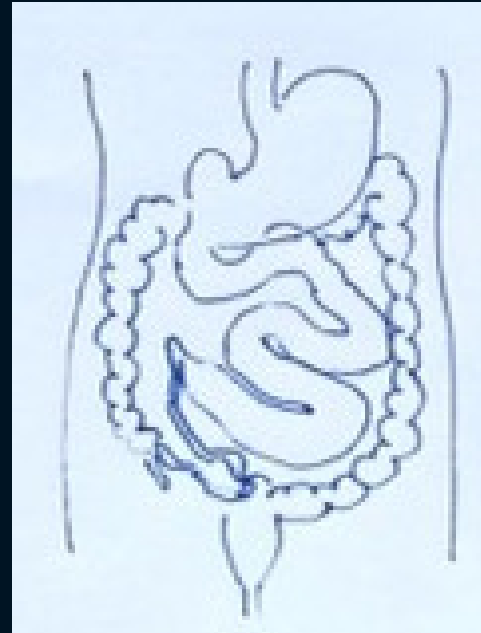
- Adhesions
 - Hernia
 - Volvulus
 - Intussusception
 - Scarring
 - Inflammatory bowel disease
 - Diverticulitis
 - Tumor
 - Foreign objects
 - Meckel's diverticulum
- Developed countries → >75% adhesions
 - Developing countries → >80% hernia

Bowel obstruction - imaging

- Plain abdominal film
 - Air/fluid levels
 - Dilatation
 - String-of-beads sign
 - Airless abdomen
- CT abdomen with iv-contrast
- Small bowel follow through
 - If immediate surgery is not indicated

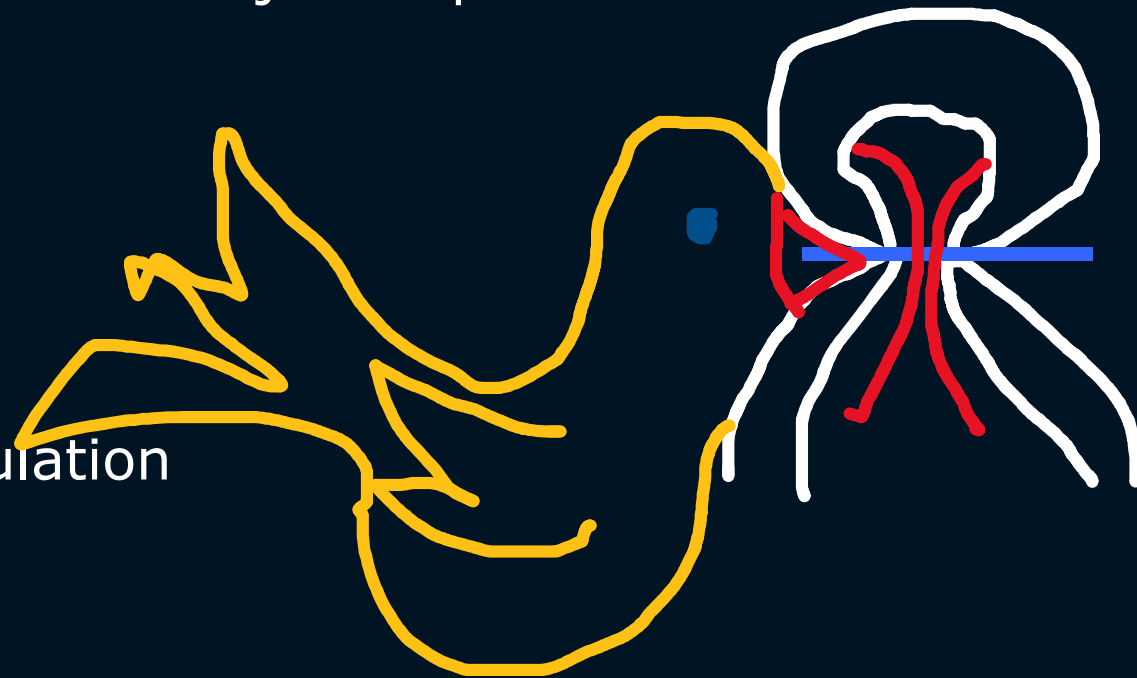Bowel obstruction – CT signs small bowel

- Dilatation $>2.5-3$ cm
 - Normal or collapsed bowel distally
- Small bowel feces sign
- Transition zone

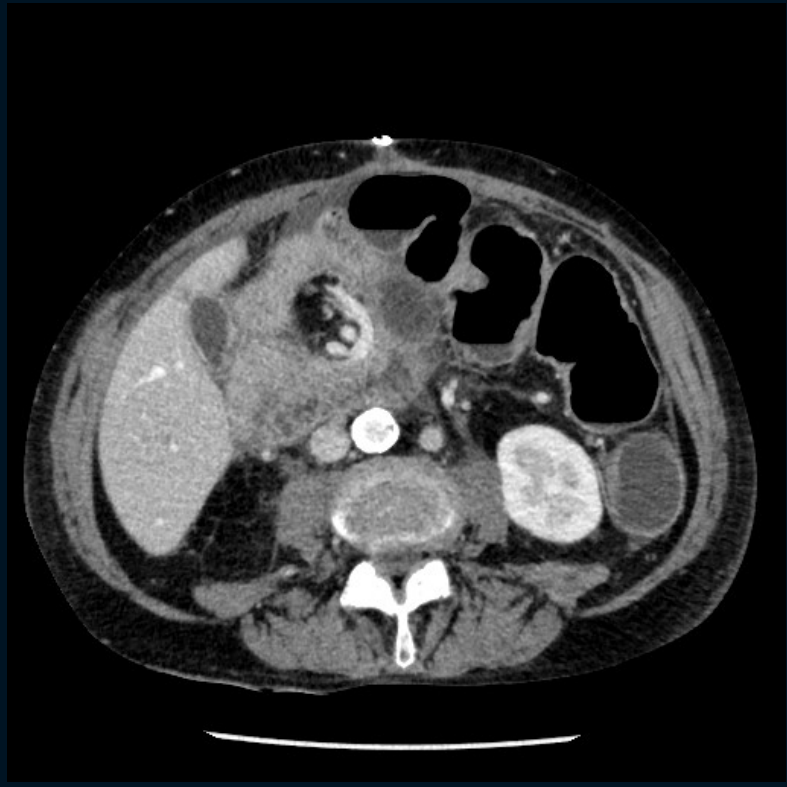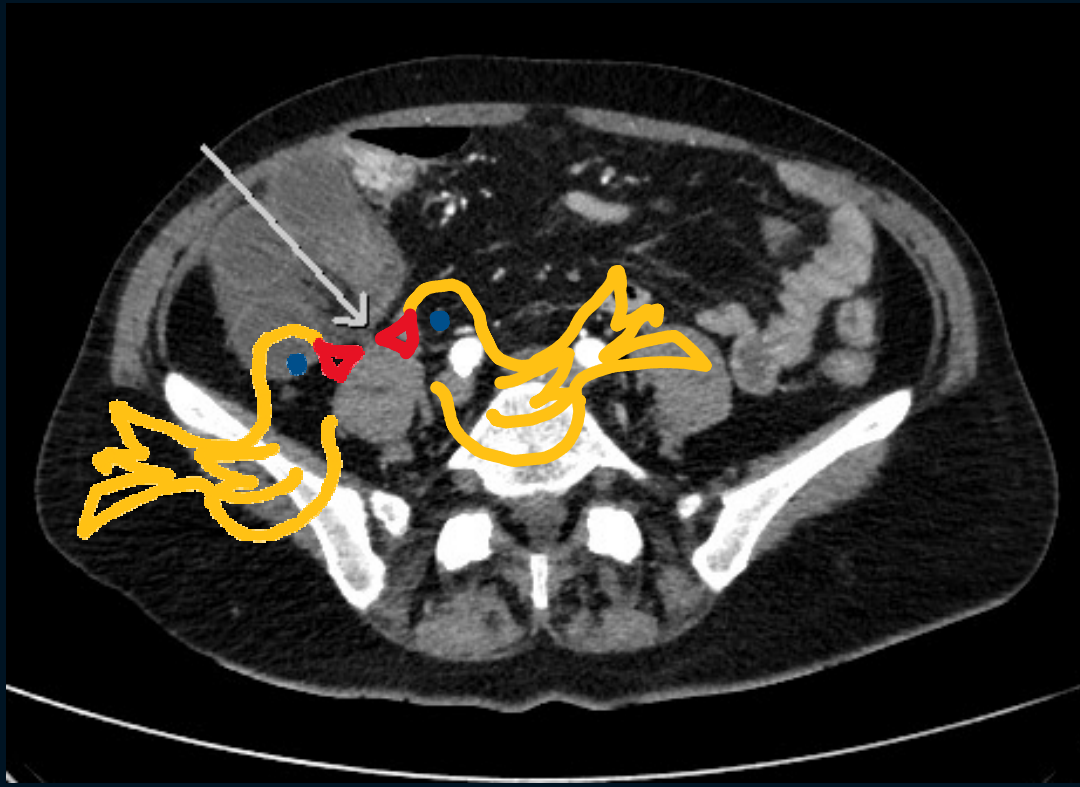


Bowel obstruction – closed loop

- Bowel loop occluded at two adjacent points
- Beak sign
- Whirl sign
- Risk of vessel strangulation



Bowel obstruction – closed loop

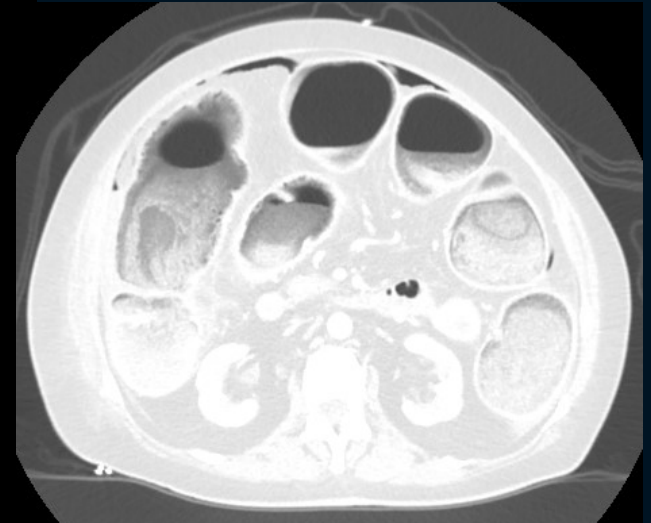
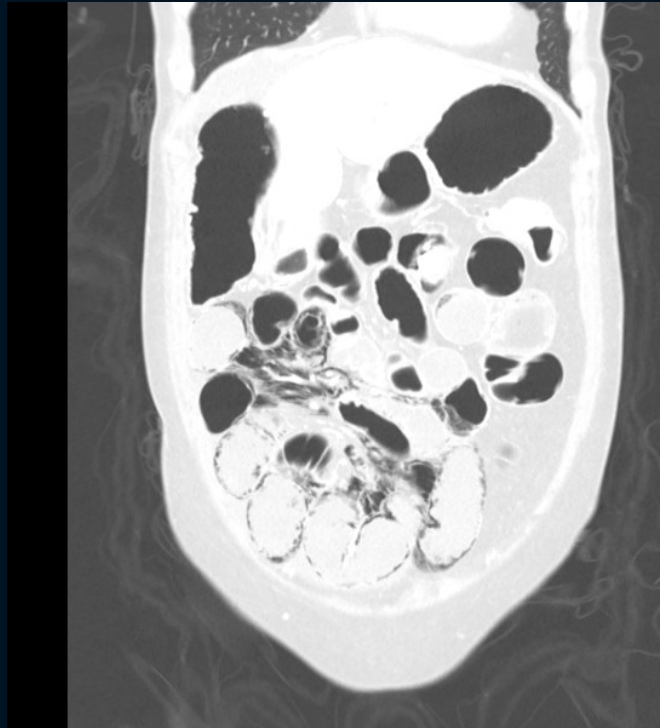


Bowel obstruction - large bowel

- > 6 cm – caecum > 9 cm
- Tumor
- Diverticulitis
- Volvulus
 - (Sigmoid more common than caecal)

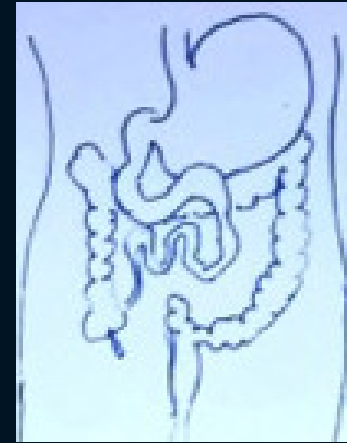Bowel obstruction - complications

- Strangulation of vessels
- Thickened and increased attenuation in the bowel wall due to venous stasis
- Decreased perfusion of bowel wall
- Ischemia
- Necrosis
- Pneumatosis intestinalis
- Portal venous gas
- Perforation

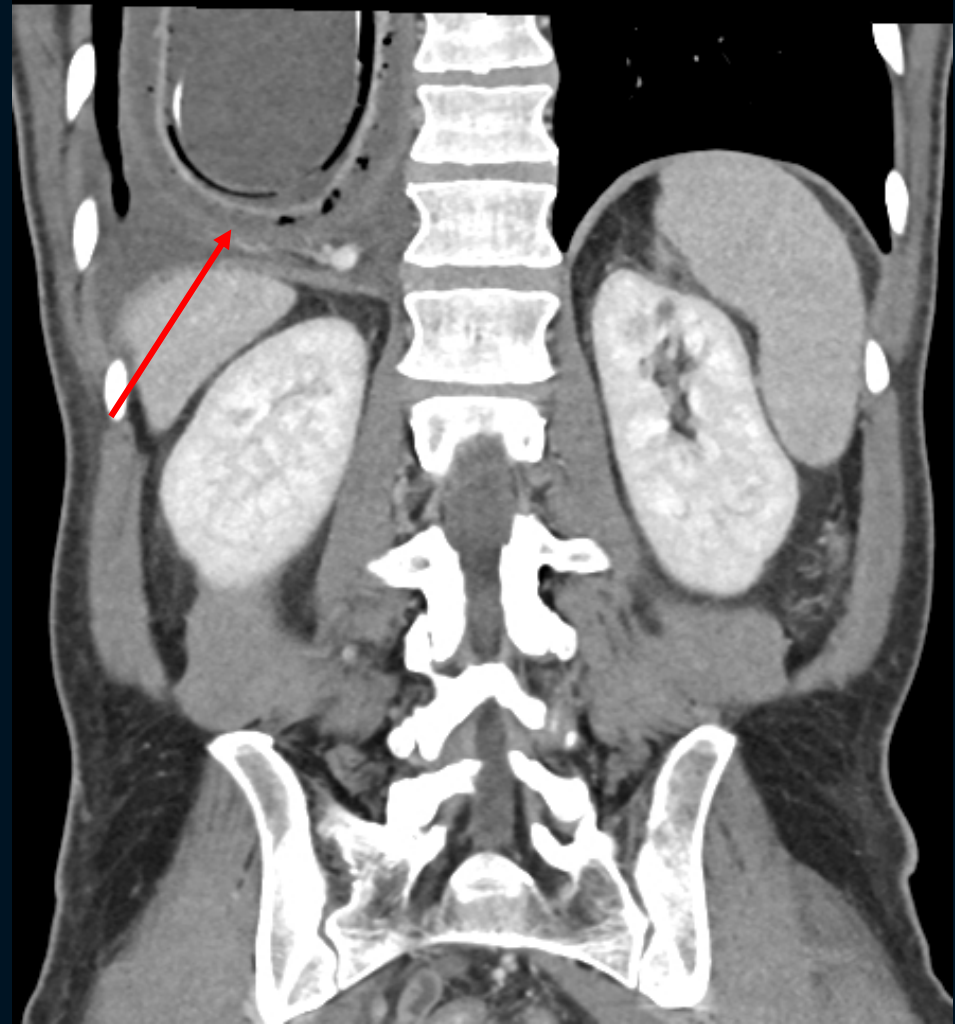
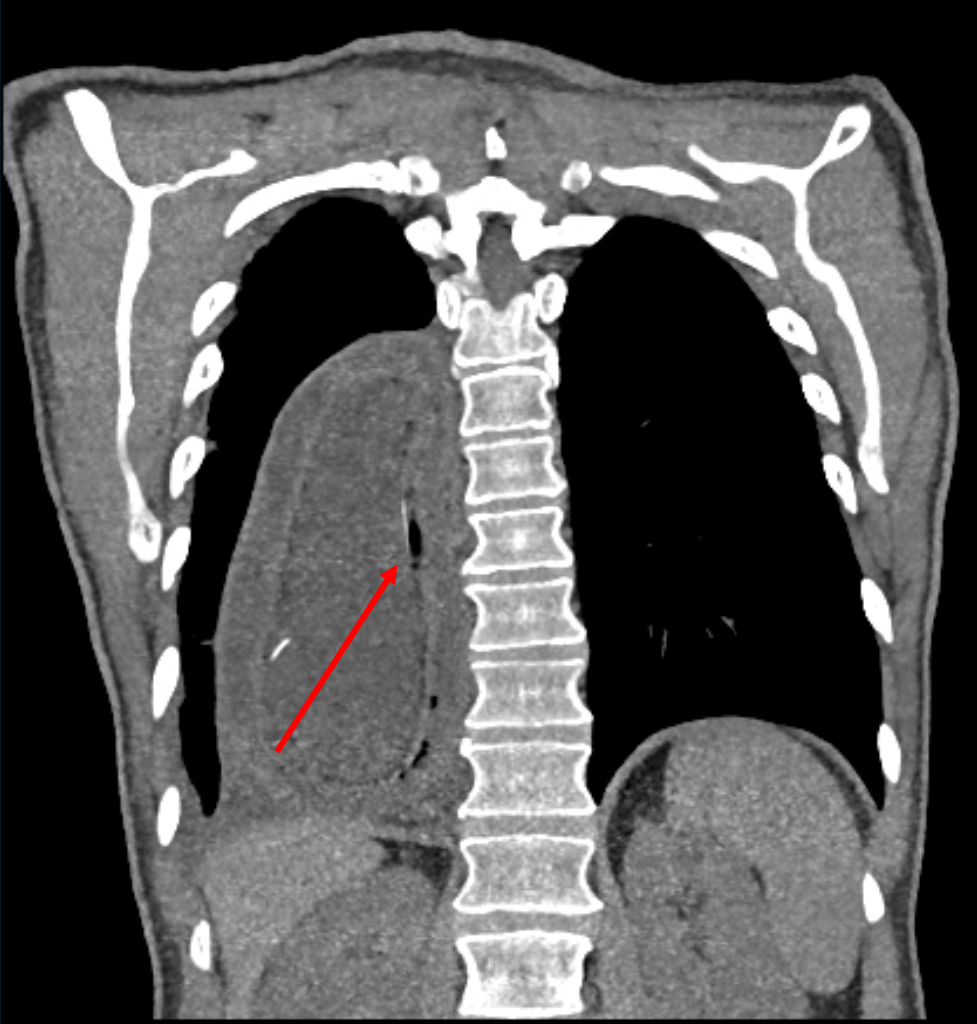


Bowel obstruction - high

- 69-yo female. Abdominal pain. Free gas?

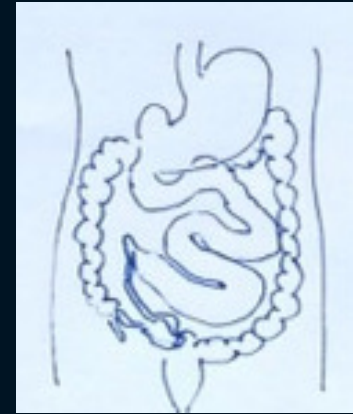


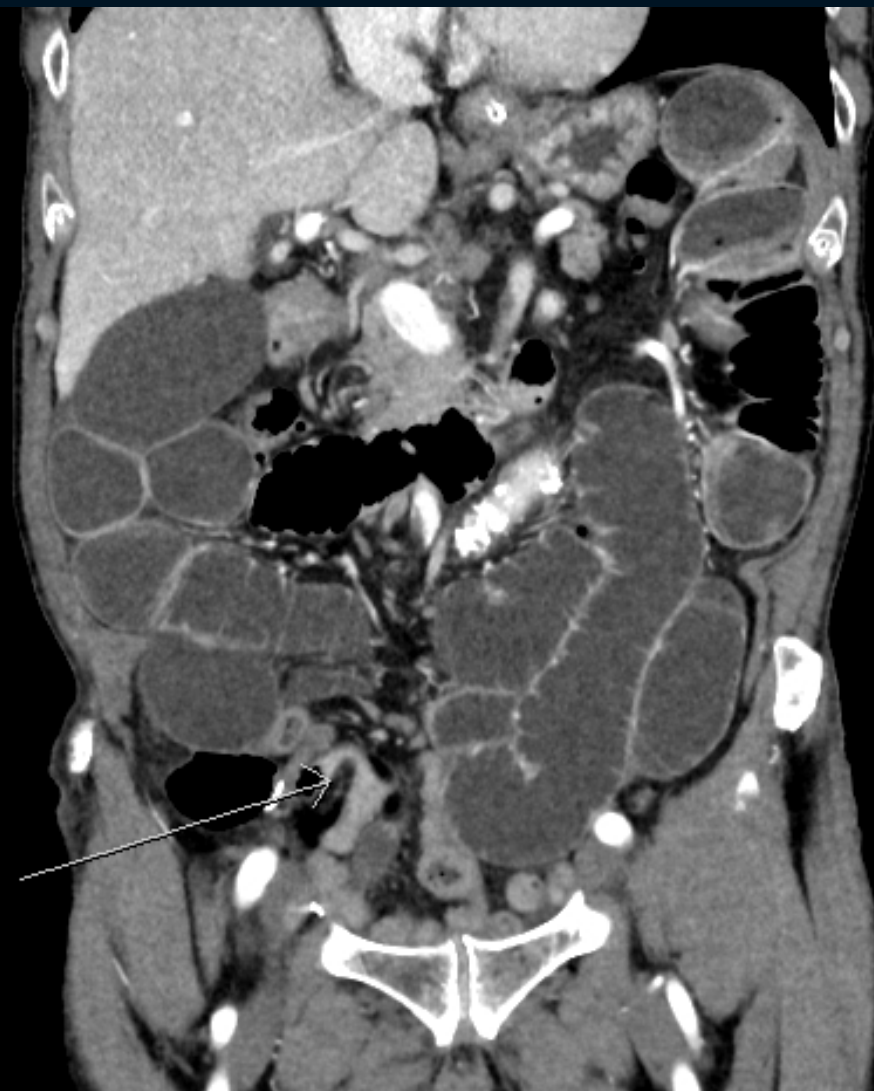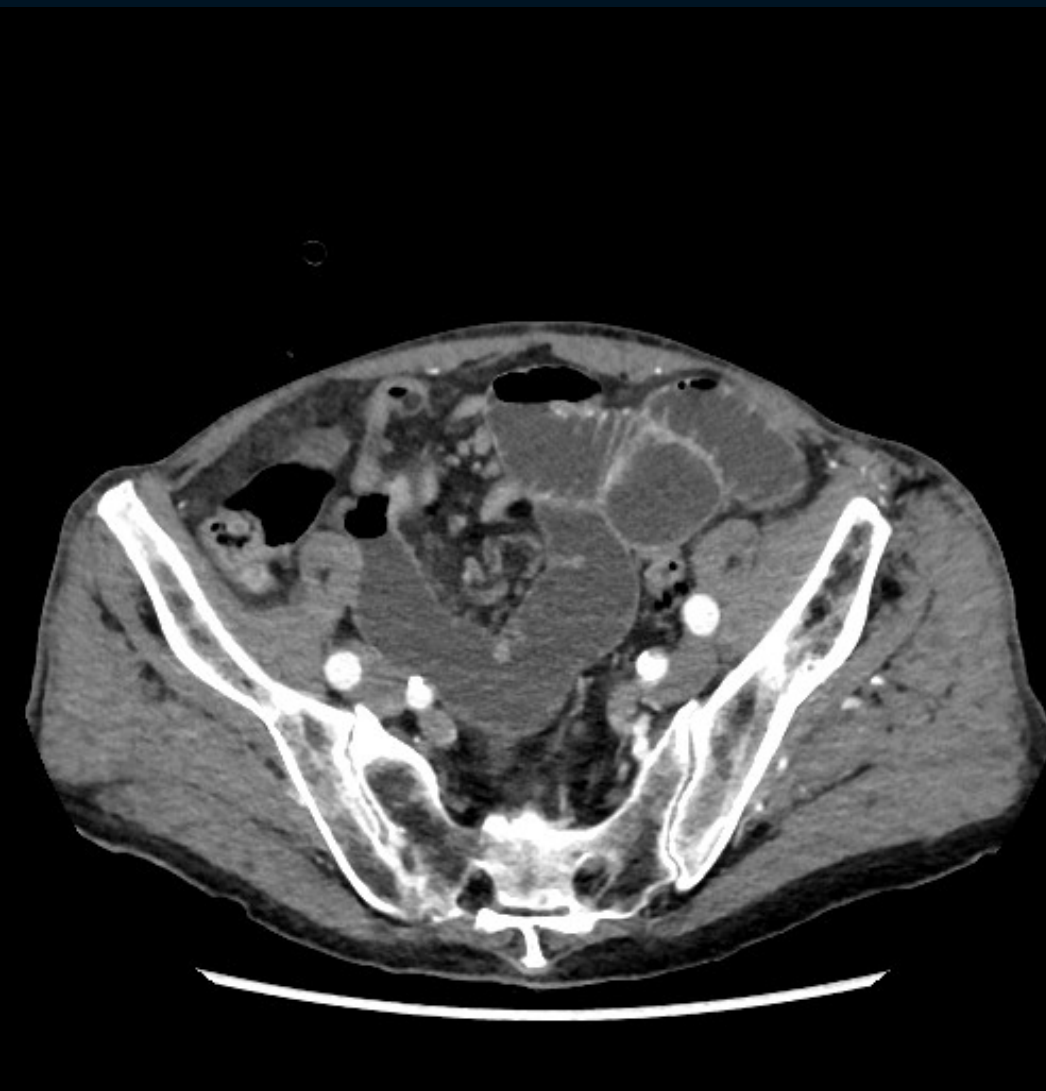Complication



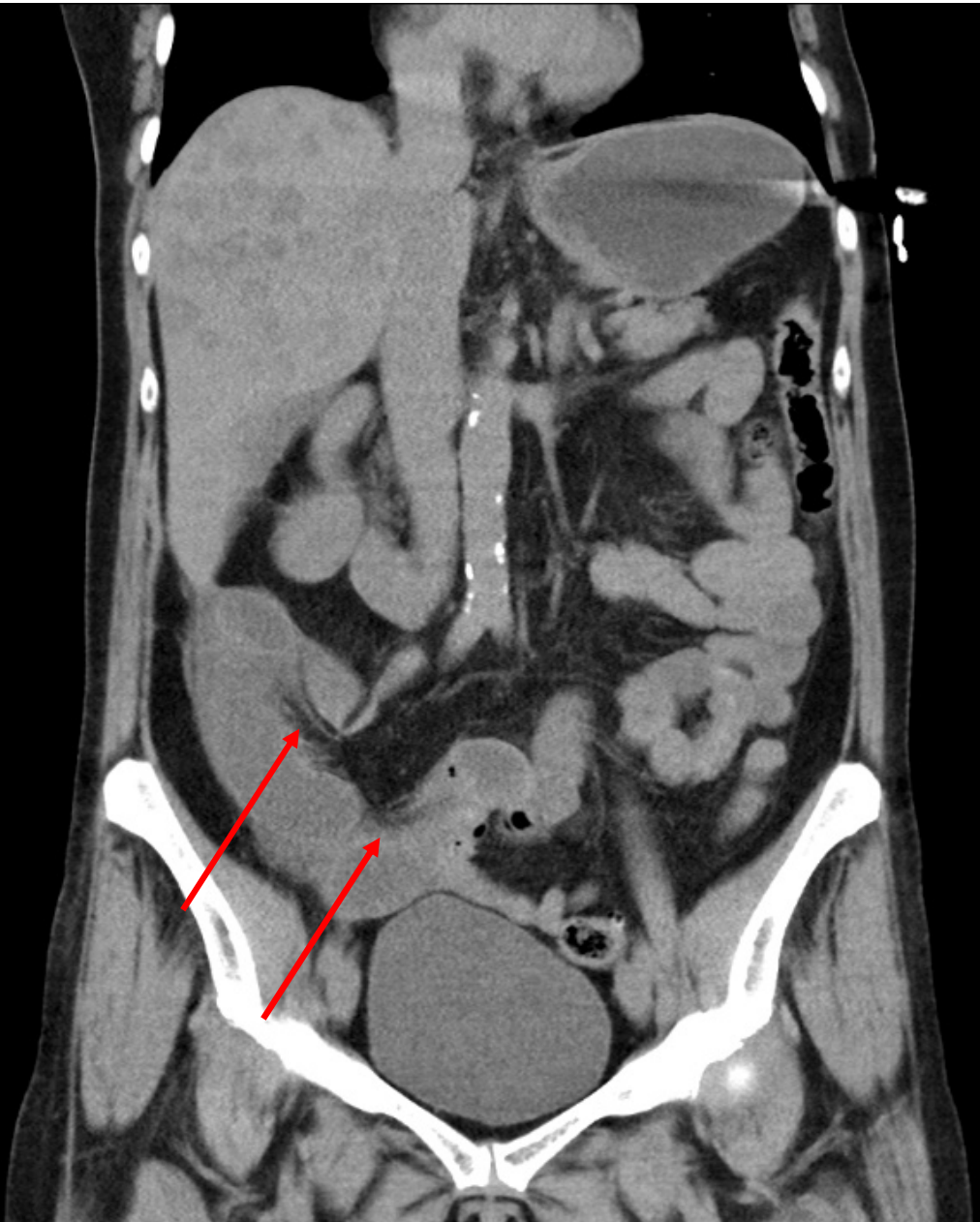
Bowel obstruction – small bowel

- 79-yo male, cystectomy 9 months prior, vomiting, abdominal pain.



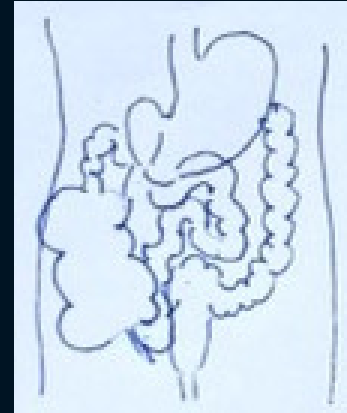


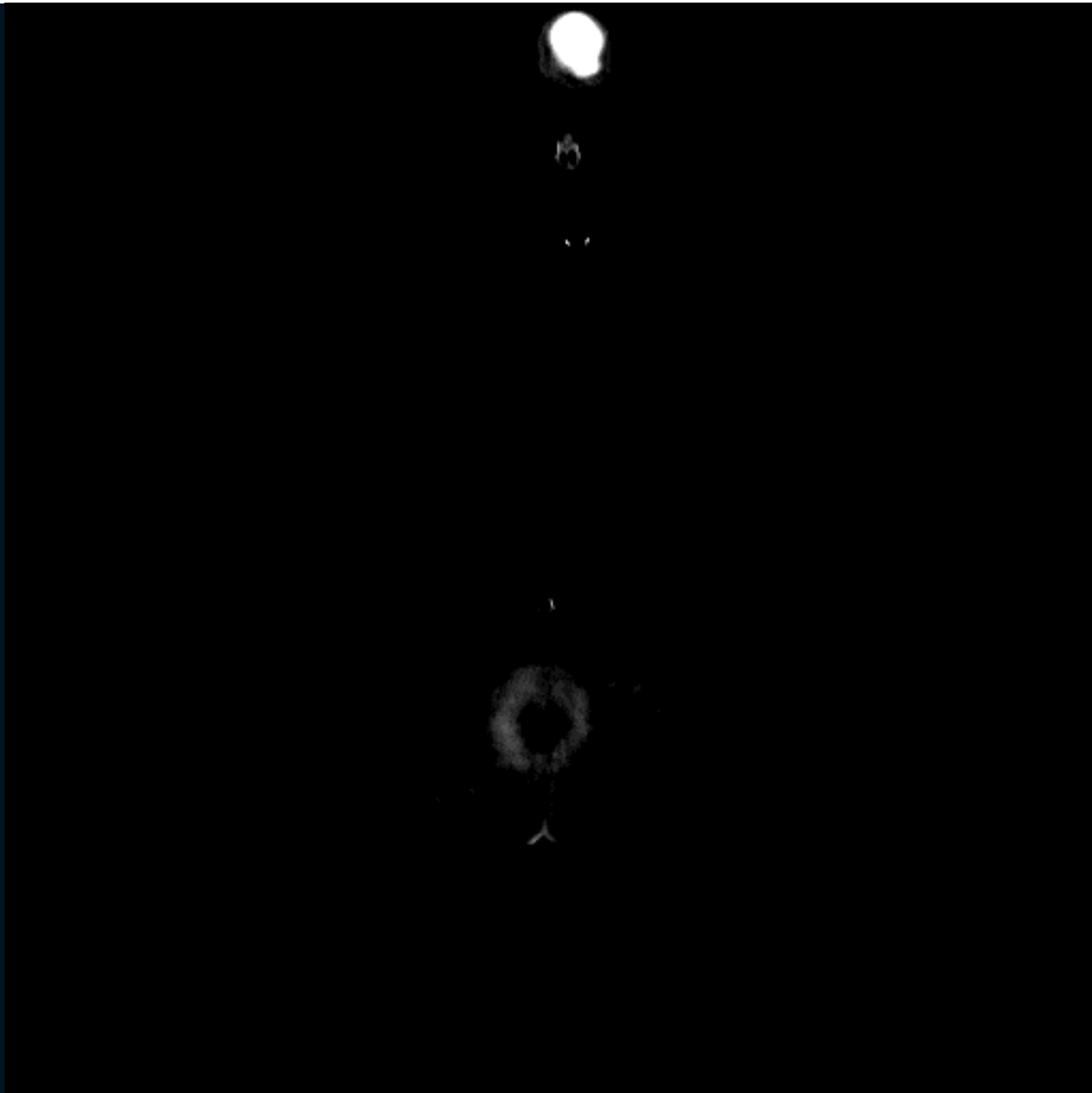
Closed loop



Bowel obstruction - low

- 63-yo female, abdominal and back pain, pale, fluctuation in BP, tachycardia. Type A dissection?






Caecal volvulus

- 73-yo female. Increasing abdominal pain and increasing size of the abdomen. Recent video-assisted thoracoscopic surgery.

Sigmoid volvulus

- 12-yo girl, mentally retarded, CF, and prone to obstipation. Abdominal pain.



Summary

- Ask for history/clinical findings
- CT with iv-contrast agent
- Look for a transition zone
 - Small bowel feces sign
- Look for the reason of obstruction
 - Hernia, tumor etc
- Look for complications
 - Ischemia
 - Pneumatosis
 - Portal venous gas

