



All imaging anonymised and pseudoanonymised



Thoracic Trauma: What not to Miss Interactive Session



Professor Elizabeth Dick, MRCP, FRCR, MD, EDER
Consultant Radiologist & Professor of Practice, Imperial College,
London, UK

Past President: British Society of Emergency Radiology &
European Society of Emergency Radiology



pollEv.com/edick900

elizabeth.dick1@nhs.net

Nordter, Stockholm, SE, June 2024

**TRAUMA
RADIOLOGY**

12TH NORDIC COURSE

**JUNE 10TH – 13TH, 2024
STOCKHOLM, SWEDEN**

Disclosures



1.GC Global Healthcare/RANZCR:


Speaker sponsorship for RANZCR Brisbane 2023

pollEv.com/edick900

2.Everlight Radiology: honorarium (2023) donated to Crisis Rescue Foundation and Meningitis Now

Learning Objectives

1. Develop a personal checklist for Thoracic trauma imaging
2. Understand how mechanism of injury and patient physiology influence findings



pollEv.com/edick900

CHECKLIST

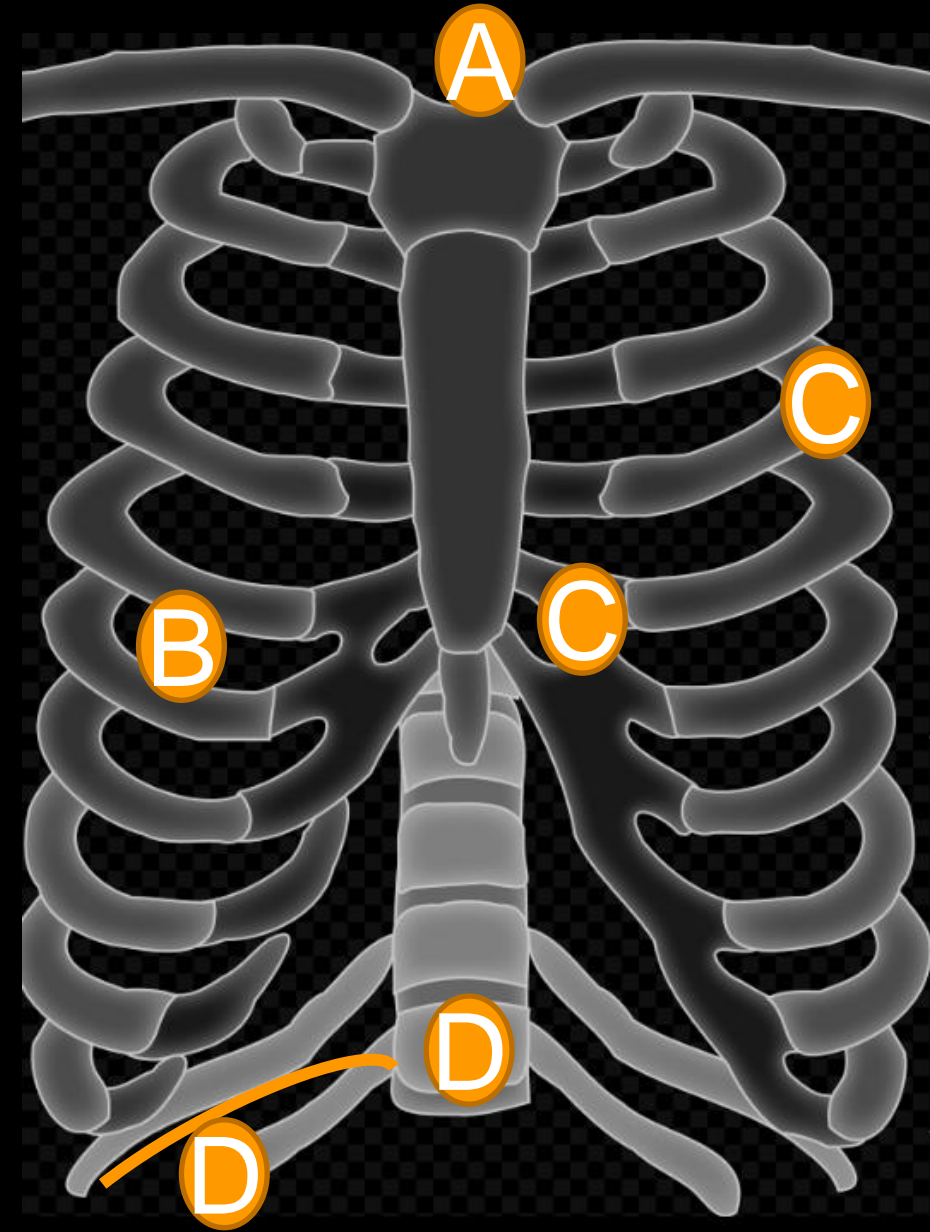
A airway

B breathing

C circulation, chest wall,
costal cartilage

(3)D diaphragm, disability

pollEv.com/edick900



AIRWAY

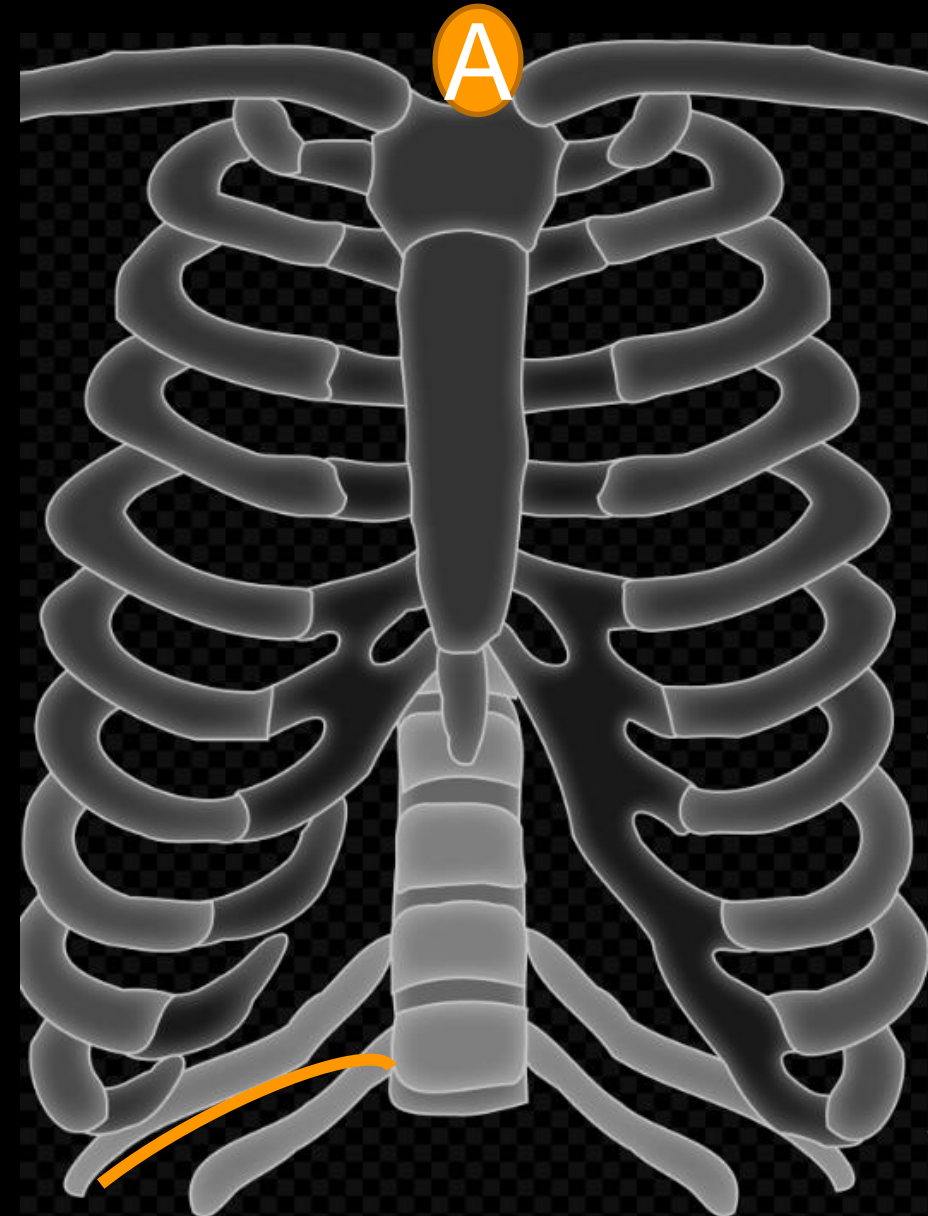
A airway

B breathing

C circulation, chest wall,
costal cartilage

(3)D diaphragm, disability

pollEv.com/edick900



AIRWAY CHECKLIST

Trachea & bronchi – intact?

Debris

Endotracheal tube and cuff

pollEv.com/edick900



AIRWAY CHECKLIST

Trachea & bronchi – intact?

Debris

Endotracheal tube and cuff

pollEv.com/edick900



AIRWAY CHECKLIST

Trachea & bronchi – intact?

Debris

Endotracheal tube and cuff

pollEv.com/edick900

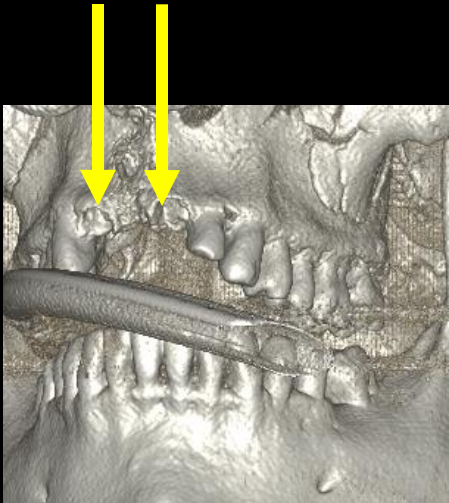


AIRWAY CHECKLIST

Trachea & bronchi – intact?

Debris

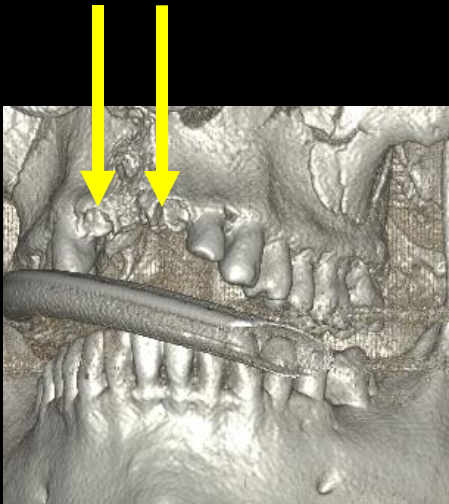
Endotracheal tube and cuff



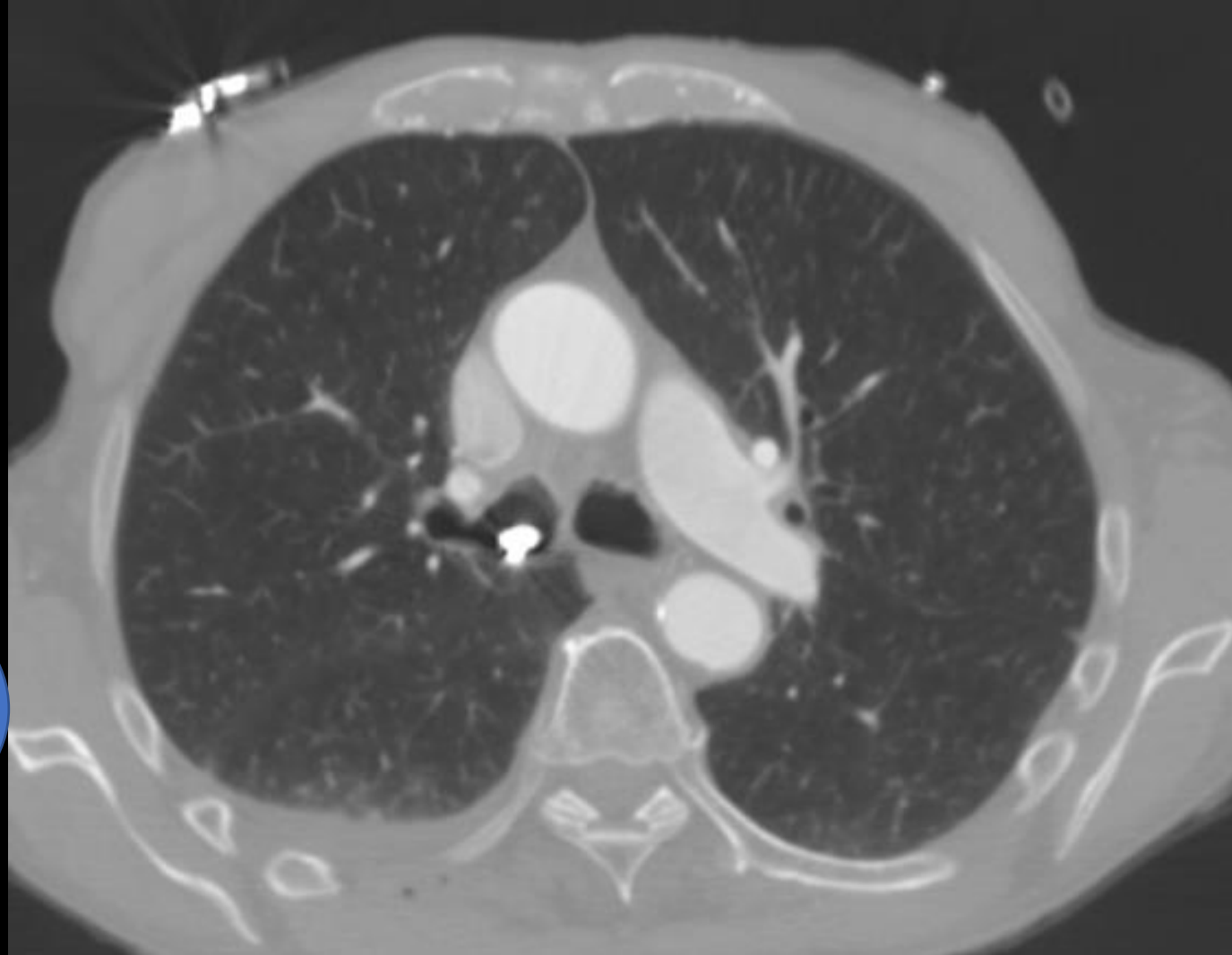Mechanism
of Injury

AIRWAY CHECKLIST

Trachea & bronchi – intact?
Debris
Endotracheal tube and cuff



Mechanism
of Injury

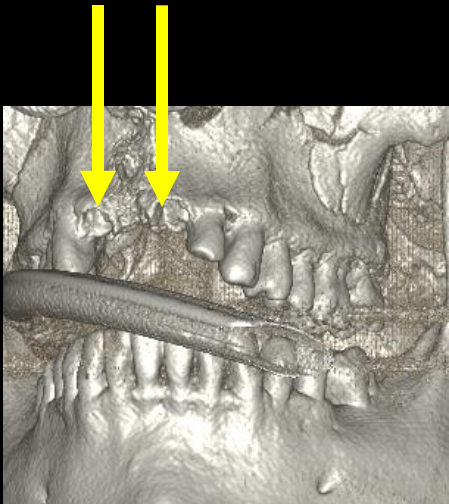


AIRWAY CHECKLIST

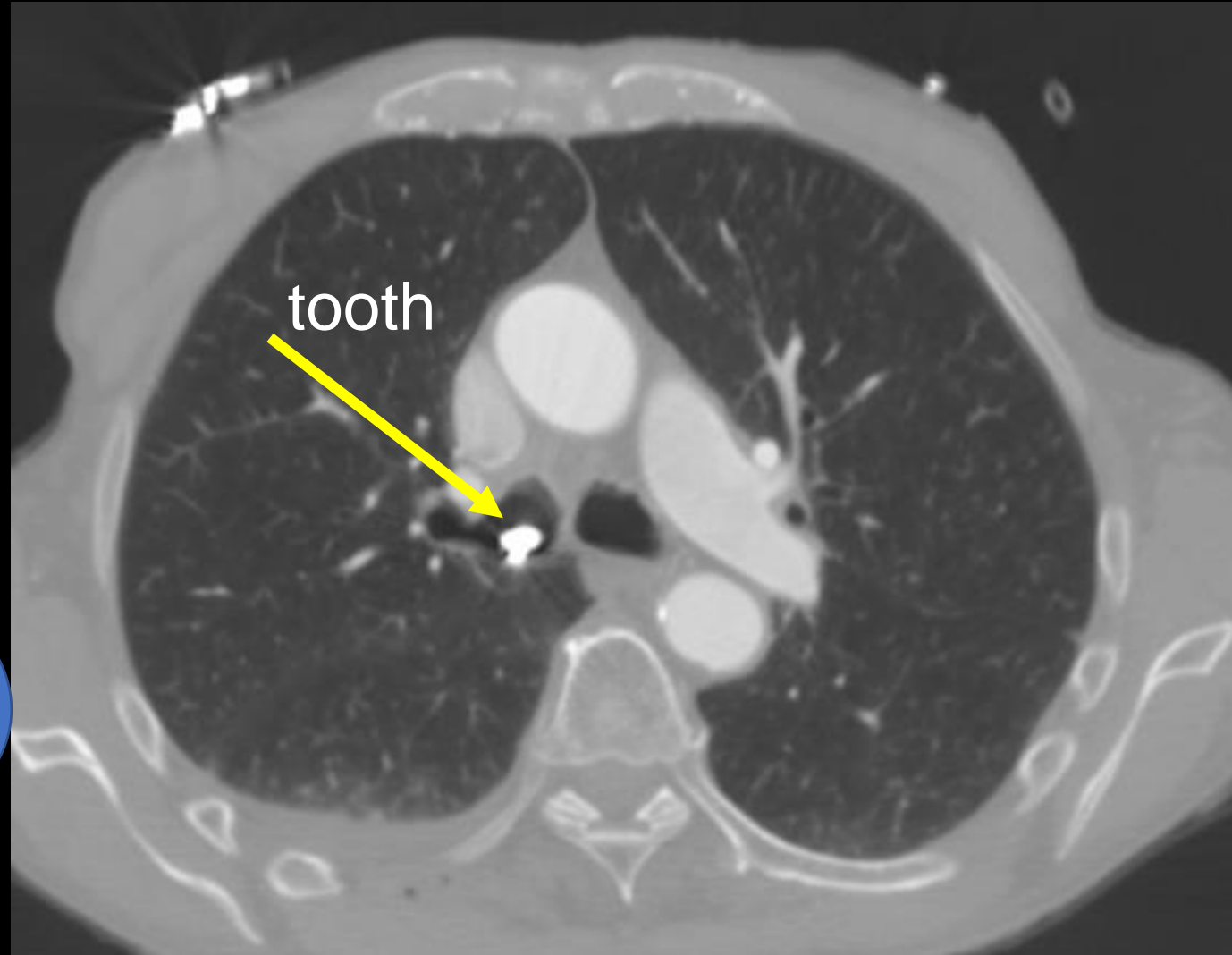
Trachea & bronchi – intact?

Debris

Endotracheal tube and cuff



Mechanism
of Injury



AIRWAY CHECKLIST

ETT in airway?

ETT tip >5cm above the carina

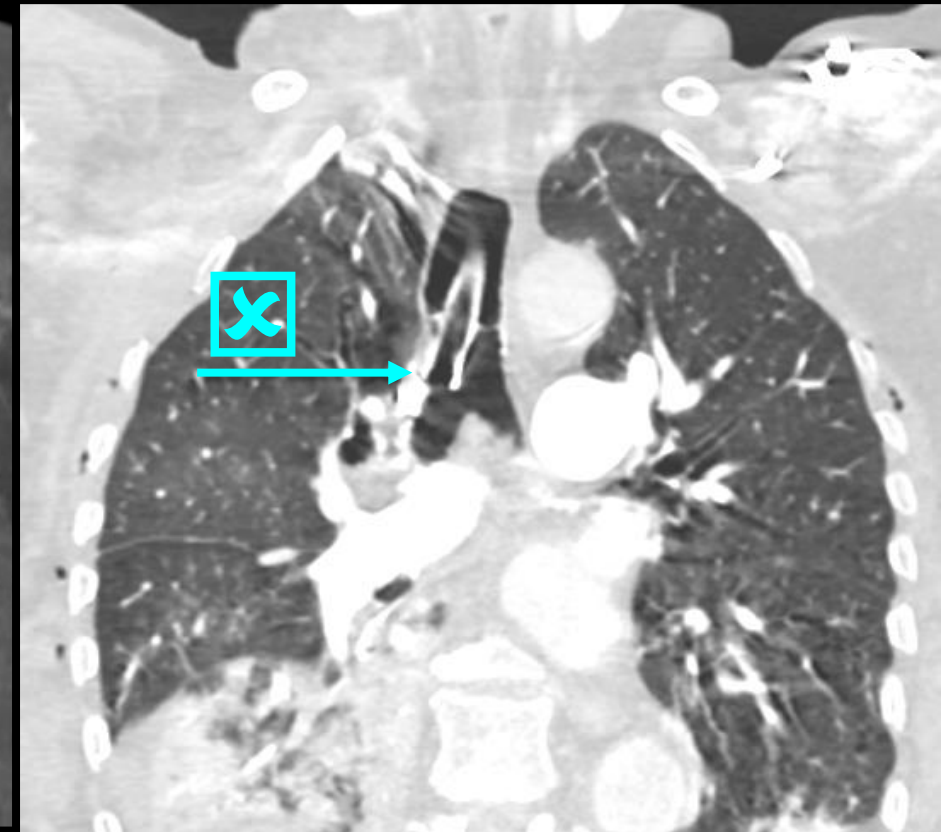
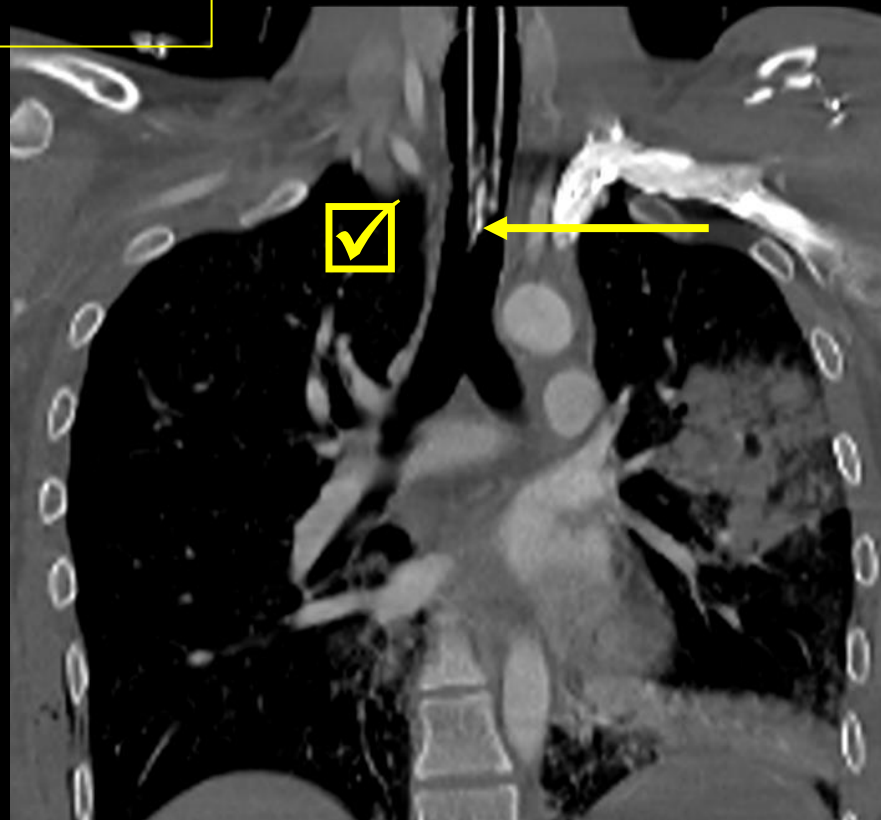
Cuff below vocal cords

Cuff symmetrical

Cuff diameter < 2.8cm

Endotracheal tube

Position: Tip should be 5cm above carina



AIRWAY CHECKLIST

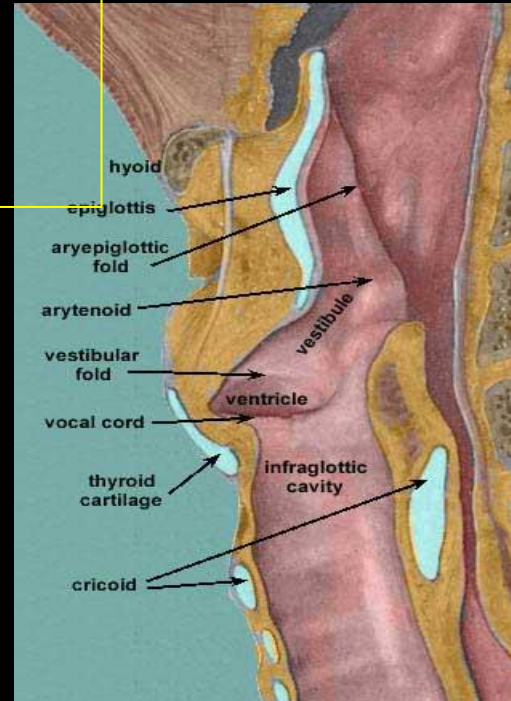
ETT in airway?

ETT tip >5cm above the carina

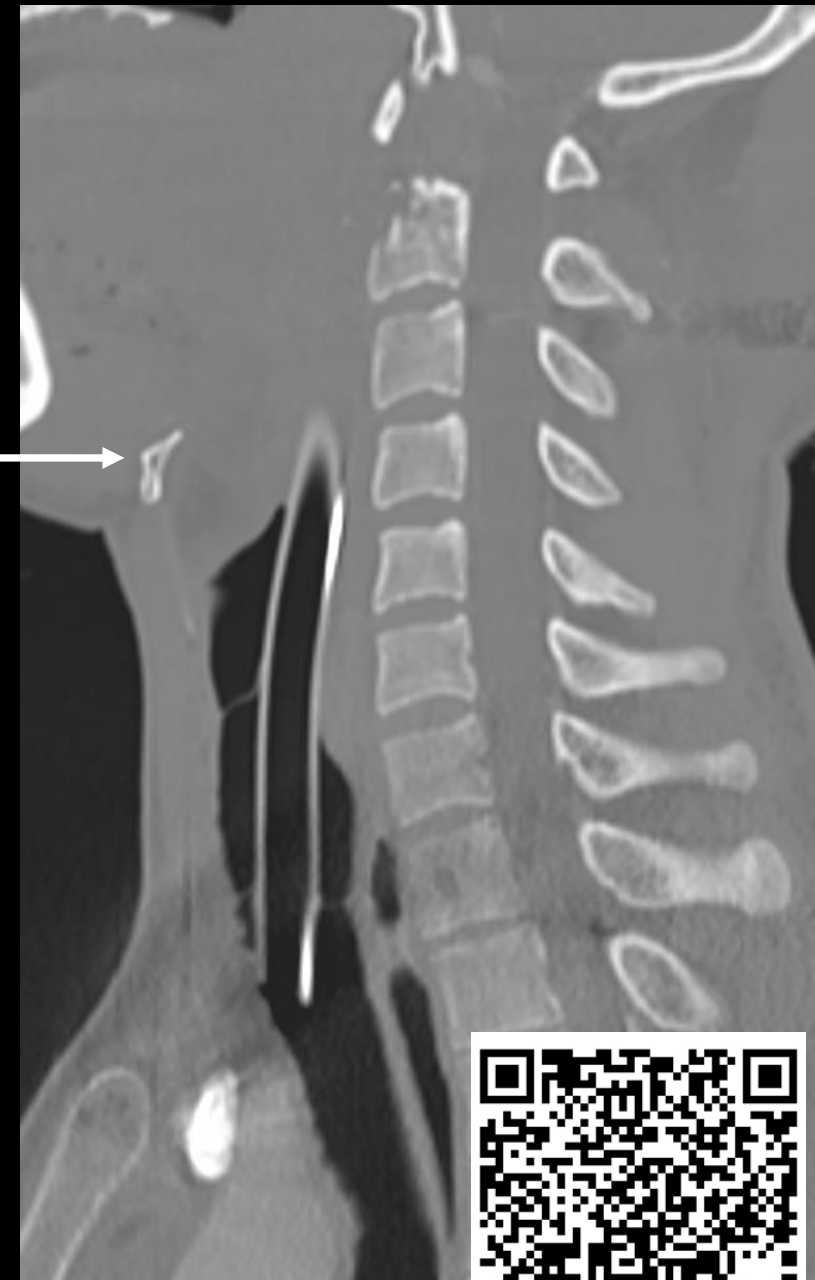Cuff below vocal cords

Cuff symmetrical

Cuff diameter < 2.8cm



Hyoid →



AIRWAY CHECKLIST

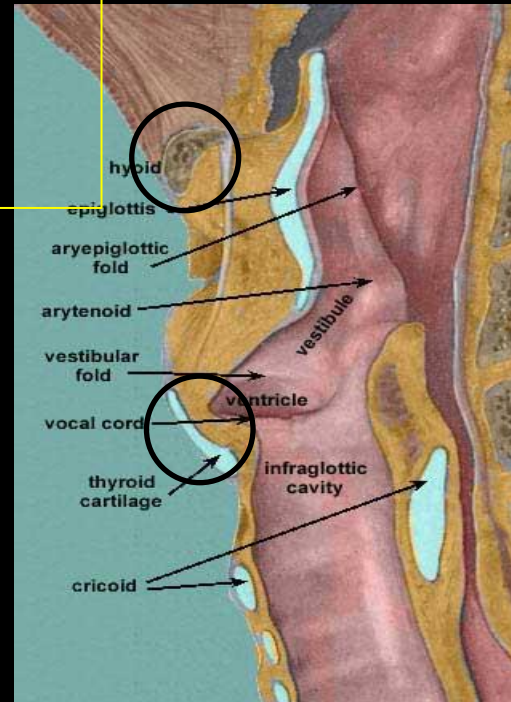
ETT in airway?

ETT tip >5cm above the carina

Cuff below vocal cords

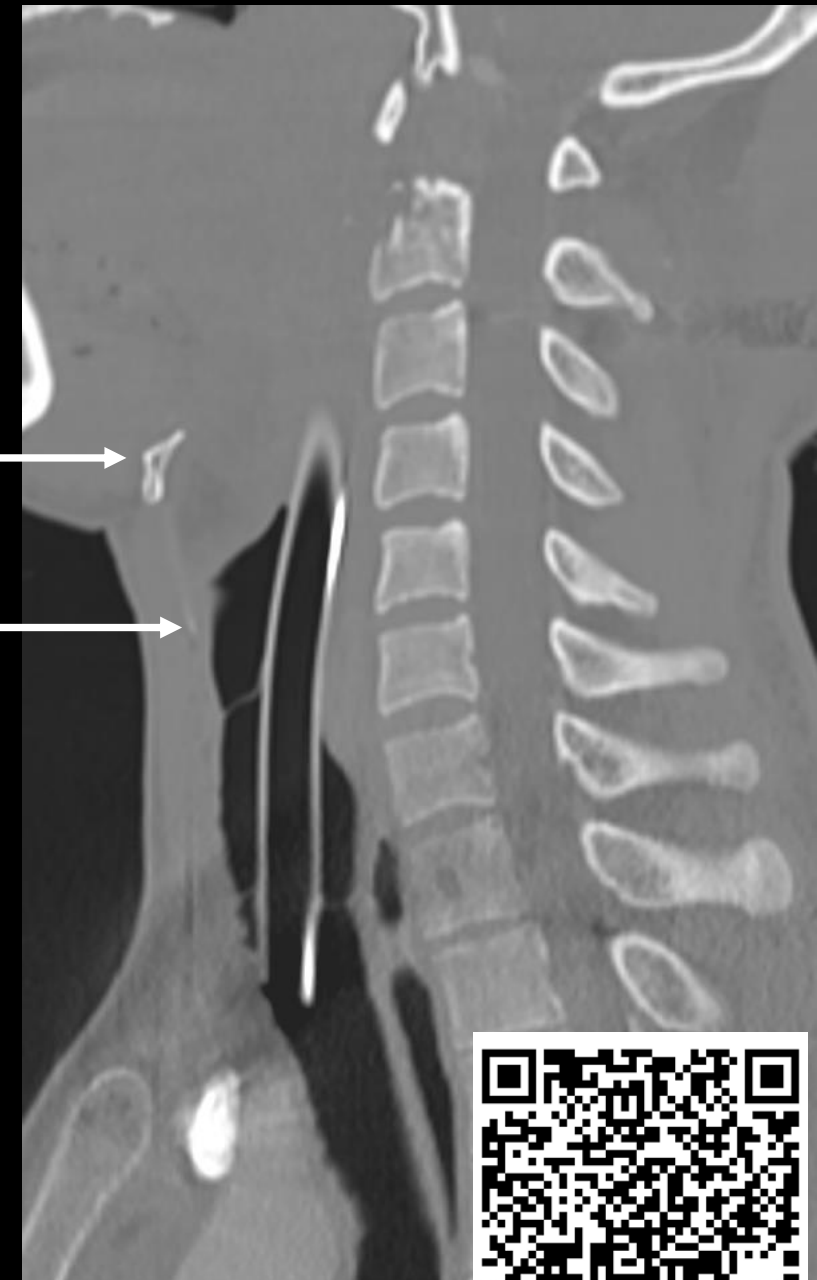
Cuff symmetrical

Cuff diameter < 2.8cm



Anaesthetist: 'I am looking for cuff to be at Cricoid level – below thyroid cartilage'

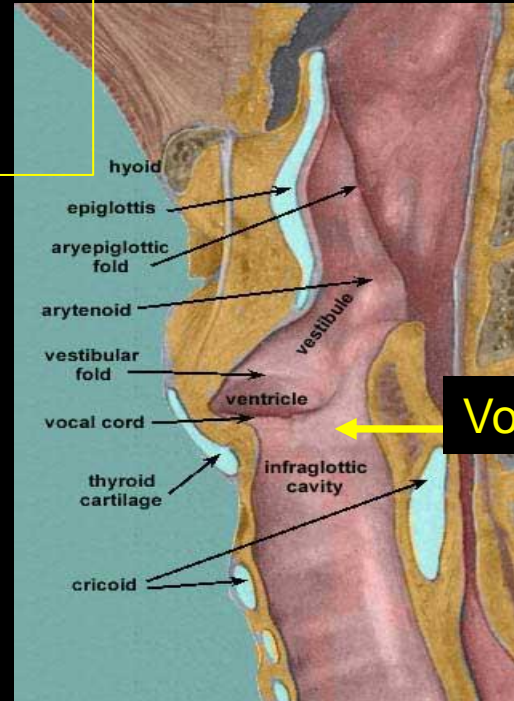
Hyoid →
Thyroid →
Cricoid



pollEv.com/edick900

AIRWAY CHECKLIST

- ETT in airway?
- ETT tip >5cm above the carina
- Cuff below vocal cords
- Cuff symmetrical
- Cuff diameter < 2.8cm



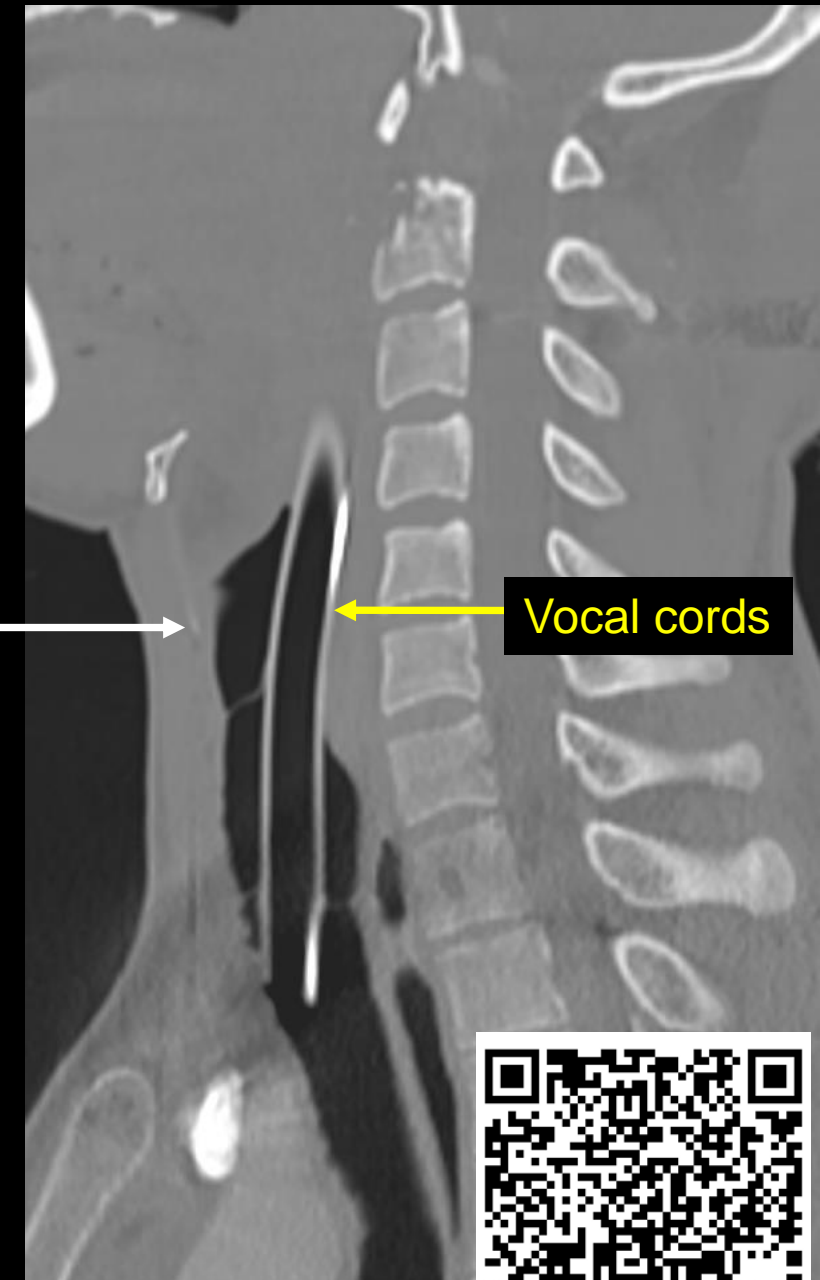
Vocal cords

Anaesthetist: 'I am looking for cuff to be at Cricoid level – below thyroid cartilage'

Hyoid

Thyroid

Cricoid



Vocal cords

Vocal cords at midpoint of thyroid cartilage



pollEv.com/edick900

AIRWAY CHECKLIST

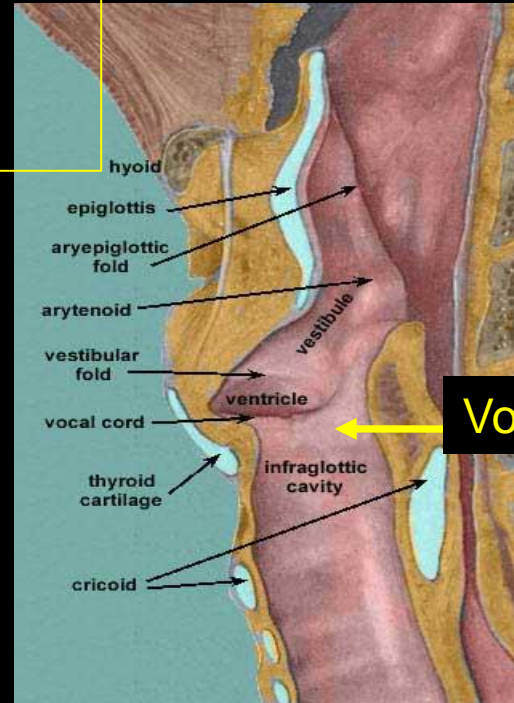
ETT in airway?

ETT tip >5cm above the carina

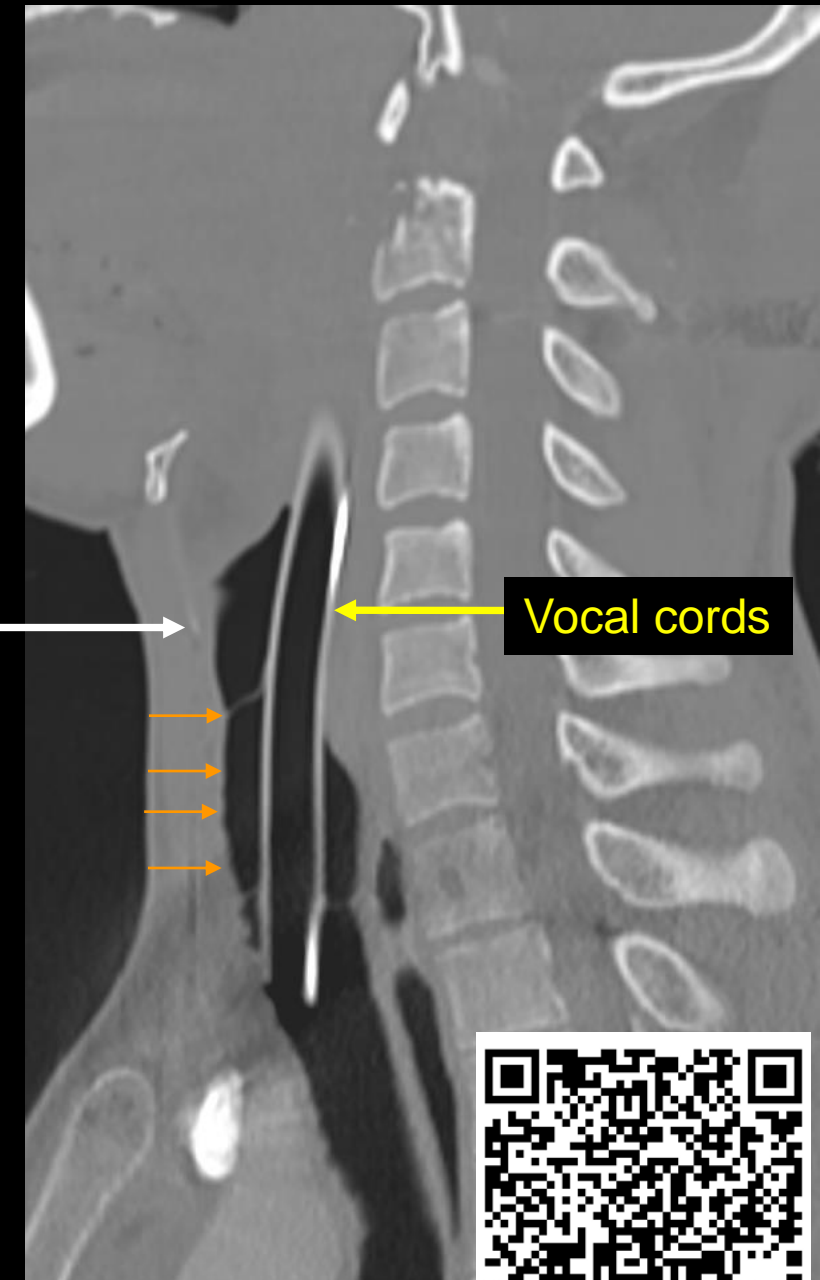
Cuff below vocal cords

Cuff symmetrical

Cuff diameter < 2.8cm



Vocal cords



Hyoid

Thyroid

Cricoid

Vocal cords

Anaesthetist: 'I am looking for cuff to be at Cricoid level – below thyroid cartilage'

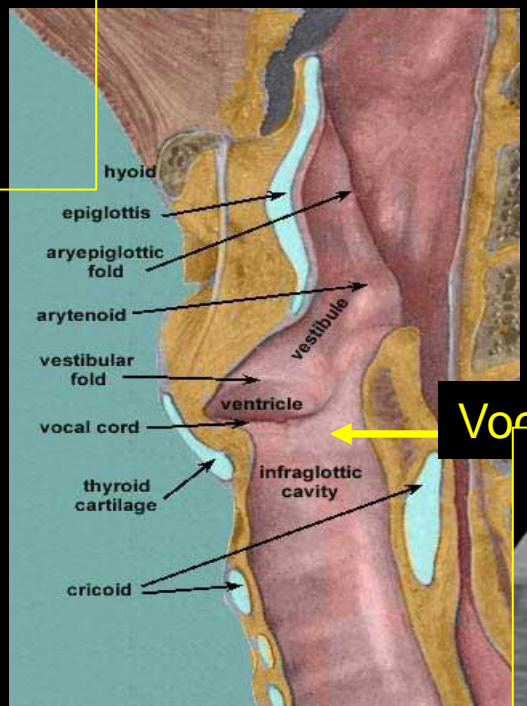
Cuff below the vocal cords

pollEv.com/edick900

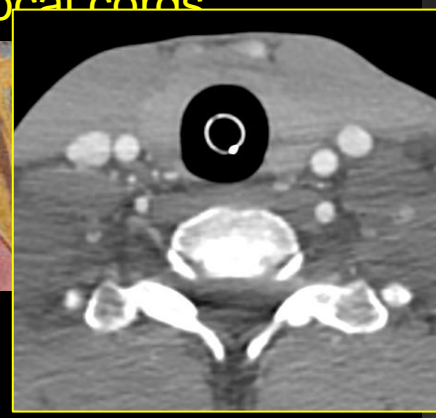


AIRWAY CHECKLIST

- ETT in airway?
- ETT tip >5cm above the carina
- Cuff below vocal cords
- Cuff symmetrical
- Cuff diameter <2.8cm



Vocal cords



Hyoid

Thyroid

Vocal cords

Cuff contour symmetrical, <2.8cm diameter

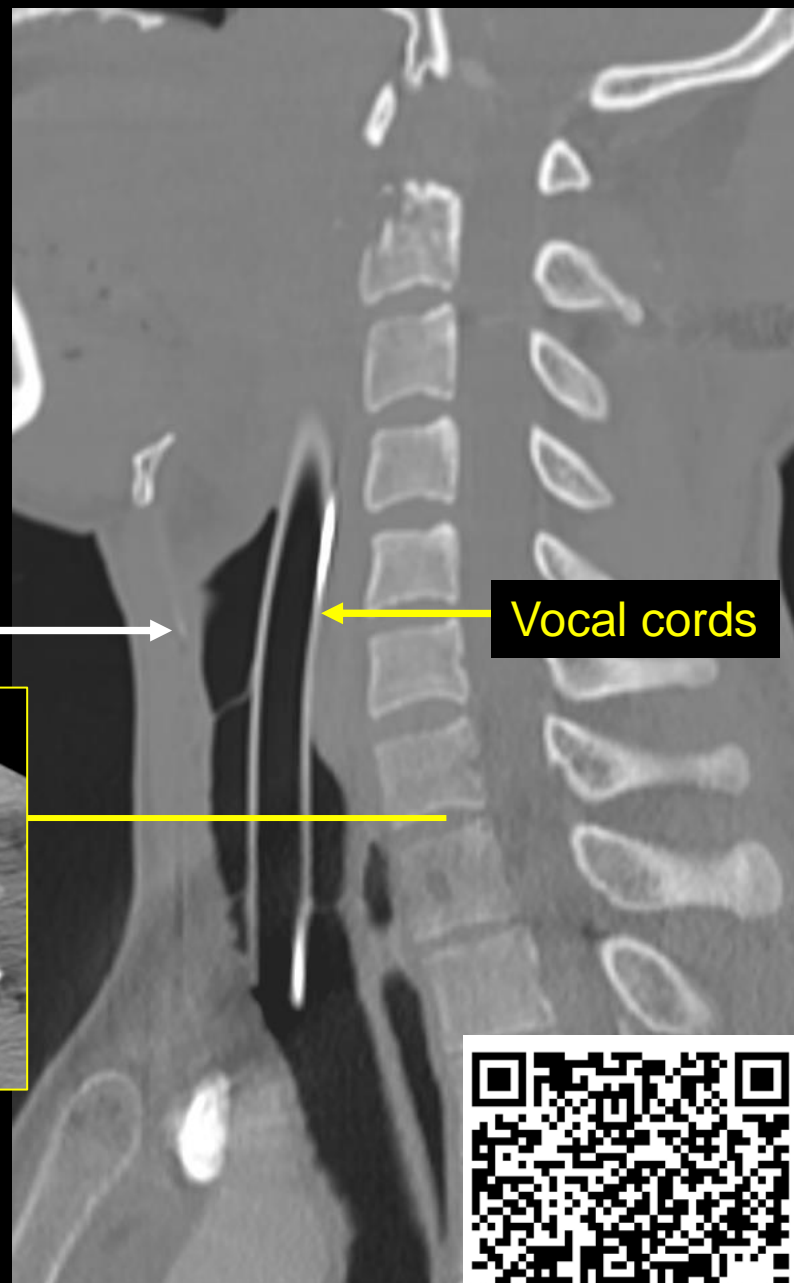
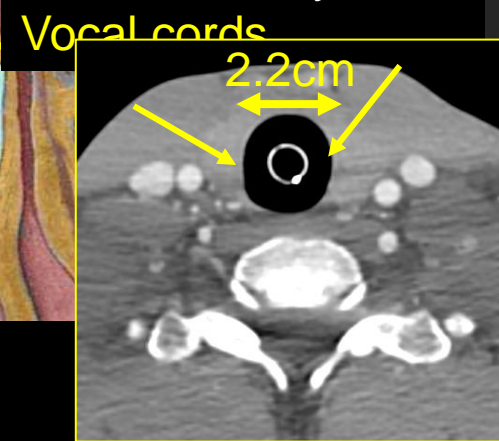
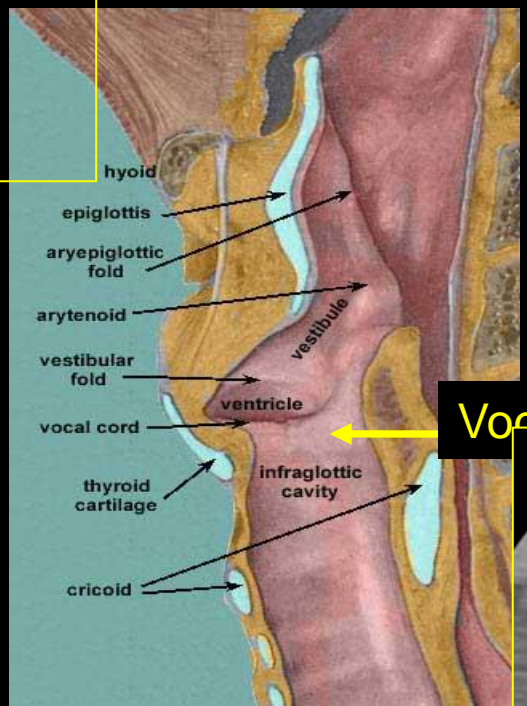
pollEv.com/edick900



AIRWAY CHECKLIST

- ETT in airway?
- ETT tip >5cm above the carina
- Cuff below vocal cords

- Cuff symmetrical
- Cuff diameter <2.8cm



Cuff contour symmetrical, <2.8cm diameter

pollEv.com/edick900



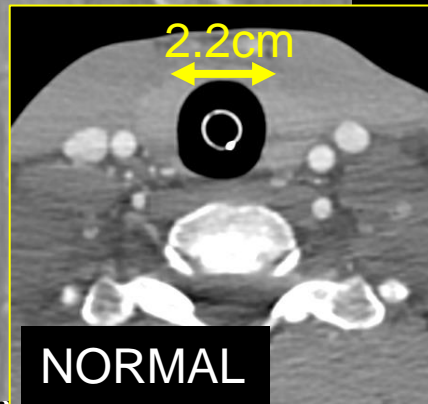
NORMAL

AIRWAY CHECKLIST

- ETT in airway?
- ETT tip >5cm above the carina
- Cuff below vocal cords
- Cuff symmetrical
- Cuff diameter <2.8cm

DIFFICULT INTUBATION

Hyoid
Thyroid
Cricoid



NORMAL

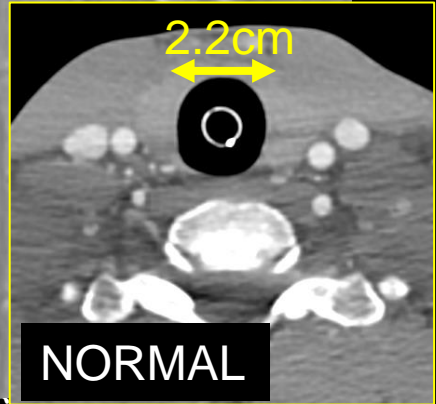
AIRWAY CHECKLIST

- ETT in airway?
- ETT tip >5cm above the carina
- Cuff below vocal cords
- Cuff symmetrical
- Cuff diameter <2.8cm

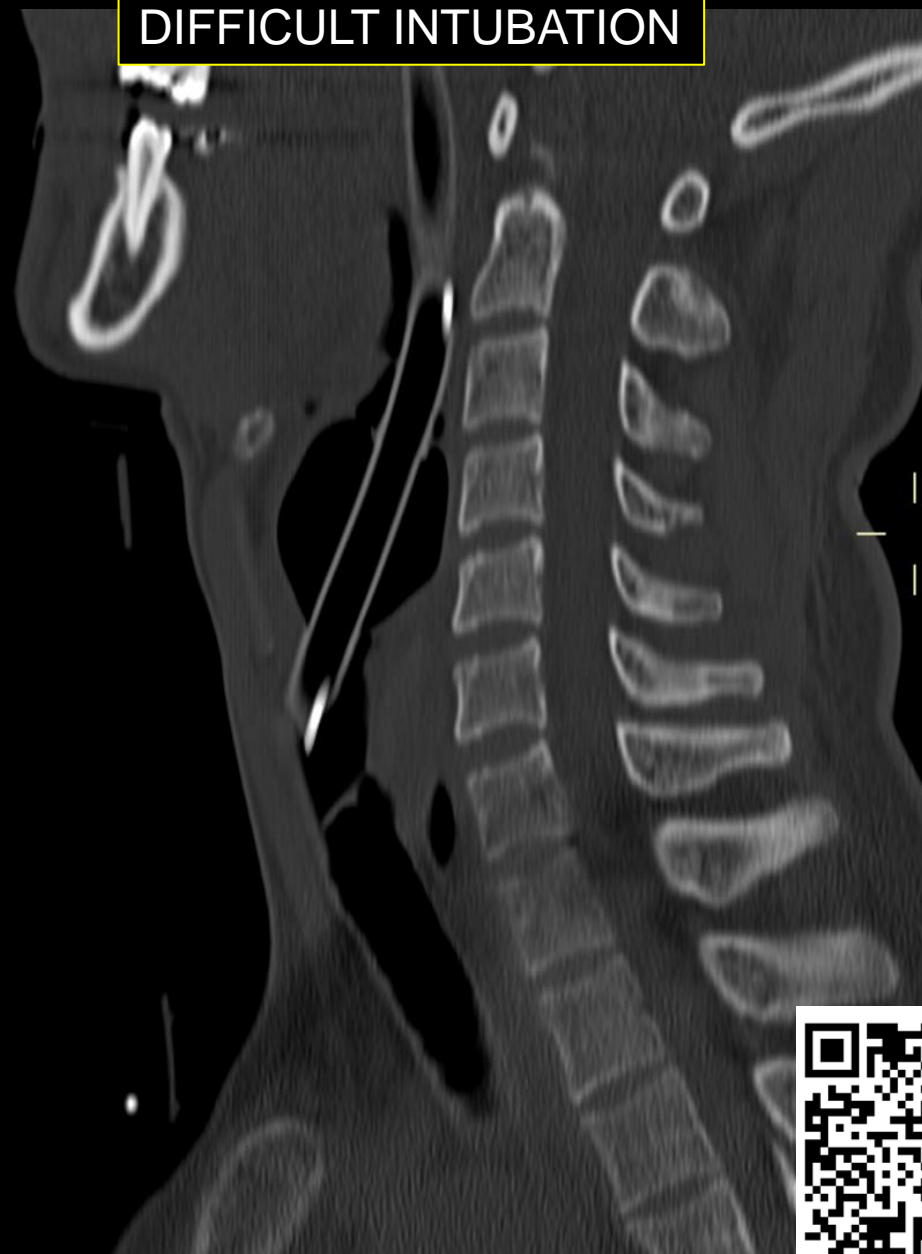
Hyoid

Thyroid

Cricoid



DIFFICULT INTUBATION



pollEv.com/edick900

NORMAL

AIRWAY CHECKLIST

- ETT in airway?
- ETT tip >5cm above the carina
- Cuff below vocal cords
- Cuff symmetrical
- Cuff diameter < 2.8cm

Hyoid

Thyroid

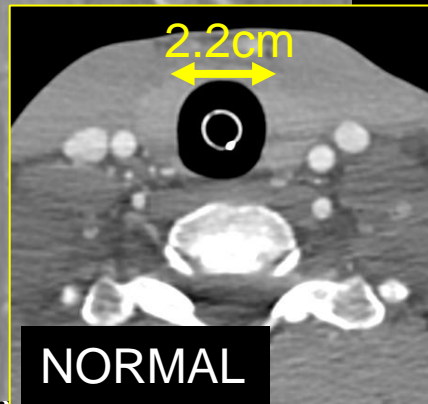
Cricoid

DIFFICULT INTUBATION

Hyoid

Thyroid

Cricoid

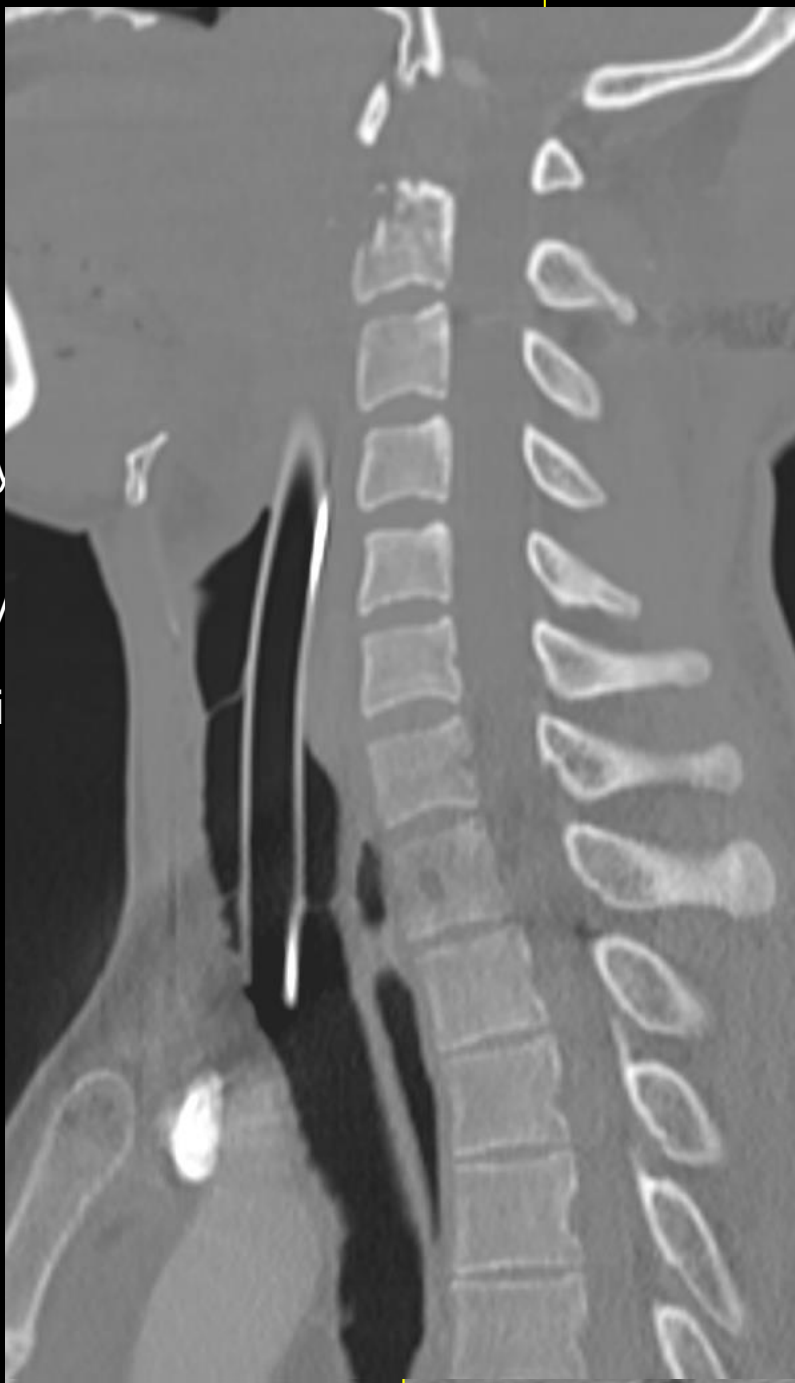

pollEv.com/edick900

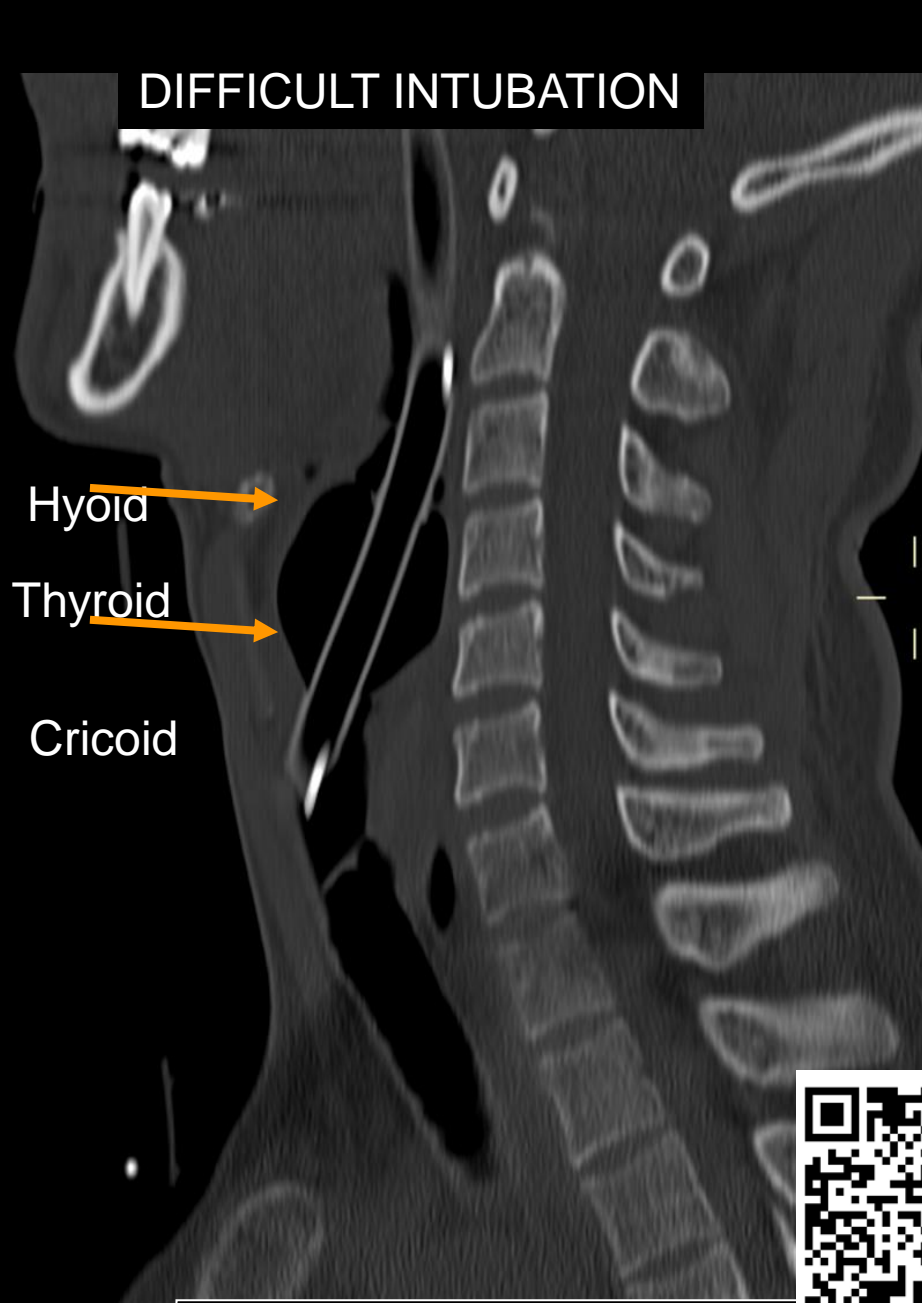
CHECKLIST

- way?
- 5cm above the carina
- v vocal cords
- metrical
- eter < 2.8cm

Hy
Thy
Cri



DIFFICULT INTUBATION



DIFFICULT INTUBAT pollEv.com/edick900



NORMAL

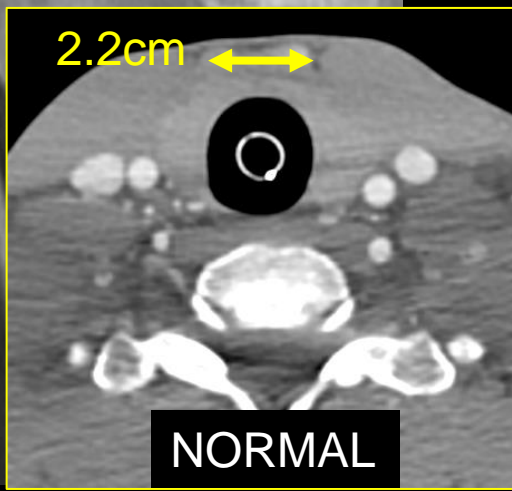
AIRWAY CHECKLIST

- ETT in airway?
- ETT tip >5cm above the carina
- Cuff below vocal cords
- Cuff symmetrical
- Cuff diameter <2.8cm

Hyoid

Thyroid

Cricoid



DIFFICULT INTUBATION

Hyoid

Thyroid

Cricoid

CUFF



DIFFICULT INTUBAT pollEv.com/edick900



NORMAL

AIRWAY CHECKLIST

- ETT in airway?
- ETT tip >5cm above the carina
- Cuff below vocal cords
- Cuff symmetrical
- Cuff diameter <2.8cm

Hyoid

Thyroid

Cricoid

DIFFICULT INTUBATION

Hyoid

Thyroid

Cricoid

CUFF

2.2cm

NORMAL

DIFFICULT INTUBAT

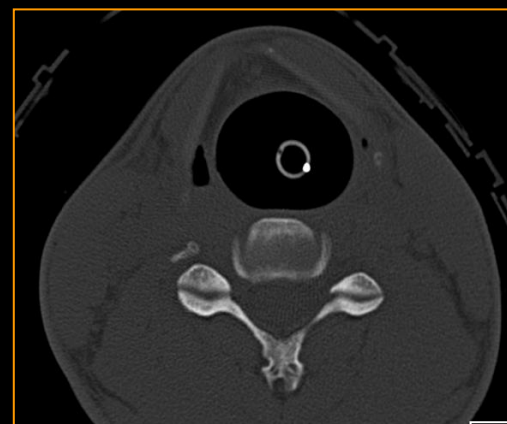
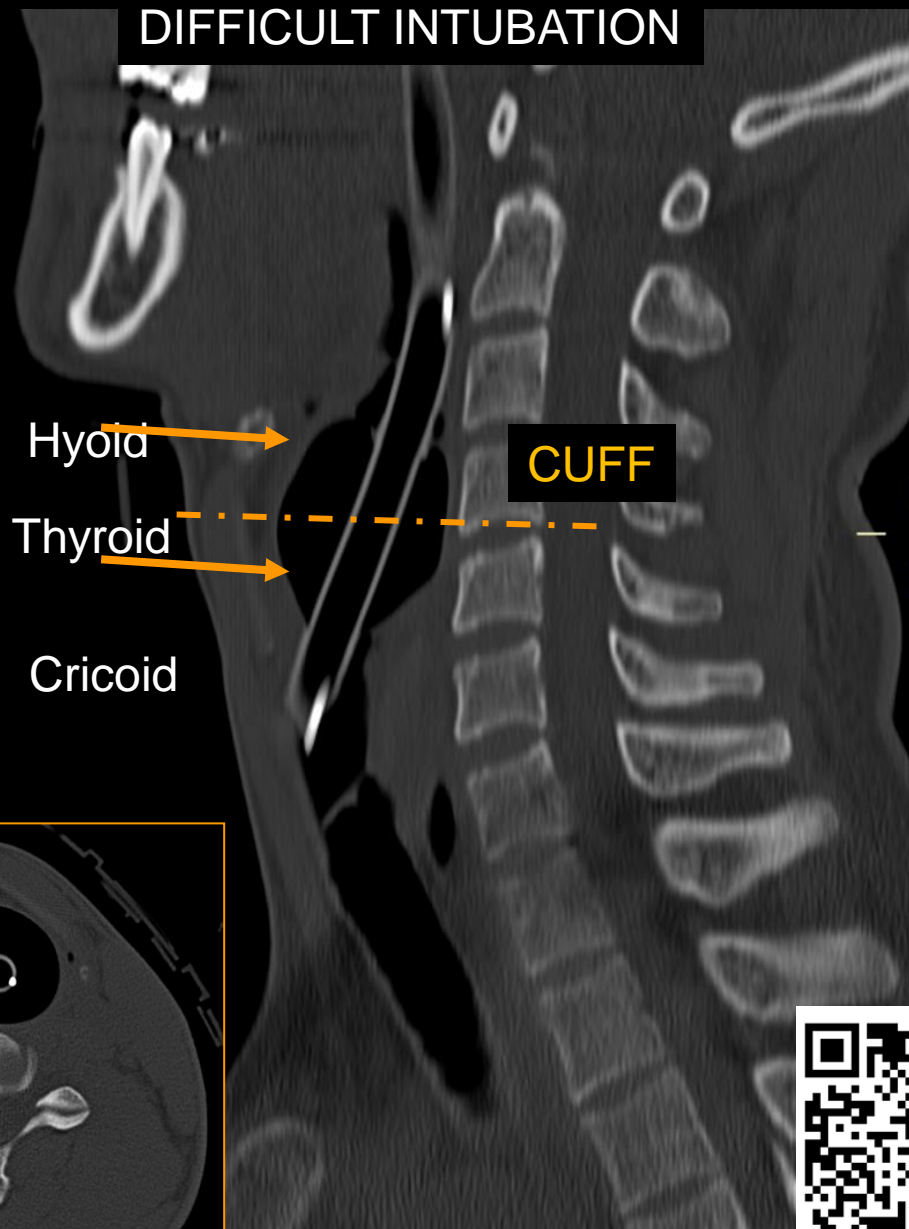
pollEv.com/edick900



Which of the following are true

Cuff below vocal cords

Cuff is not symmetrical



DIFFICULT INTUBAT

pollEv.com/edick900



Select all that are correct

(A) The Cuff lies below the vocal cords

0%

(B) The cuff is not symmetrical

0%

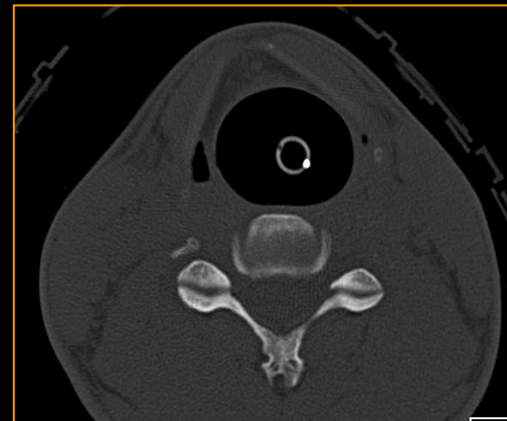
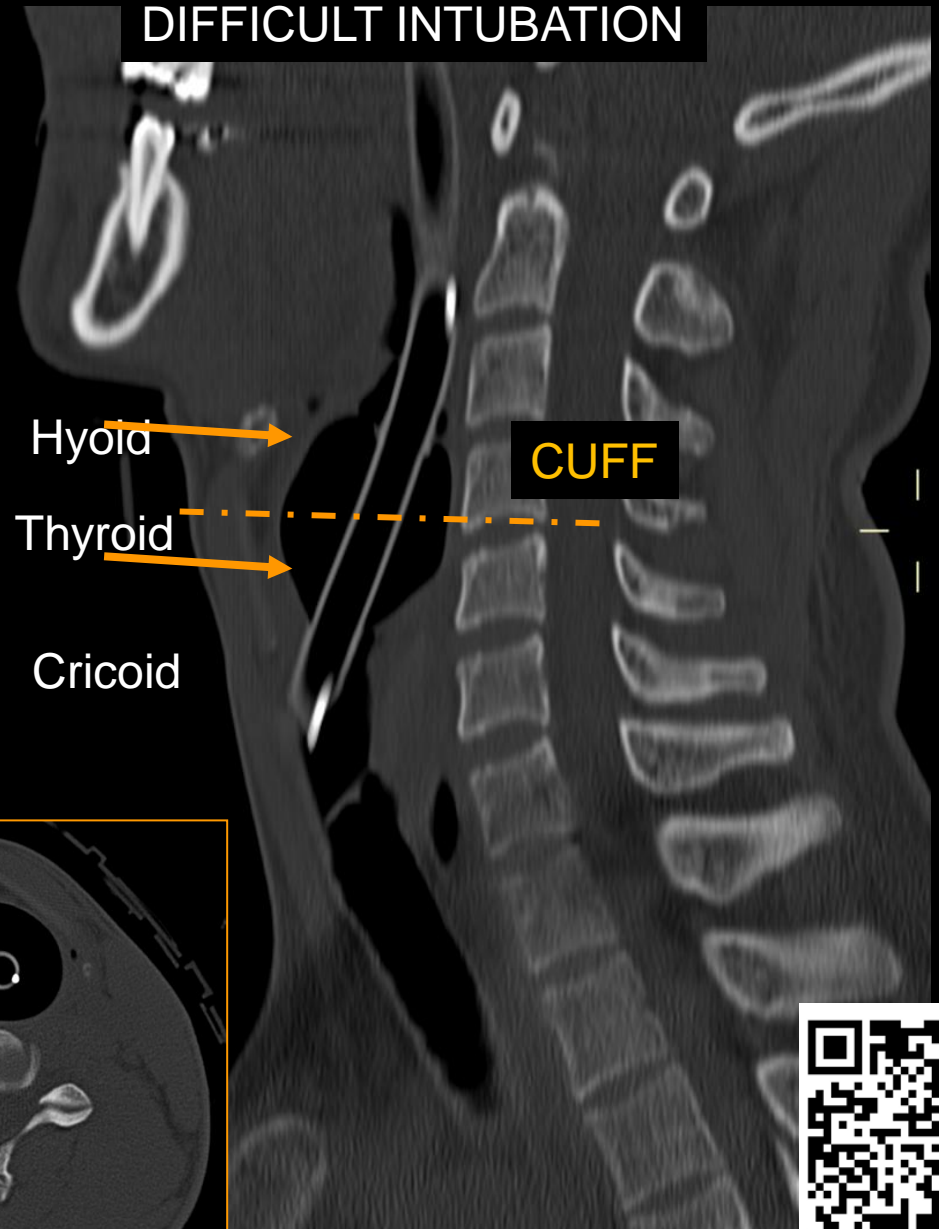
Which of the following are true

ETT in airway? TRUE

Cuff below vocal cords FALSE

Cuff symmetrical FALSE

Cuff diameter < 2.8cm FALSE



DIFFICULT INTUBAT

pollEv.com/edick900



NORMAL

Which of the following are true

ETT in airway? TRUE

Cuff below vocal cords FALSE

Cuff symmetrical FALSE

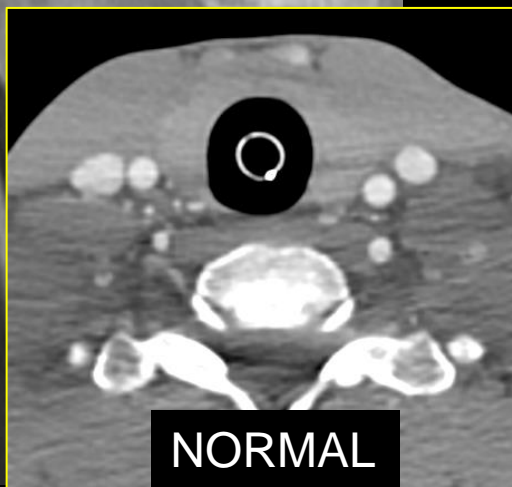
Cuff diameter < 2.8cm FALSE

Hyoid

Thyroid

Cricoid

CUFF



DIFFICULT INTUBATION

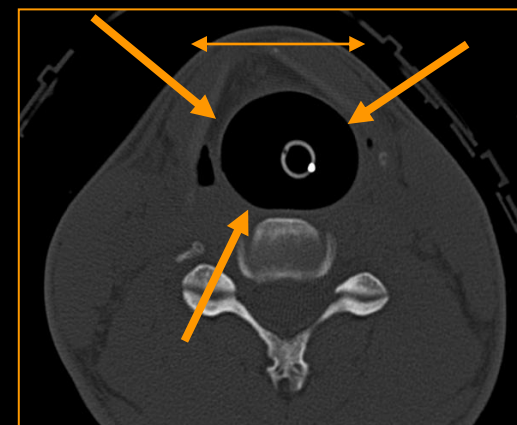
Hyoid

Thyroid

Cricoid

CUFF ABOVE CRICOID ie AT OR ABOVE VOCAL CORDS

>2.8cm



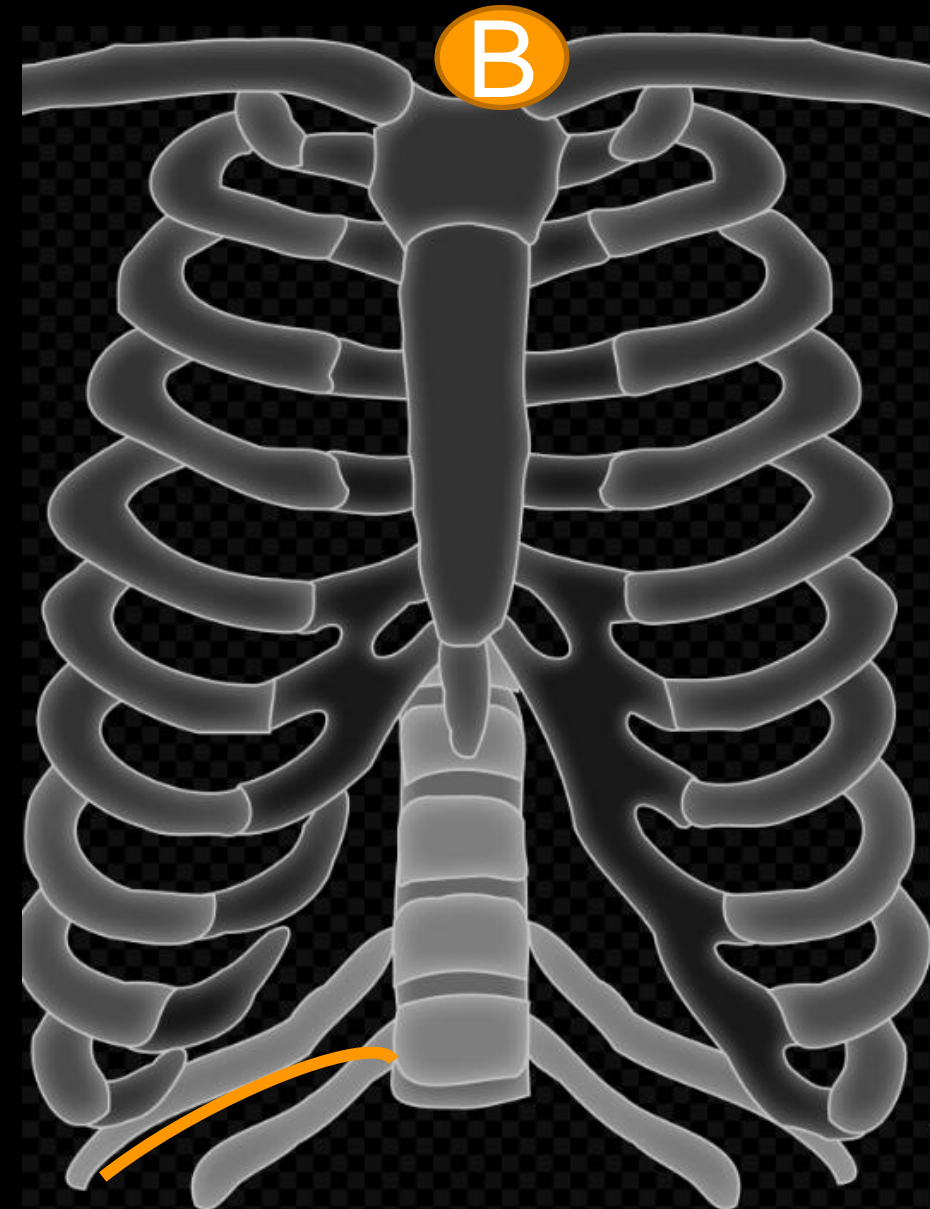
BREATHING

A airway

B breathing

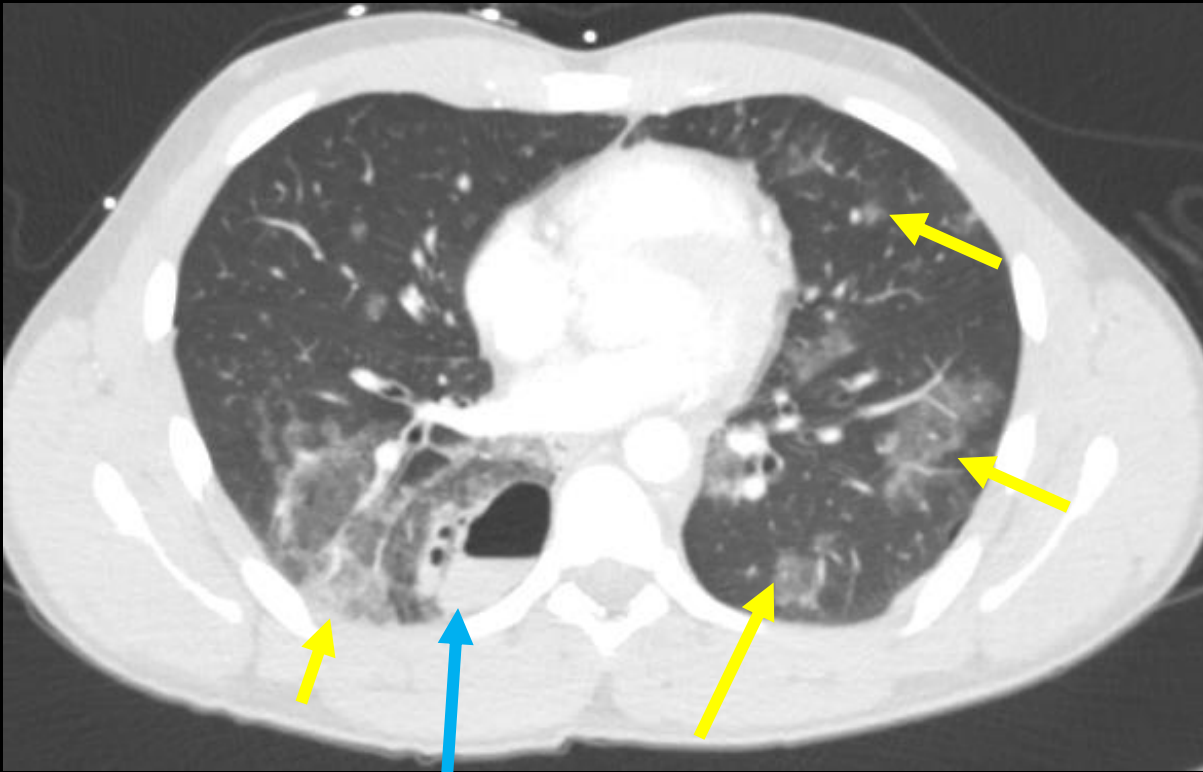
C circulation, chest wall,
costal cartilage

(3)D diaphragm, disability



Lung Injury

Day 0



Contusion =
ground glass
shadowing

Haematopneumatocele

Lung Injury

Day 0

LEARNING POINT: See contusion or laceration?
Look for associated rib fractures

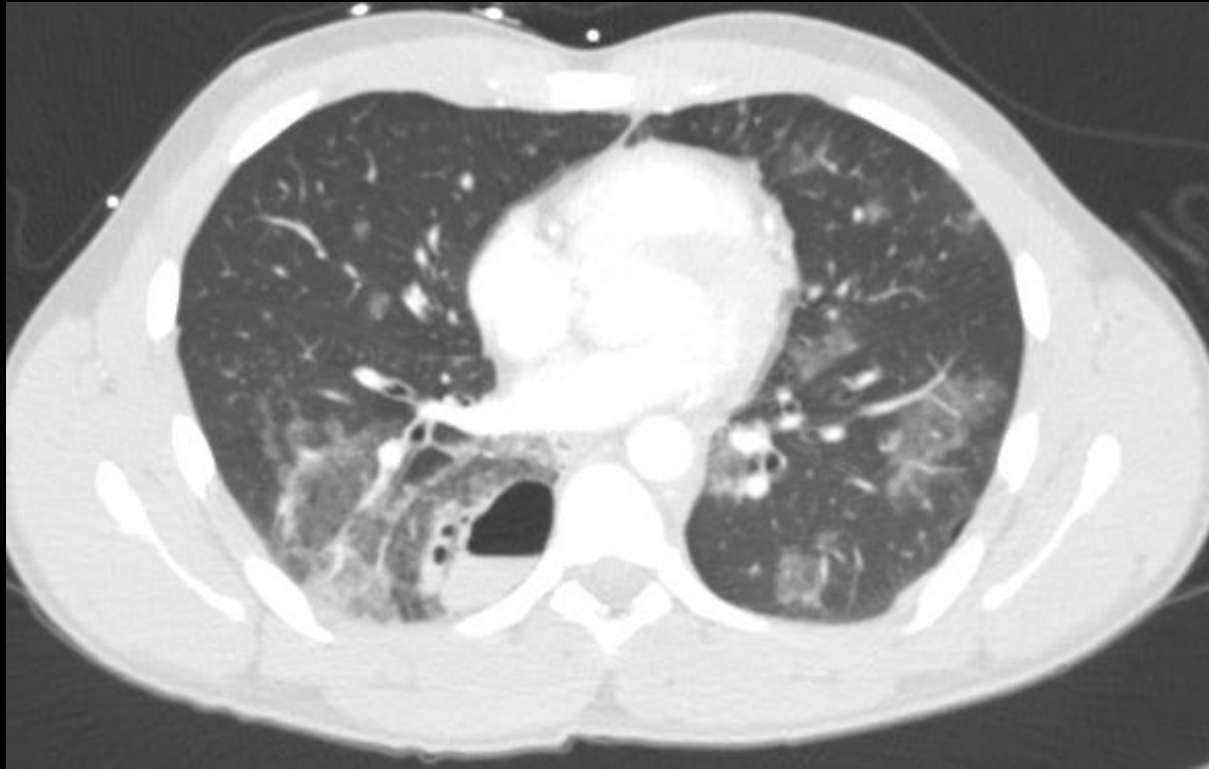

Haematopneumatocele

Contusion =
ground glass
shadowing

Lung Injury

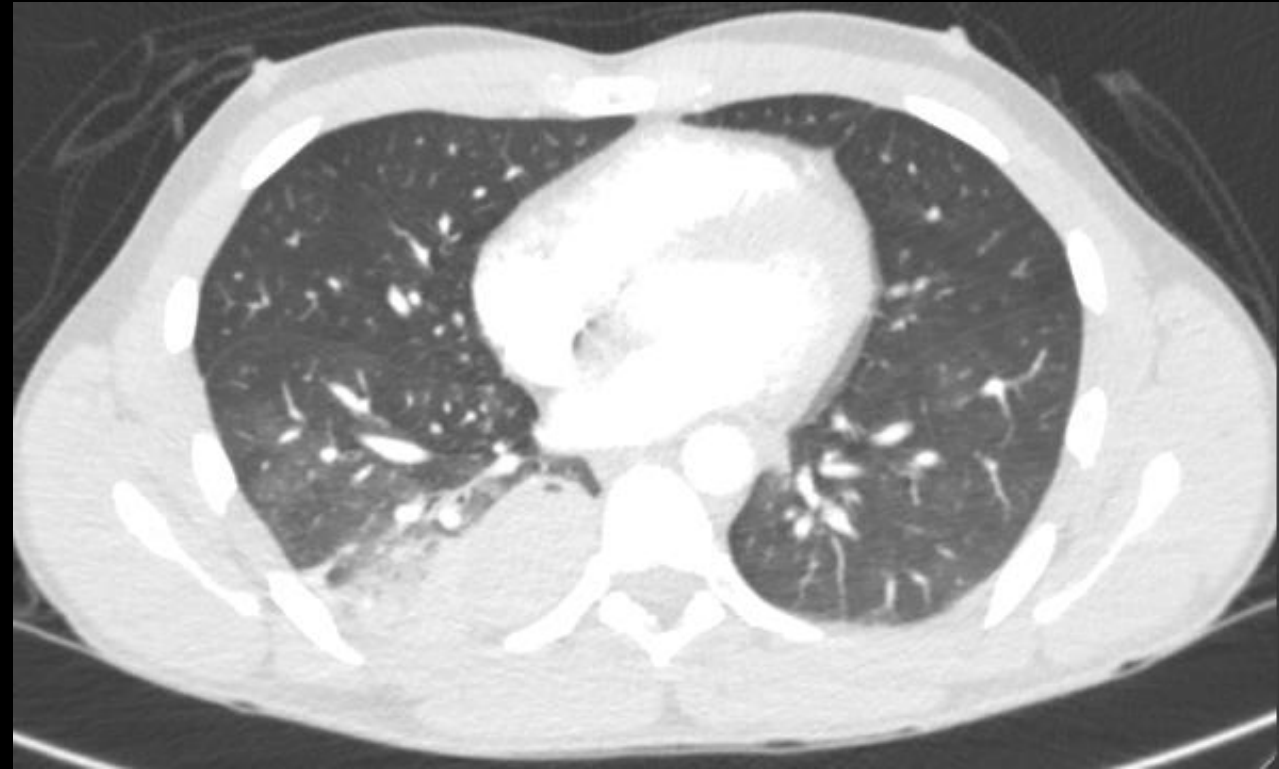Day 0



Contusion

Haematopneumatocele

Day 7



Haematopneumatocele

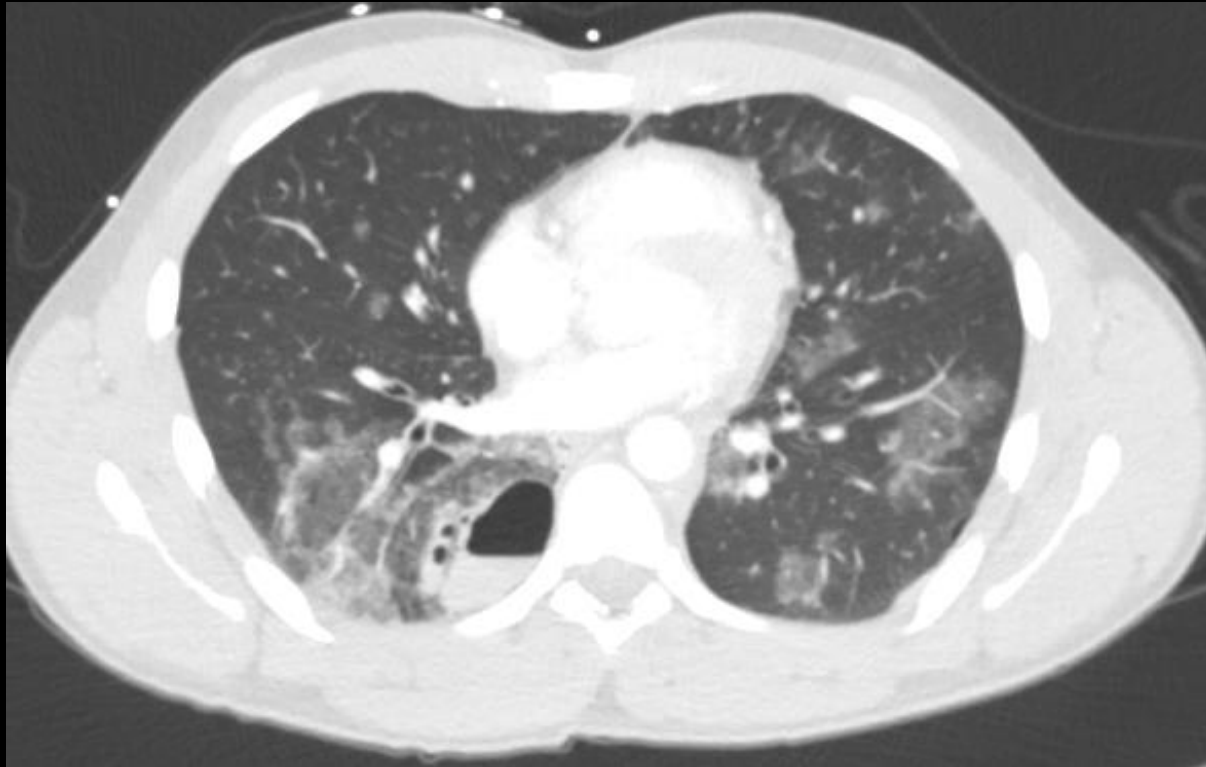How does lung injury evolve?

Time to resolve

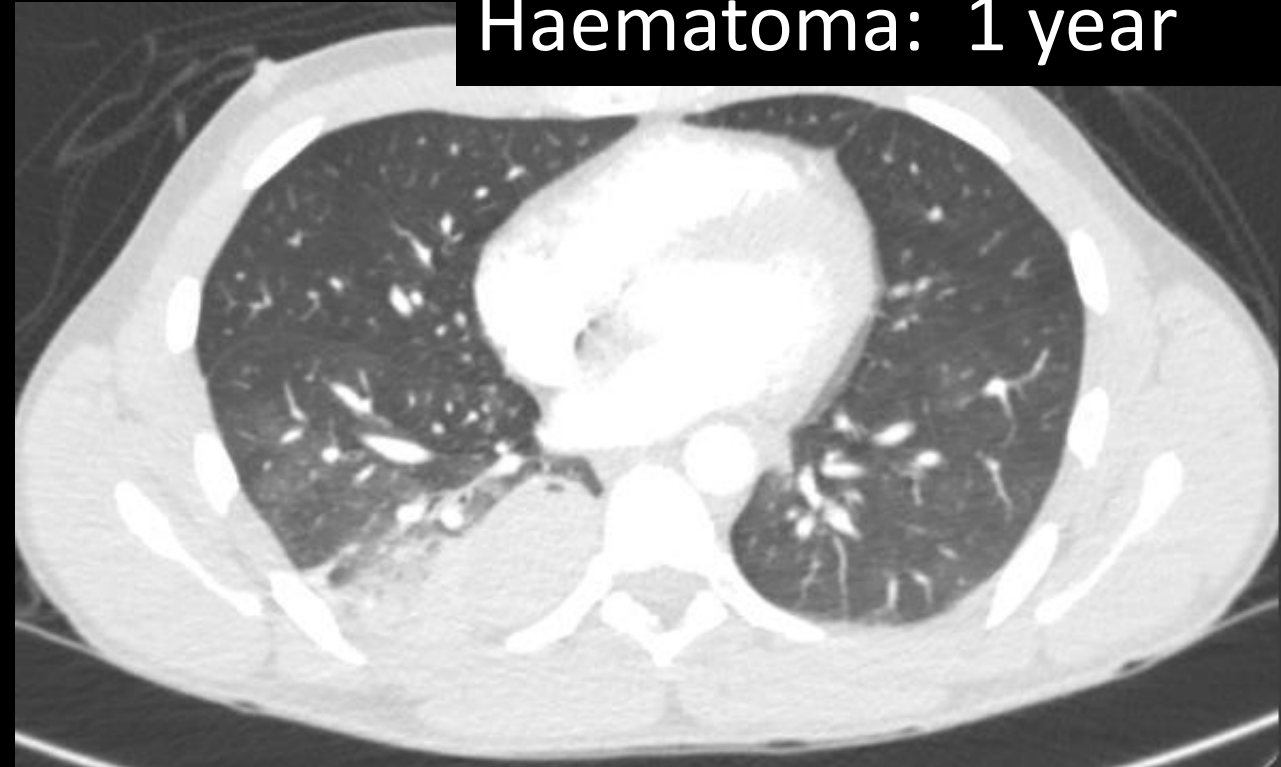Day 0

Day 7

Contusion: 2 weeks
Laceration: 1 year
Haematoma: 1 year



Contusion
Haematopneumatocele



Haematopneumatocele

Time to resolve

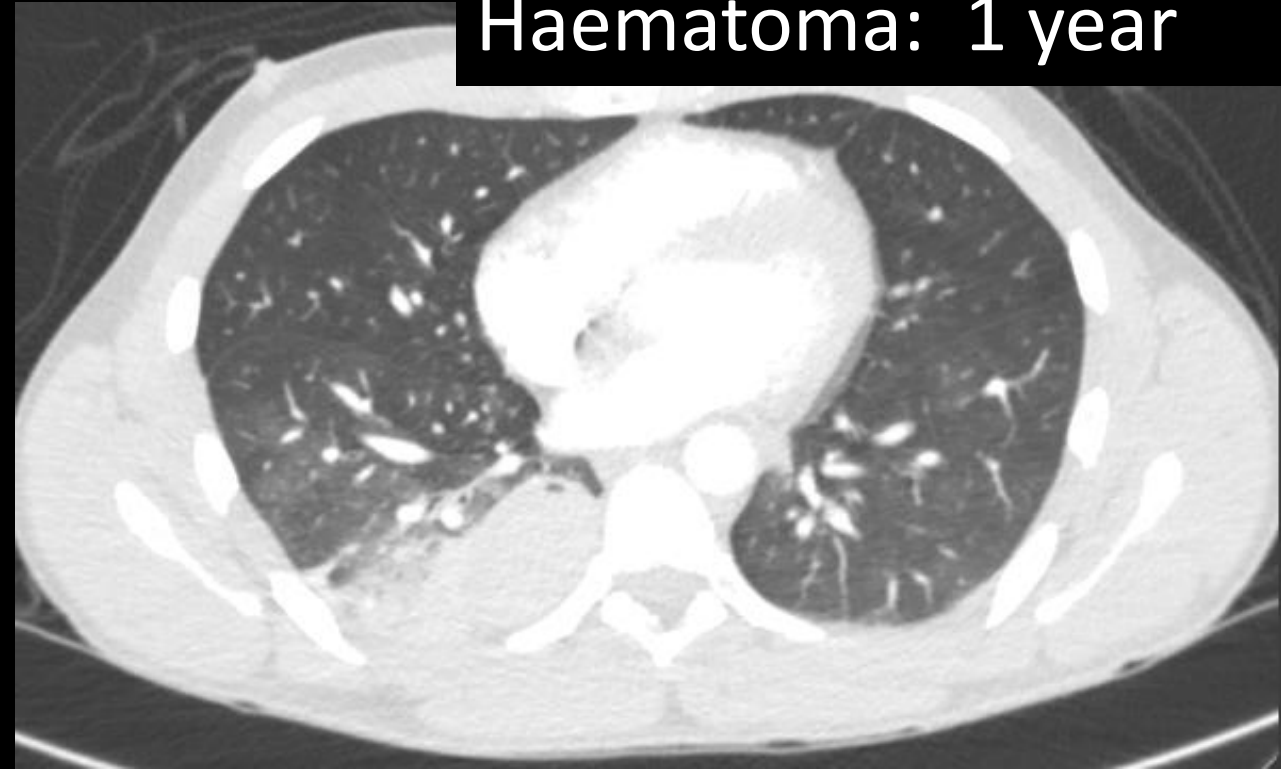
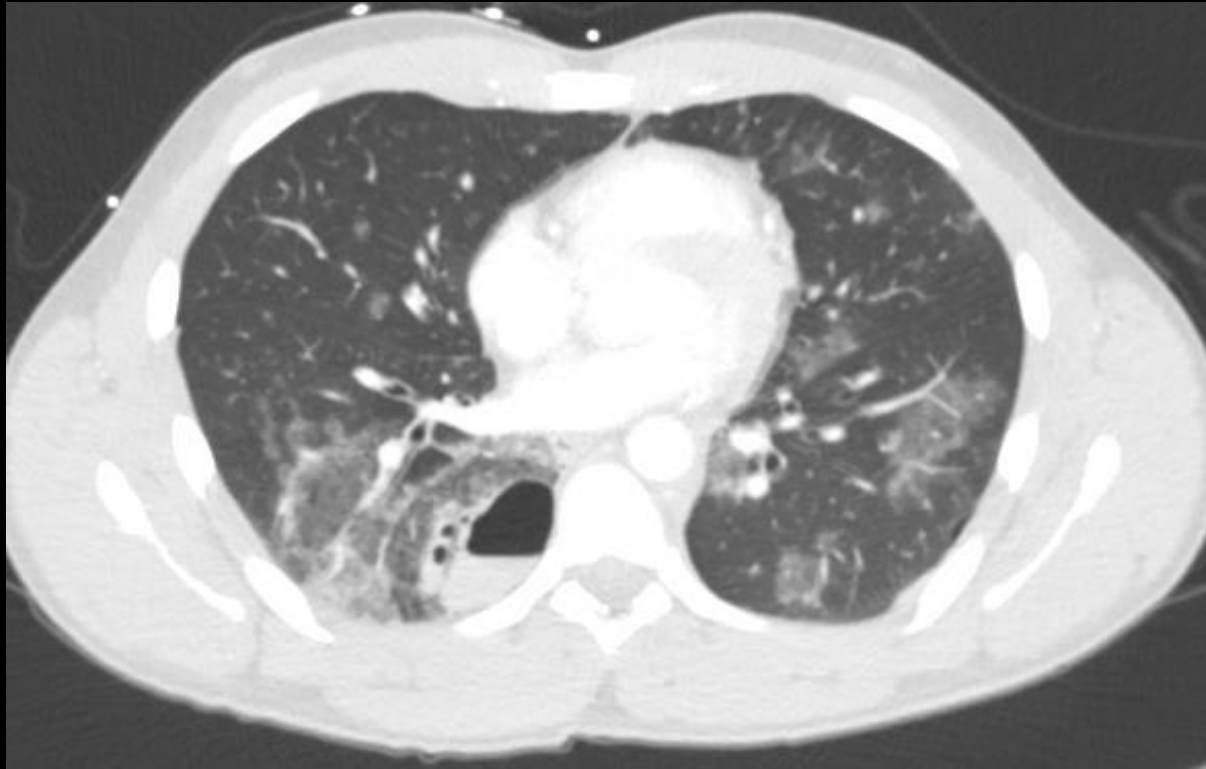Day 0

Day 7

Contusion: 2 weeks

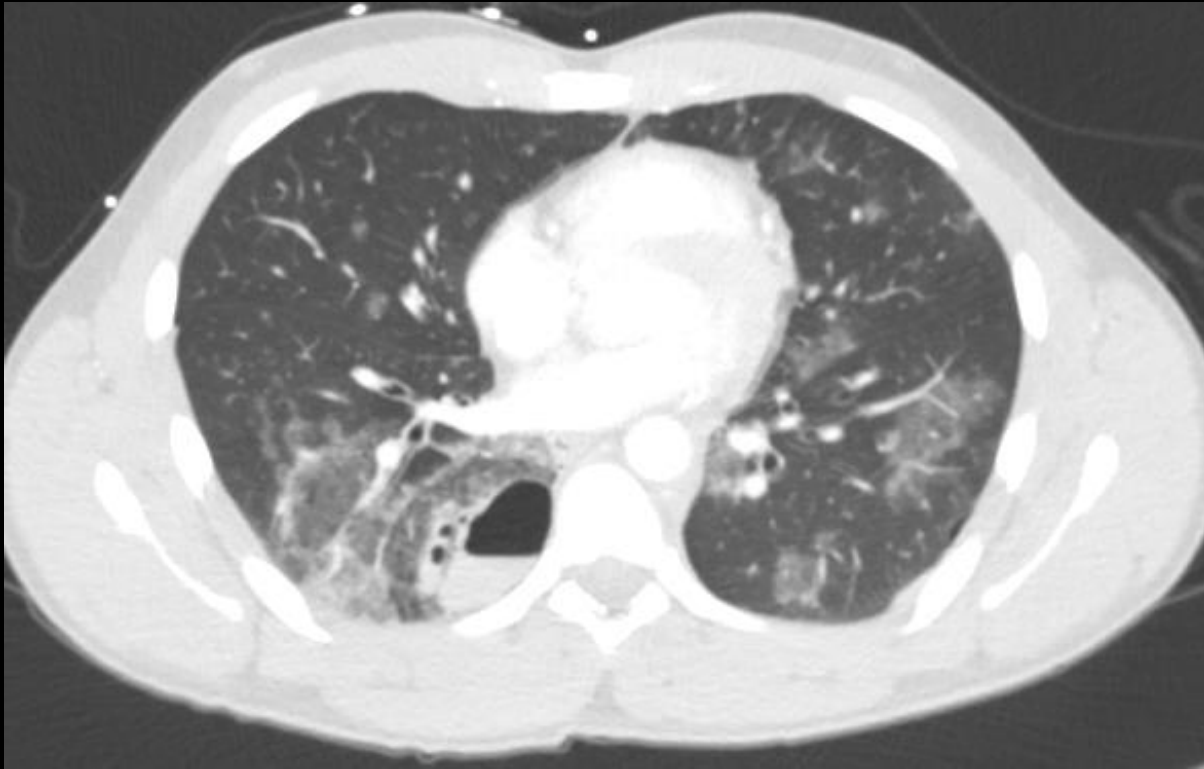Laceration: 1 year

Haematoma: 1 year

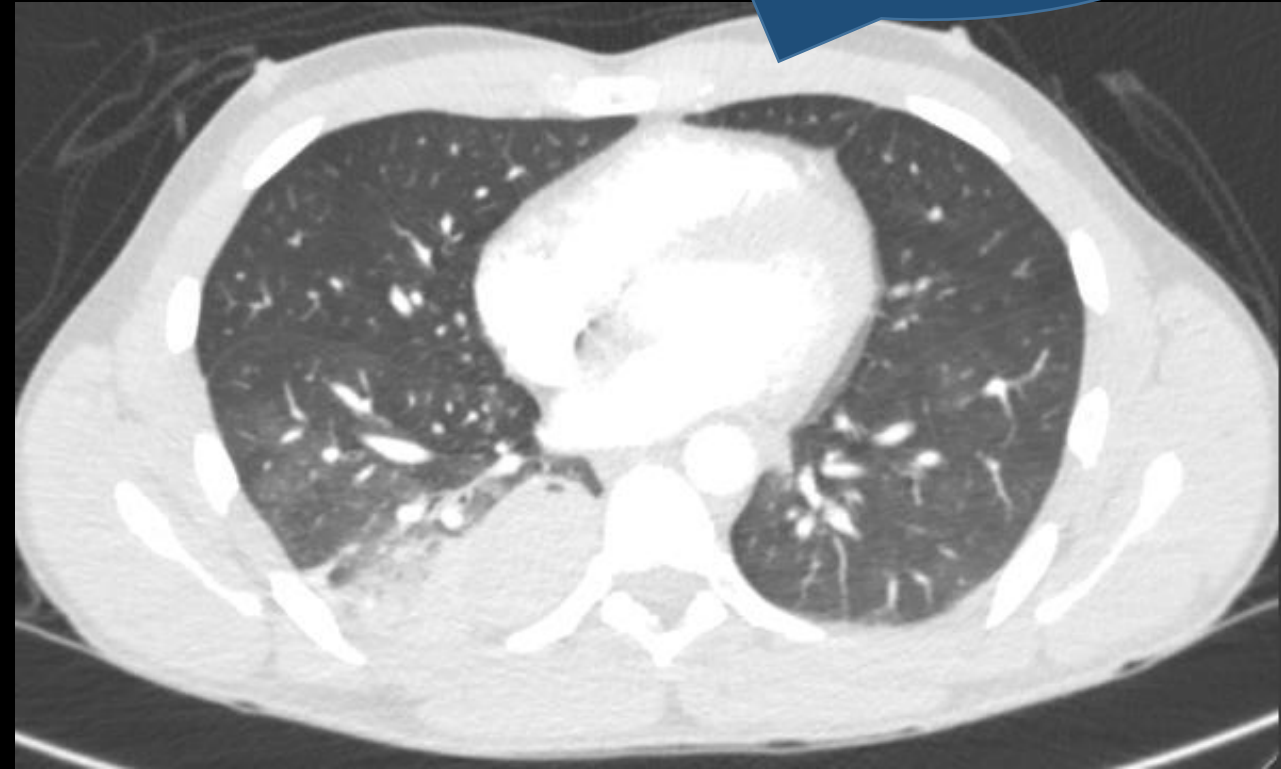

LEARNING POINT: Ground glass shadowing resolves quickly
haemopneumatoceles mature and change

Day 0



Day 7

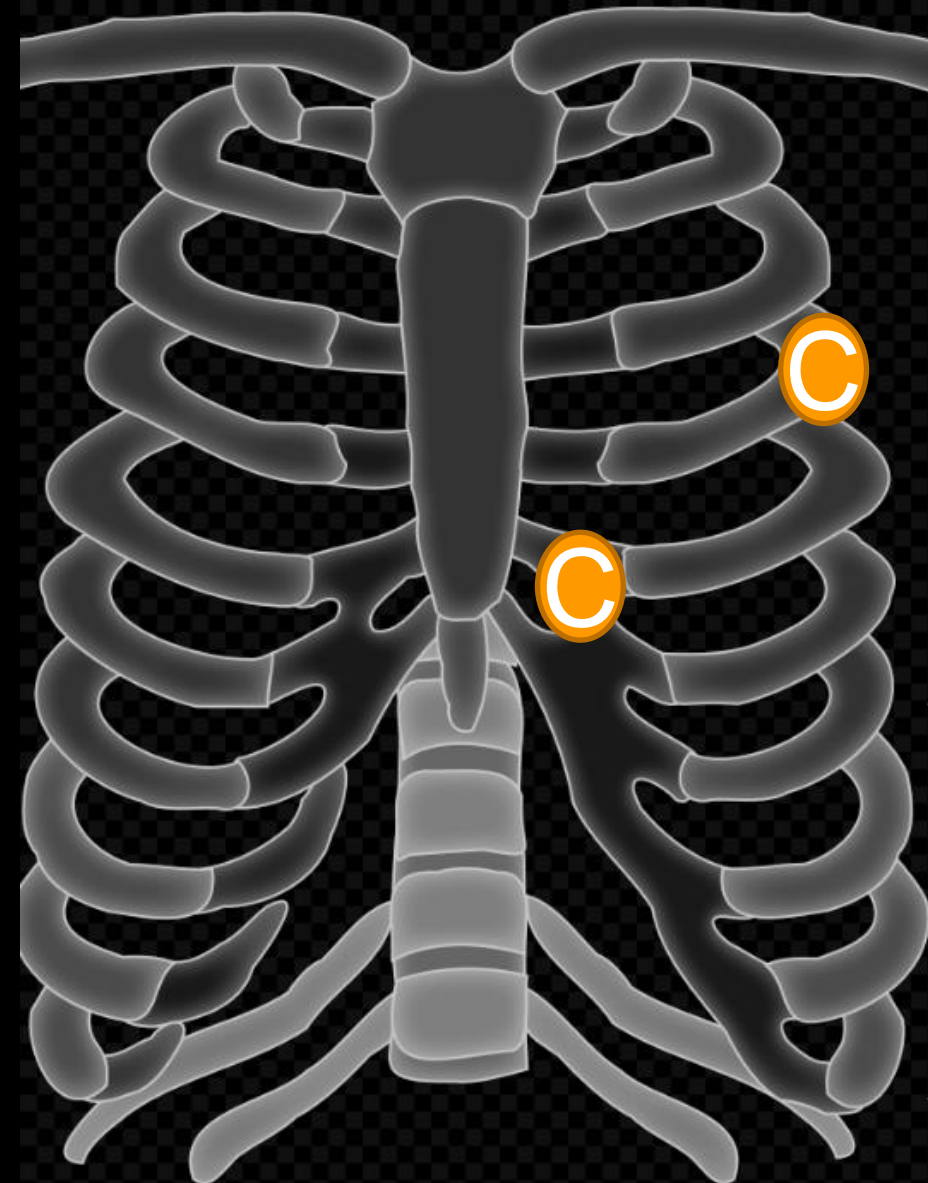


Radiologist can add value: recognise maturing pneumatoceles

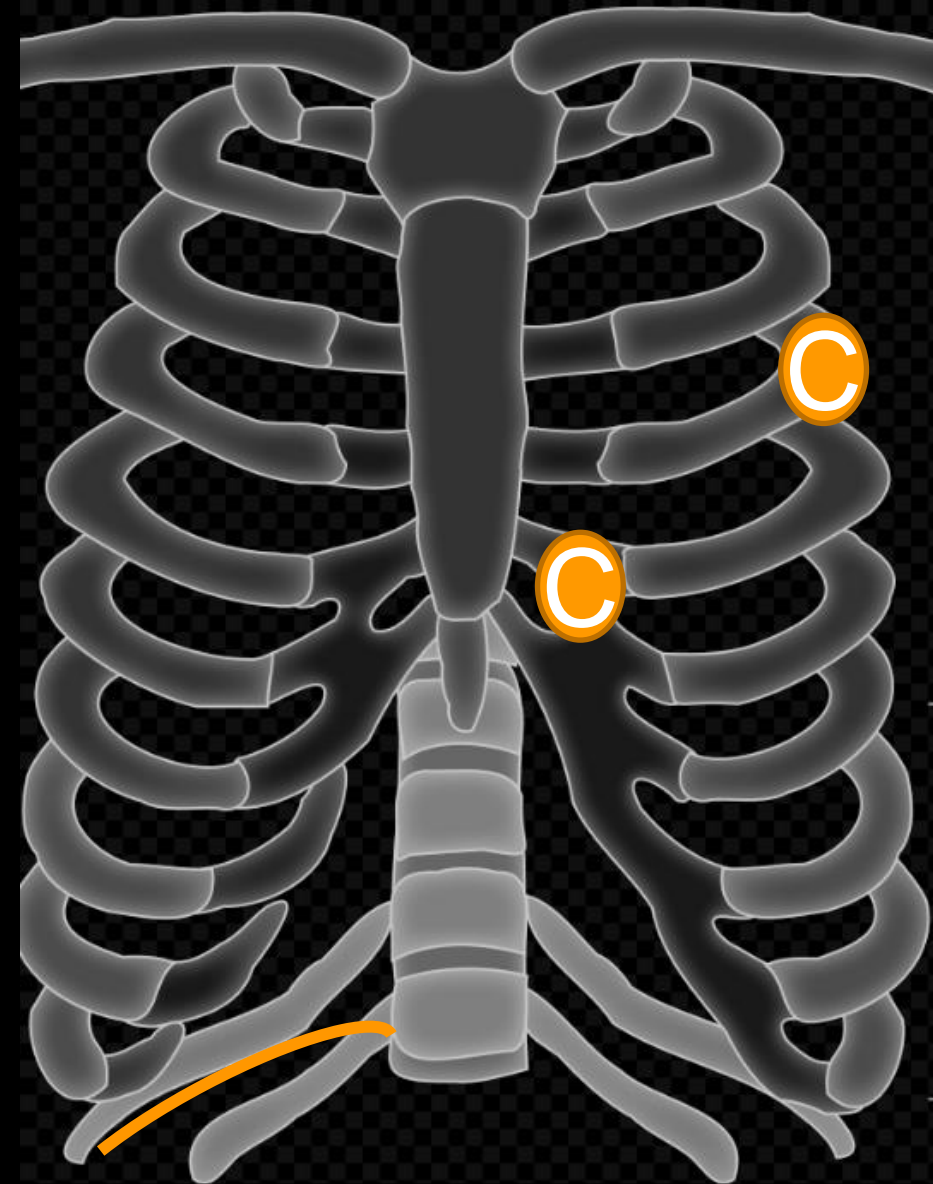
LEARNING POINT: Ground glass shadowing resolves quickly
haemopneumatoceles mature and change

CIRCULATION

- A airway
- B breathing
- C **Circulation** chest wall, costal cartilage
- (3)D diaphragm, disability



CIRCULATION



Learning Points

Key Radiology
task: identifying
active bleeding

- Identify active bleeding first
- Interrogate chest wall vessels systematically
 - Aorta and great vessels
 - Subclavian/Axillary
 - Internal mammary
 - intercostal

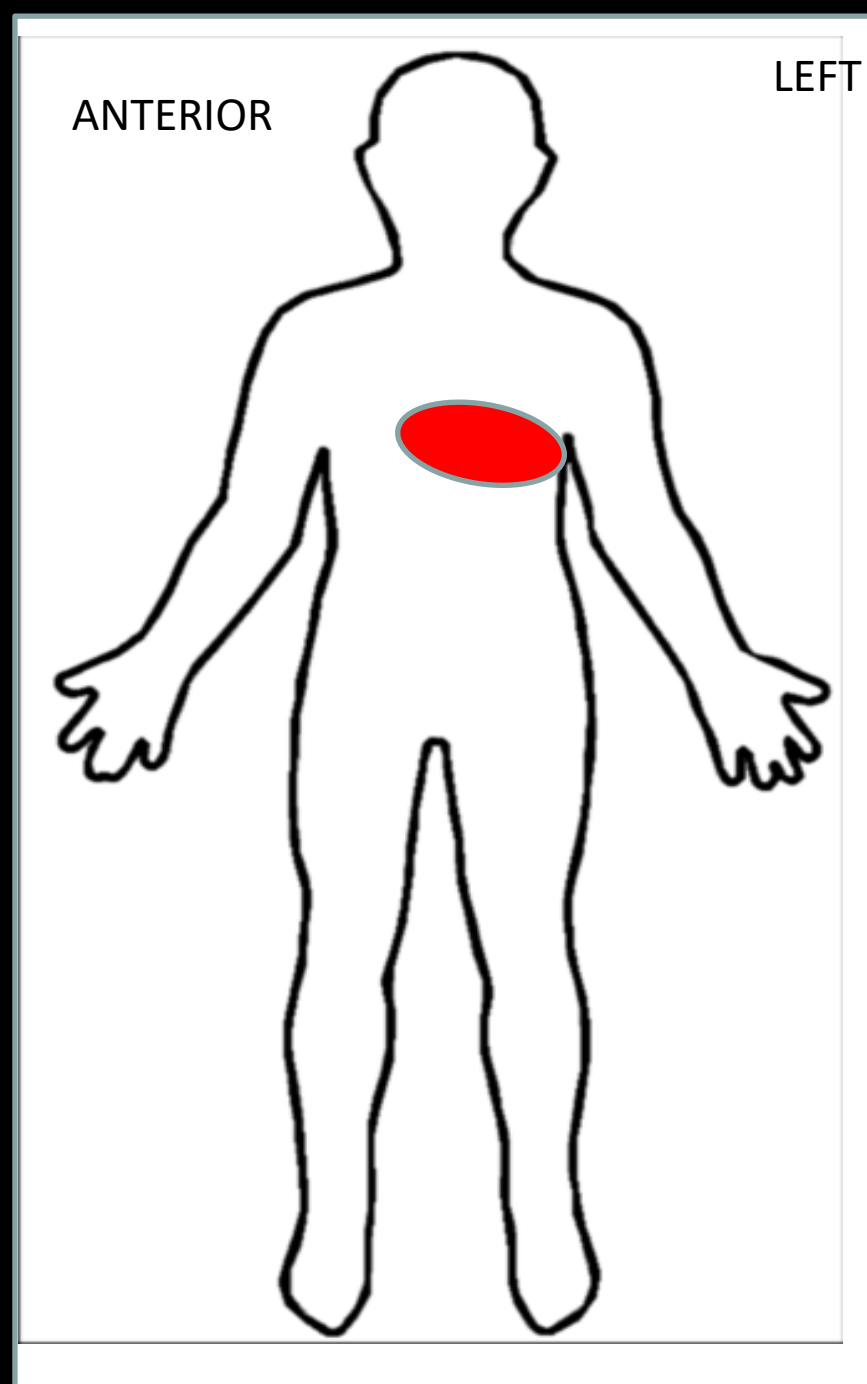
Learning Points

Key Radiology
task: identifying
active bleeding

- Identify active bleeding first
- Interrogate chest wall vessels systematically
 - ~~• Aorta and great vessels~~
 - Subclavian/Axillary
 - Internal mammary
 - intercostal

CIRCULATION CASE #1

1x Penetrating Wound left Chest
ACTIVE BLEEDING INTERNAL
MAMMARY A

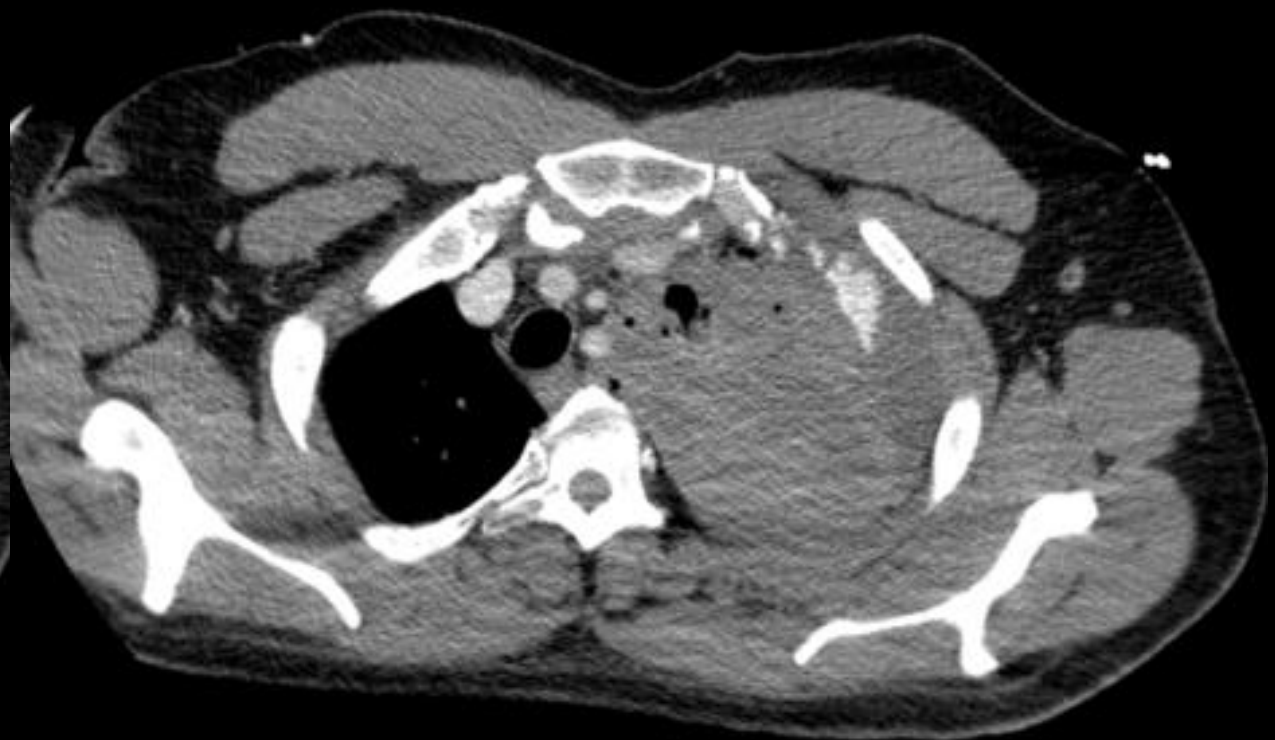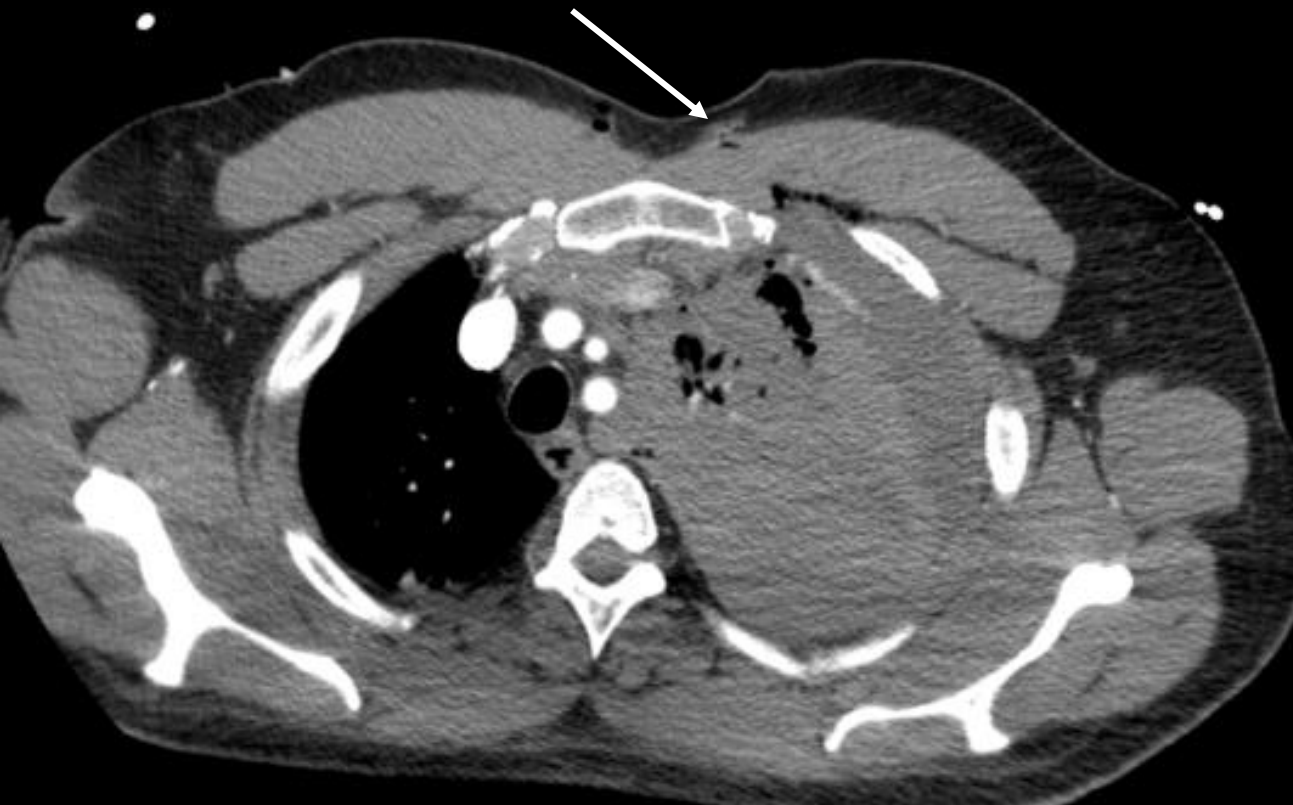


ACTIVE BLEEDING LEFT INTERNAL MAMMARY ARTERY

Entry wound

Arterial

Venous


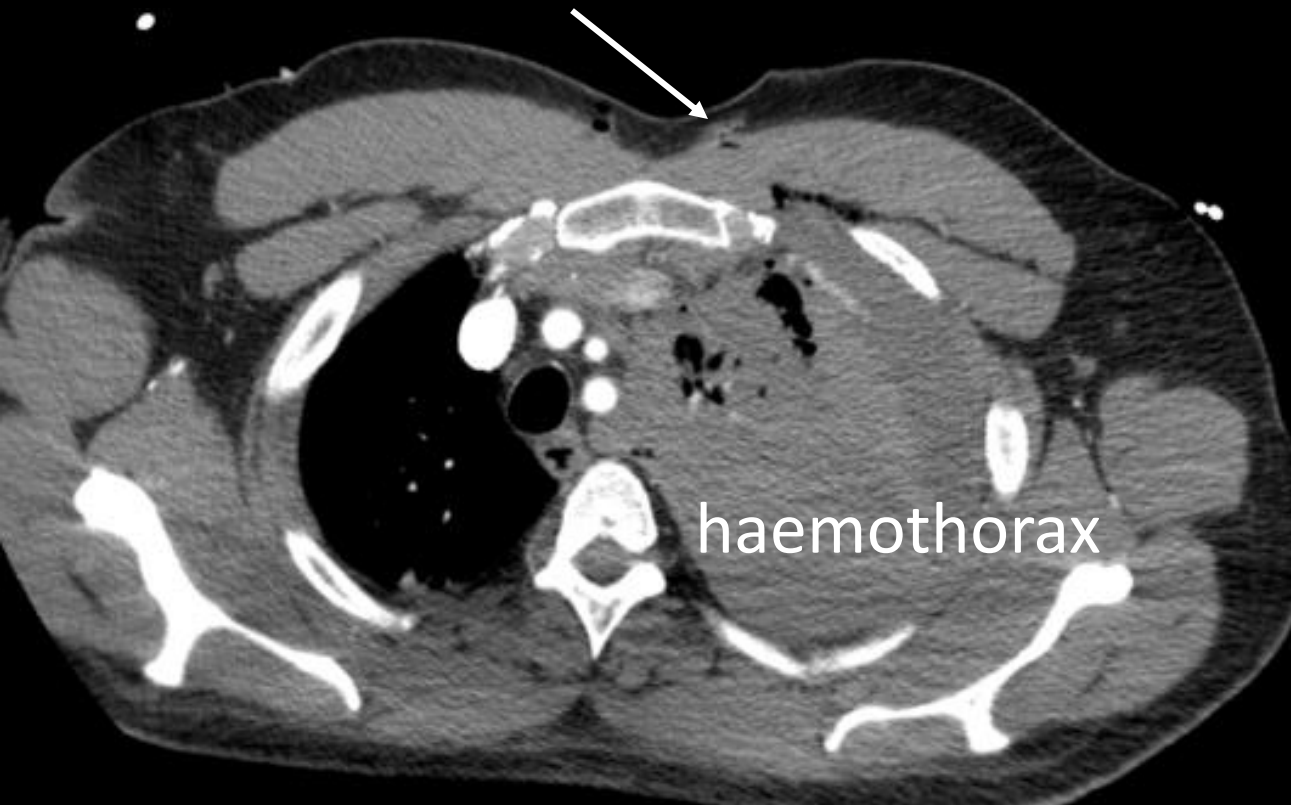
ACTIVE BLEEDING LEFT INTERNAL MAMMARY ARTERY

Entry wound

Arterial

Venous

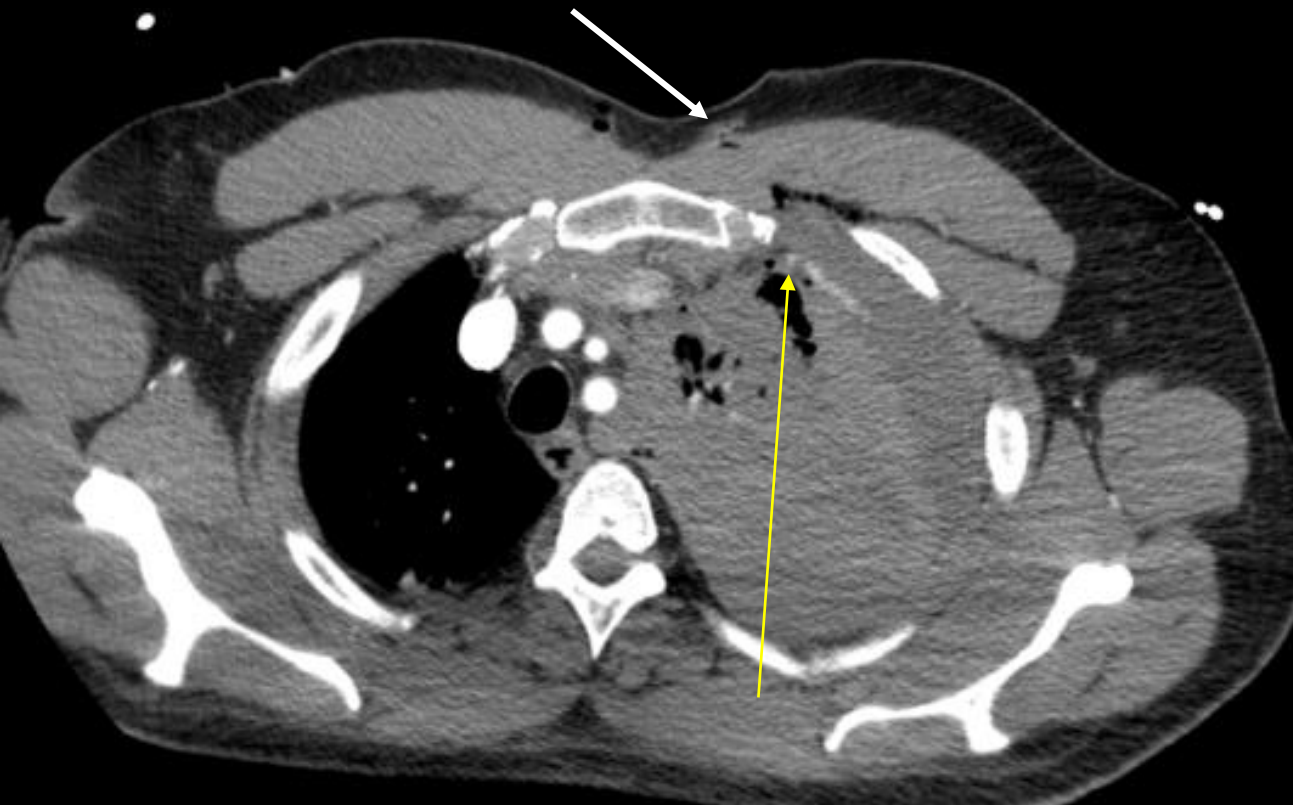

ACTIVE BLEEDING LEFT INTERNAL MAMMARY ARTERY

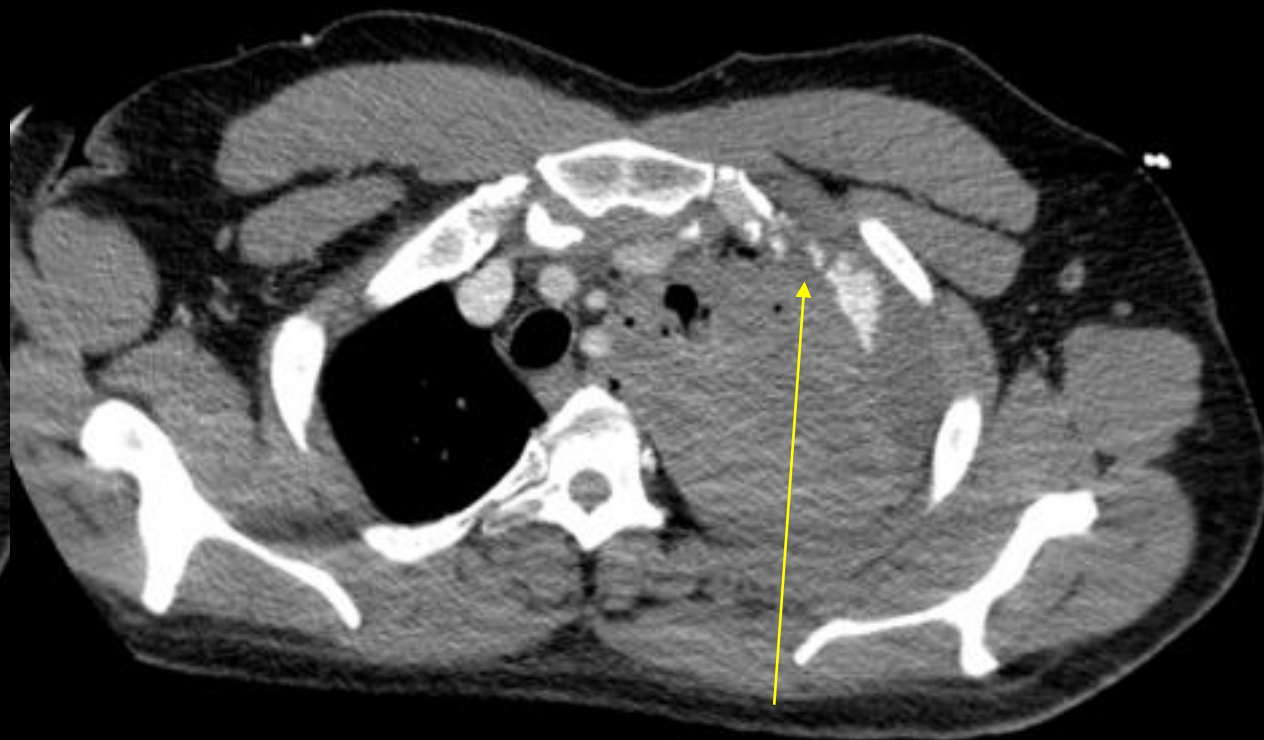
Entry wound

Arterial

Venous



Internal mammary artery



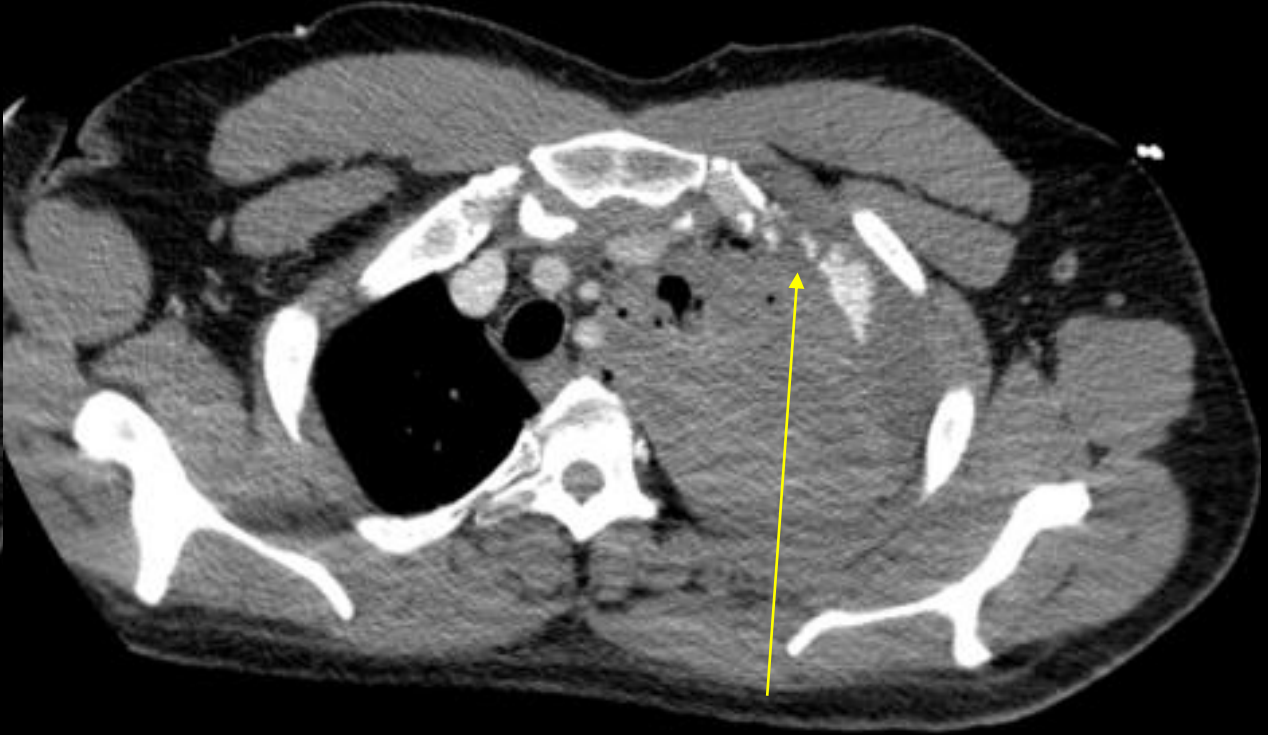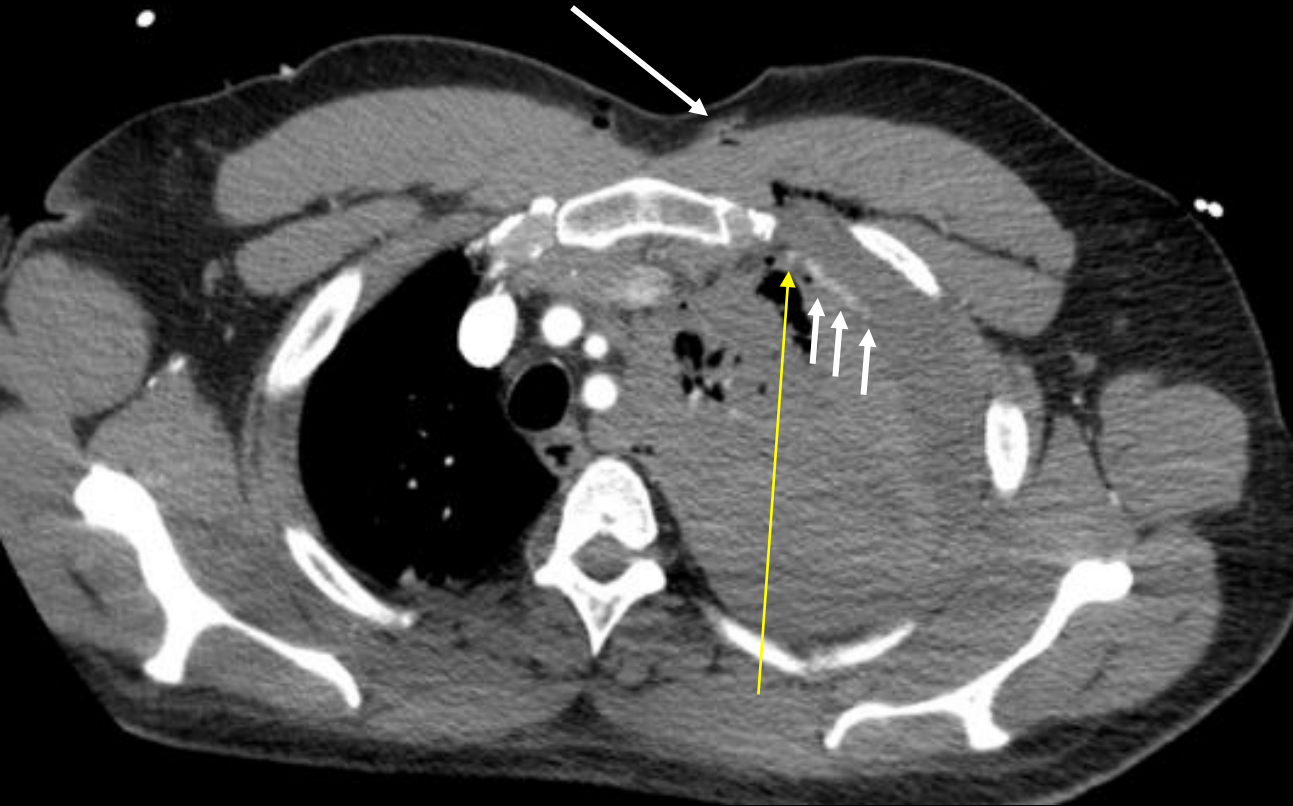
Internal mammary artery

ACTIVE BLEEDING LEFT INTERNAL MAMMARY ARTERY

Entry wound

Arterial

Venous



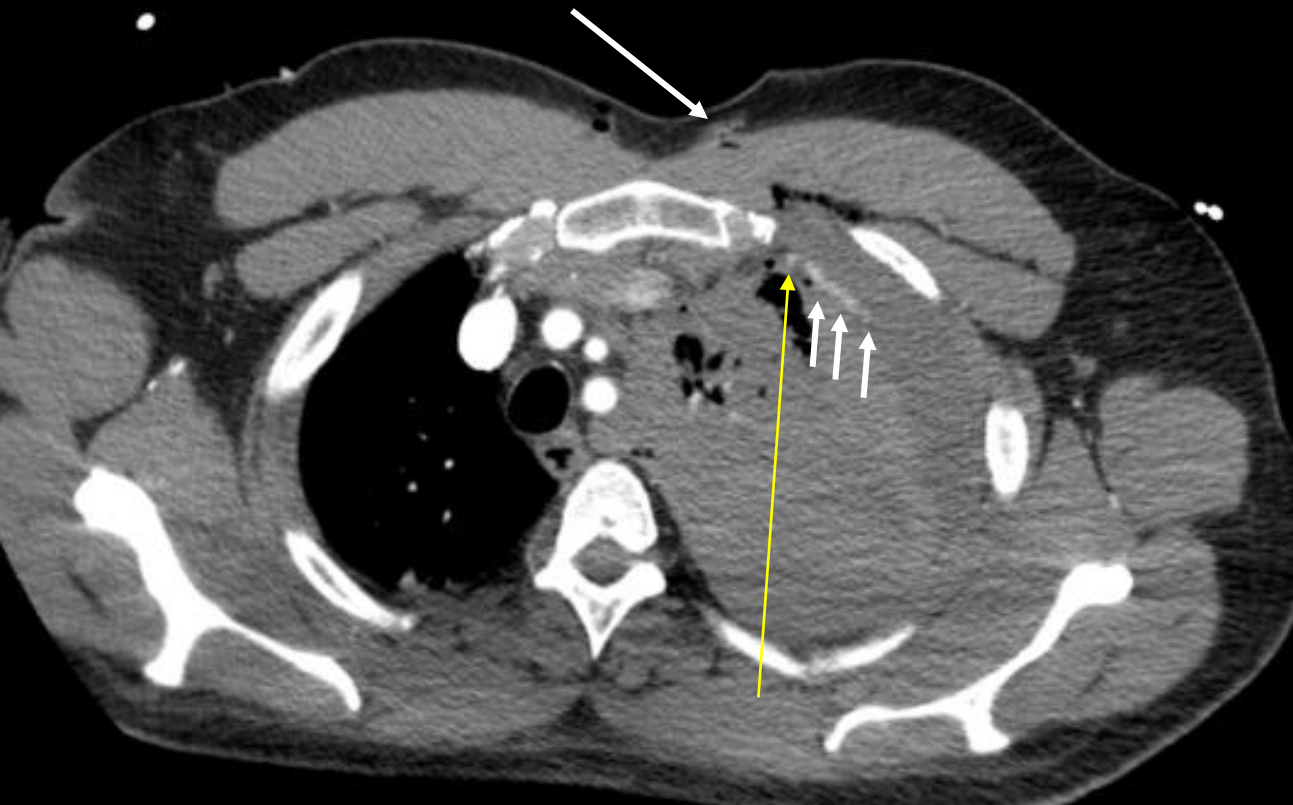
Internal mammary artery

Internal mammary artery

JET of contrast

ACTIVE BLEEDING LEFT INTERNAL MAMMARY ARTERY

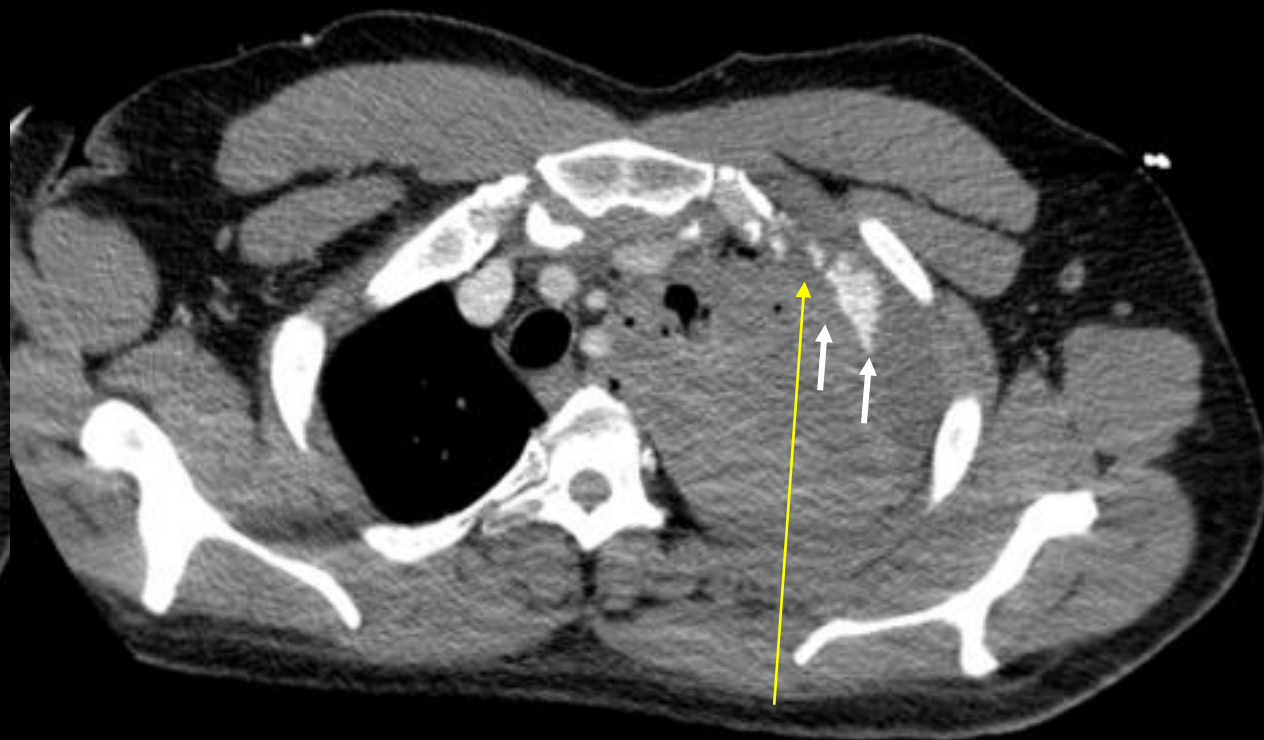Entry wound **Arterial**



Internal mammary artery

JET of contrast

Venous



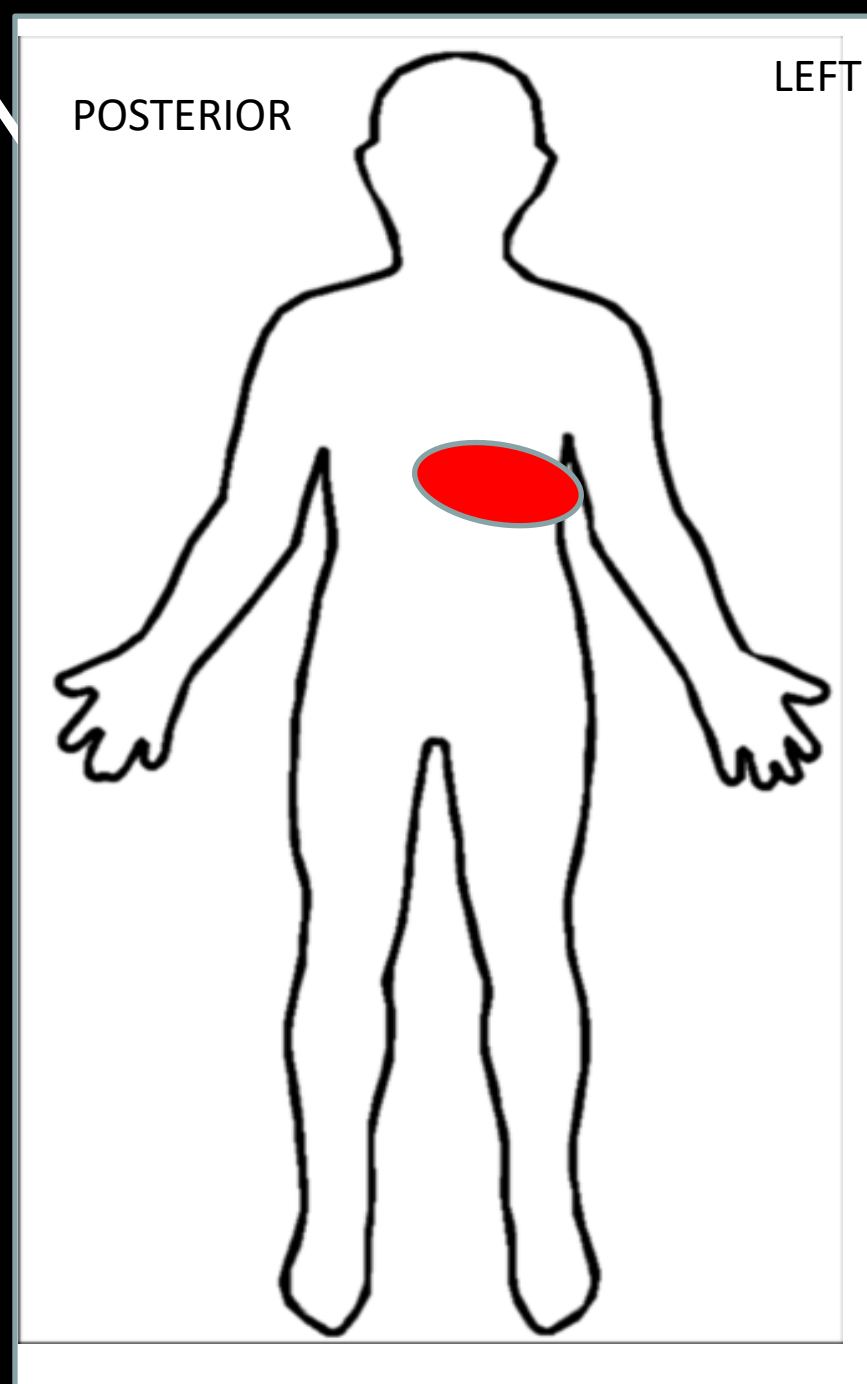
Internal mammary artery

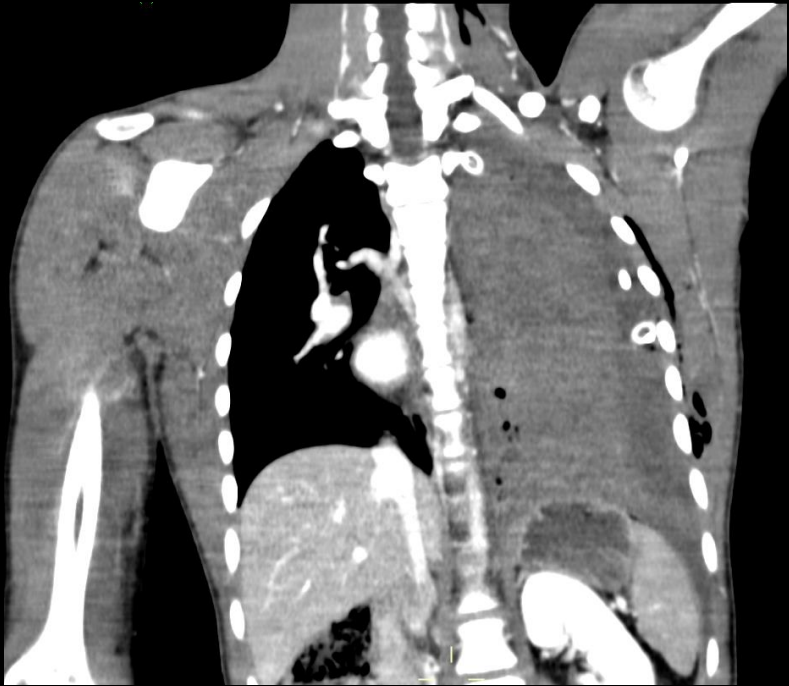spreads out in venous phase

CIRCULATION CASE#2

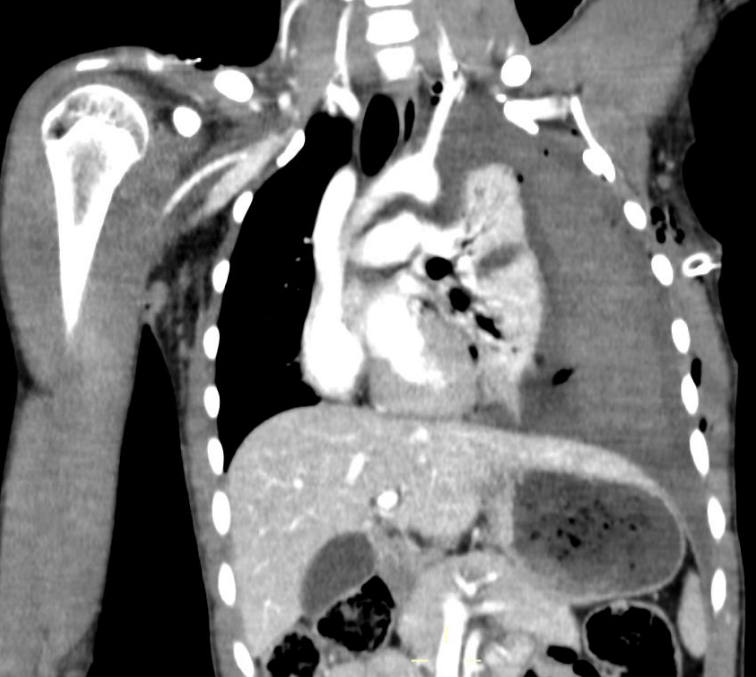
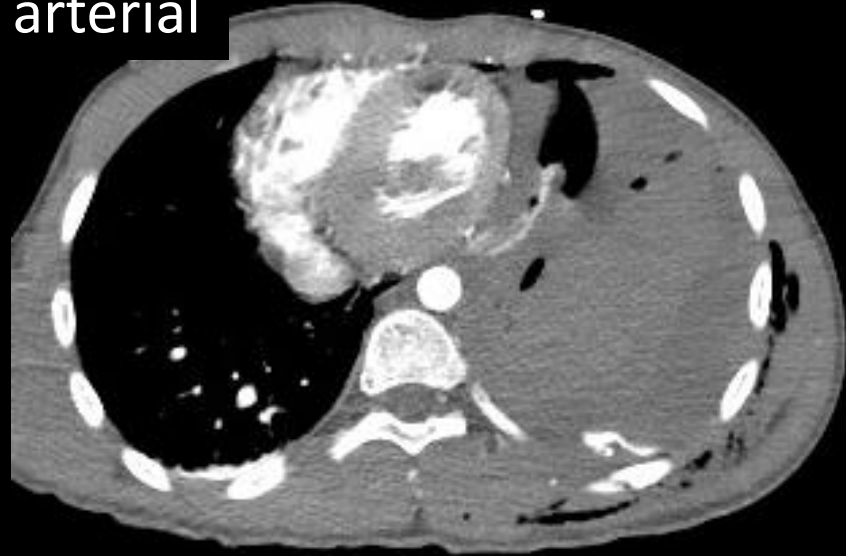
3 x Penetrating Wound left
posterior Chest

ACTIVE BLEEDING

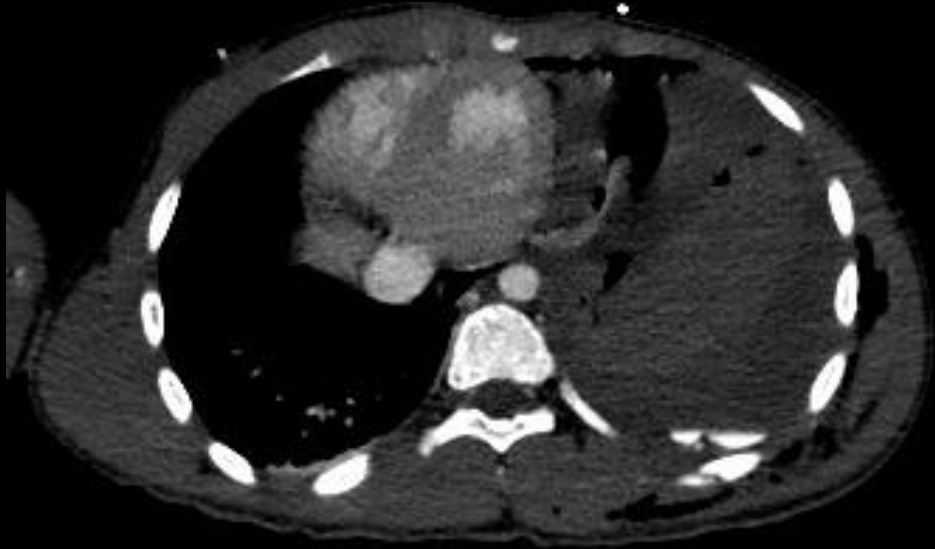


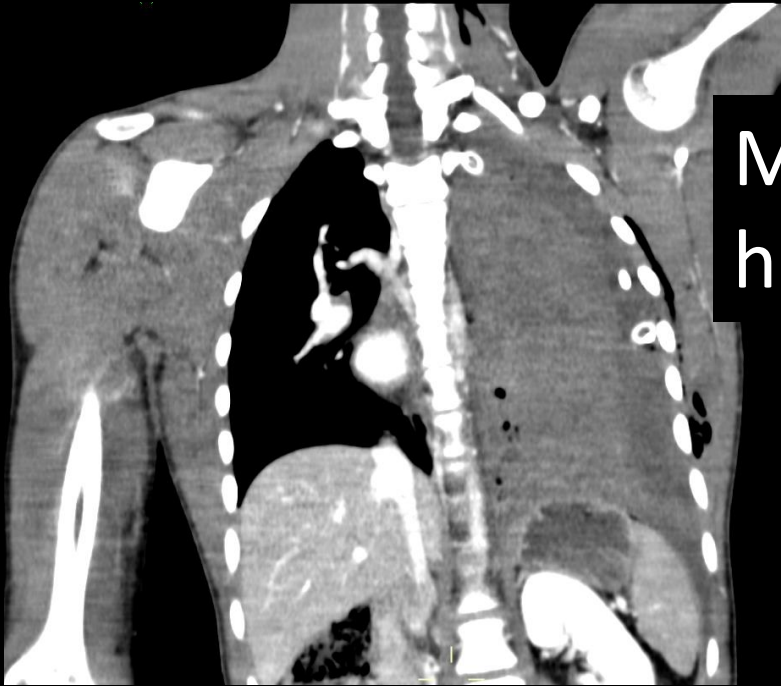

arterial



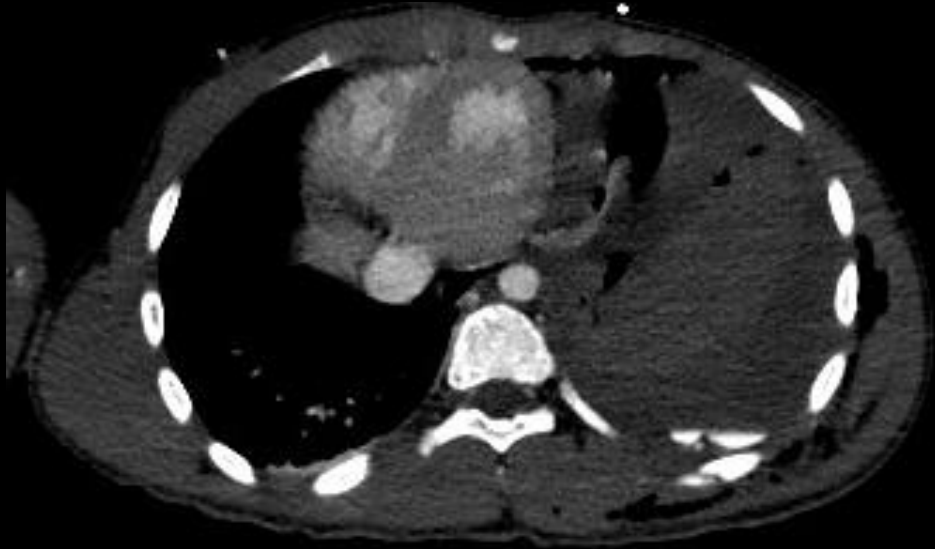
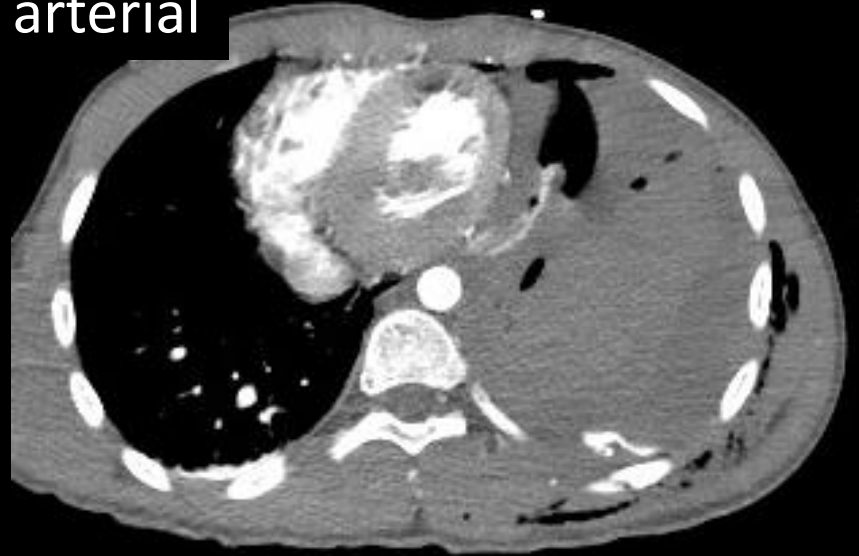venous



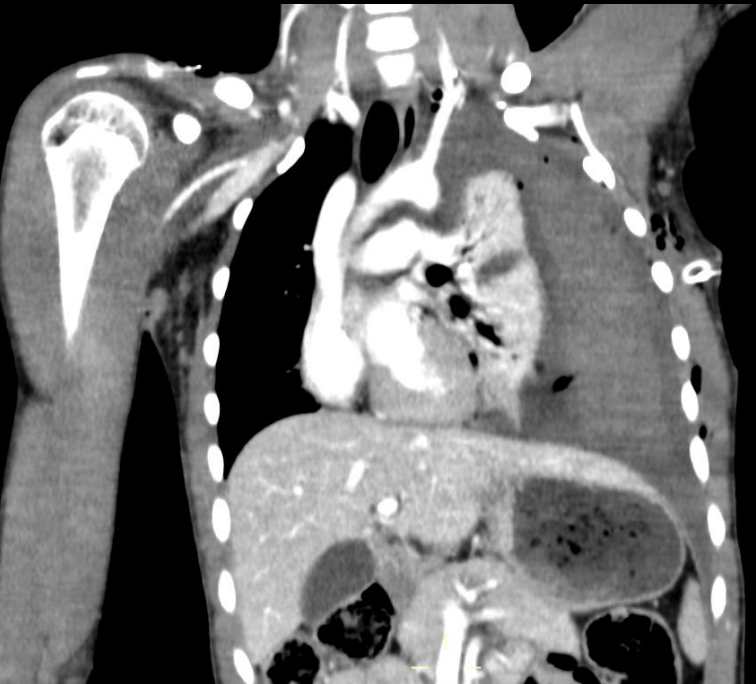


Massive left
haemothorax

arterial



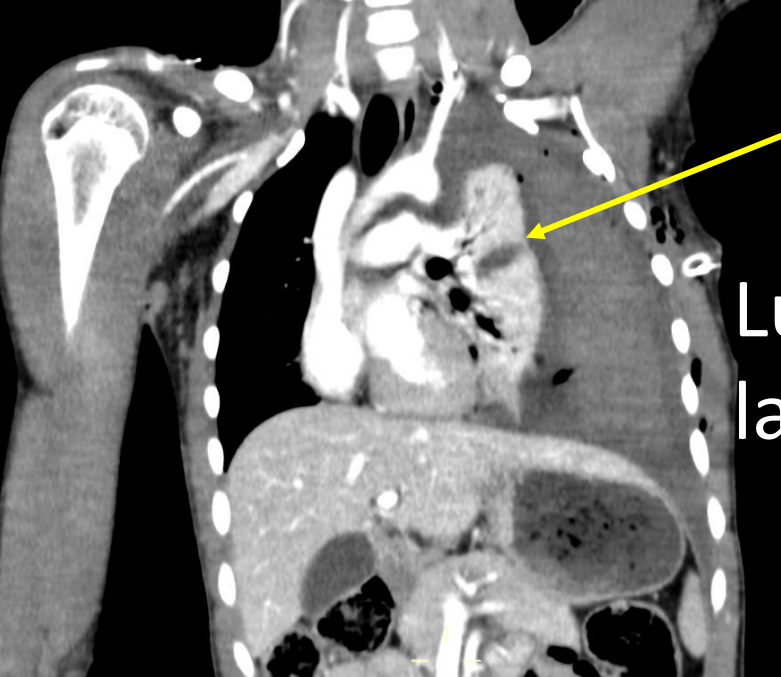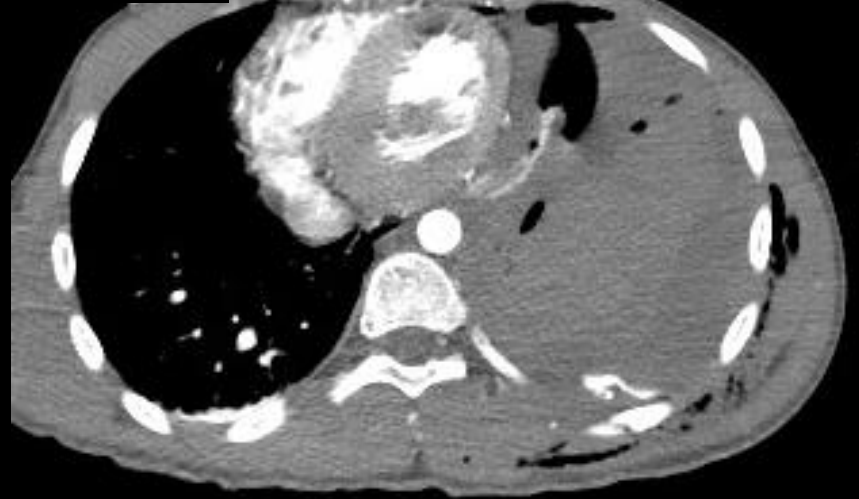
venous





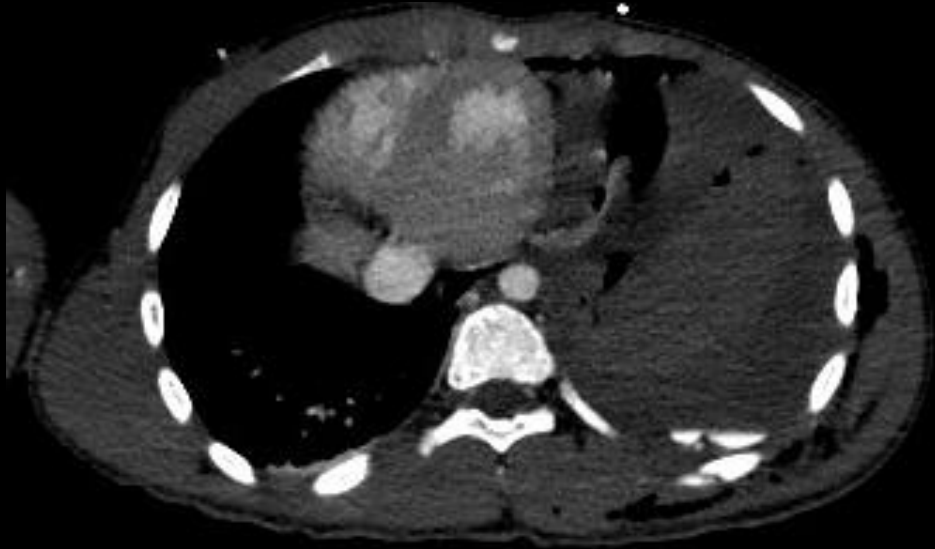
Massive left haemothorax

arterial



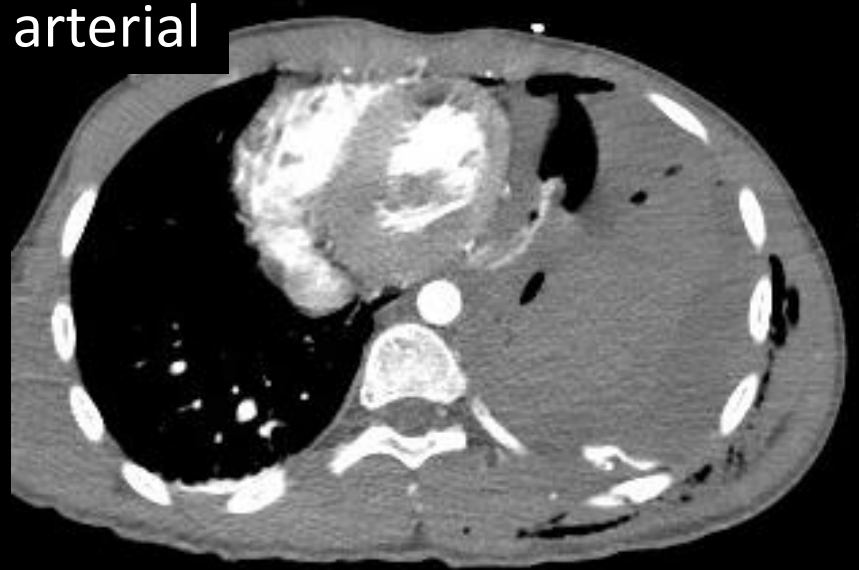
Lung laceration

venous





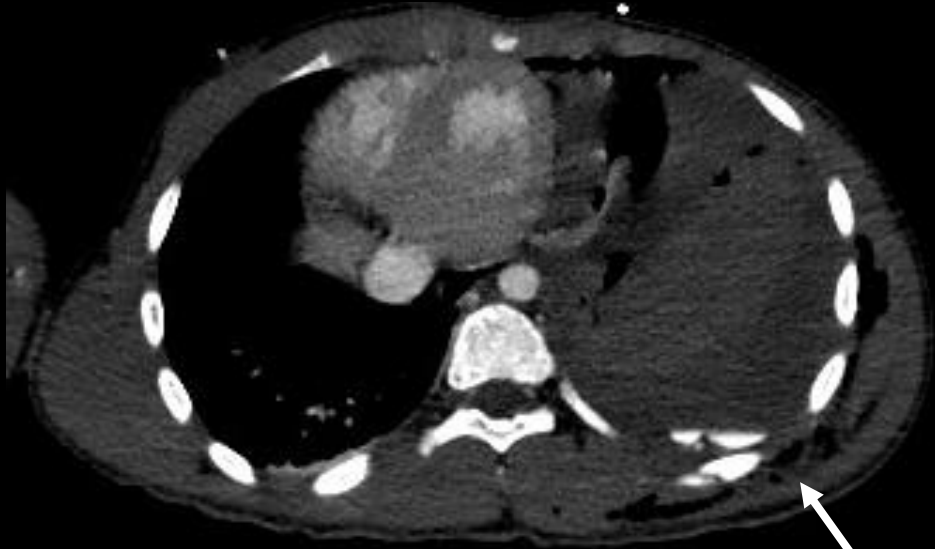
Massive left haemothorax



arterial



Lung laceration

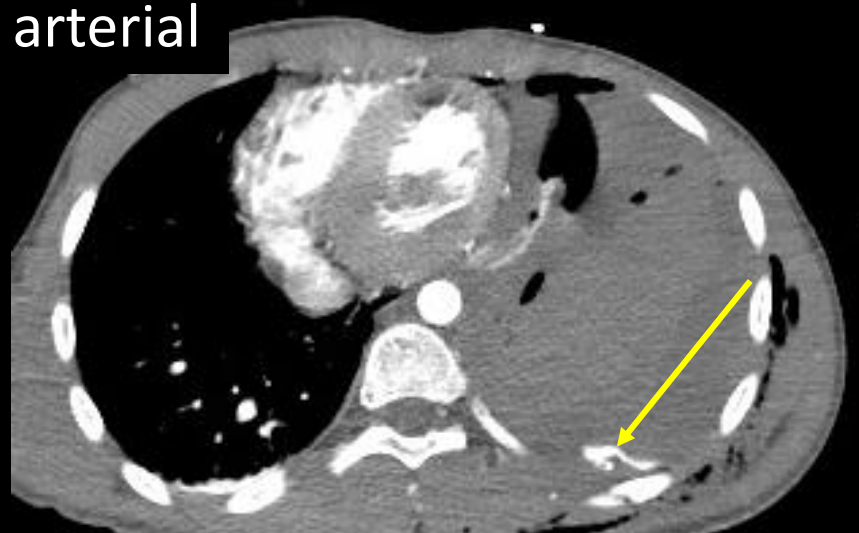


venous

Stab wound

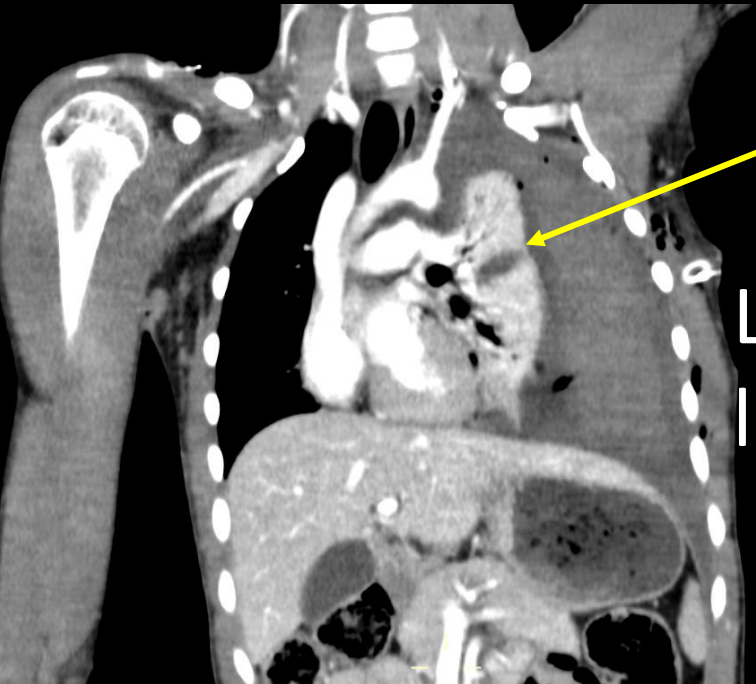

Massive left haemothorax

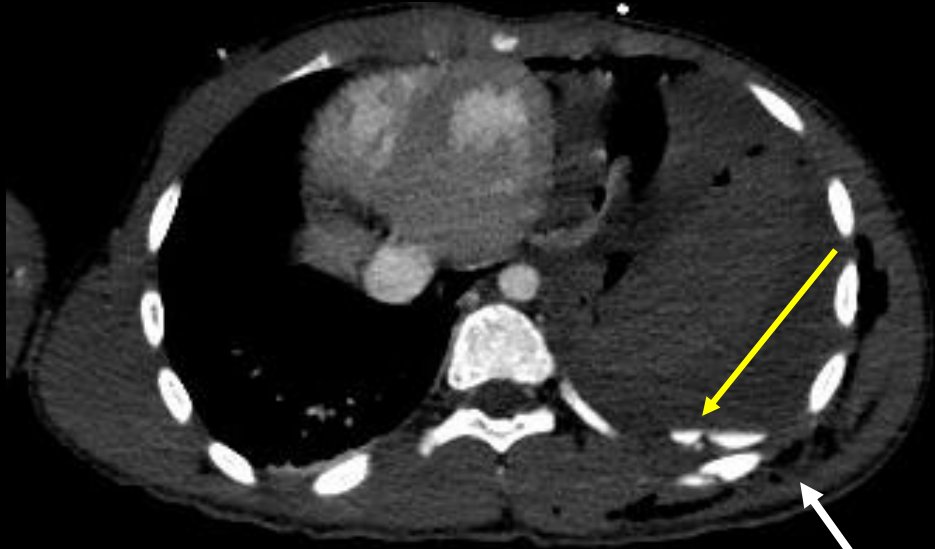


arterial

Active bleeding intercostal artery



Lung laceration

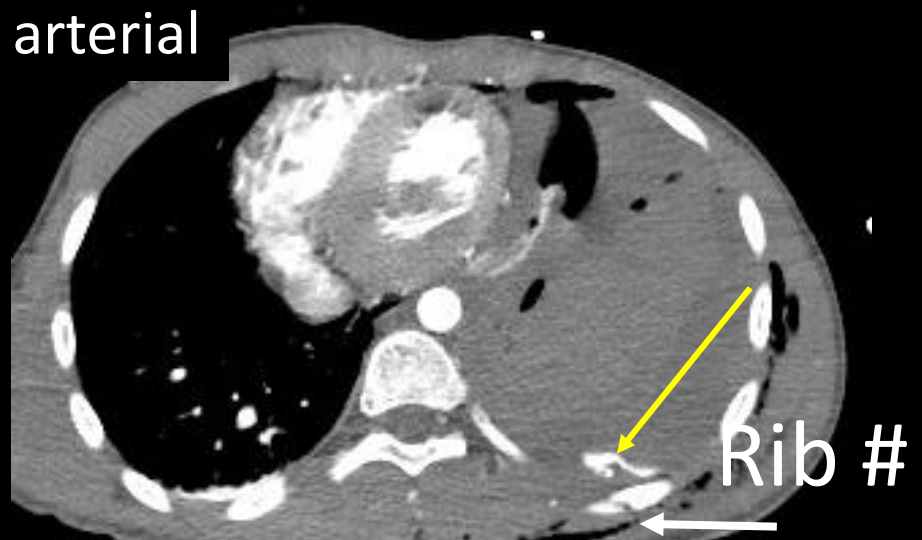

venous

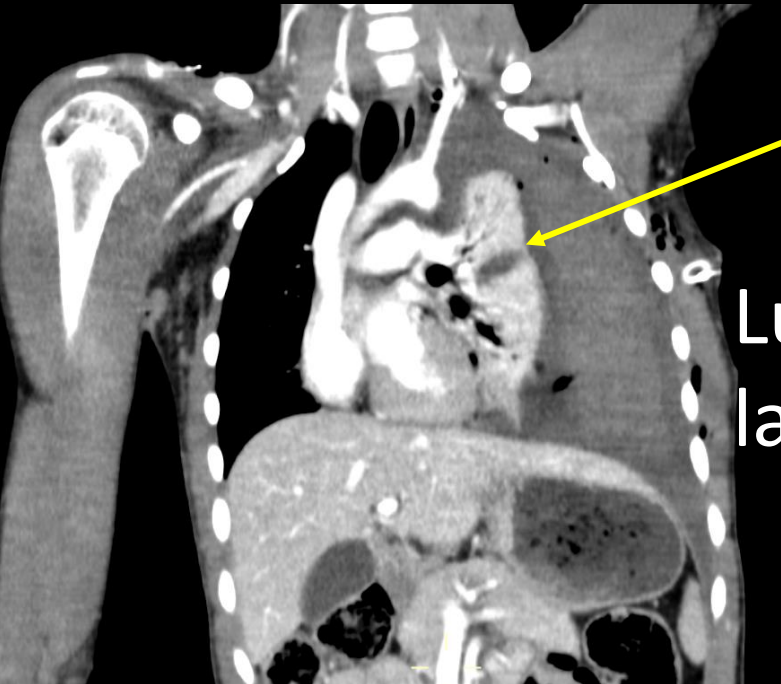Stab wound



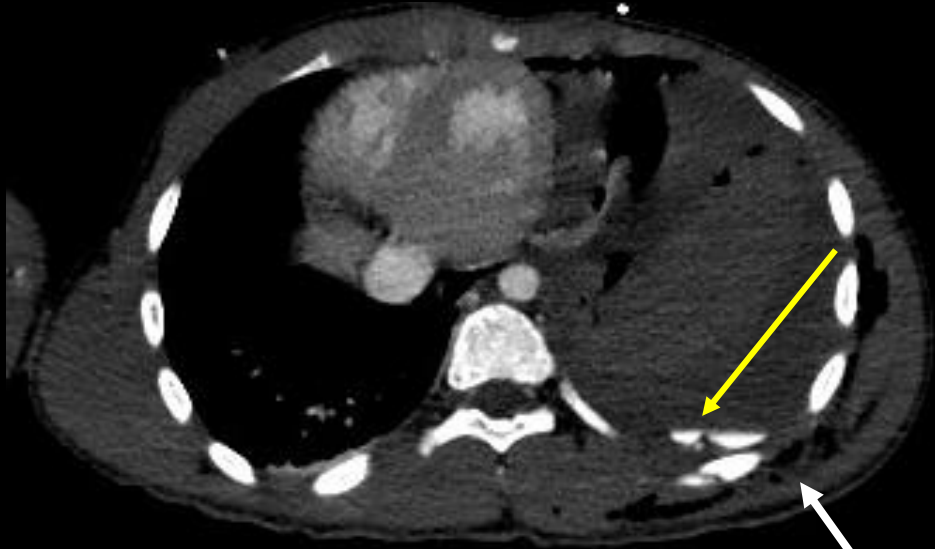
Massive left haemothorax



Active bleeding intercostal artery

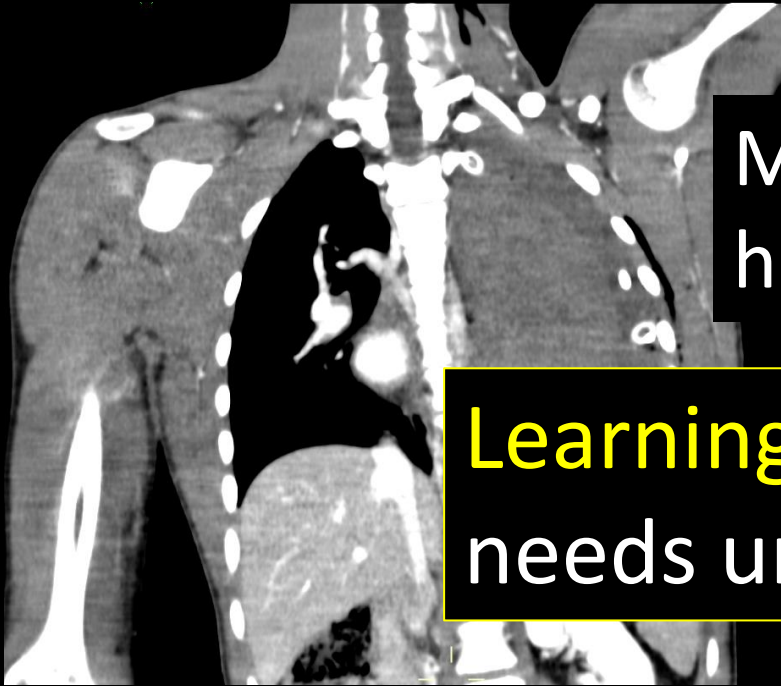

Lung laceration



venous

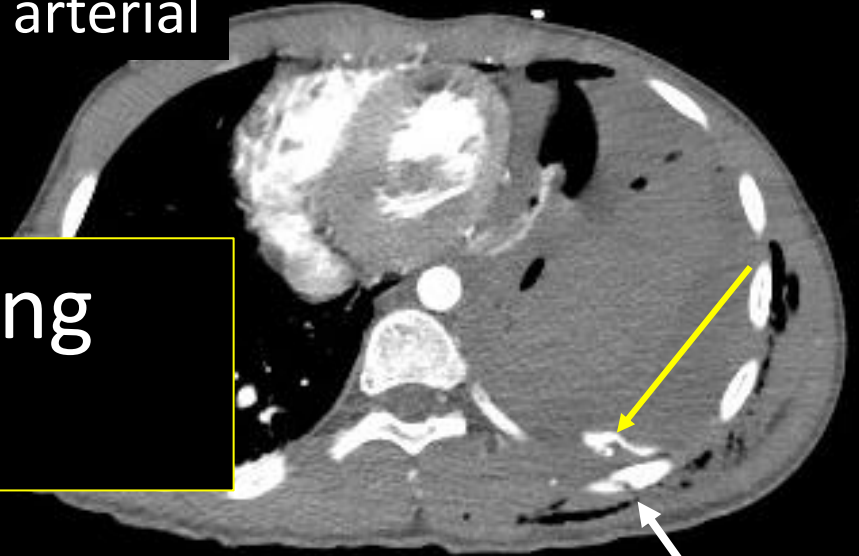
Stab wound



Massive left haemothorax

Learning Point: Active bleeding needs urgent thoracotomy

arterial

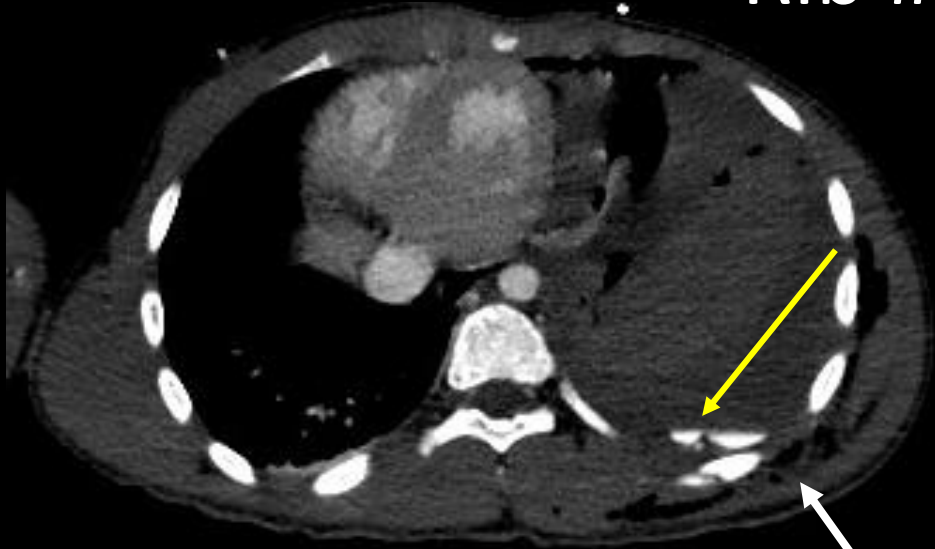


Rib #



Lung laceration

venous



Stab wound

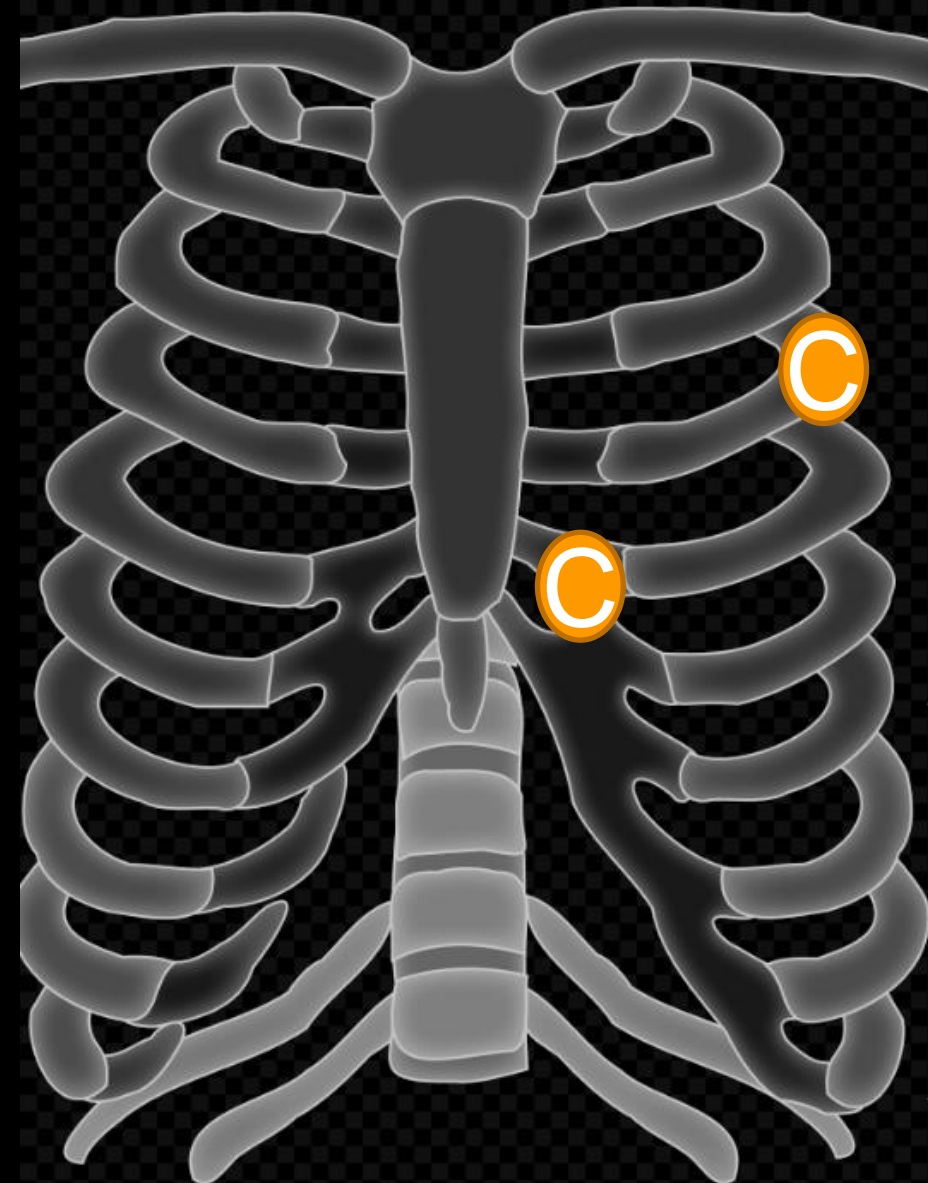
CHEST WALL

A airway

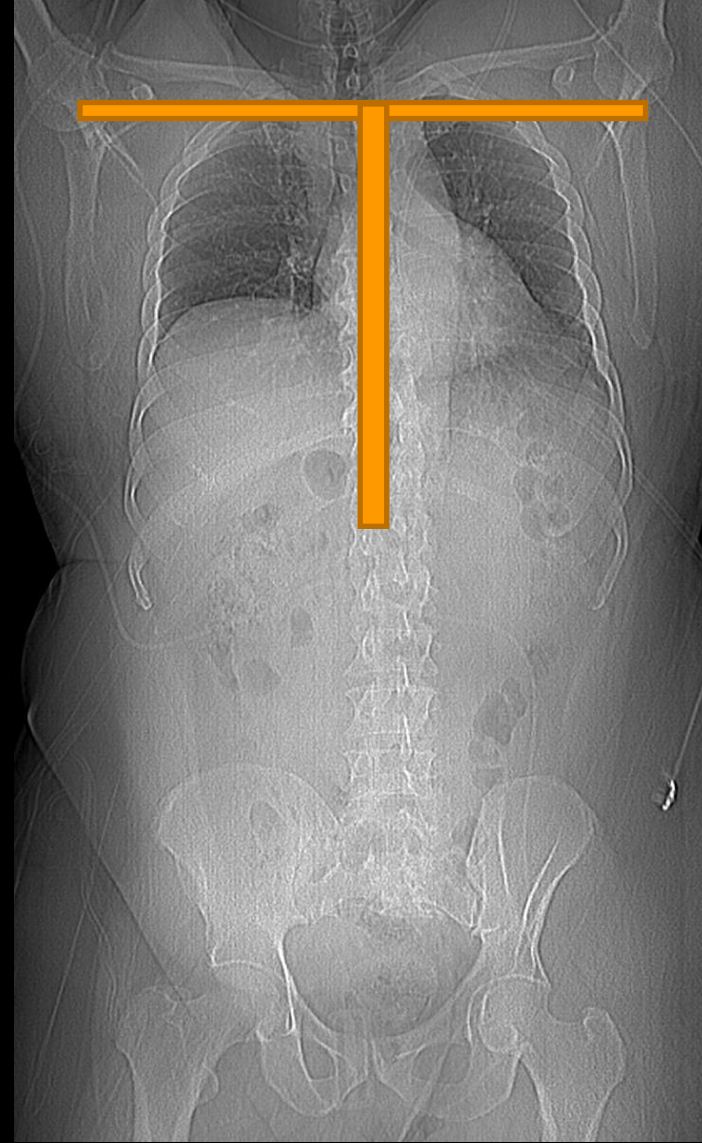
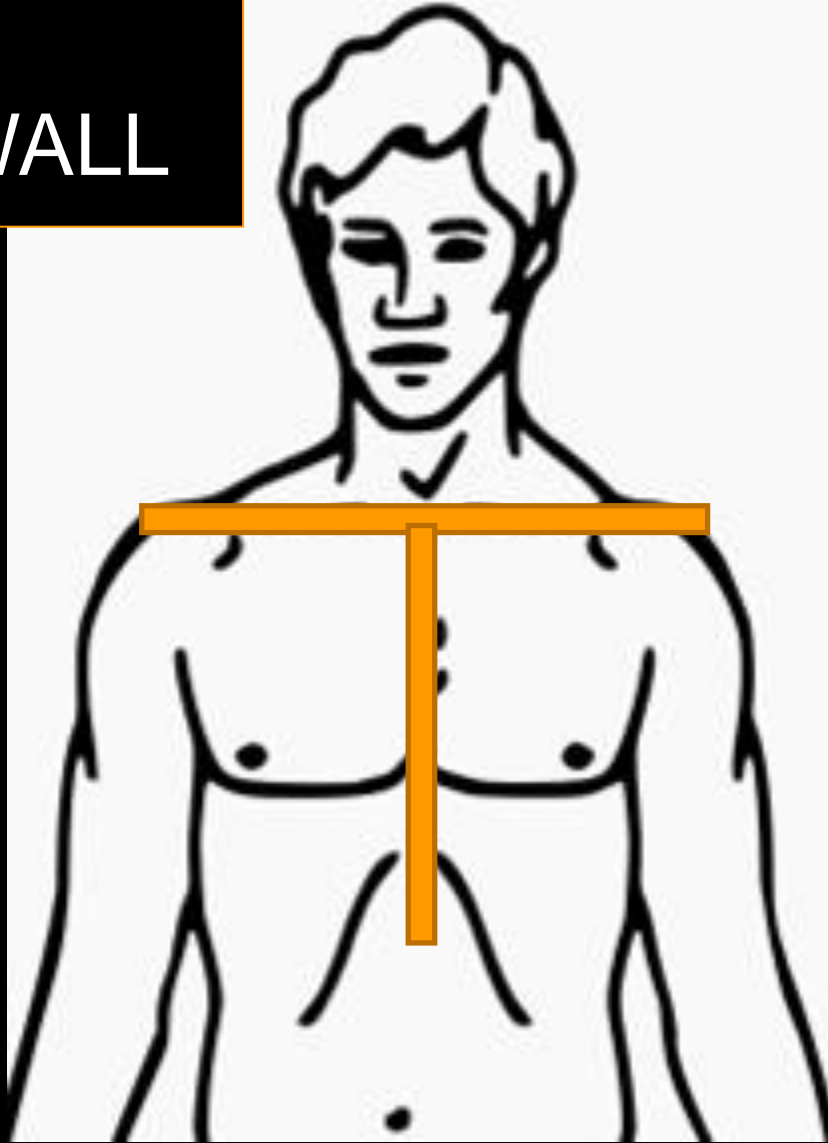
B breathing

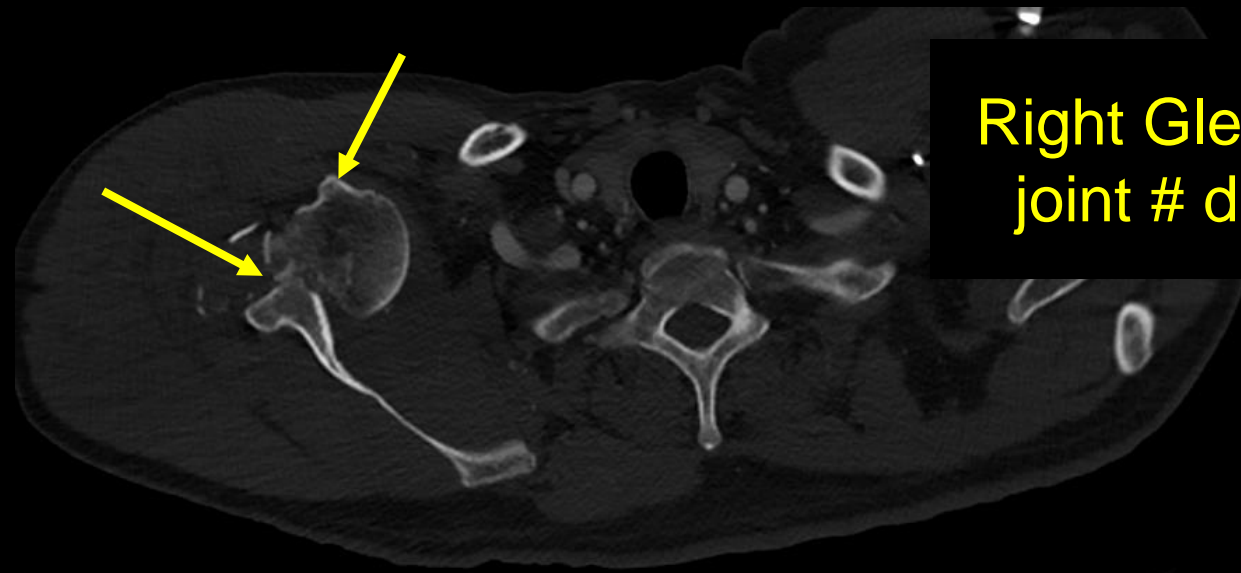
C circulation, **chesT wall**,
costal cartilage

(3)D diaphragm, disability



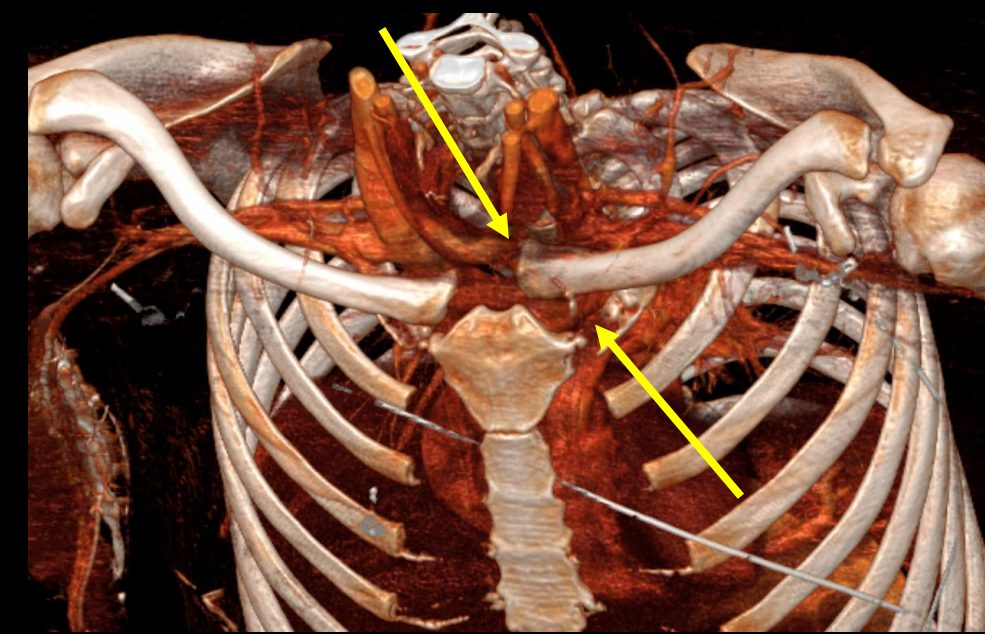
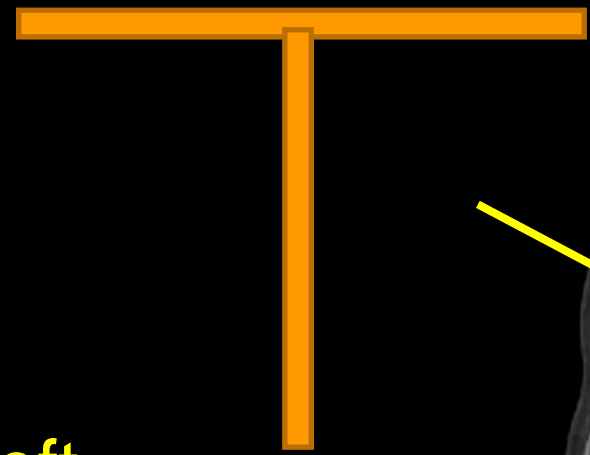
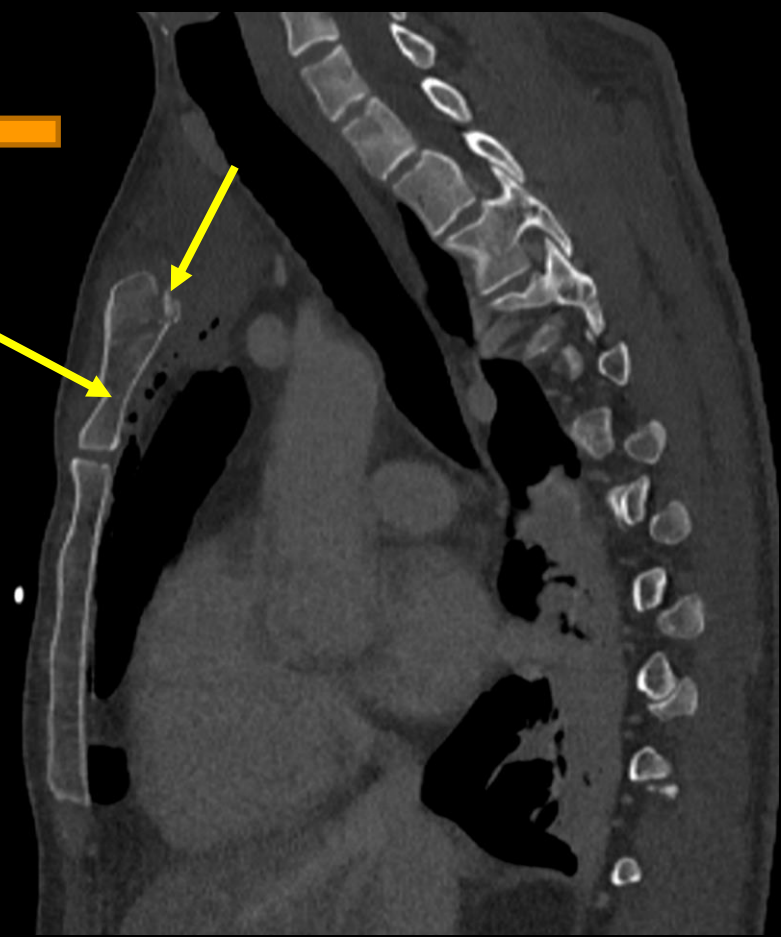
CHEST WALL





Right Glenohumeral joint # dislocation

Manubrial #



Left Sternoclavicular dislocation

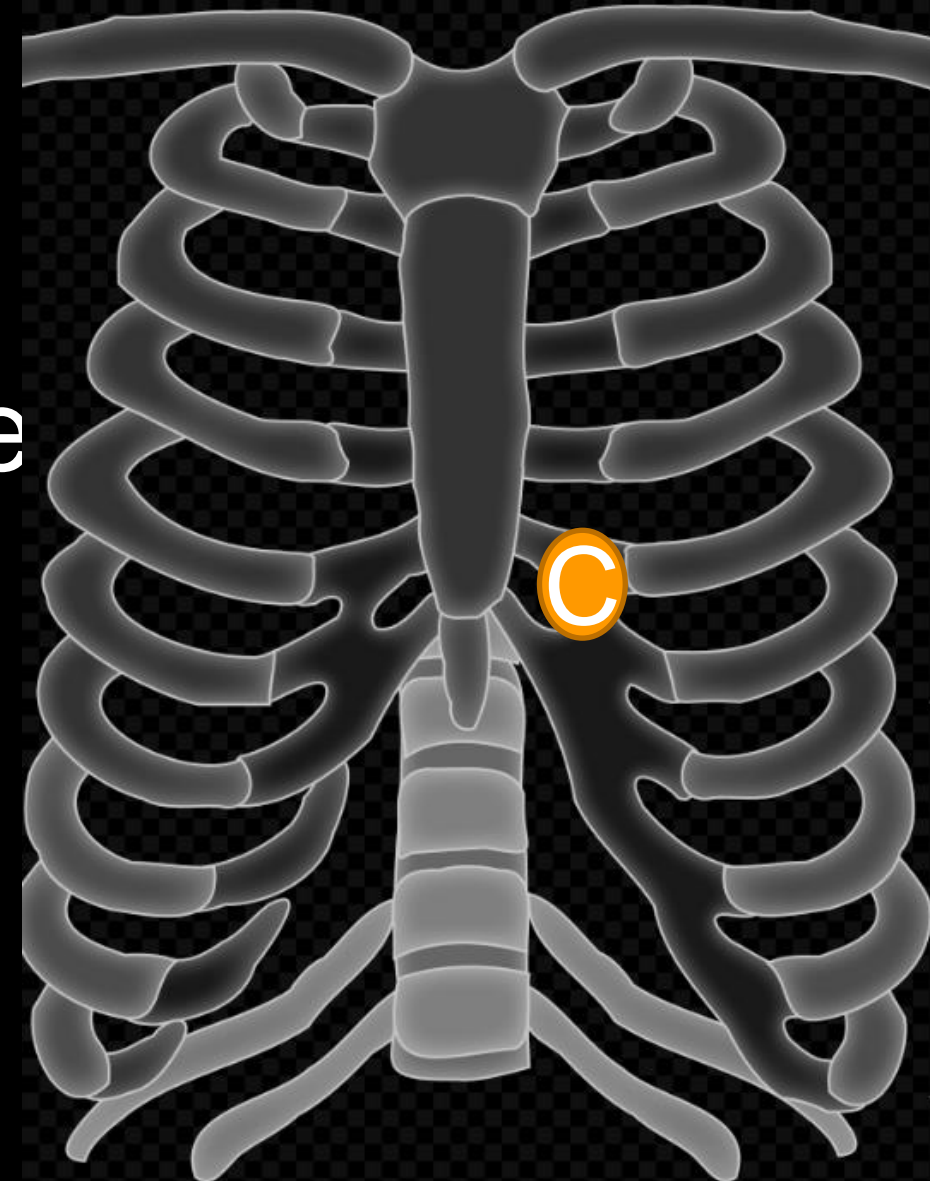
Chest wall – Rib fractures

A airway

B breathing

C **chest wall**, costal cartilage

(3) D diaphragm, disability



pollEv.com/edick900



Concerning rib fractures which of the following are associated with increased morbidity/mortality

first rib fracture

0%

displaced fractures

0%

flail segment

0%

>3 ribs fractured

0%

Age over 65 years

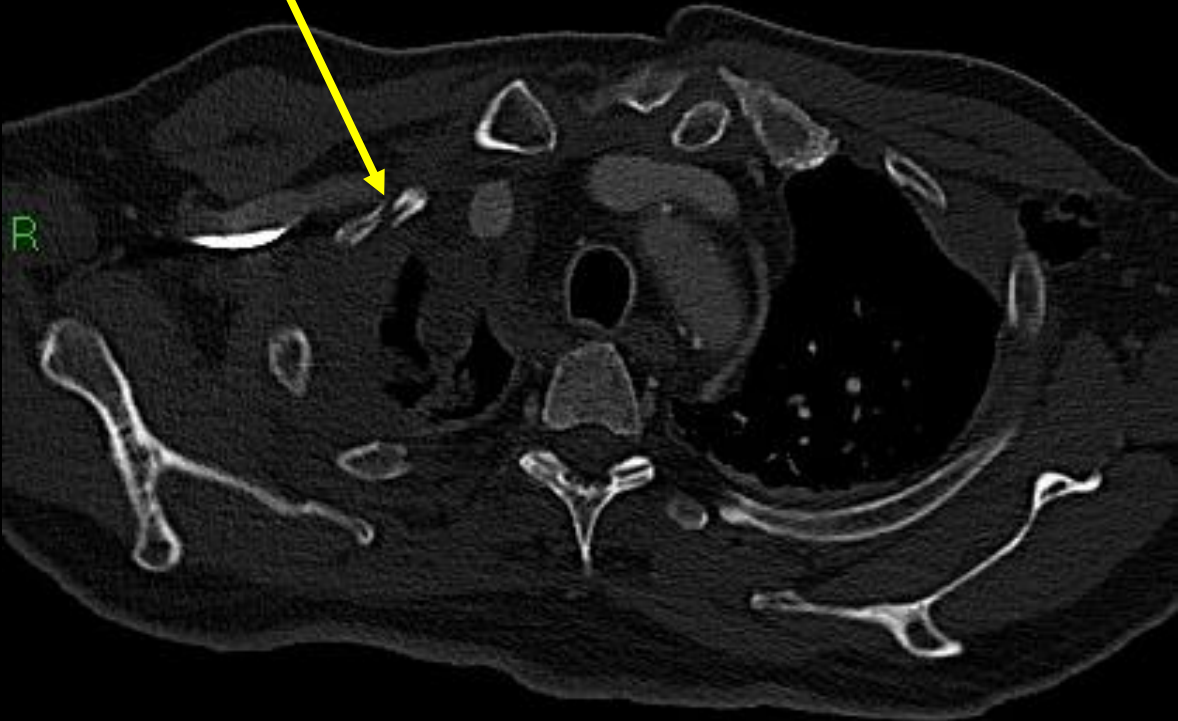
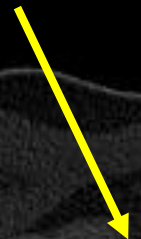
0%

Rib fractures – increased morbidity and mortality

- First rib
- Displaced rib fractures
- Flail segment (2 x 2)
- >3 ribs fractured
- Age >65

Day 0

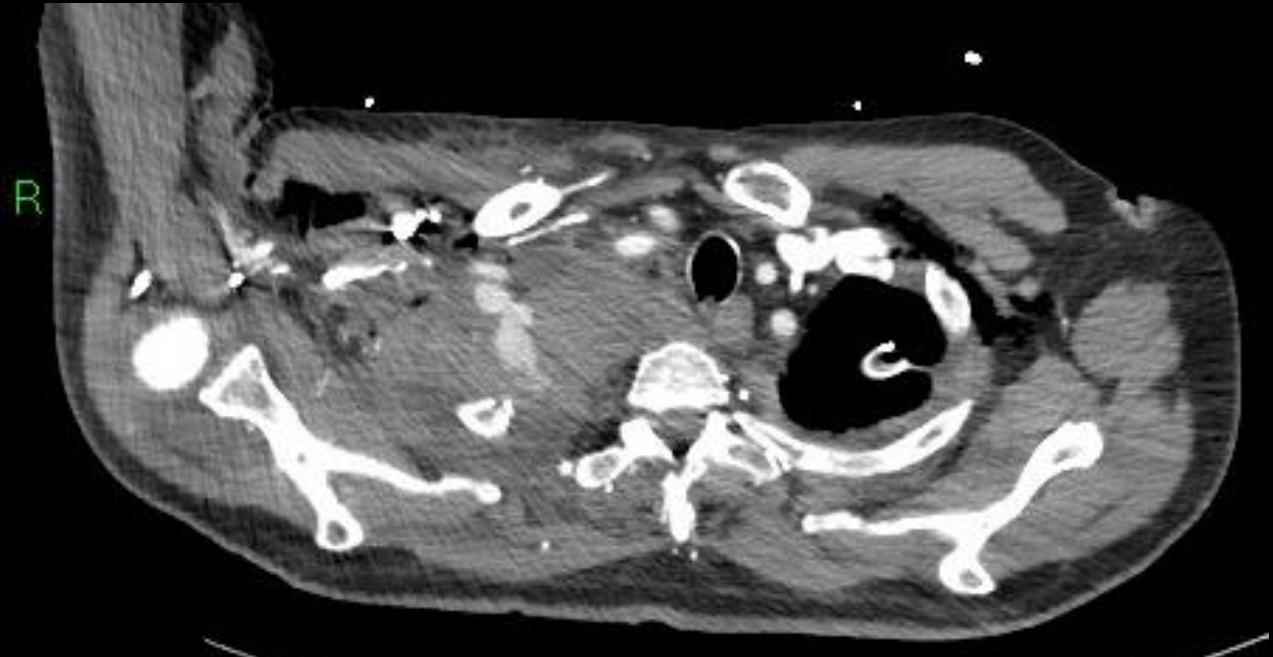
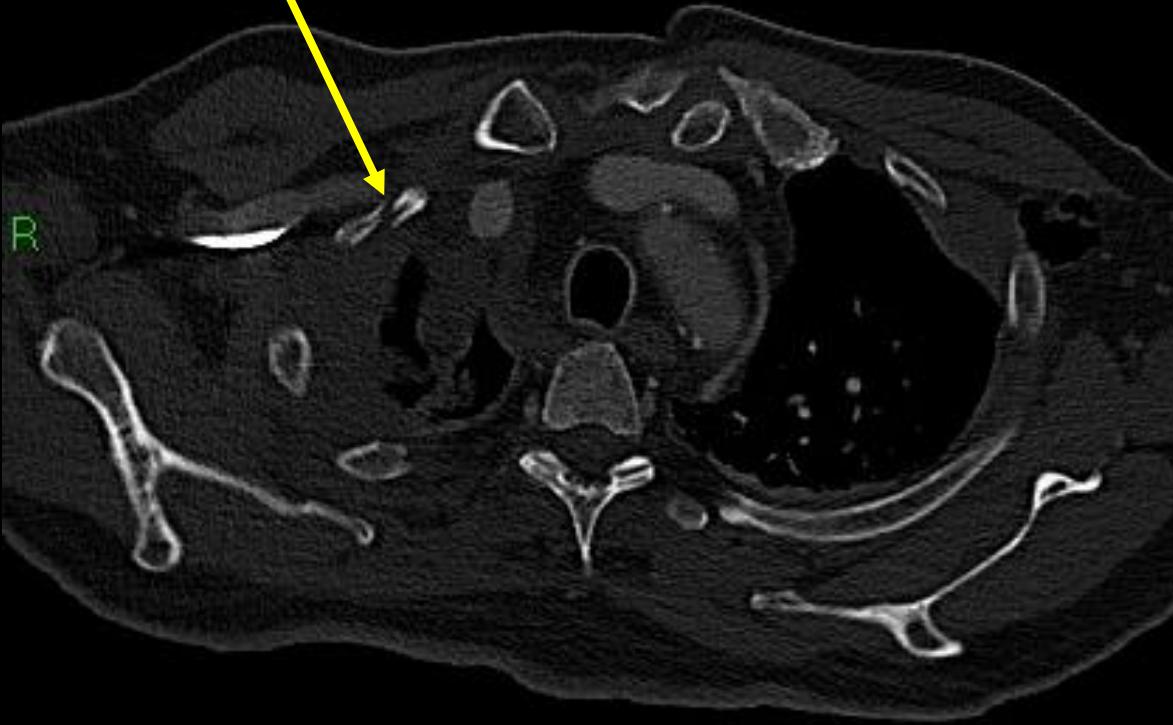
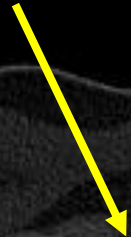
right 1st rib



Day 0

Day 3 suddenly hypotensive

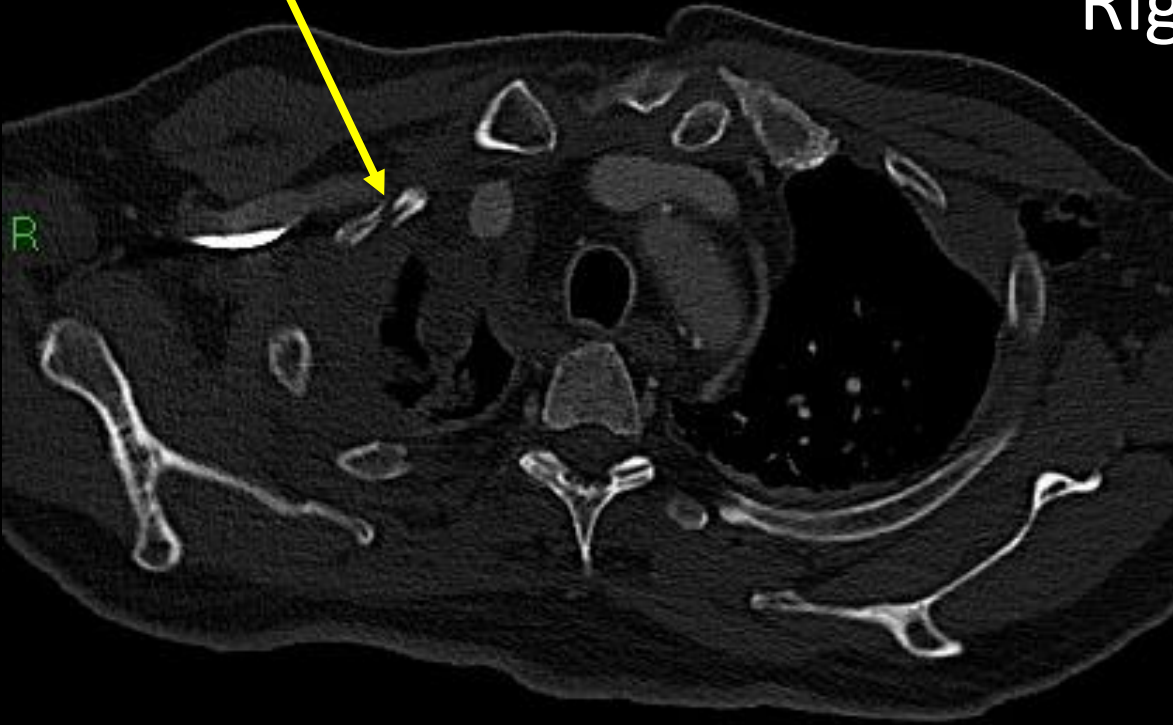
right 1st rib



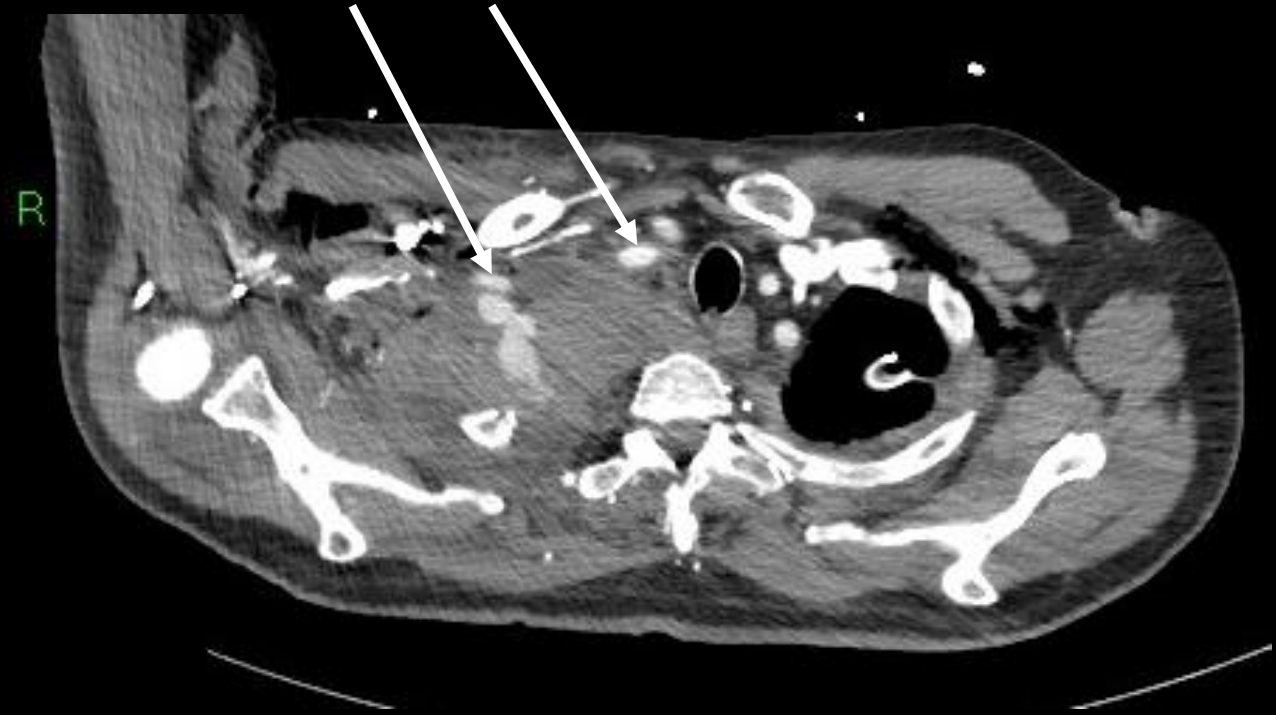
Day 0

Day 3 suddenly hypotensive

right 1st rib



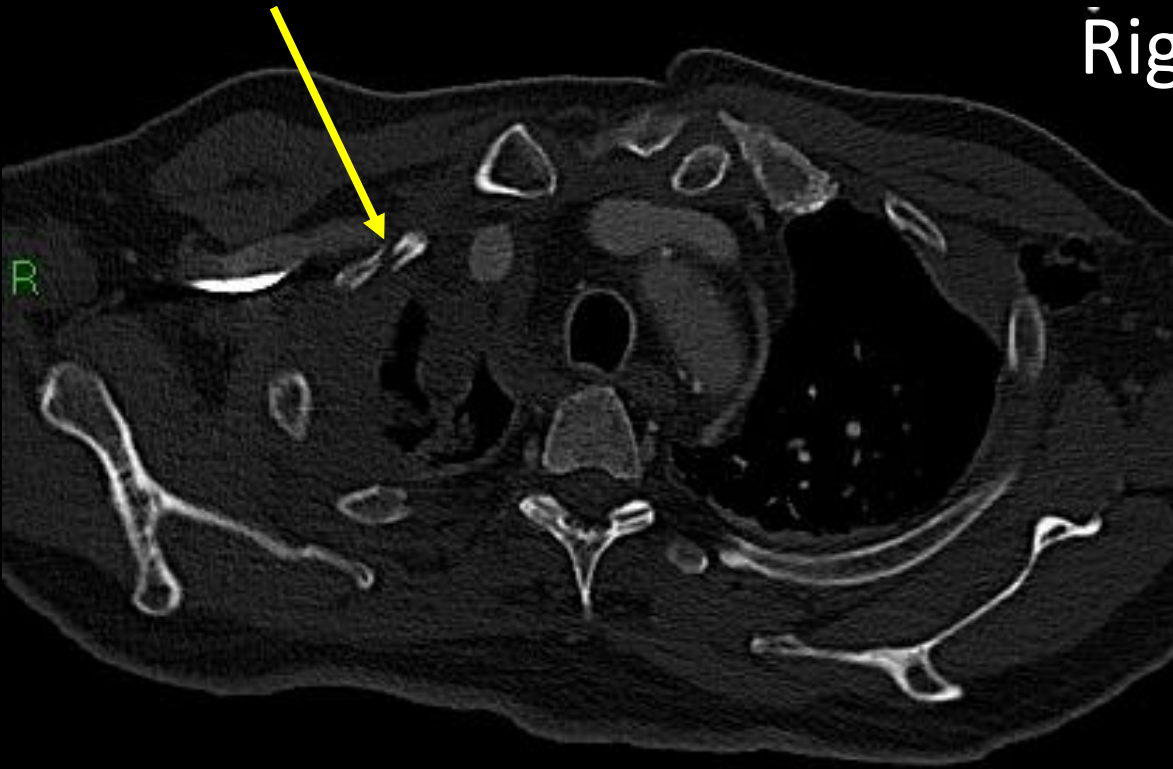
Right subclavian artery



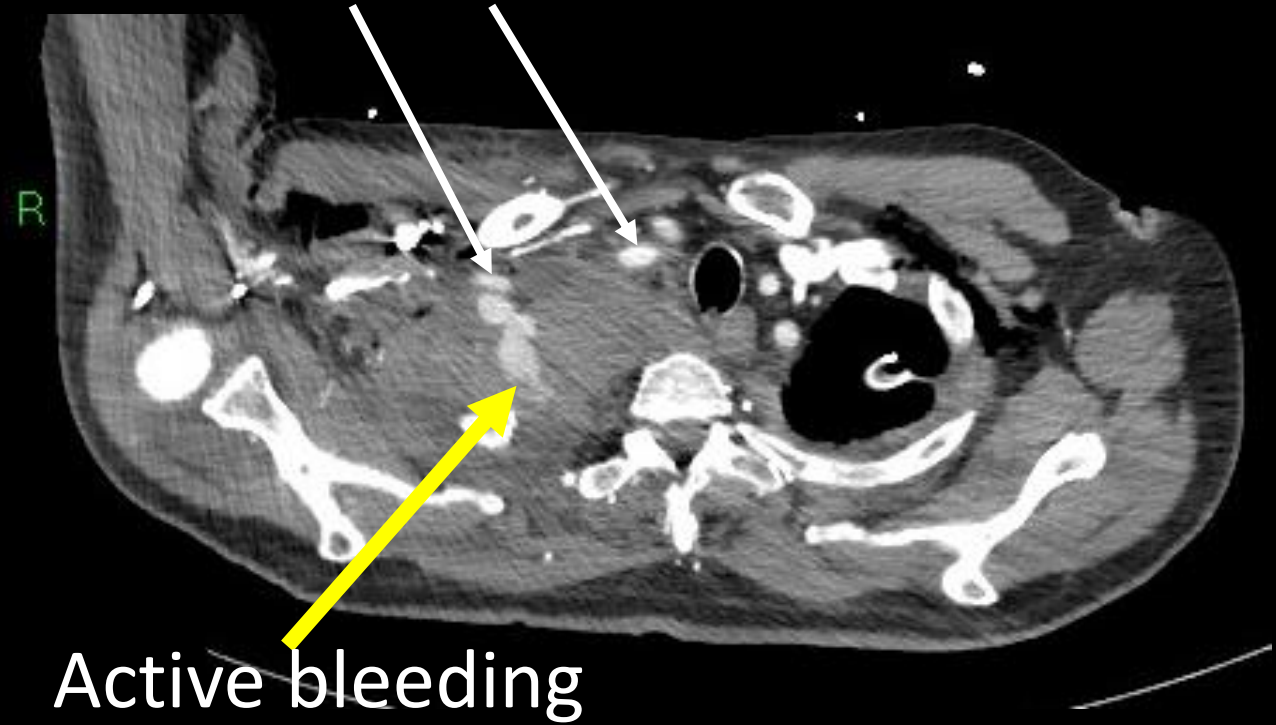
Day 0

Day 3 suddenly hypotensive

right 1st rib

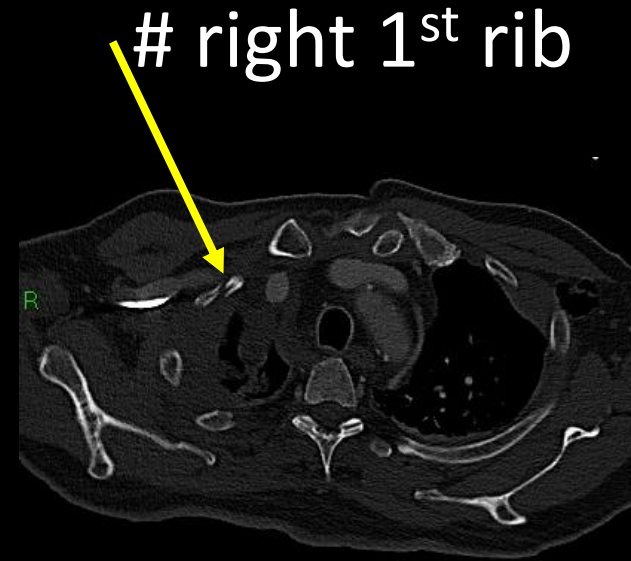


Right subclavian artery



Rib fractures – increased morbidity/ mortality

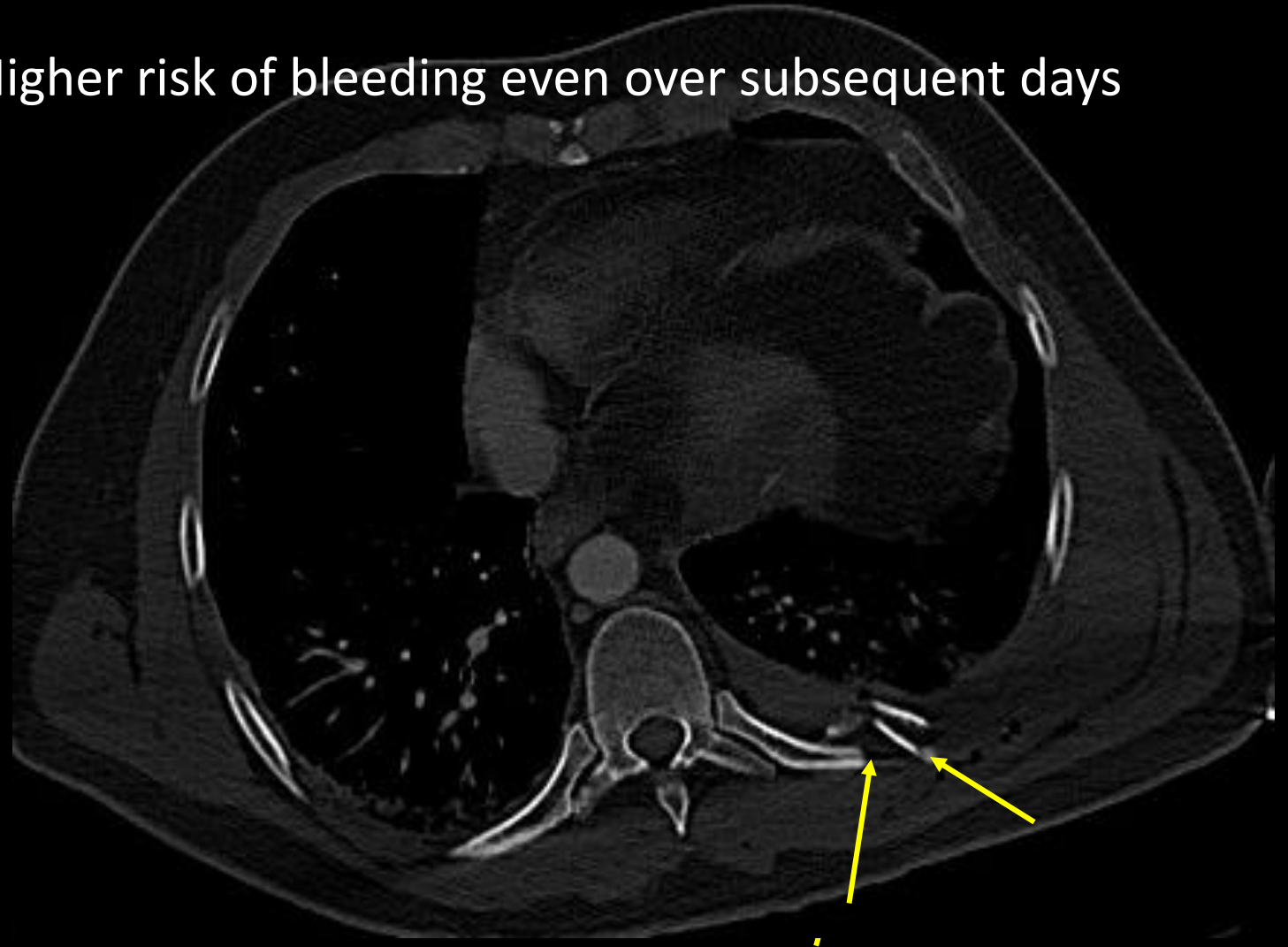
- First rib
- Displaced rib fractures
- Flail segment (2 x 2)
- >3 ribs fractured
- Age >65



Rib fractures – increased morbidity/ mortality

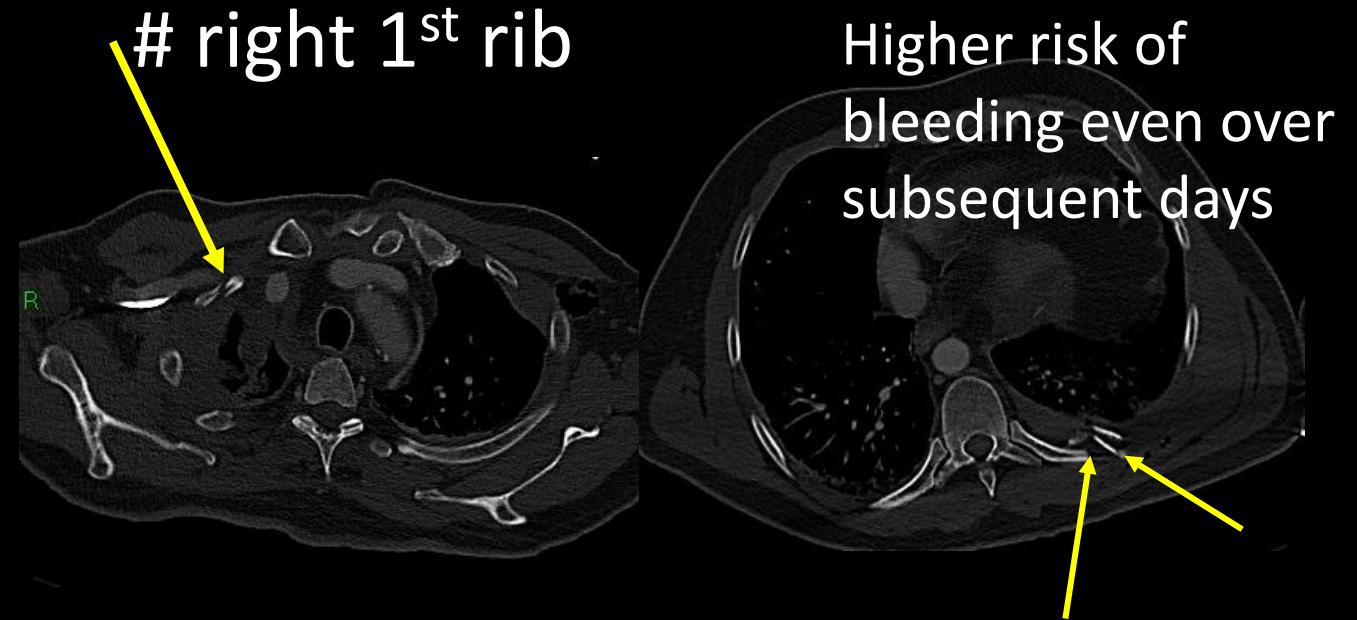
- First rib
- **Displaced rib fractures**
- Flail segment (2 x 2)
- >3 ribs fractured
- Age >65

Higher risk of bleeding even over subsequent days



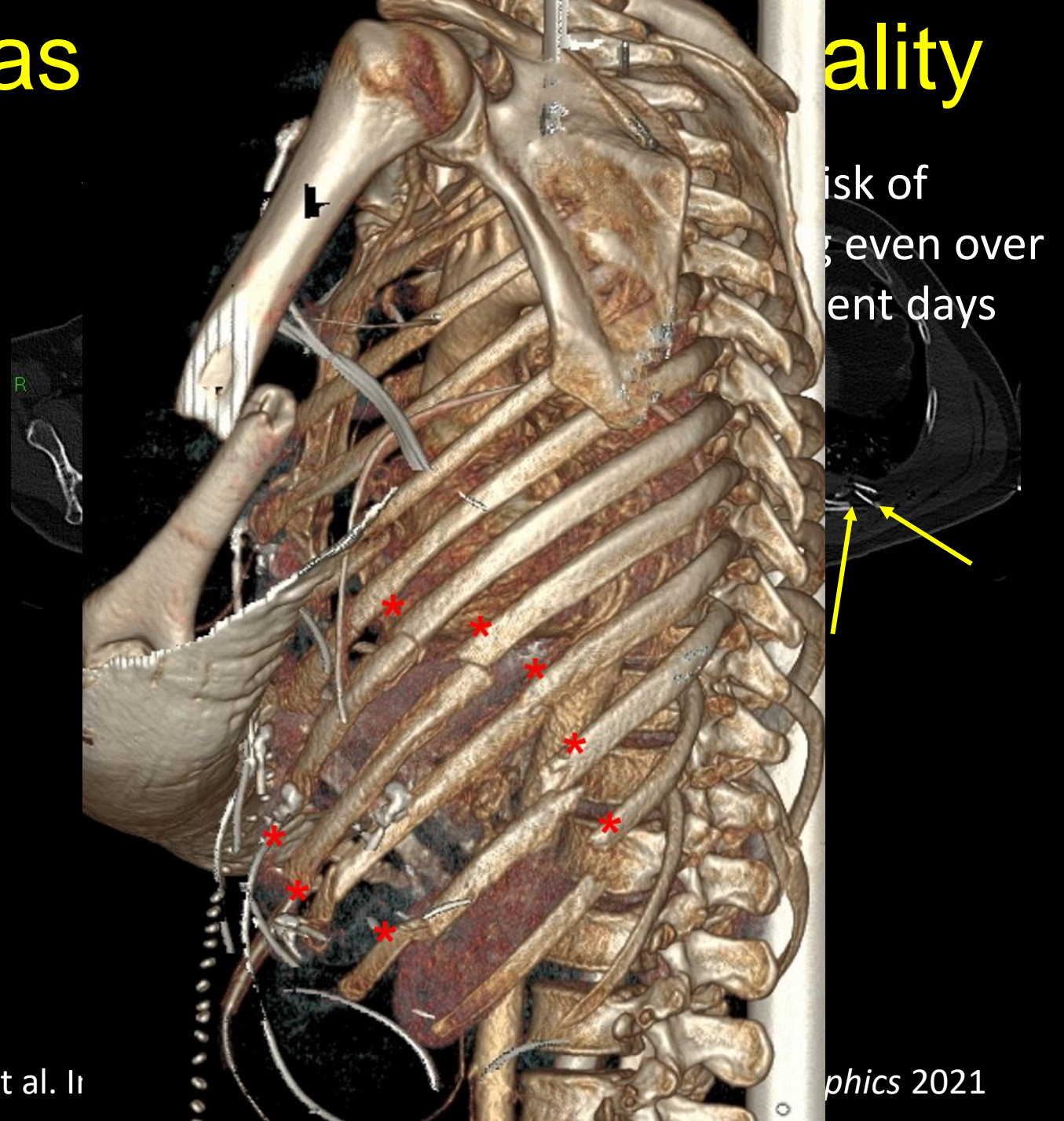
Rib fractures – increased morbidity/ mortality

- First rib
- **Displaced rib fractures**
- Flail segment (2 x 2)
- >3 ribs fractured
- Age >65



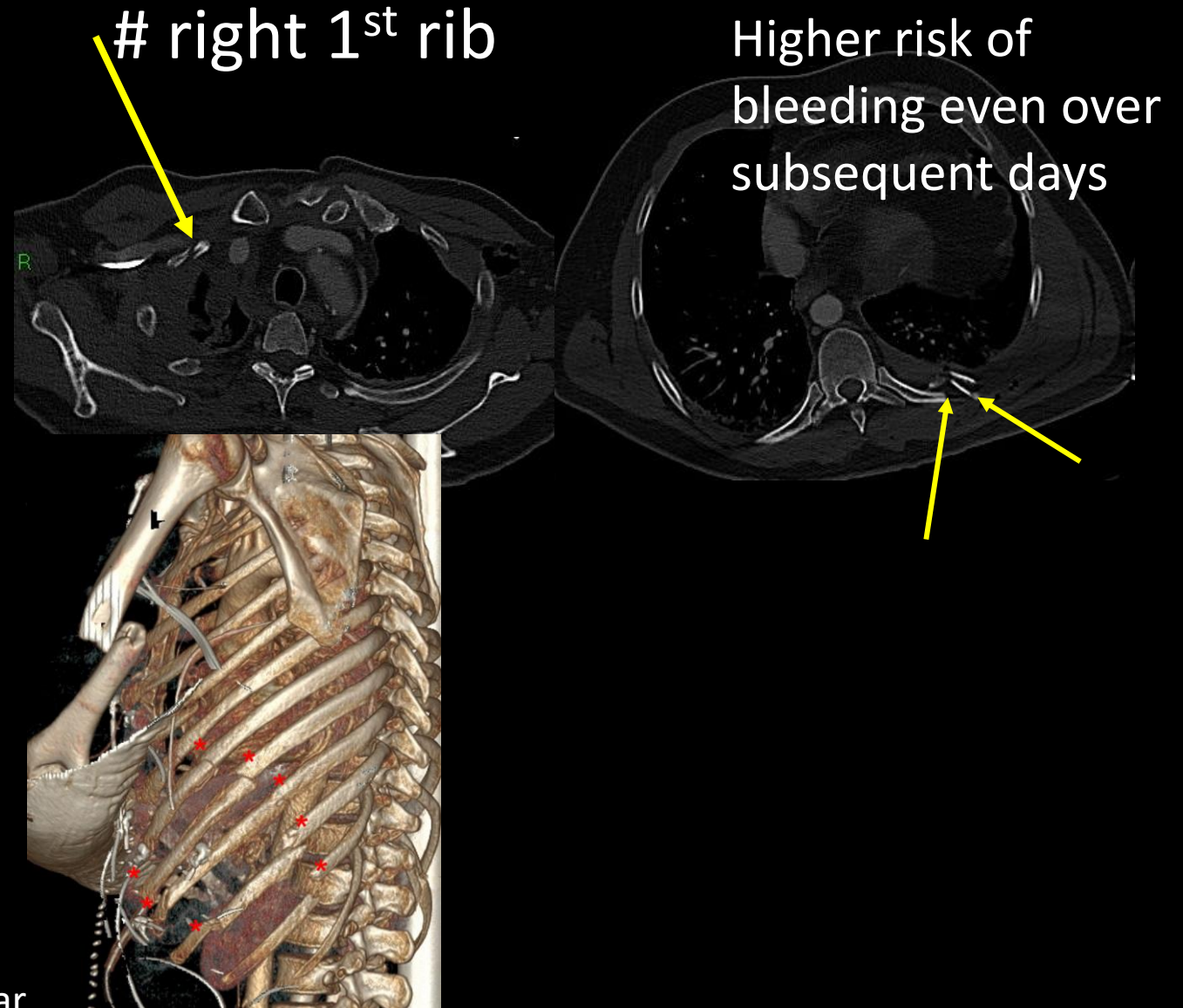
Rib fractures – increases

- First rib
- Displaced rib fractures
- **Flail segment (2 x 2)**
- >3 ribs fractured
- Age >65



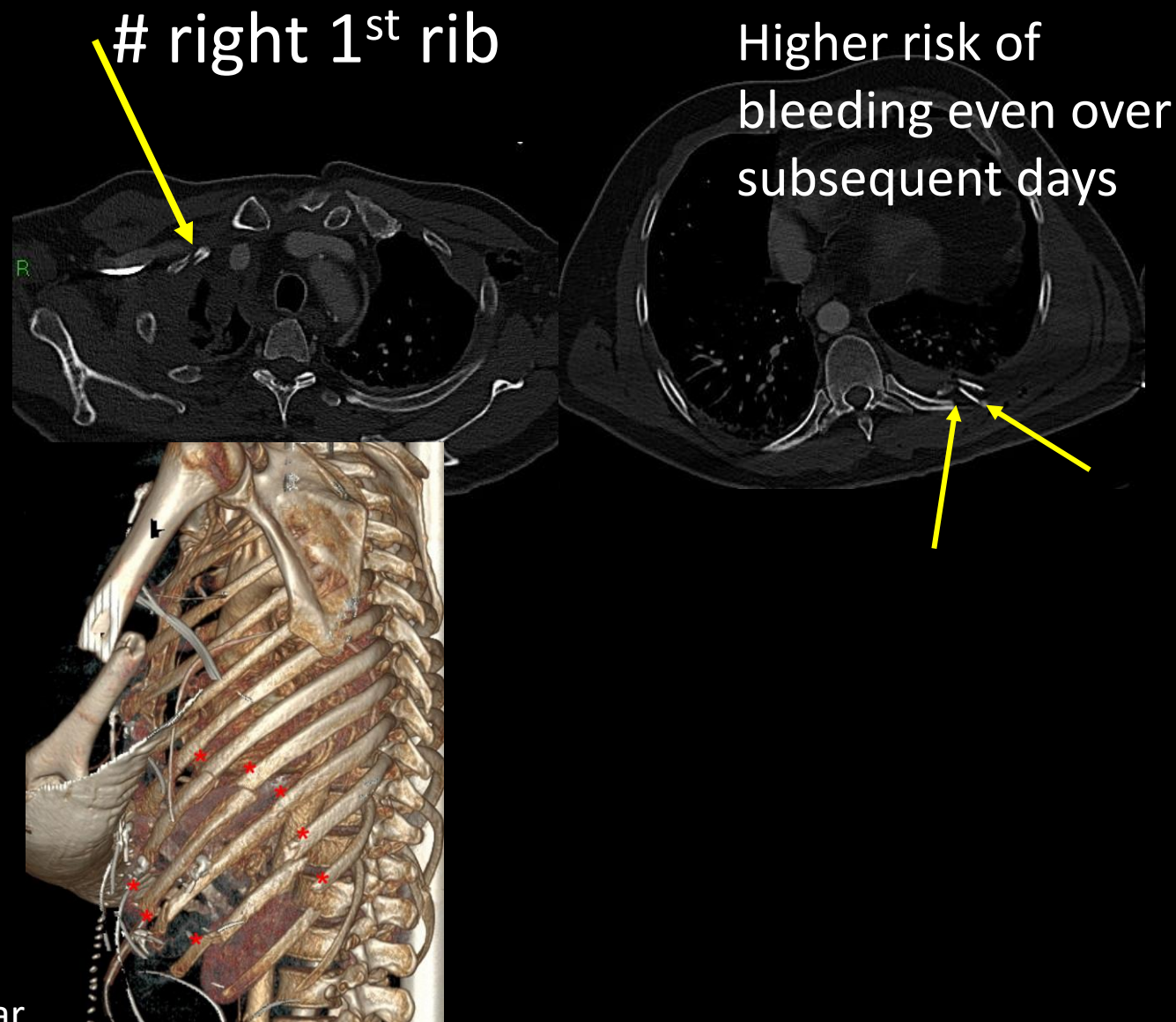
Rib fractures – increased morbidity/ mortality

- First rib
- Displaced rib fractures
- **Flail segment (2 x 2)**
- >3 ribs fractured
- Age >65



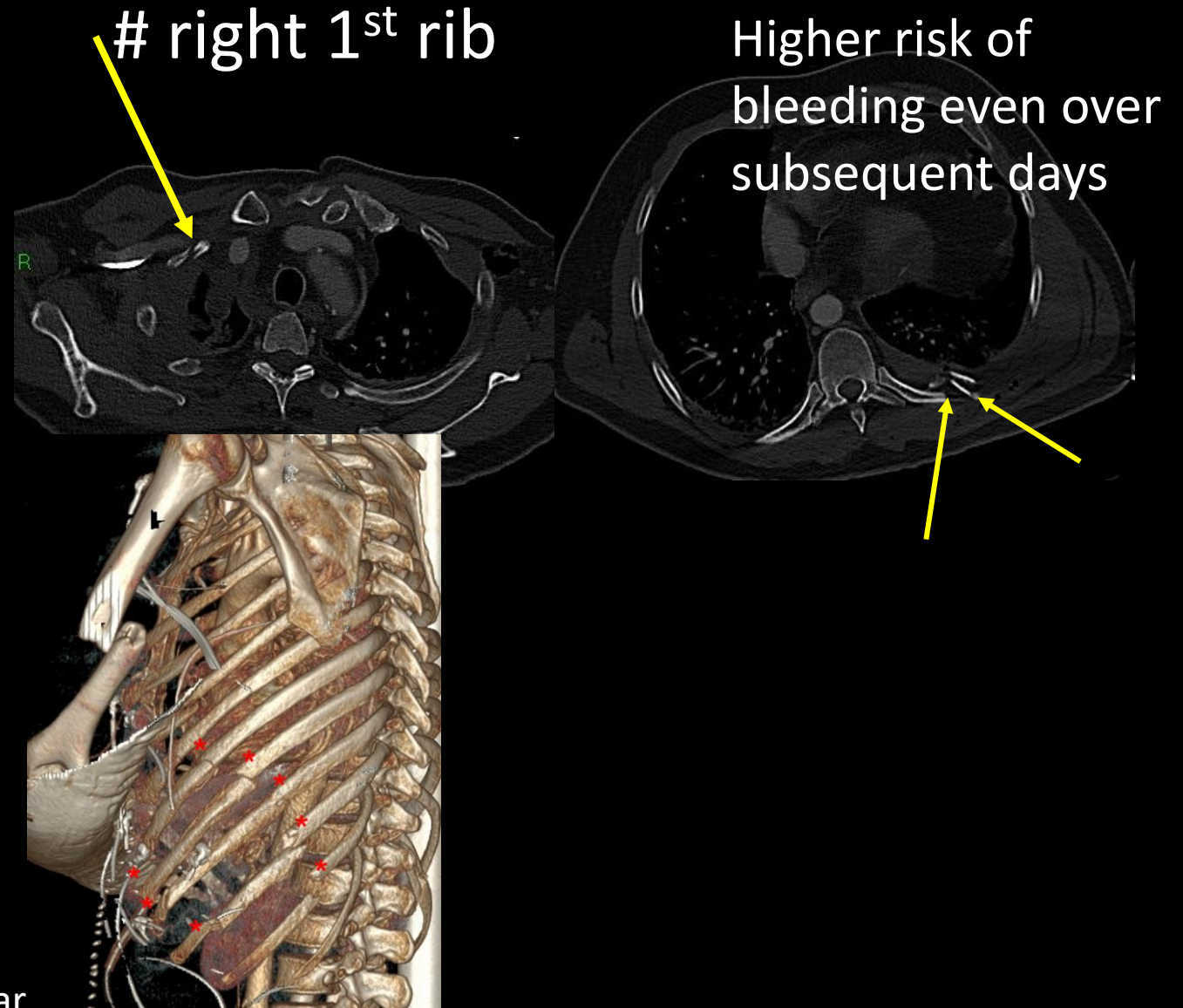
Rib fractures – increased morbidity/ mortality

- First rib
- Displaced rib fractures
- Flail segment (2 x 2)
- >3 ribs fractured
- Age >65



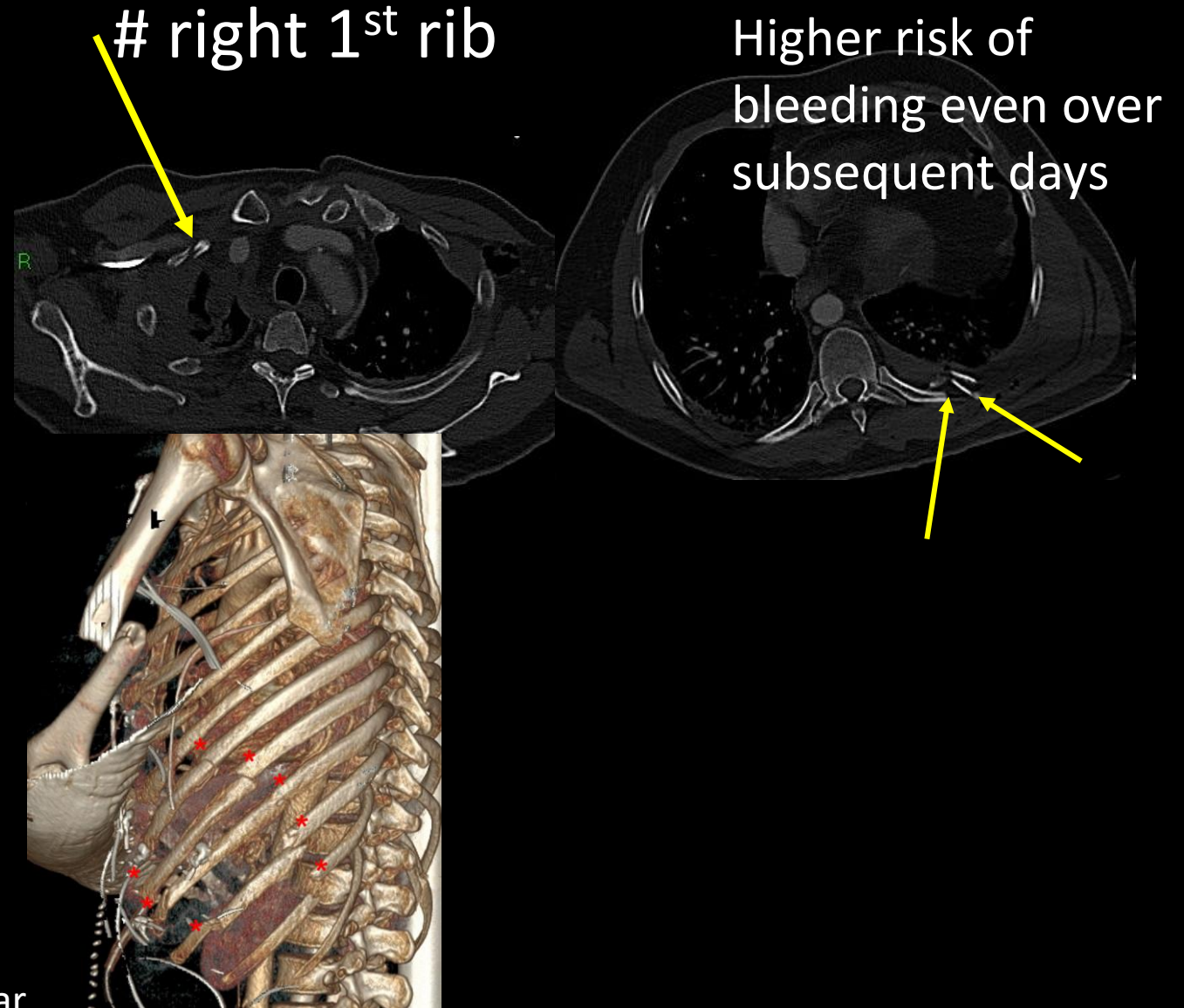
Rib fractures – increased morbidity/ mortality

- First rib
- Displaced rib fractures
- Flail segment (2 x 2)
- **>3 ribs fractured**
- Age >65



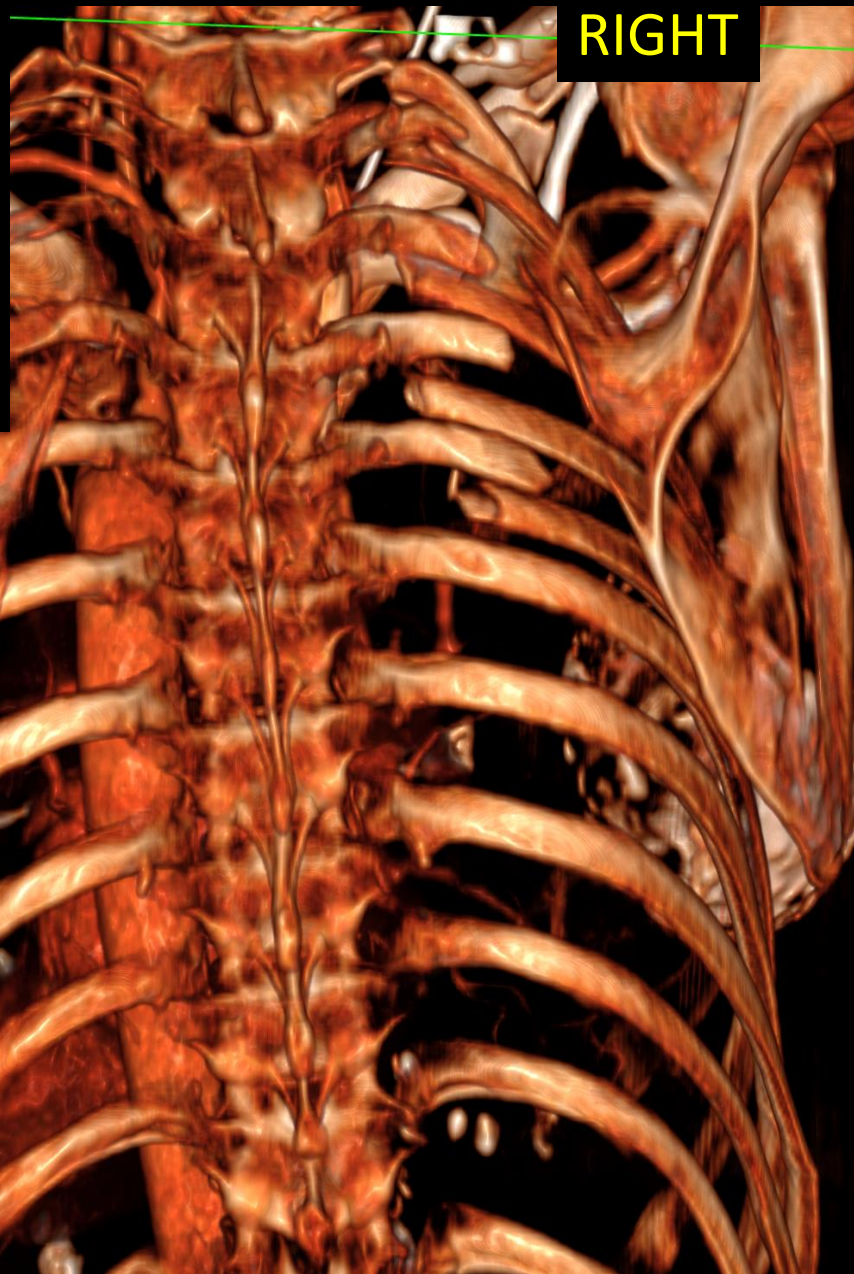
Rib fractures – increased morbidity/ mortality

- First rib
- Displaced rib fractures
- Flail segment (2 x 2)
- >3 ribs fractured
- **Age >65**



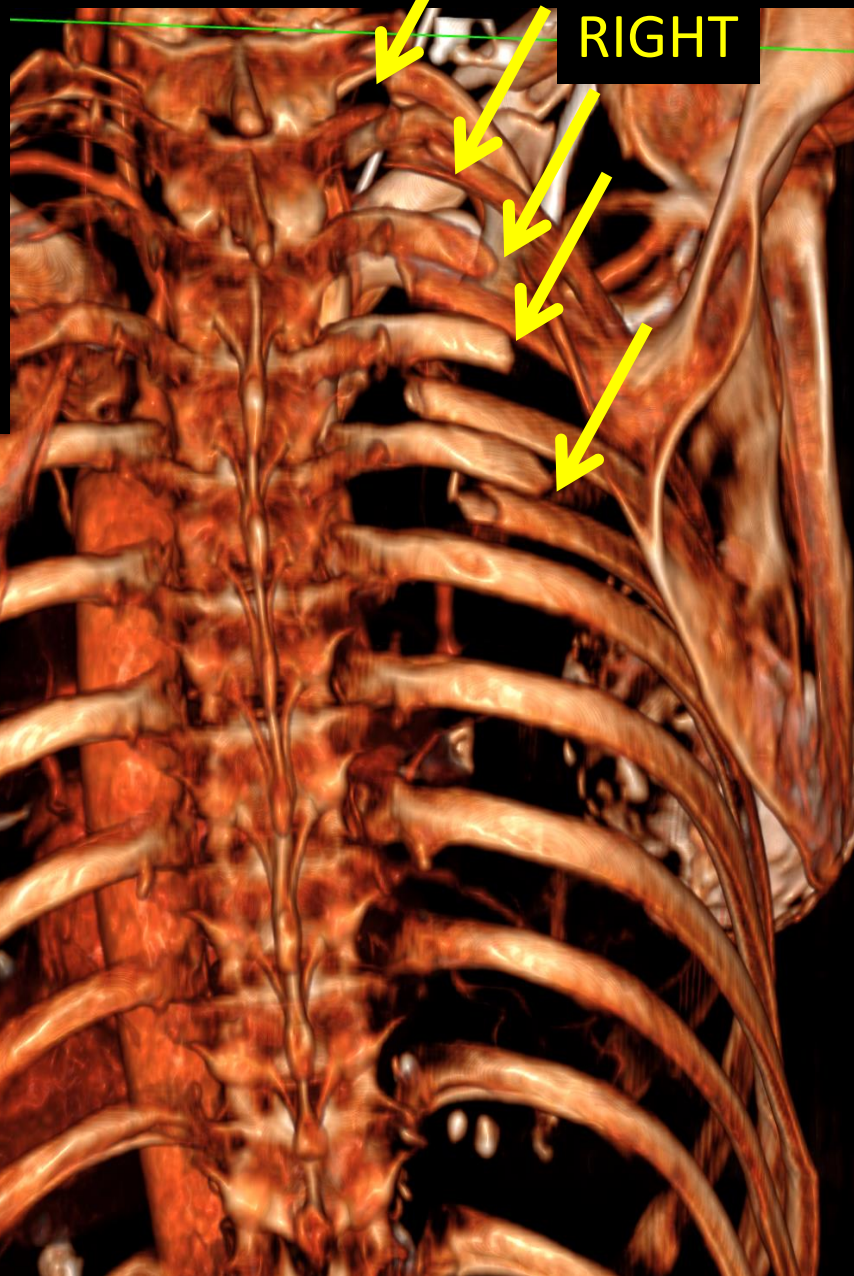
70 yo female,
fall downstairs

R 1st to 5th ribs
R clavicle



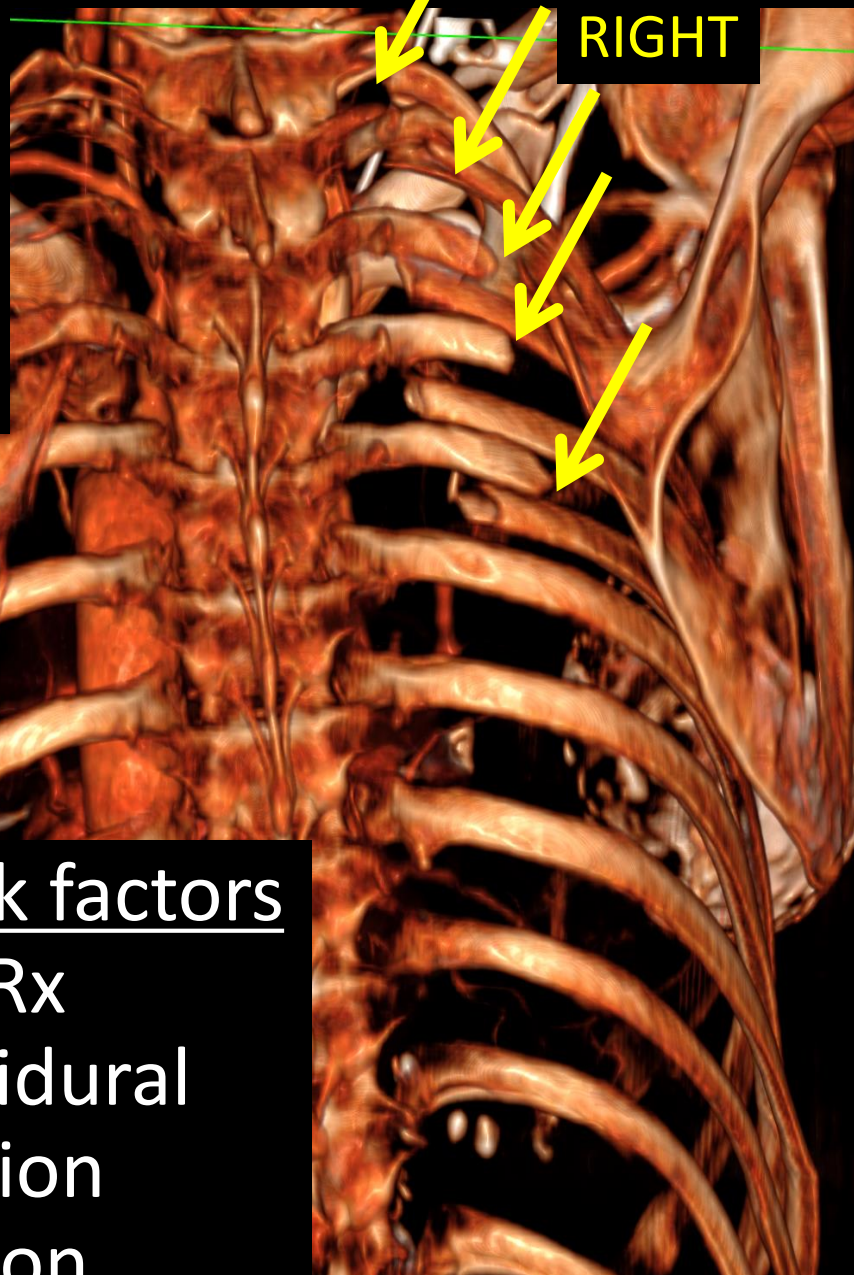
70 yo female,
fall downstairs

R 1st to 5th ribs
R clavicle



70 yo female,
fall downstairs

R 1st to 5th ribs
R clavicle

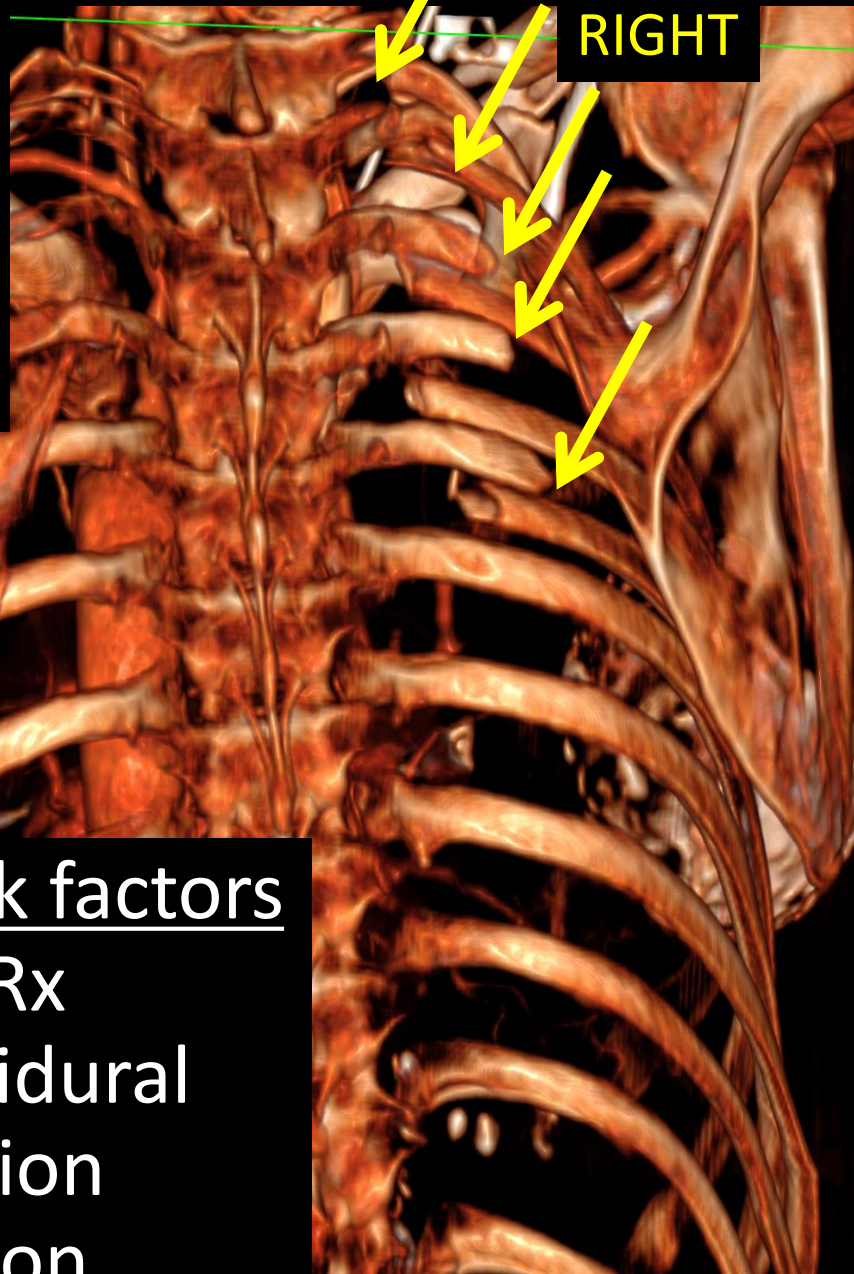


Multiple risk factors

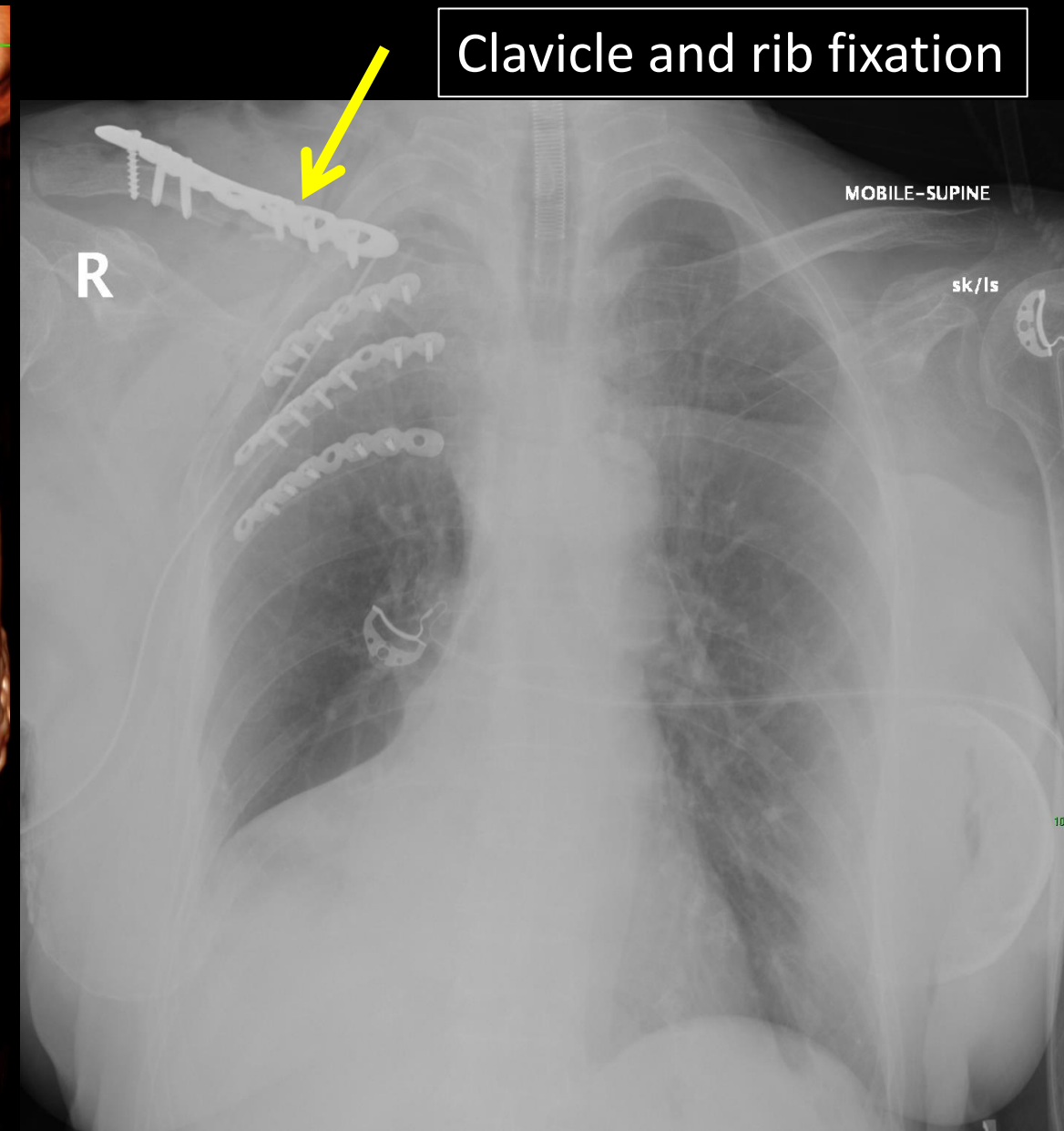
Aggressive Rx
Thoracic Epidural
ICU admission
+/- rib fixation

70 yo female,
fall downstairs

R 1st to 5th ribs
R clavicle

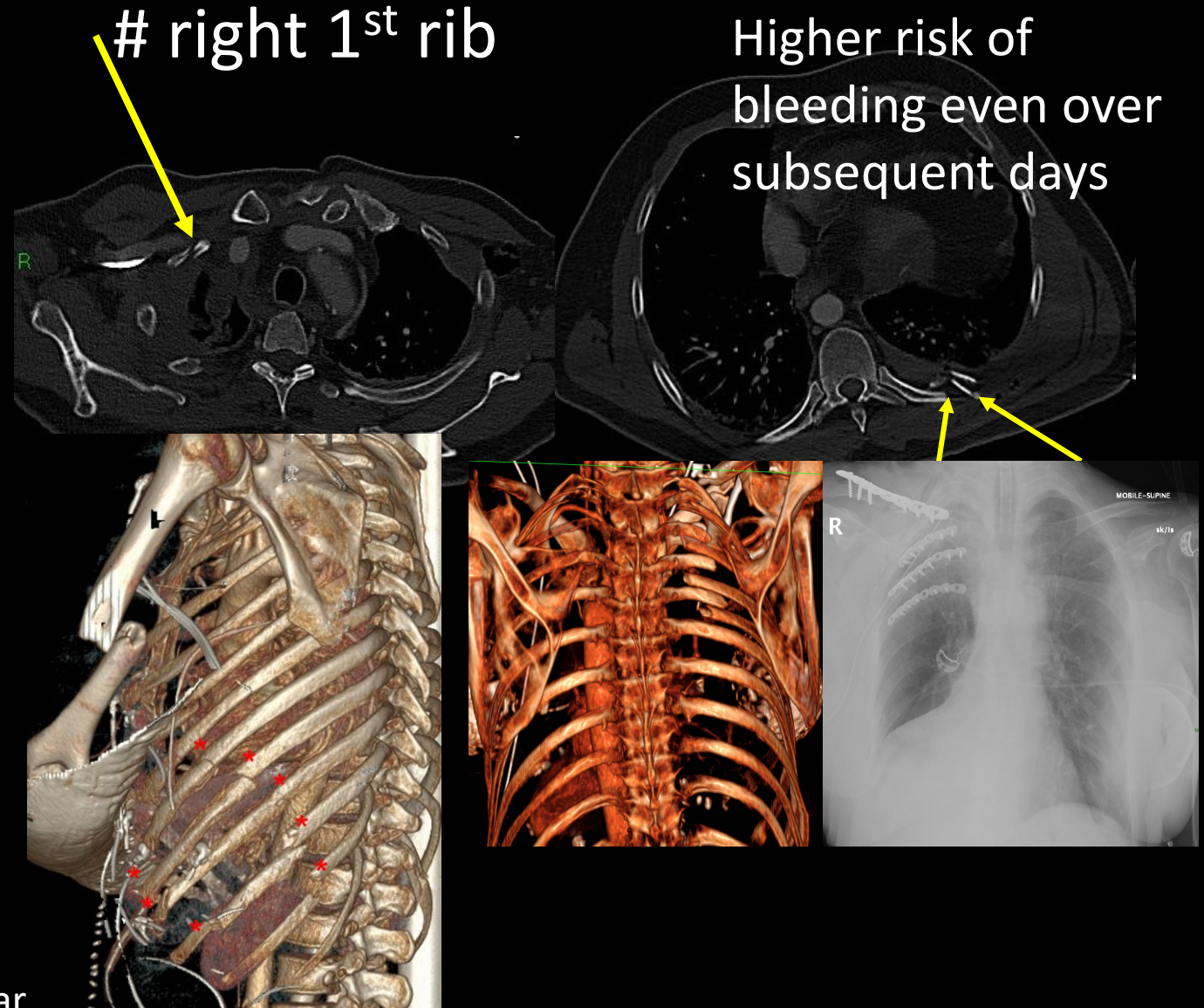


Multiple risk factors
Aggressive Rx
Thoracic Epidural
ICU admission
+/- rib fixation



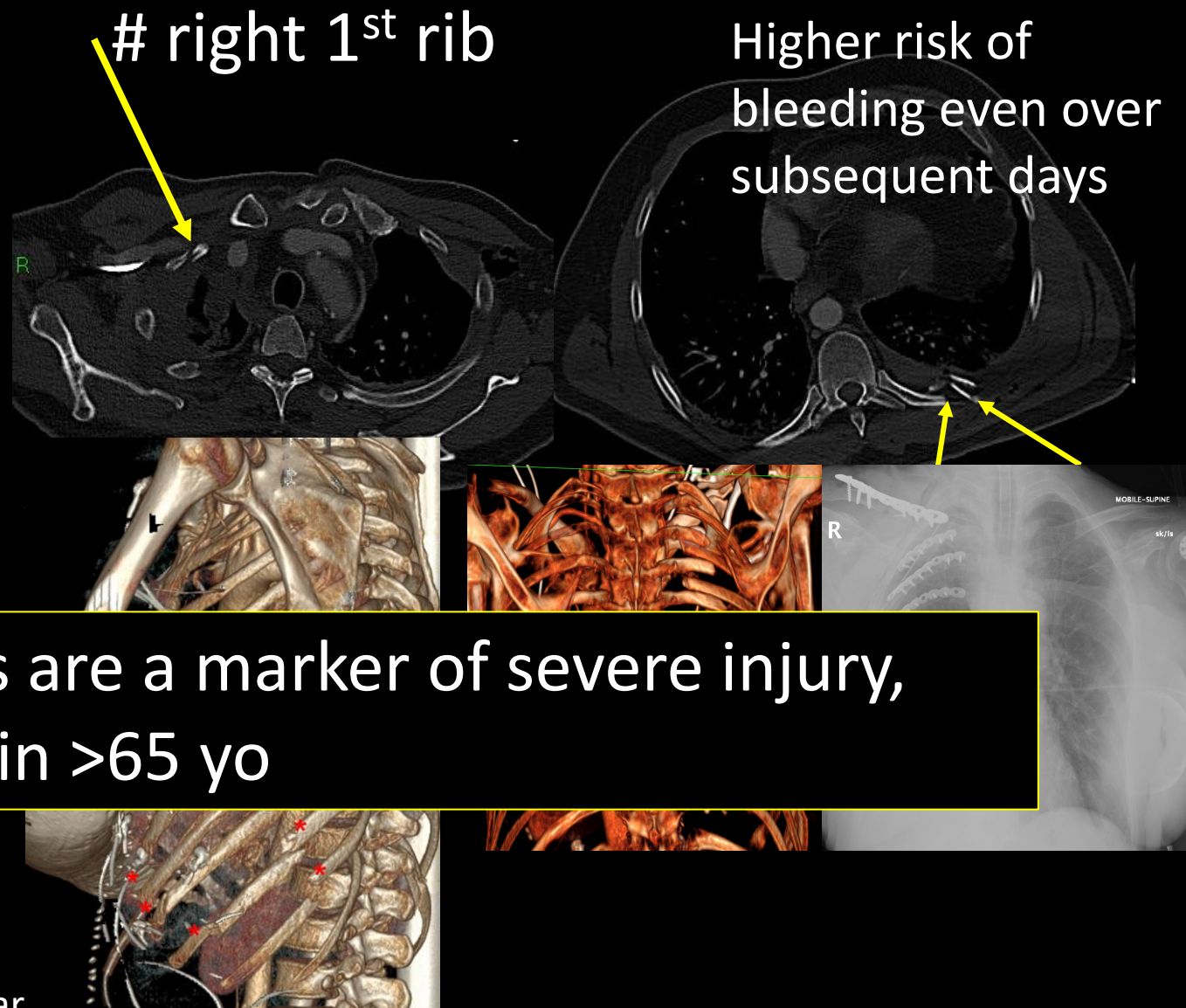Rib fractures – increased morbidity/ mortality

- First rib
- Displaced rib fractures
- Flail segment (2 x 2)
- >3 ribs fractured
- Age >65



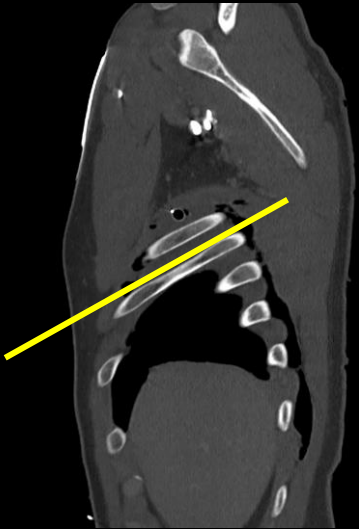
Rib fractures – increased morbidity/ mortality

- First rib
- Displaced rib fractures
- Flail segment (2 x 2)
- >3 ribs fractured
- Age >65



Learning Point: Rib fractures are a marker of severe injury, treat aggressively especially in >65 yo

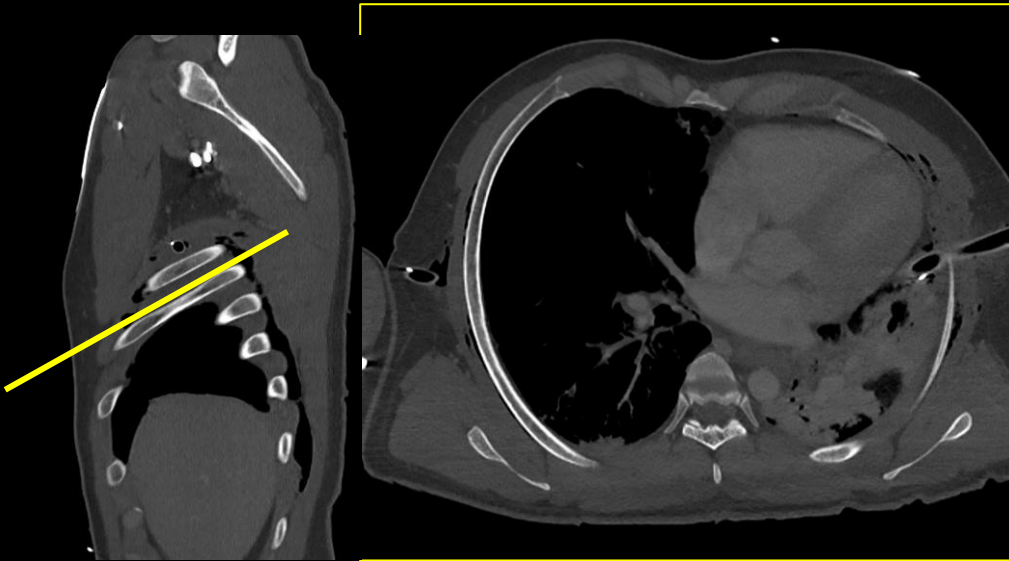
Counting rib fractures.....time consuming but essential



Fukushima, Kambe, Aramaki et al. Heliyon 2023, Evaluation of injury threshold from number of rib fractures

Learning Point: count and record each rib fracture for the patient's Injury Score.

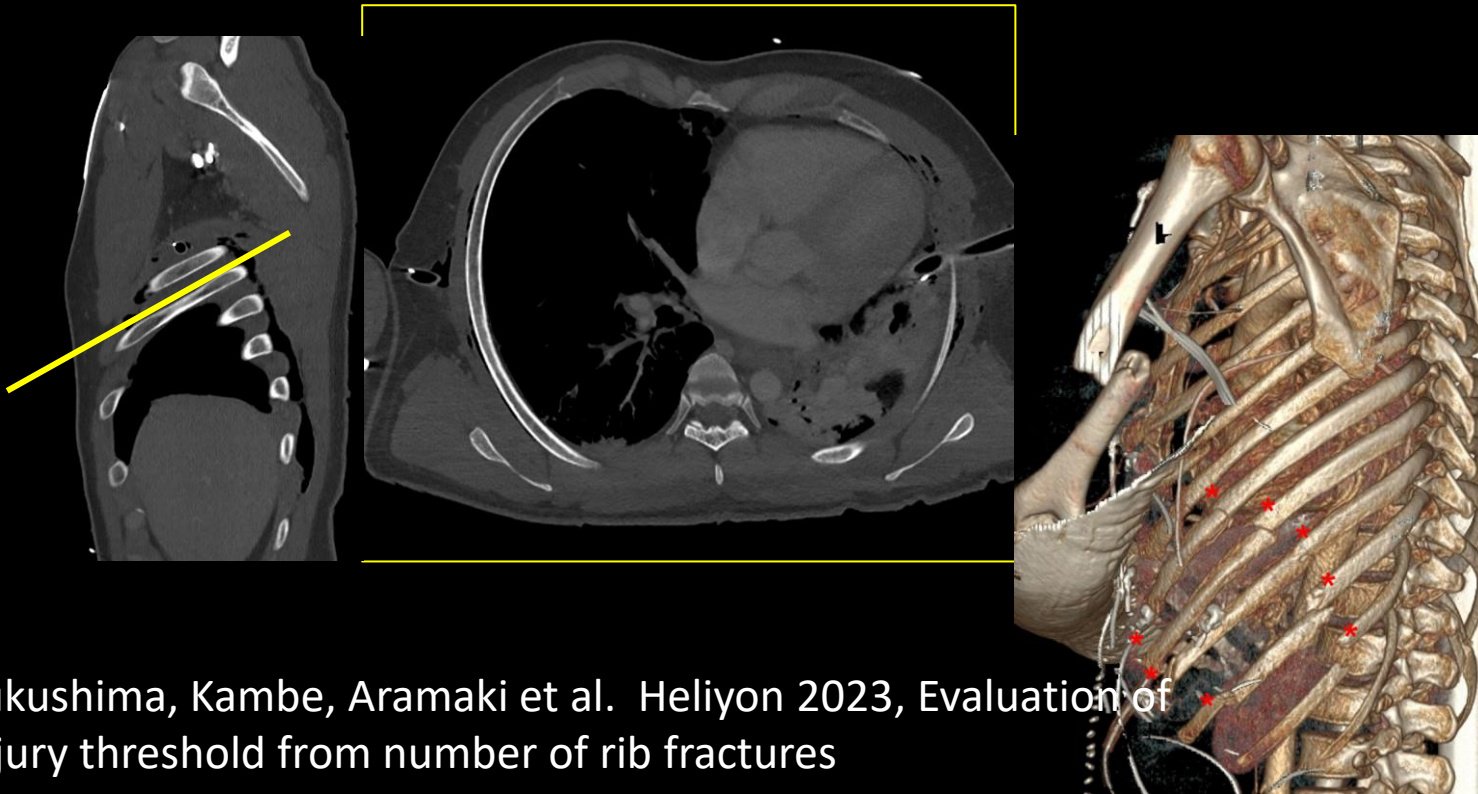
Counting rib fractures.....time consuming but essential



Fukushima, Kambe, Aramaki et al. Heliyon 2023, Evaluation of injury threshold from number of rib fractures

Learning Point: count and record each rib fracture for the patient's Injury Score.

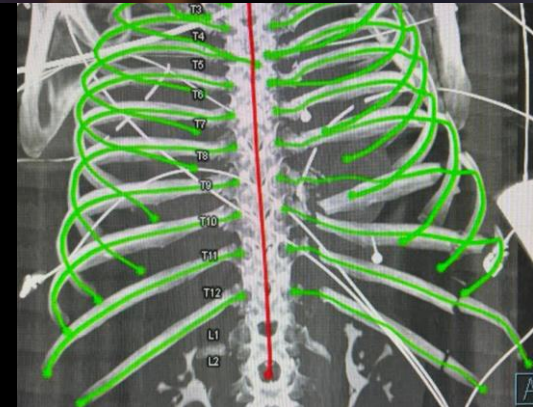

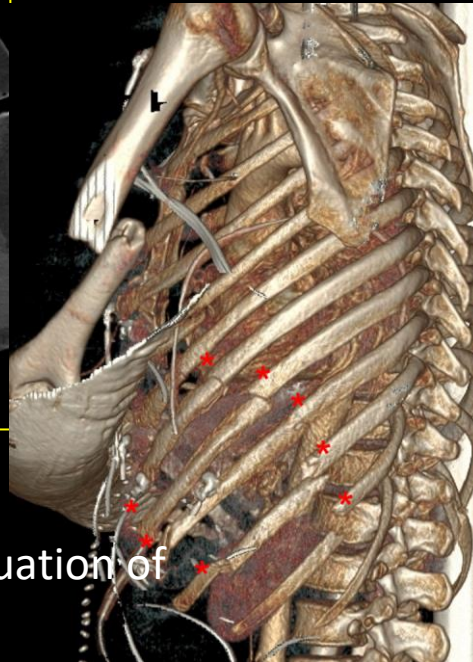
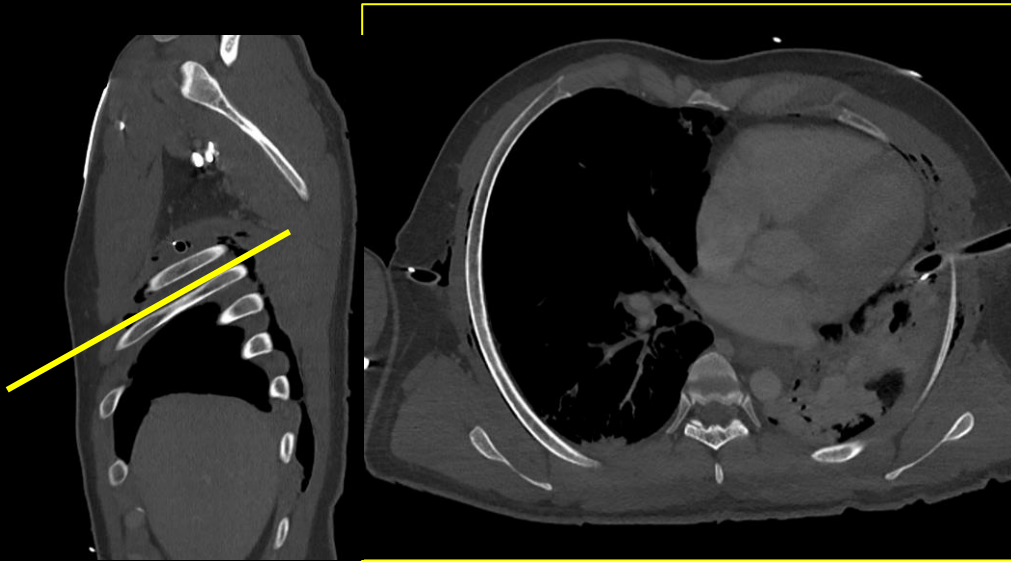
Counting rib fractures.....time consuming but essential



Fukushima, Kambe, Aramaki et al. Heliyon 2023, Evaluation of injury threshold from number of rib fractures

Learning Point: count and record each rib fracture for the patient's Injury Score.

Counting rib fractures.....time consuming but essential



Fukushima, Kambe, Aramaki et al. Heliyon 2023, Evaluation of injury threshold from number of rib fractures

Learning Point: count and record each rib fracture for the patient's Injury Score.

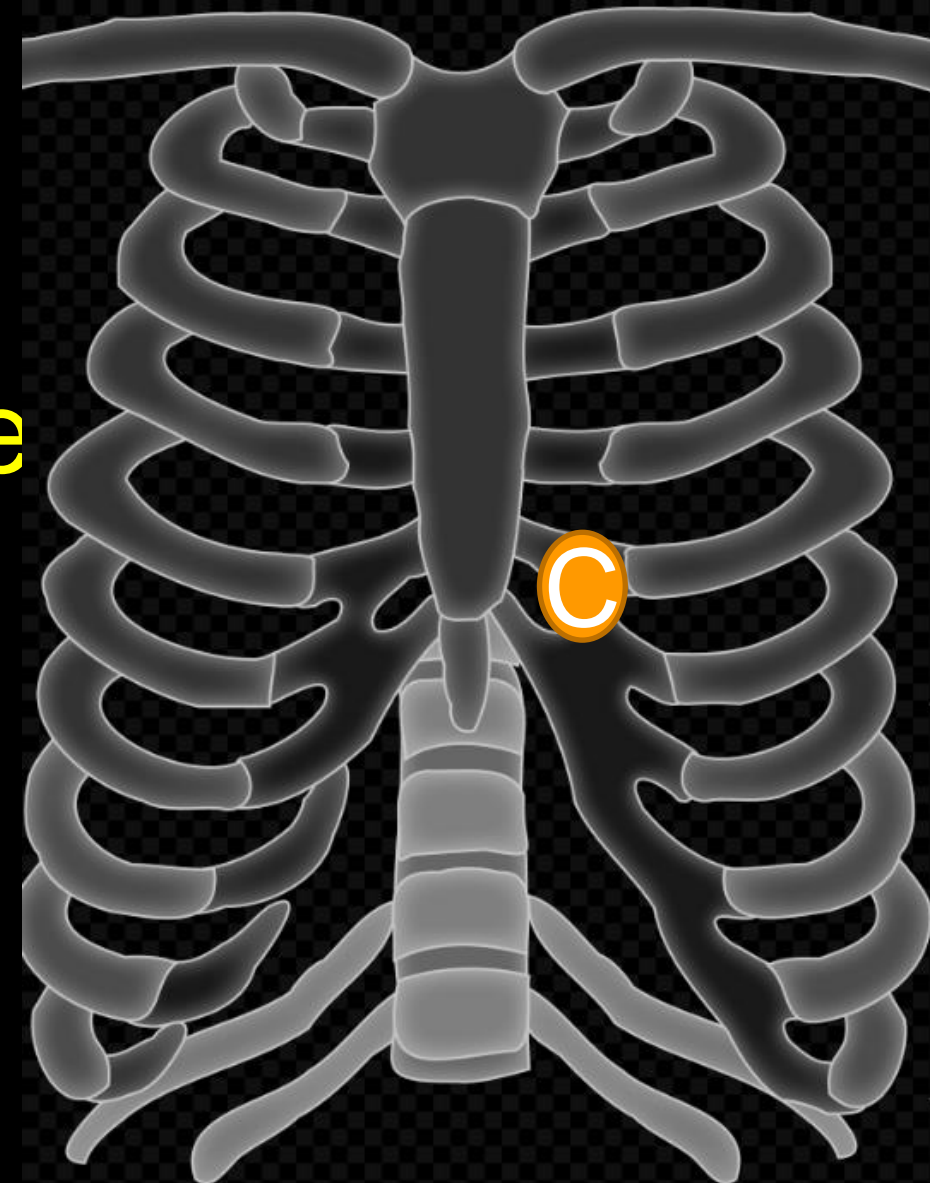
COSTAL CARTILAGE

A airway

B breathing

C chest wall, **costal cartilage**

(3)D diaphragm, disability



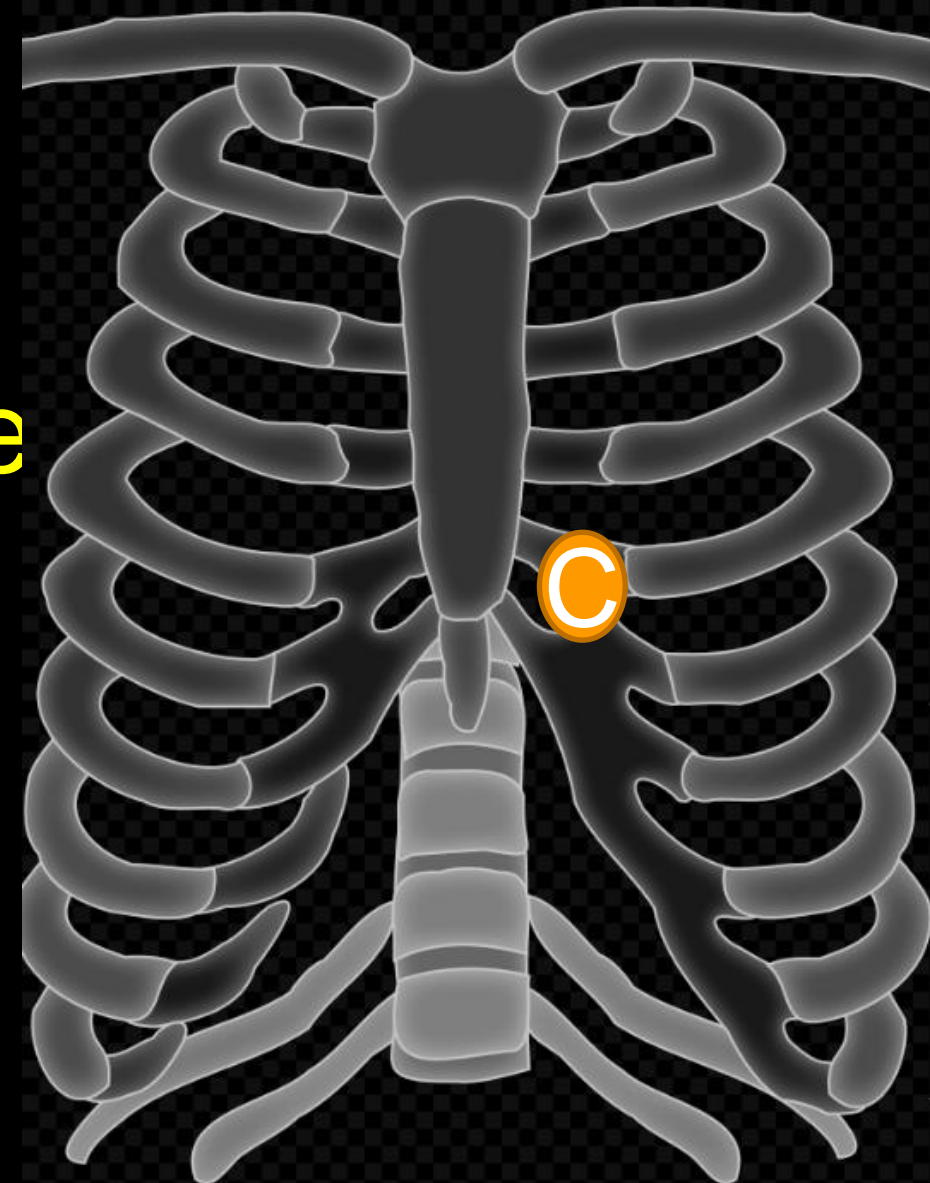
COSTAL CARTILAGE

A airway

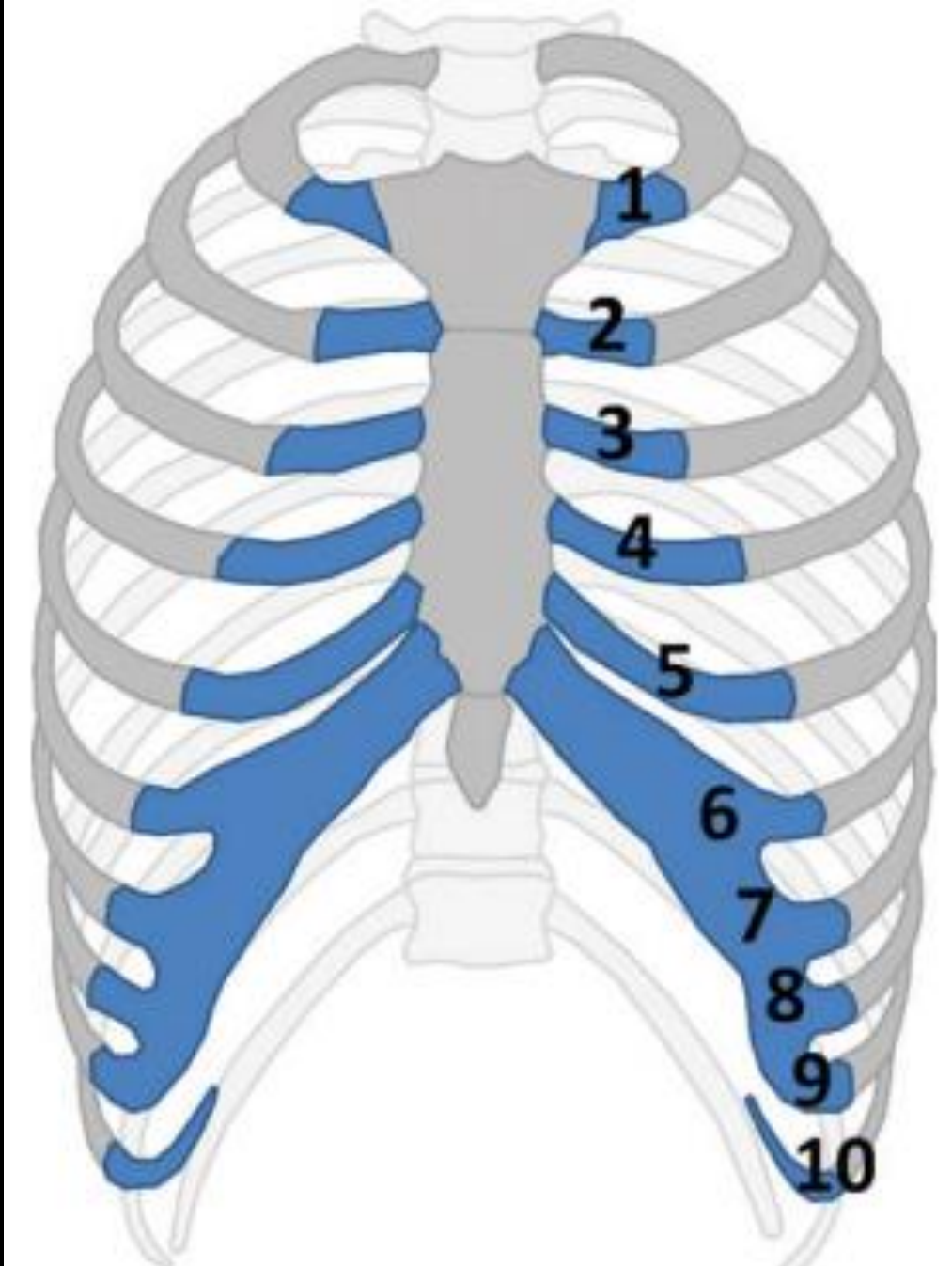
B breathing

C chest wall, **costal cartilage**

(3)D diaphragm, disability



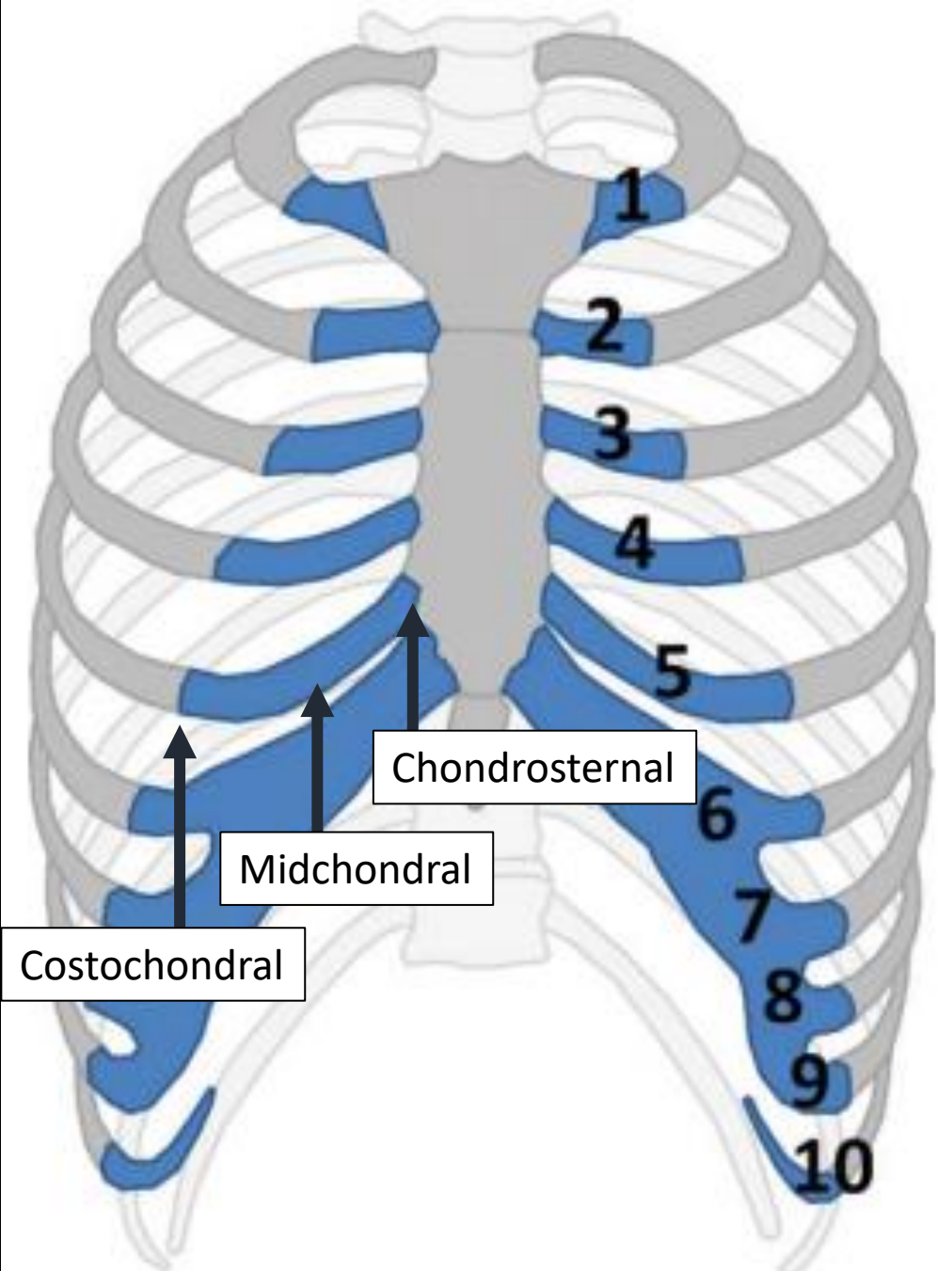
Costal cartilage



1 to 7 insert directly on sternum

8,9 +/-10 attach to costal cartilage

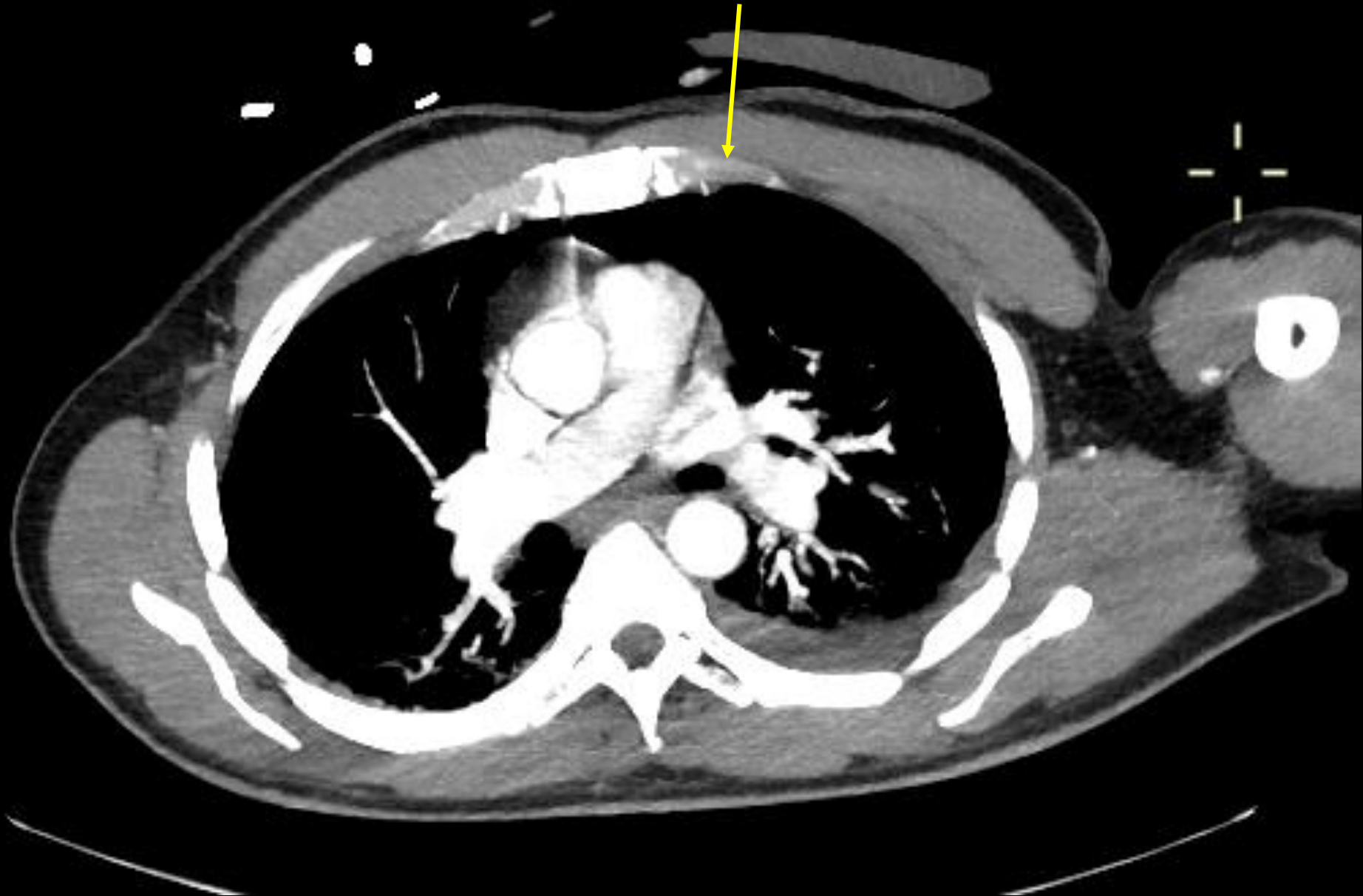Costal cartilage



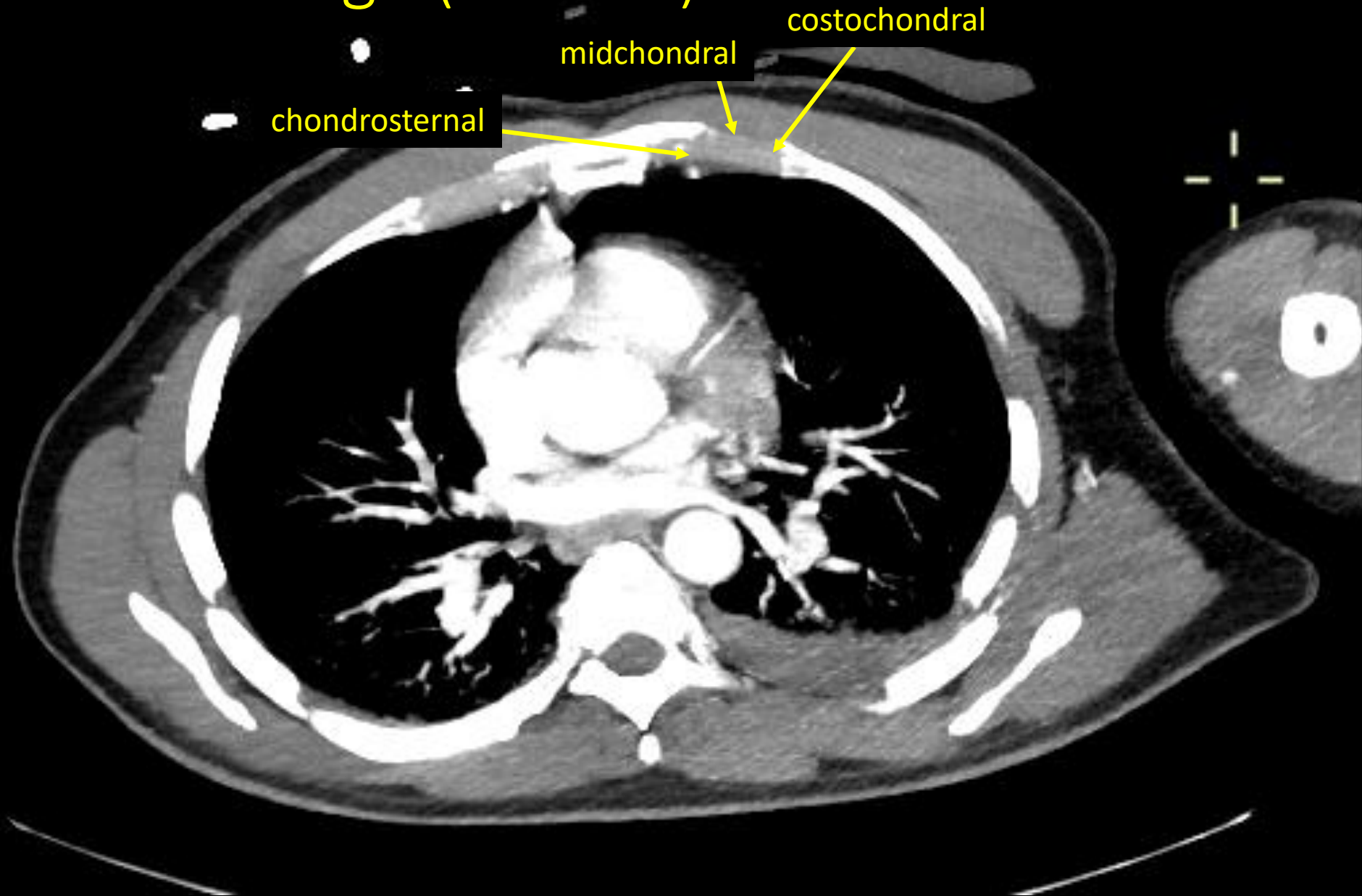
1 to 7 insert directly on sternum

8,9 +/-10 attach to costal cartilage

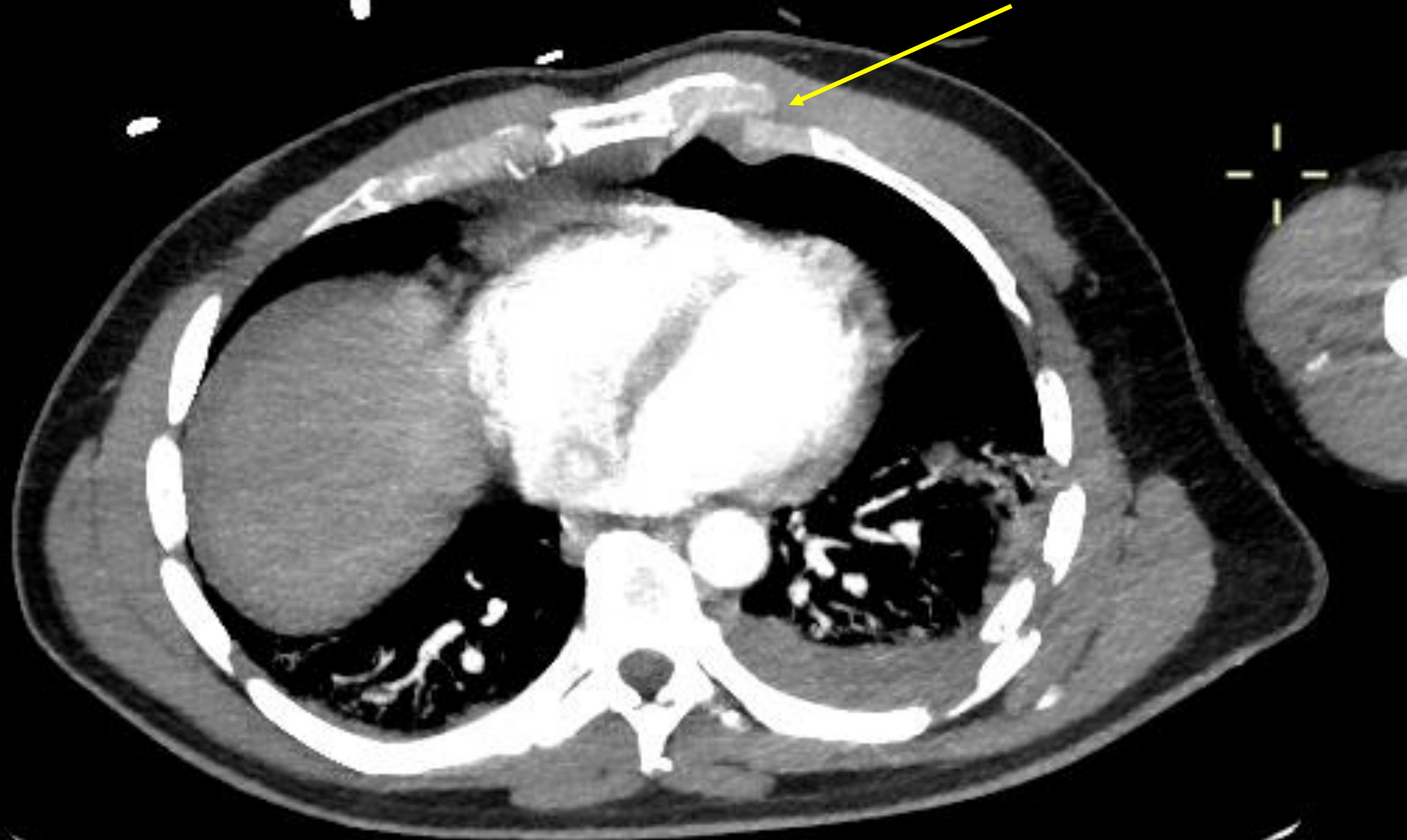
2nd costal cartilage (normal)



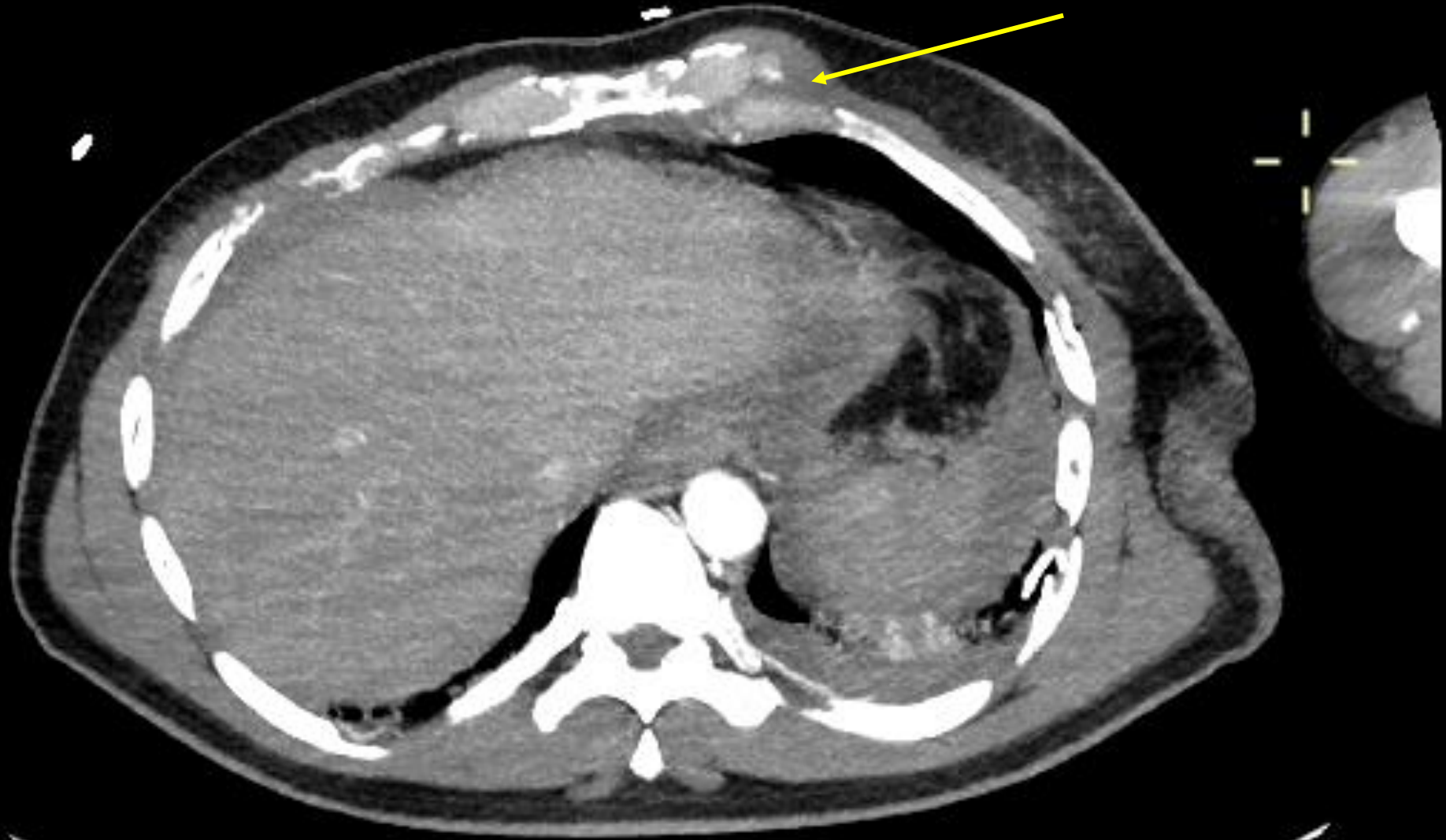3rd costal cartilage (normal)



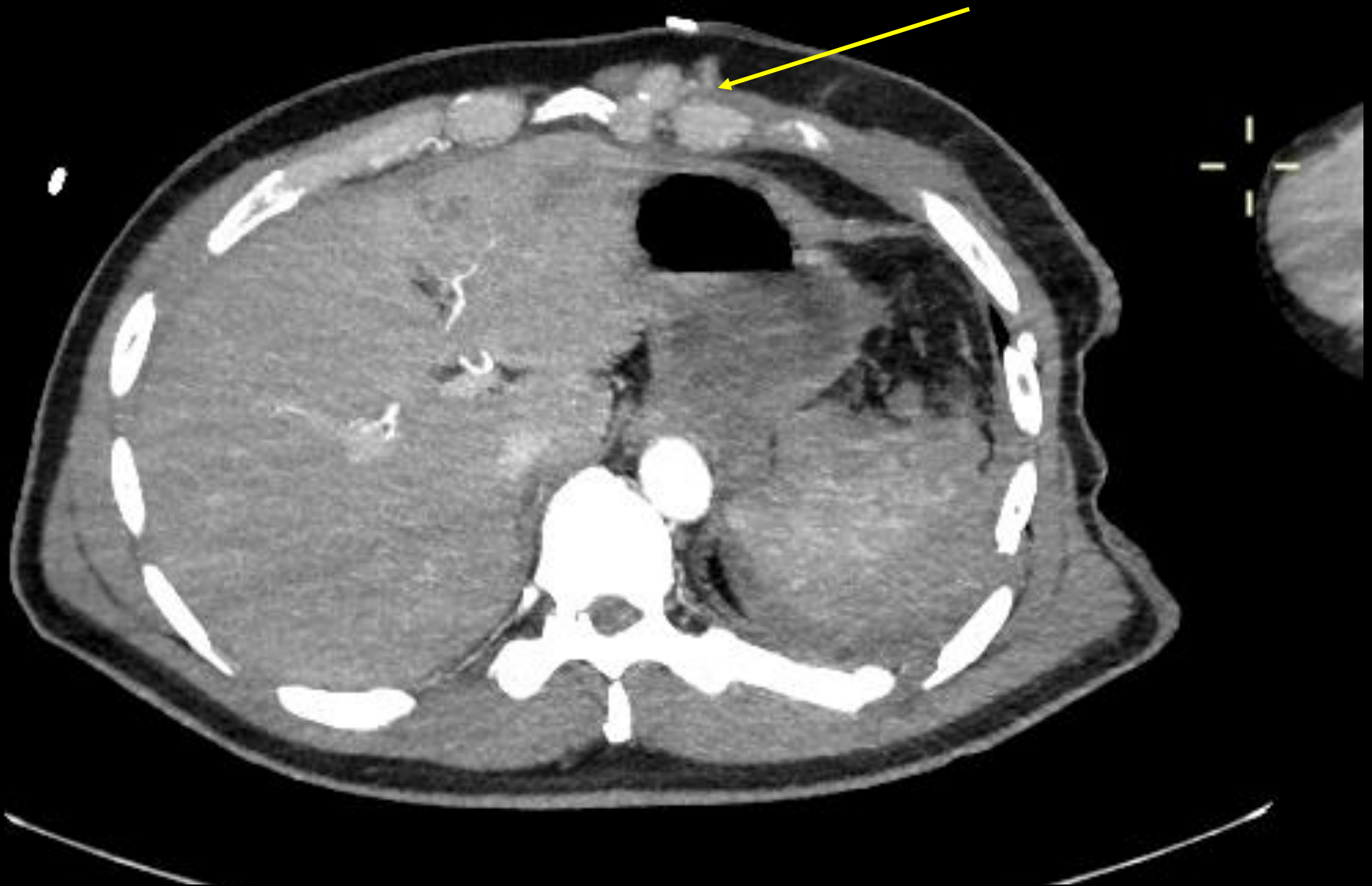4th costal cartilage: mid-chondral #/dislocation



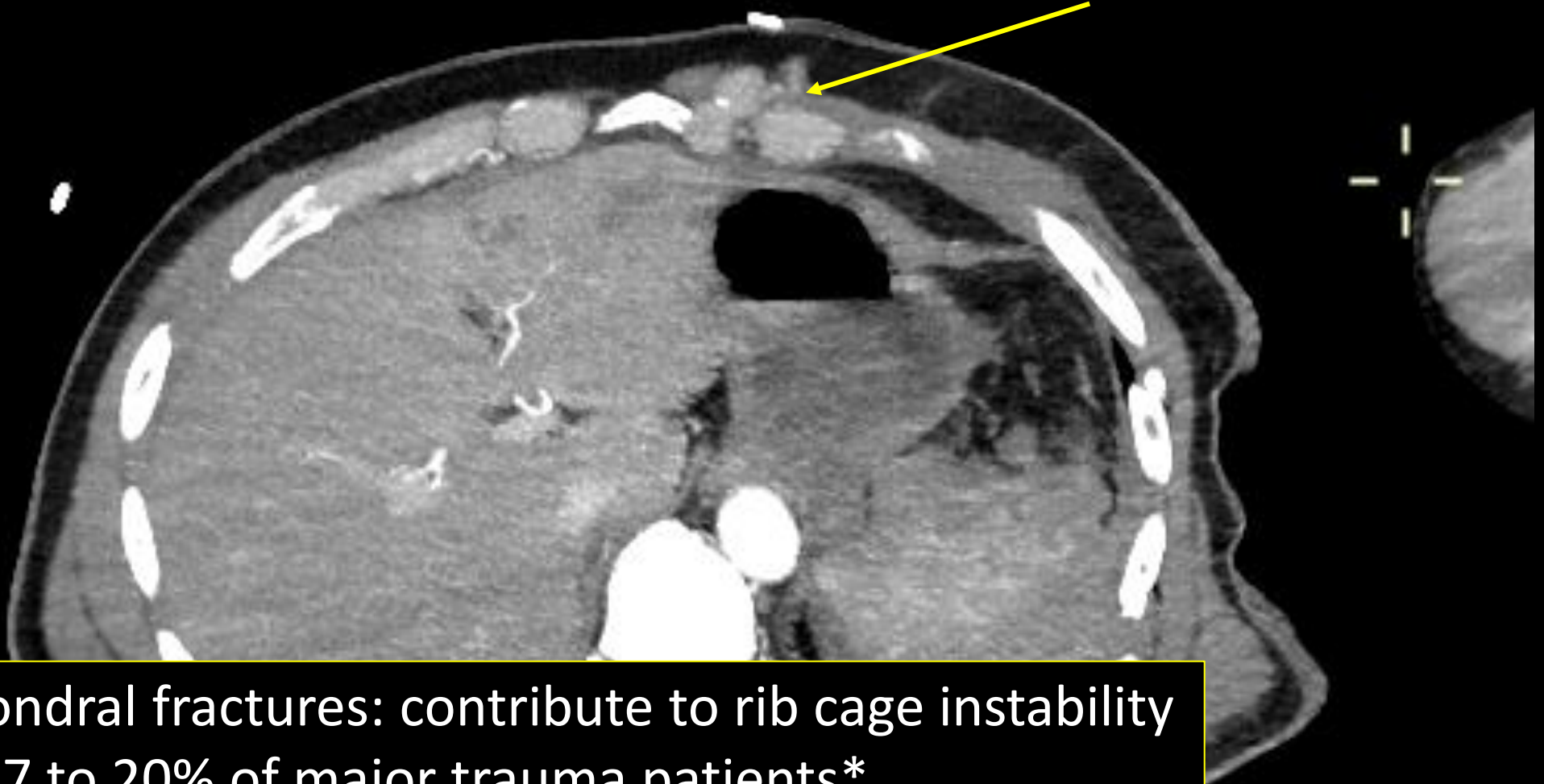
5th costal cartilage: mid-chondral #/dislocation



6th costal cartilage: mid-chondral #/dislocation



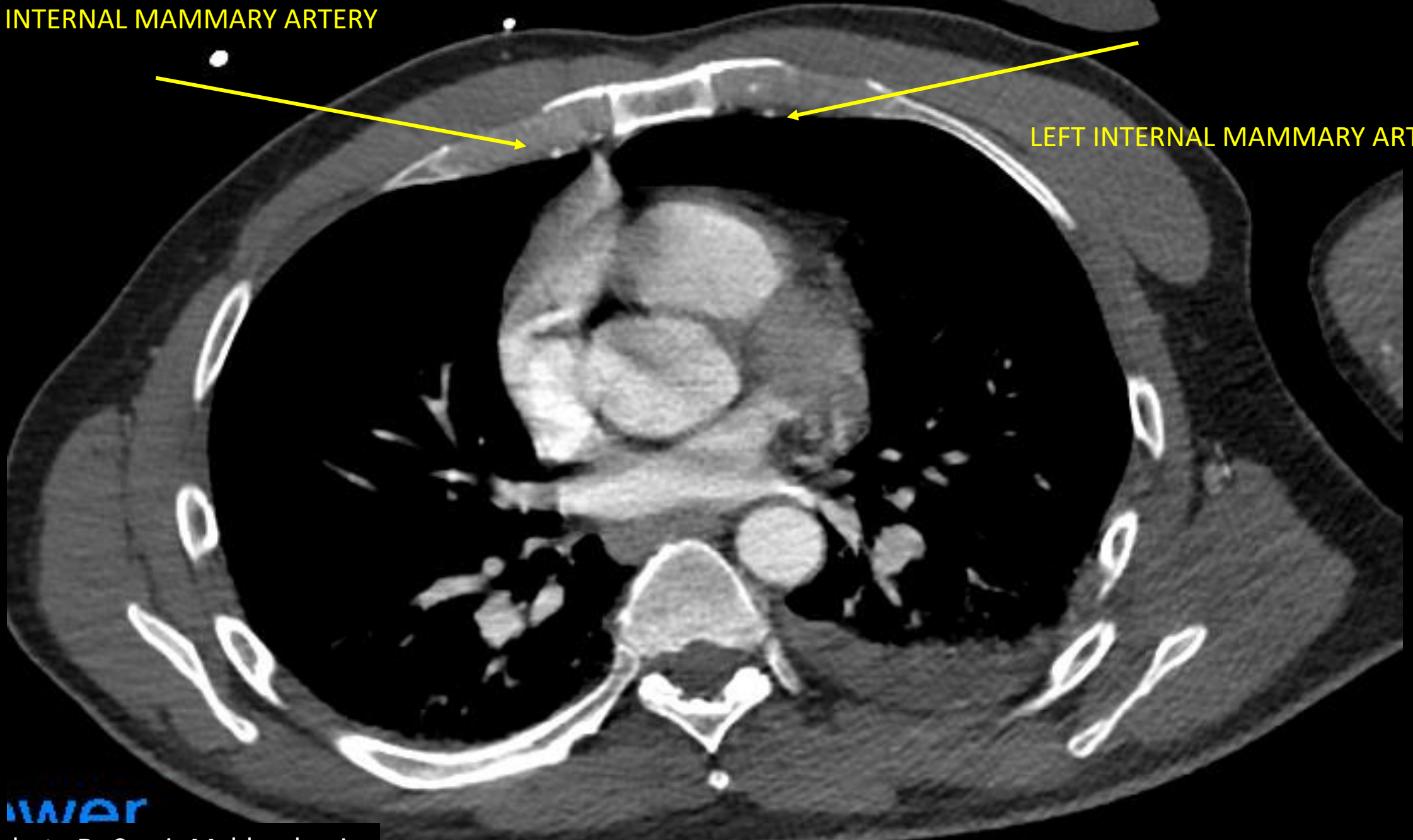
6th costal cartilage: mid-chondral #/dislocation



Costochondral fractures: contribute to rib cage instability
Occur in 7 to 20% of major trauma patients*
Often missed, especially if not displaced

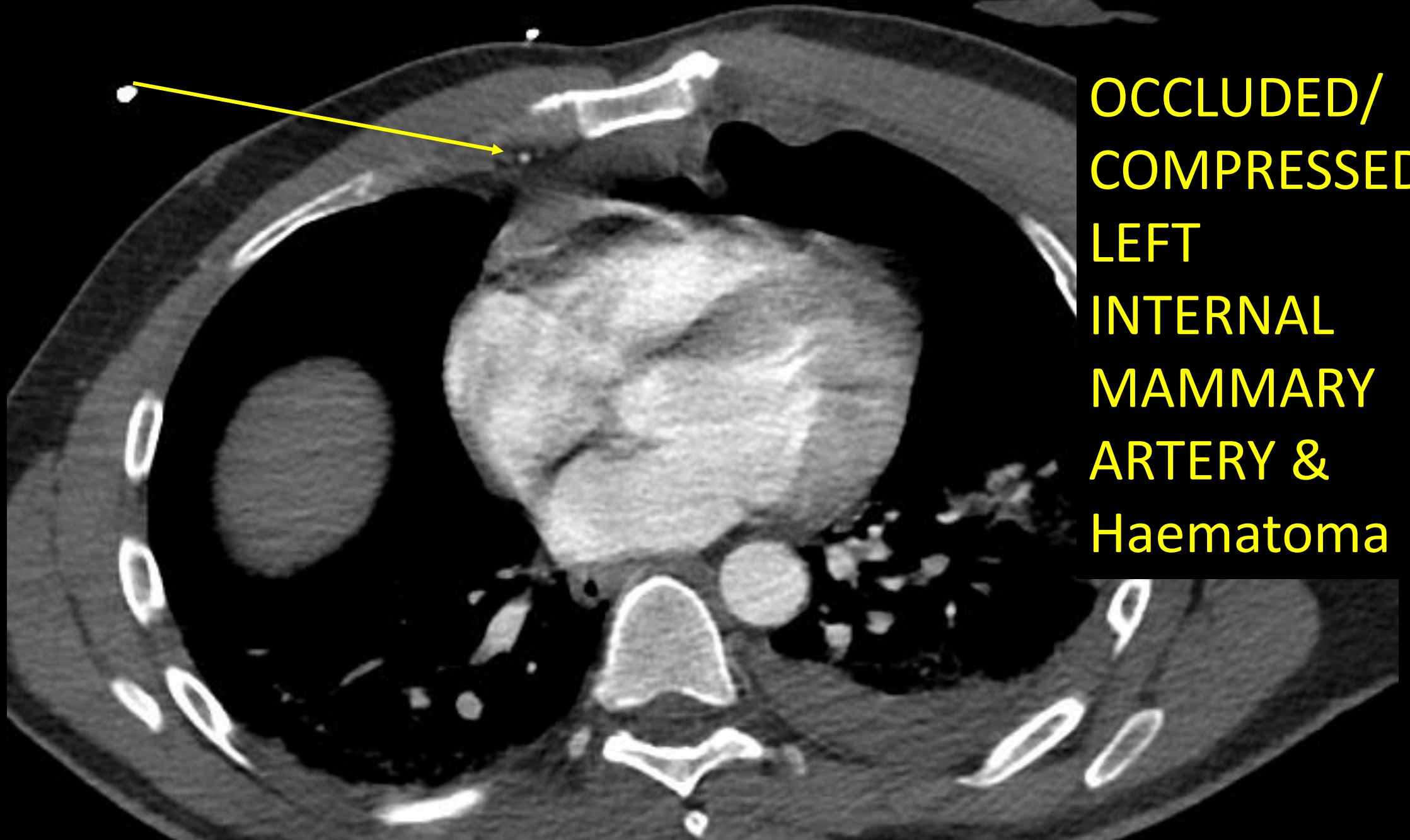
RIGHT INTERNAL MAMMARY ARTERY

LEFT INTERNAL MAMMARY ARTERY

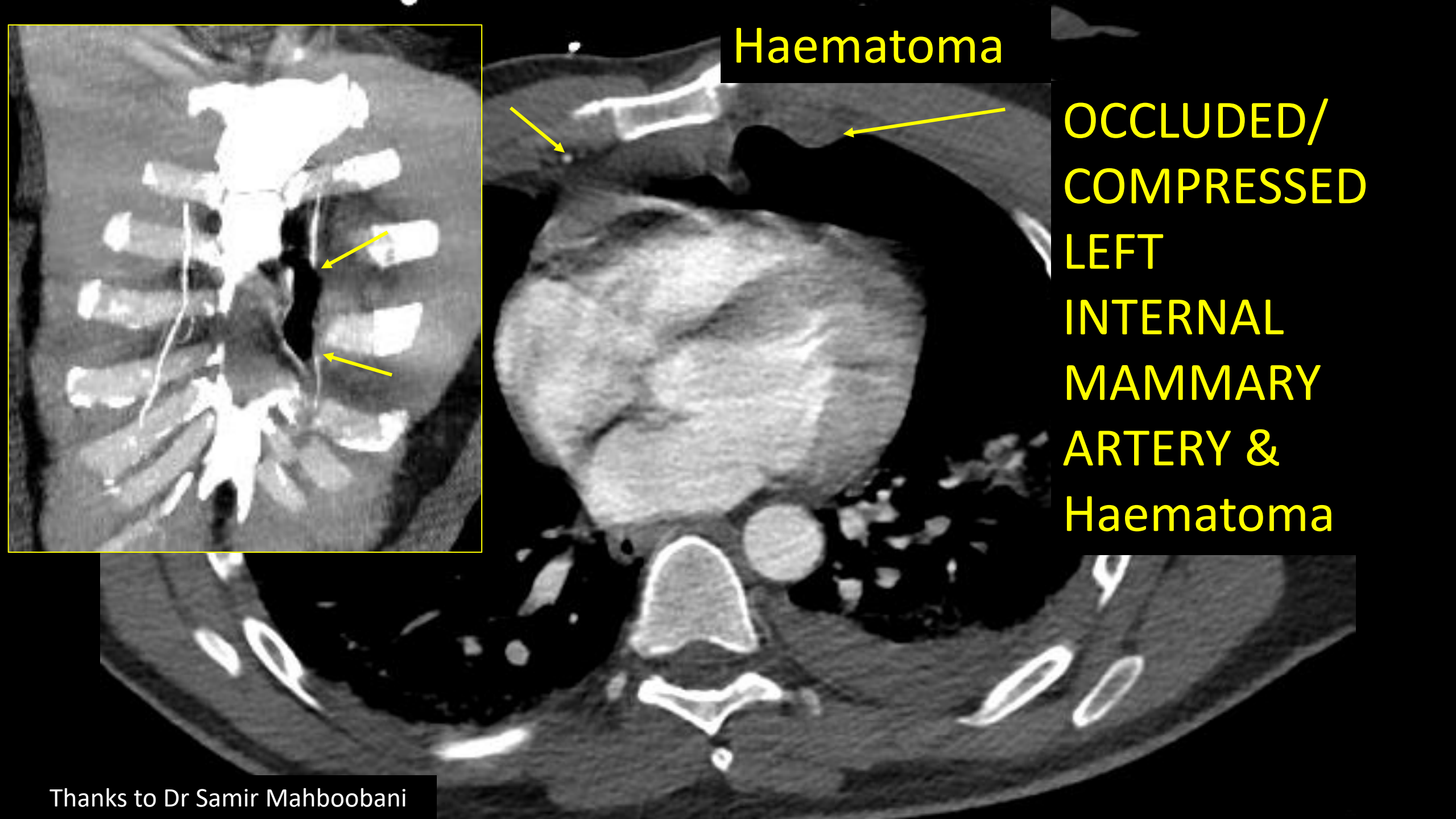


IMAR

Thanks to Dr Samir Mahboobani

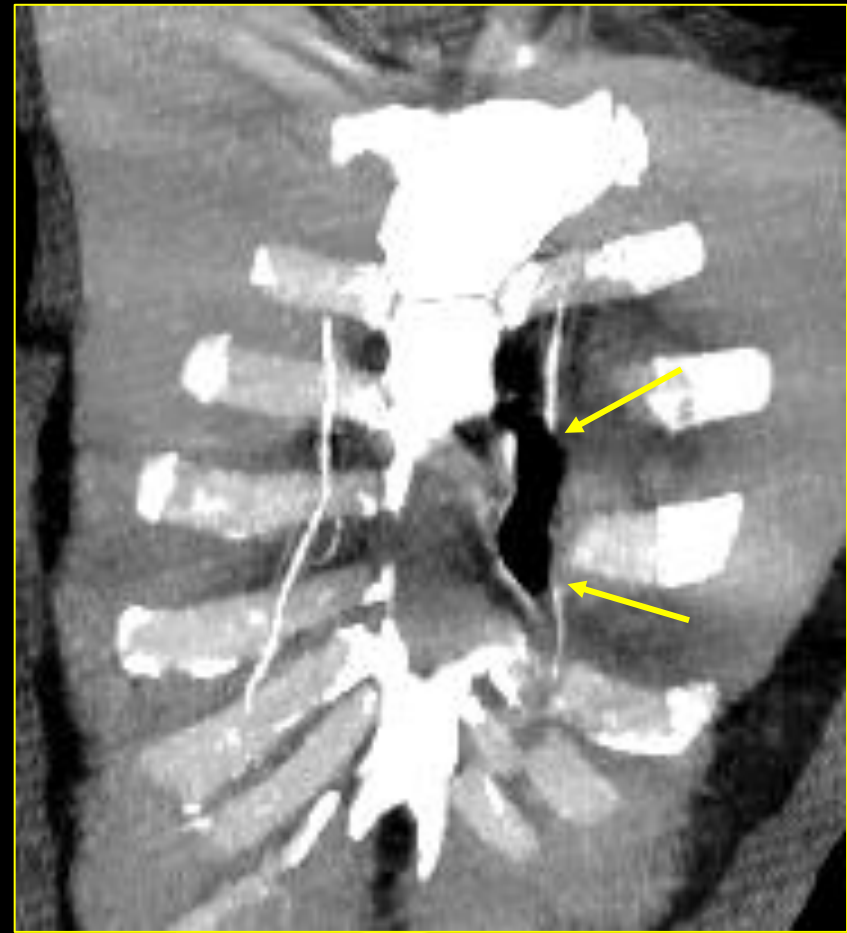


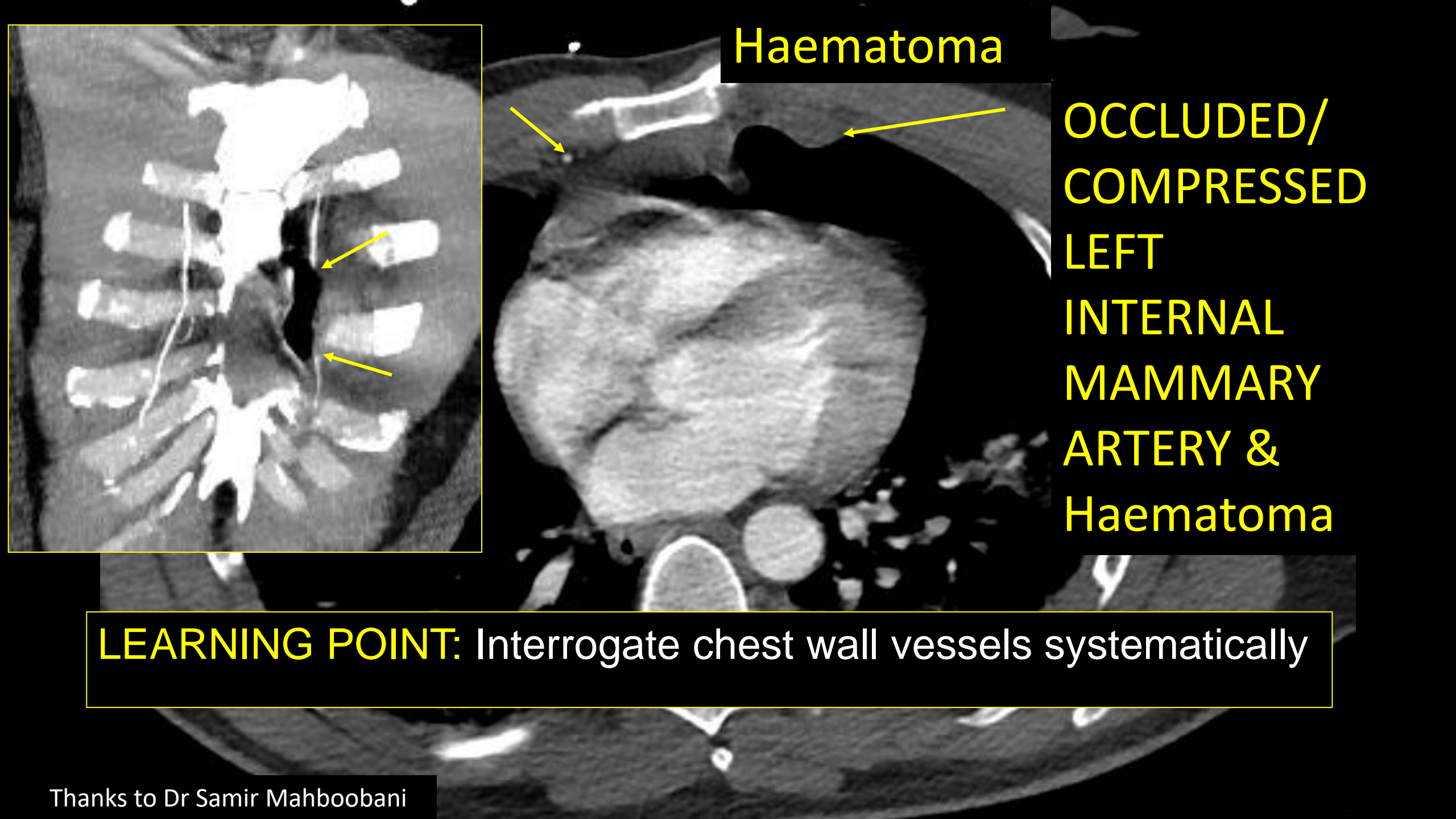
**OCCLUDED/
COMPRESSED
LEFT
INTERNAL
MAMMARY
ARTERY &
Haematoma**



Haematoma

OCCLUDED/
COMPRESSED
LEFT
INTERNAL
MAMMARY
ARTERY &
Haematoma





Haematoma

OCCLUDED/
COMPRESSED
LEFT
INTERNAL
MAMMARY
ARTERY &
Haematoma

LEARNING POINT: Interrogate chest wall vessels systematically

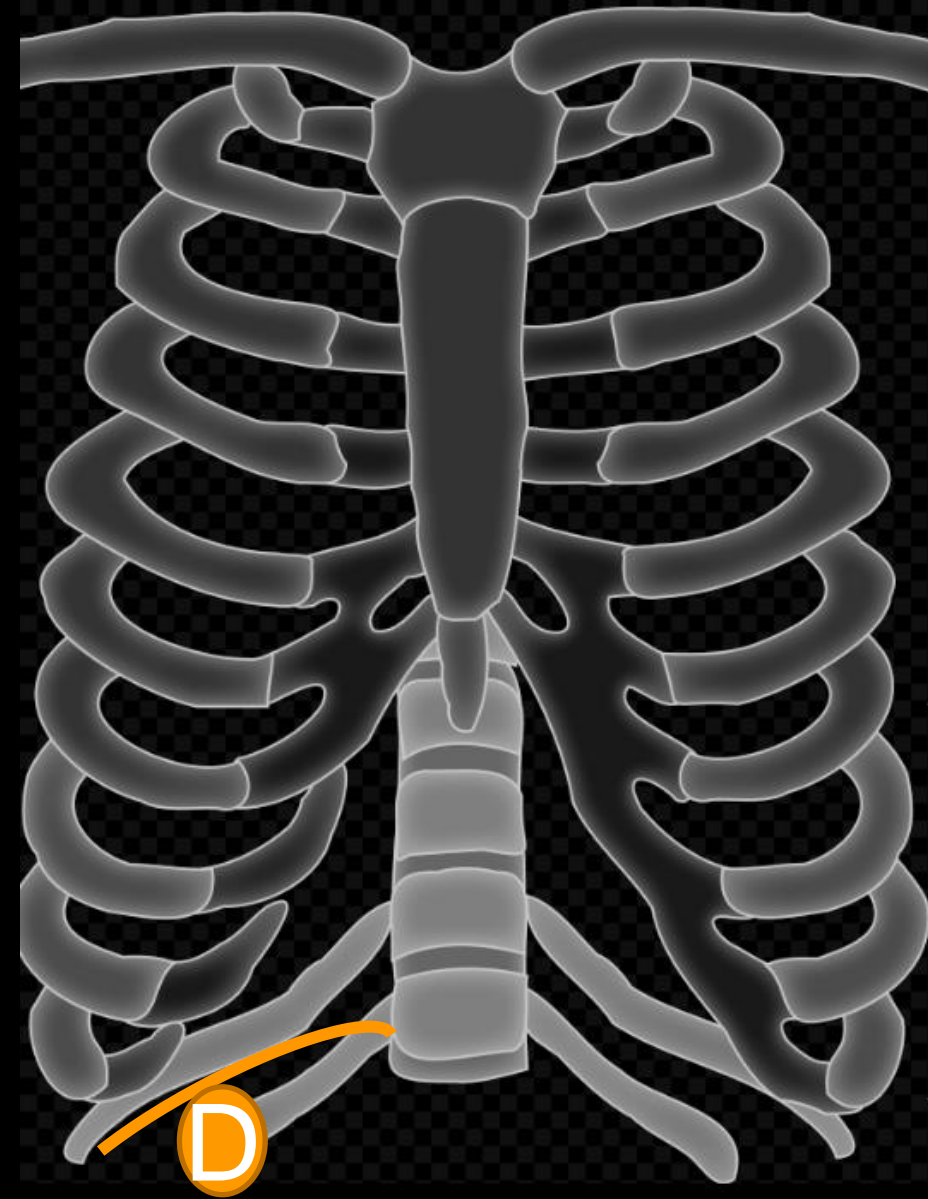
DIAPHRAGM

A airway

B breathing

C chest wall, costal cartilage

(3)D diaphragm, disability

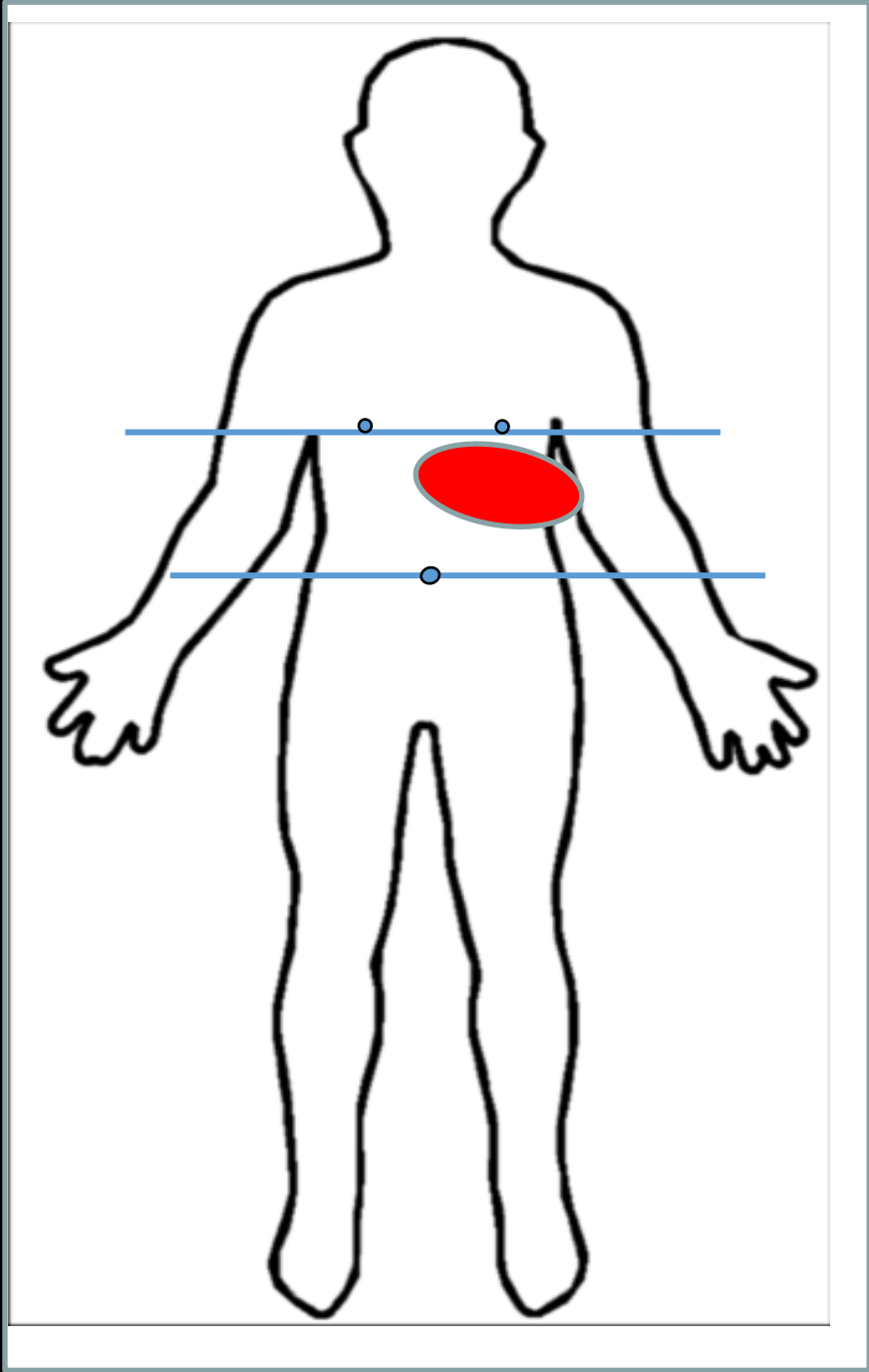


Penetrating WOUND

1x Penetrating Wound LEFT FLANK



pollEv.com/edick900



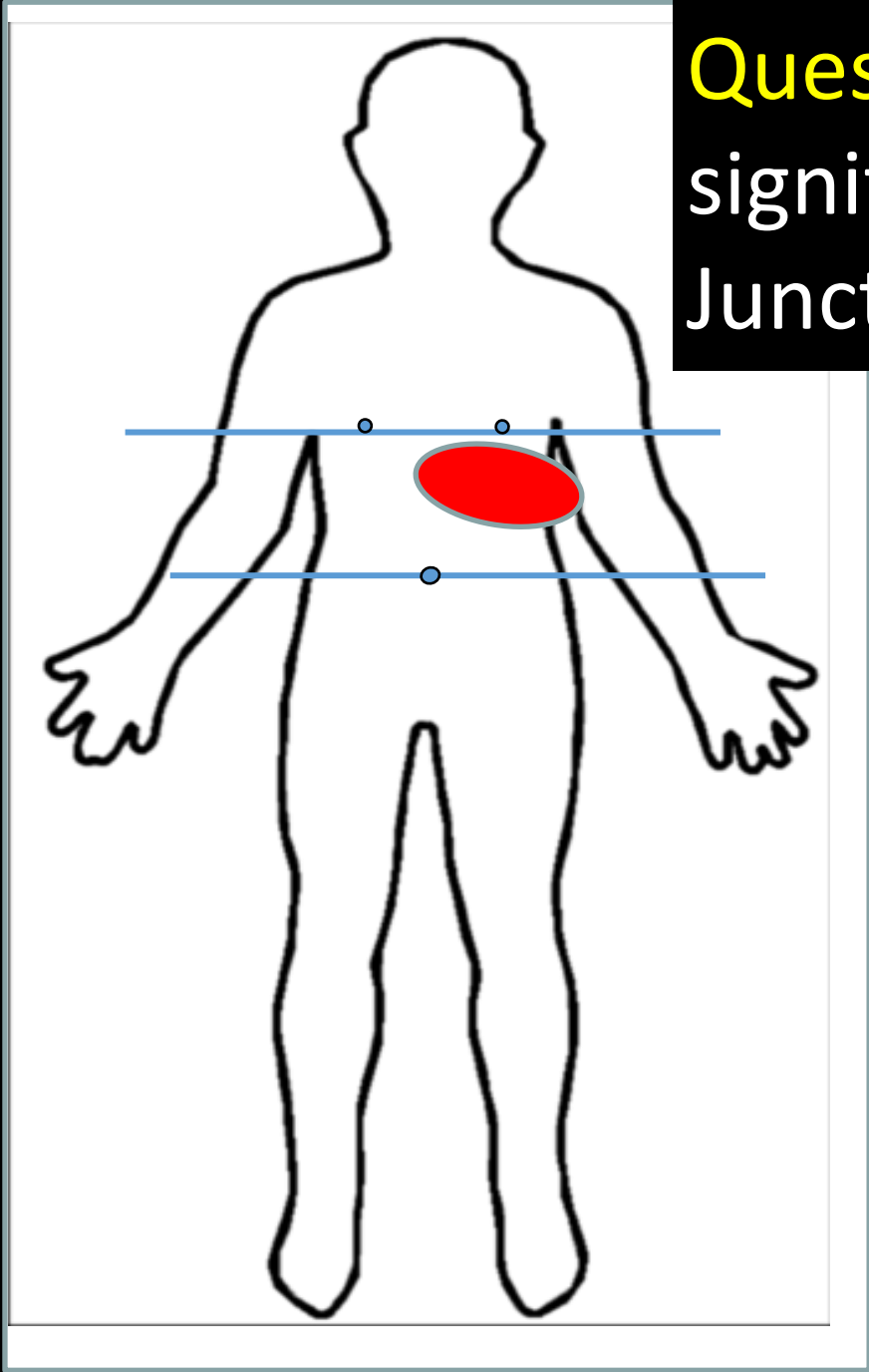
JUNCTIONAL ZONE

Penetrating WOUND

1x Penetrating Wound LEFT FLANK



pollEv.com/edick900

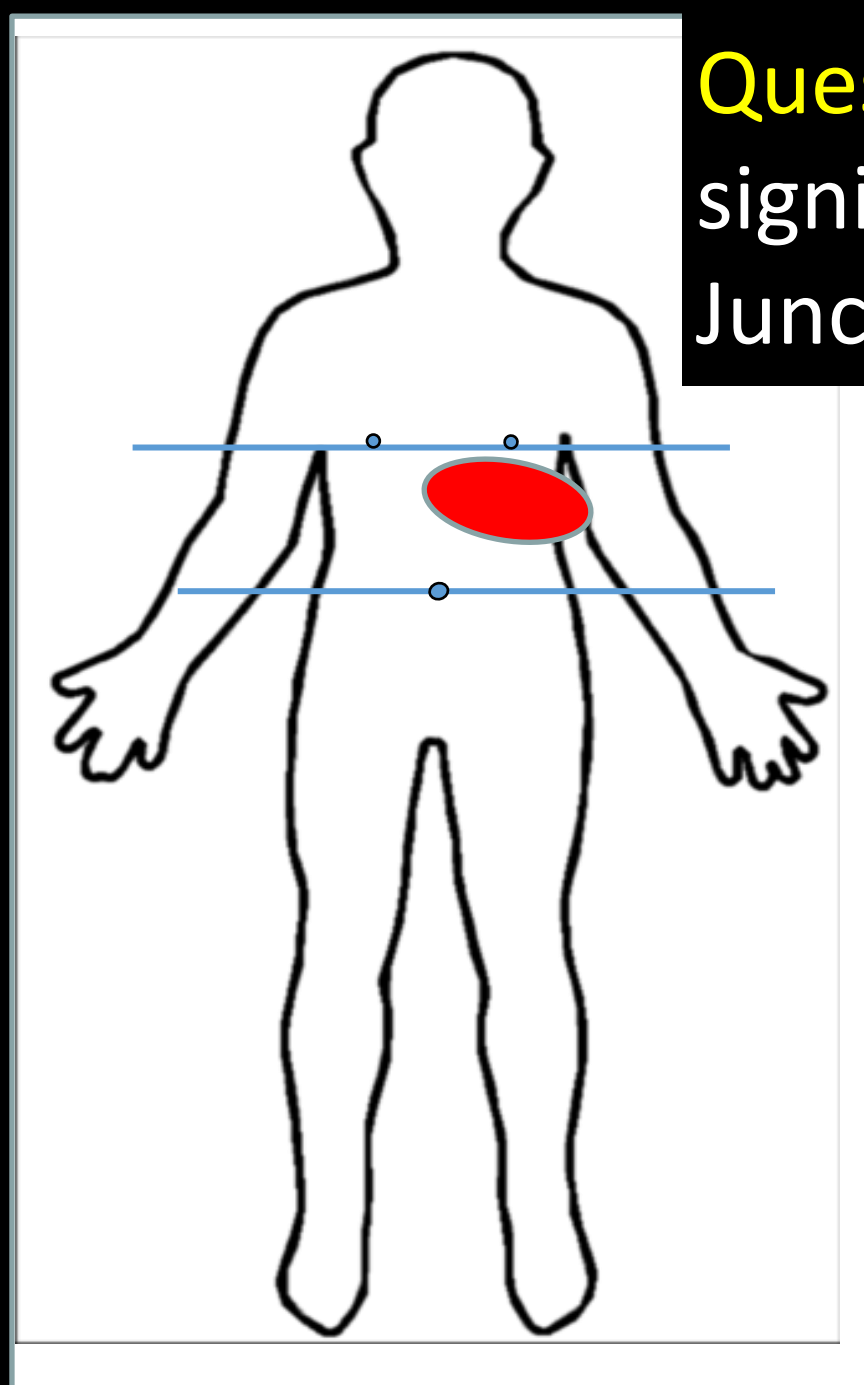


Question: what is the significance of the Junctional Zone?

JUNCTIONAL ZONE

SIGNIFICANCE OF JUNCTIONAL ZONE:

PENETRATING INJURY MAY CROSS DIAPHRAGM TO ENTER BOTH THORACIC AND ABDOMINAL CAVITY



Question: what is the significance of the Junctional Zone?

JUNCTIONAL ZONE

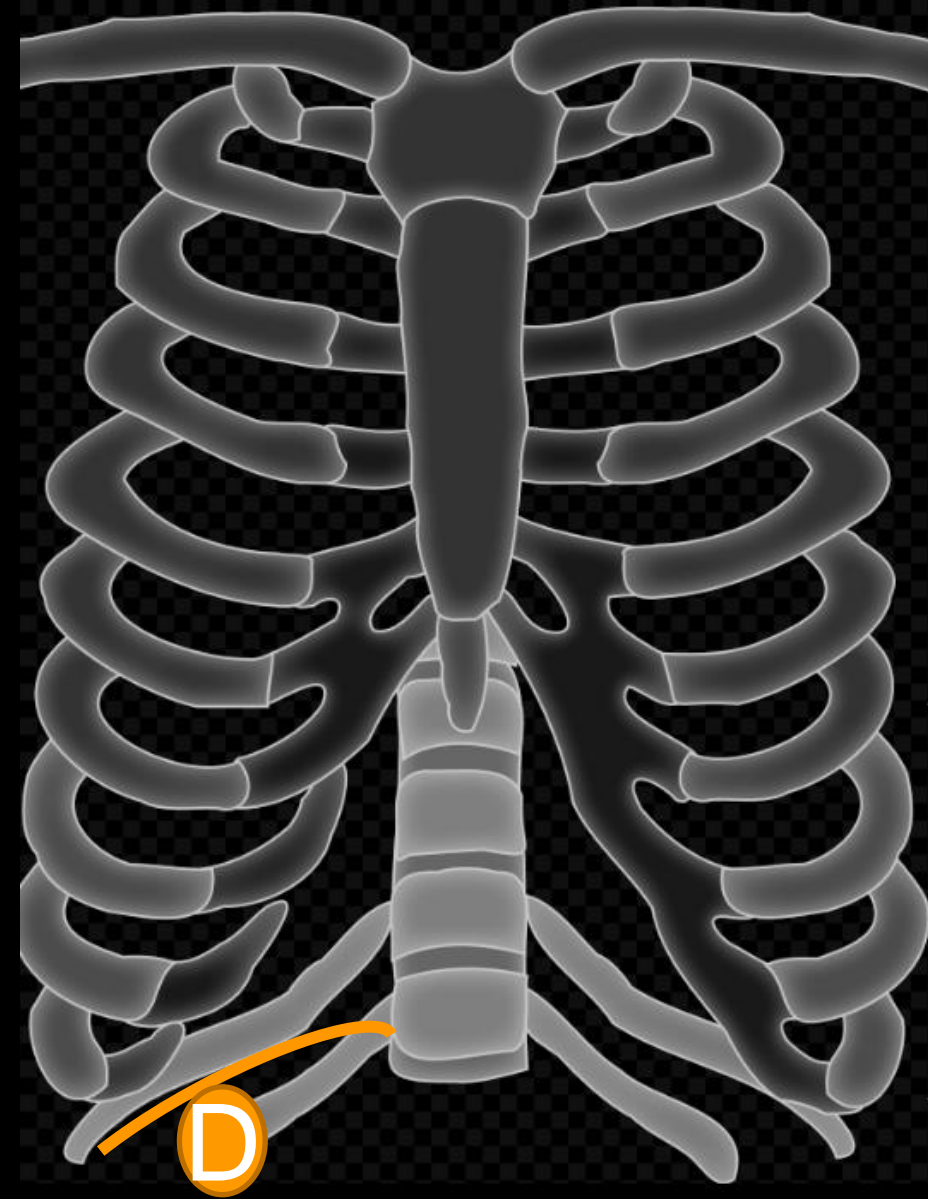
DIAPHRAGM

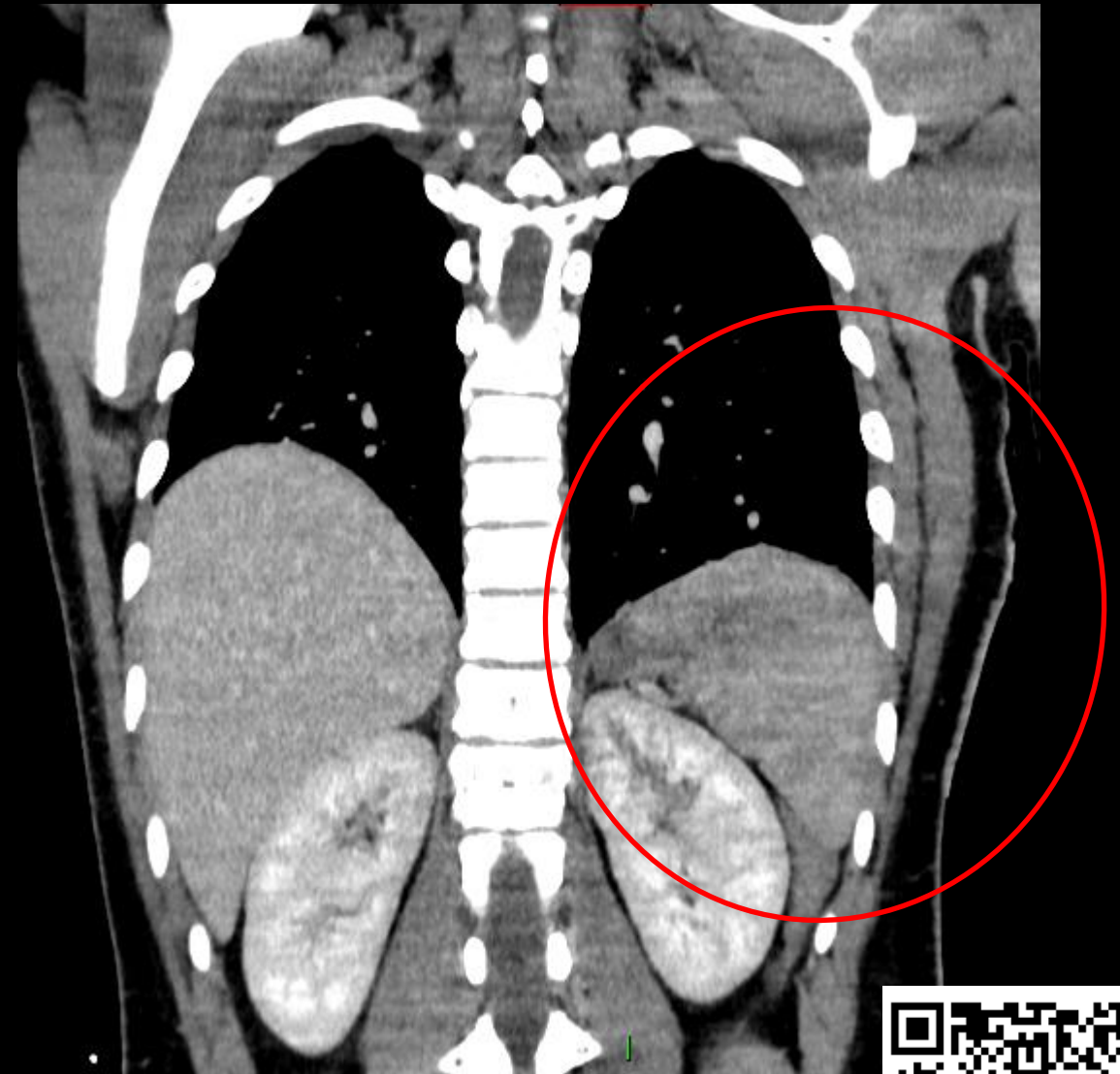
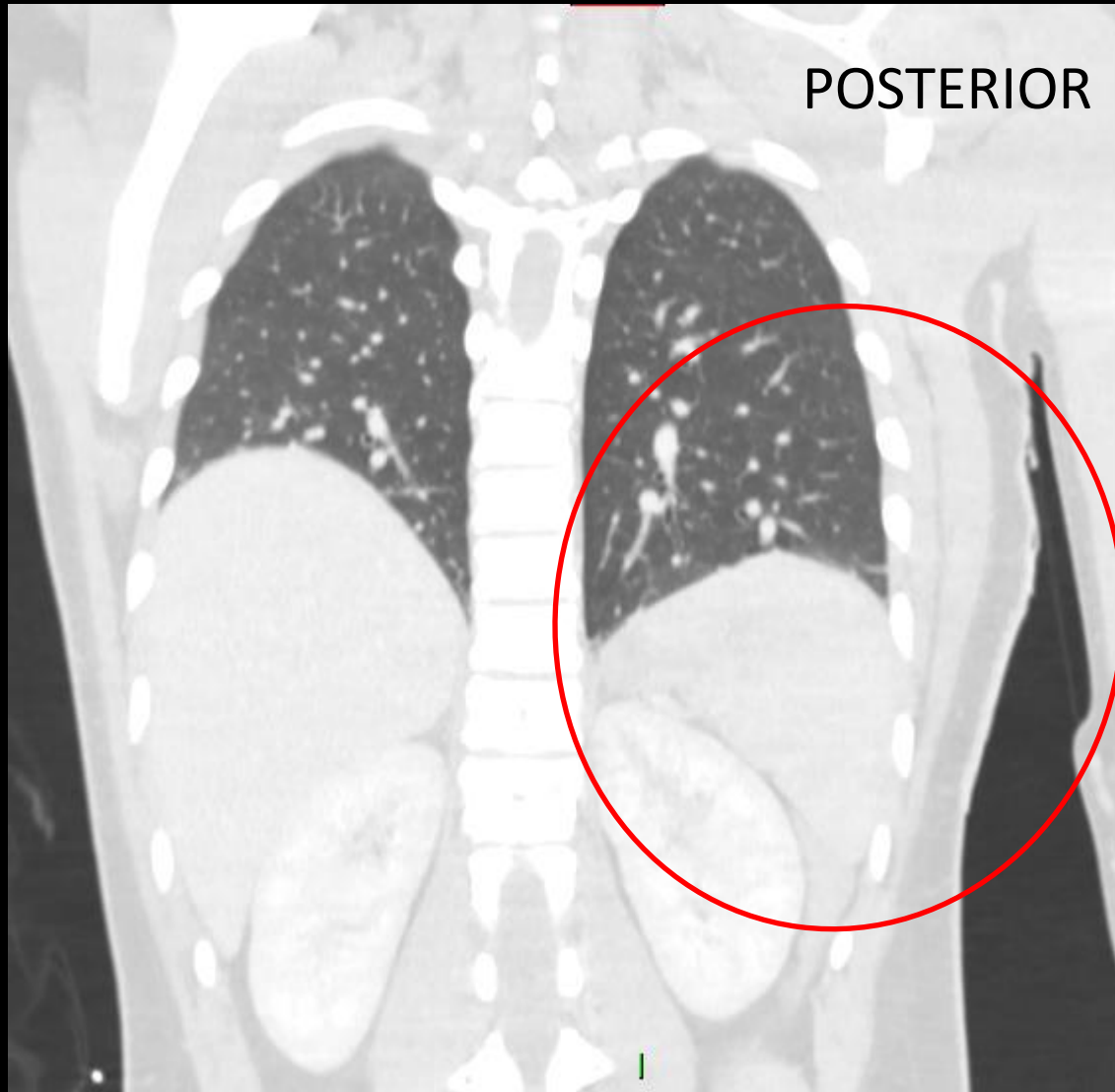A airway

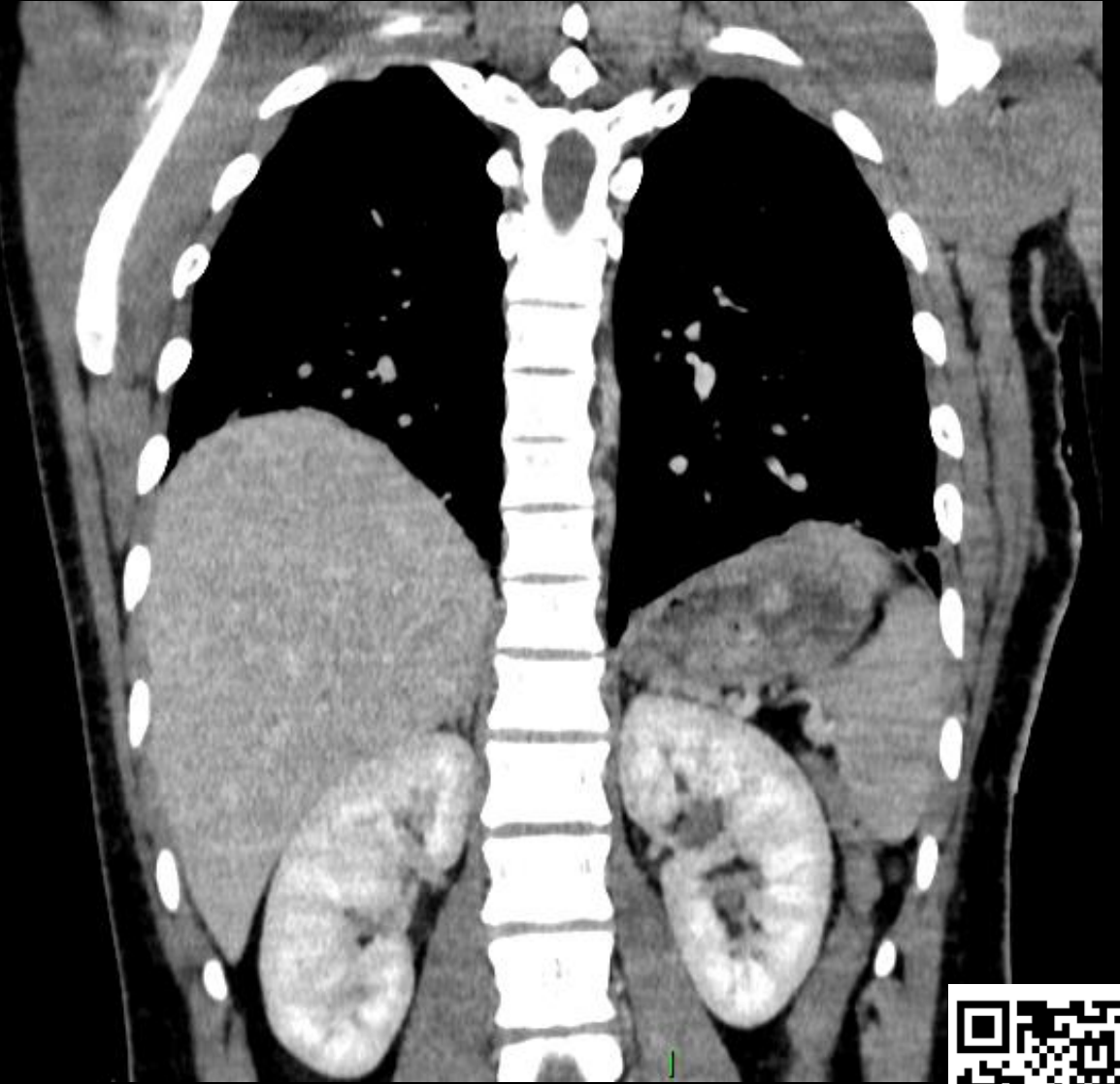
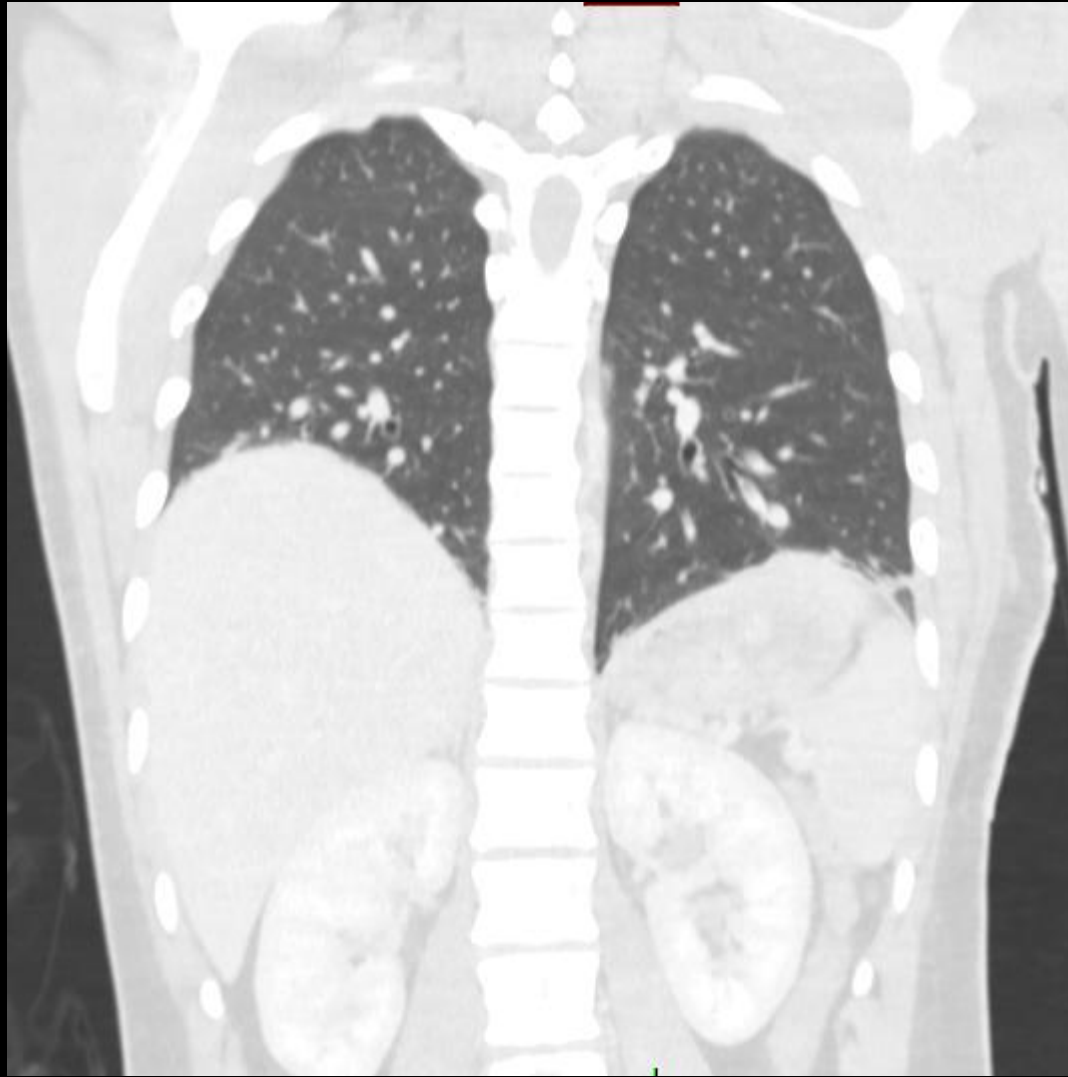
B breathing

C chest wall, costal cartilage

(3)D diaphragm, disability

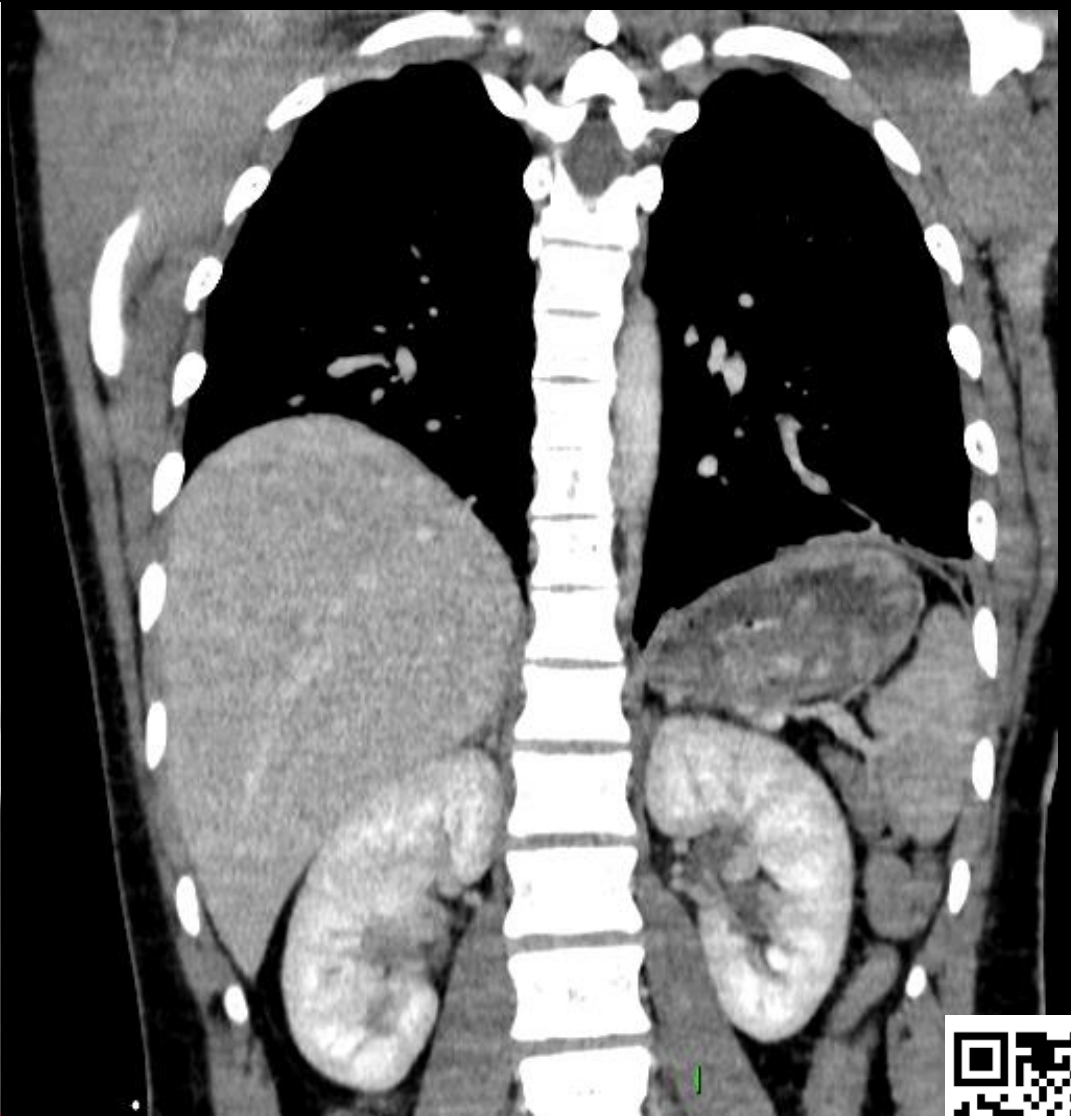
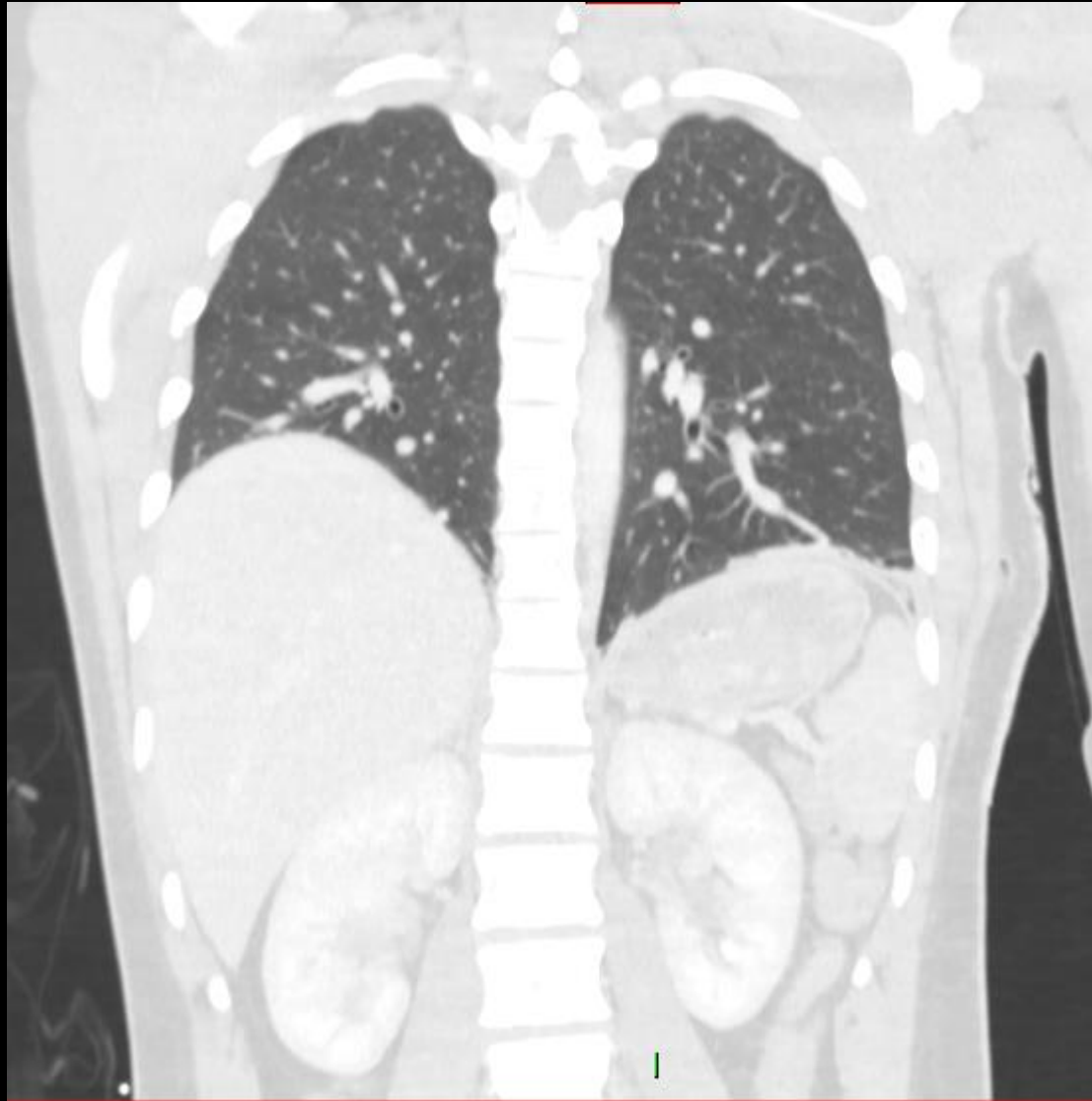






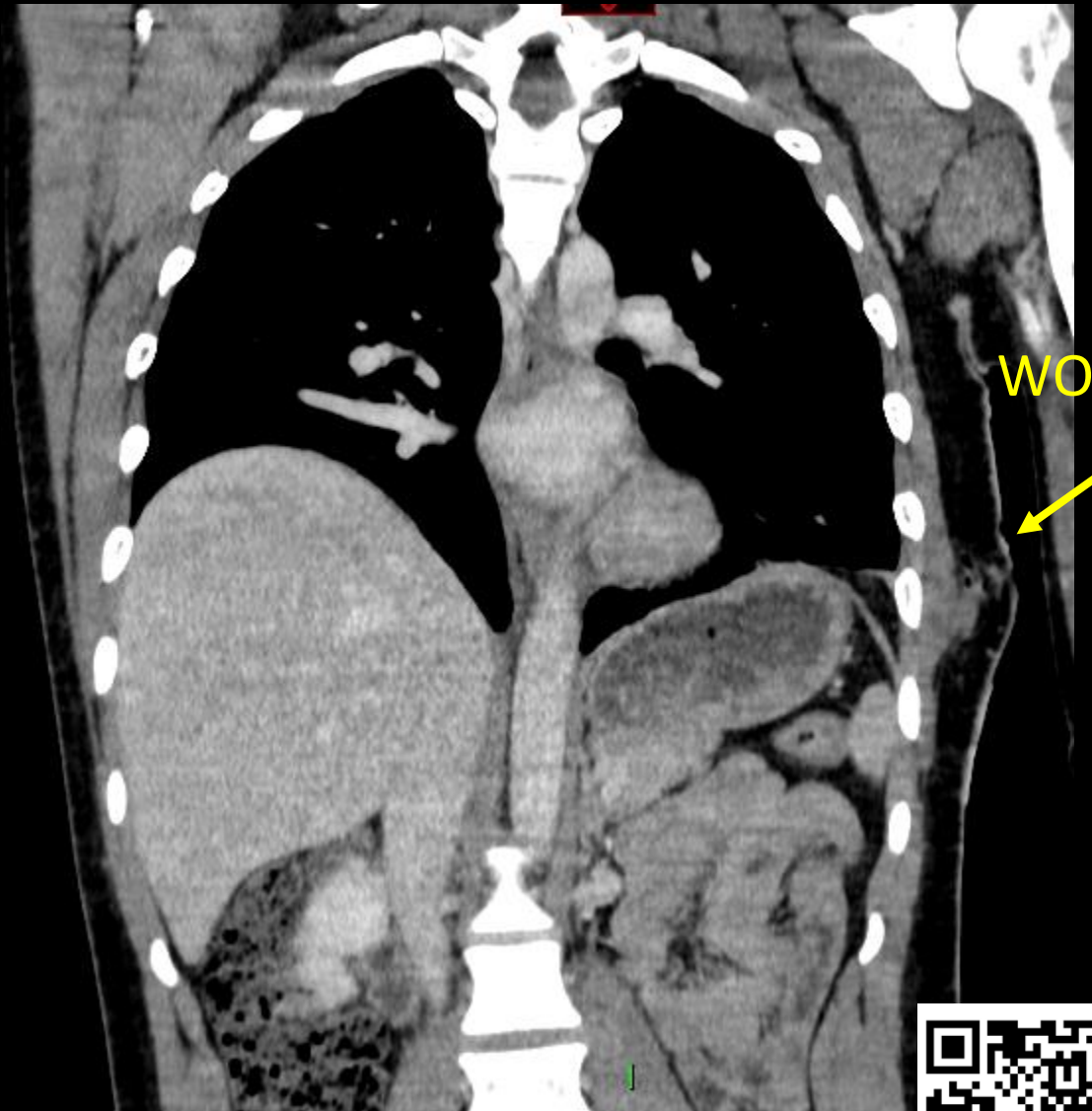
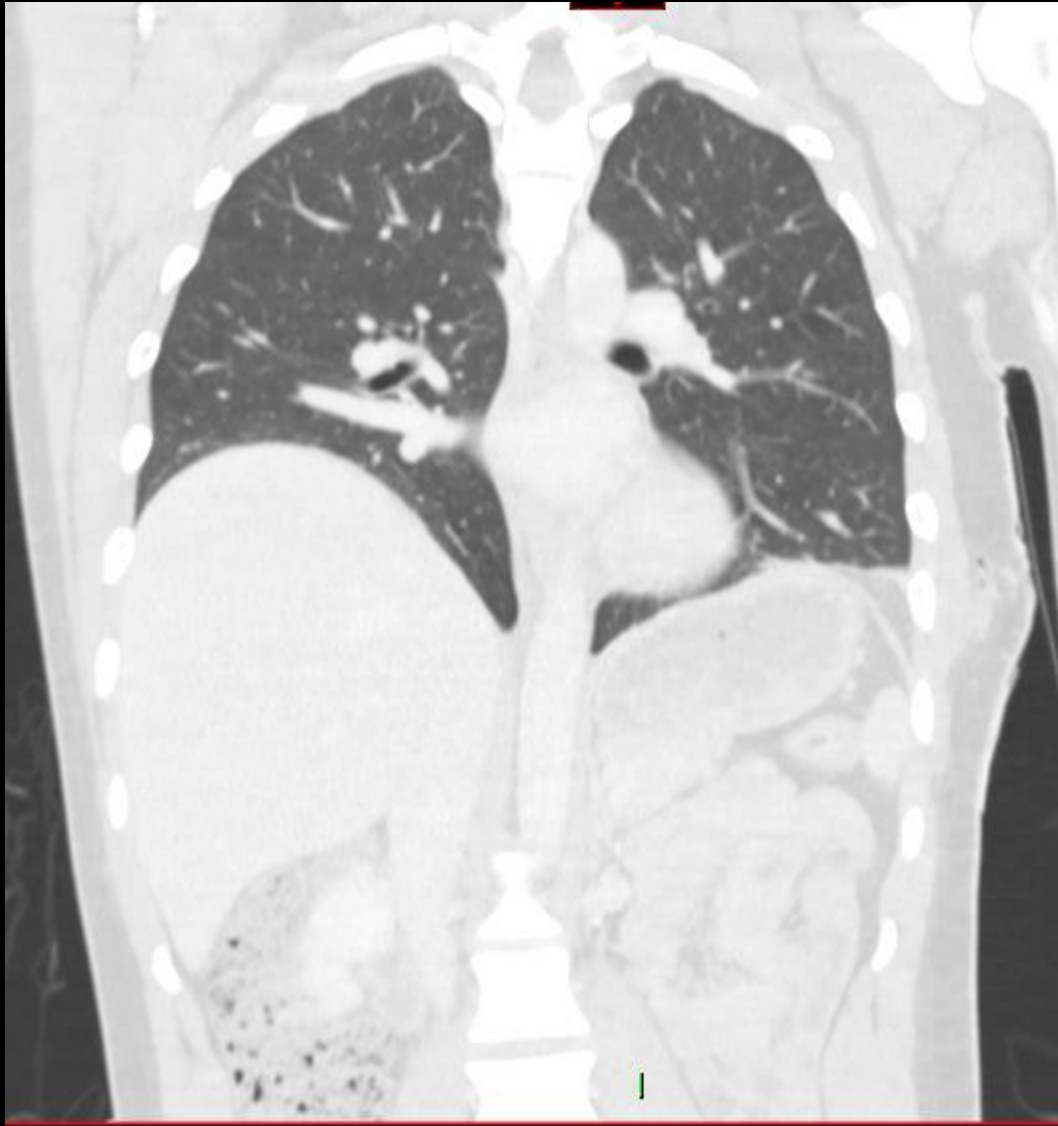pollEv.com/edick900

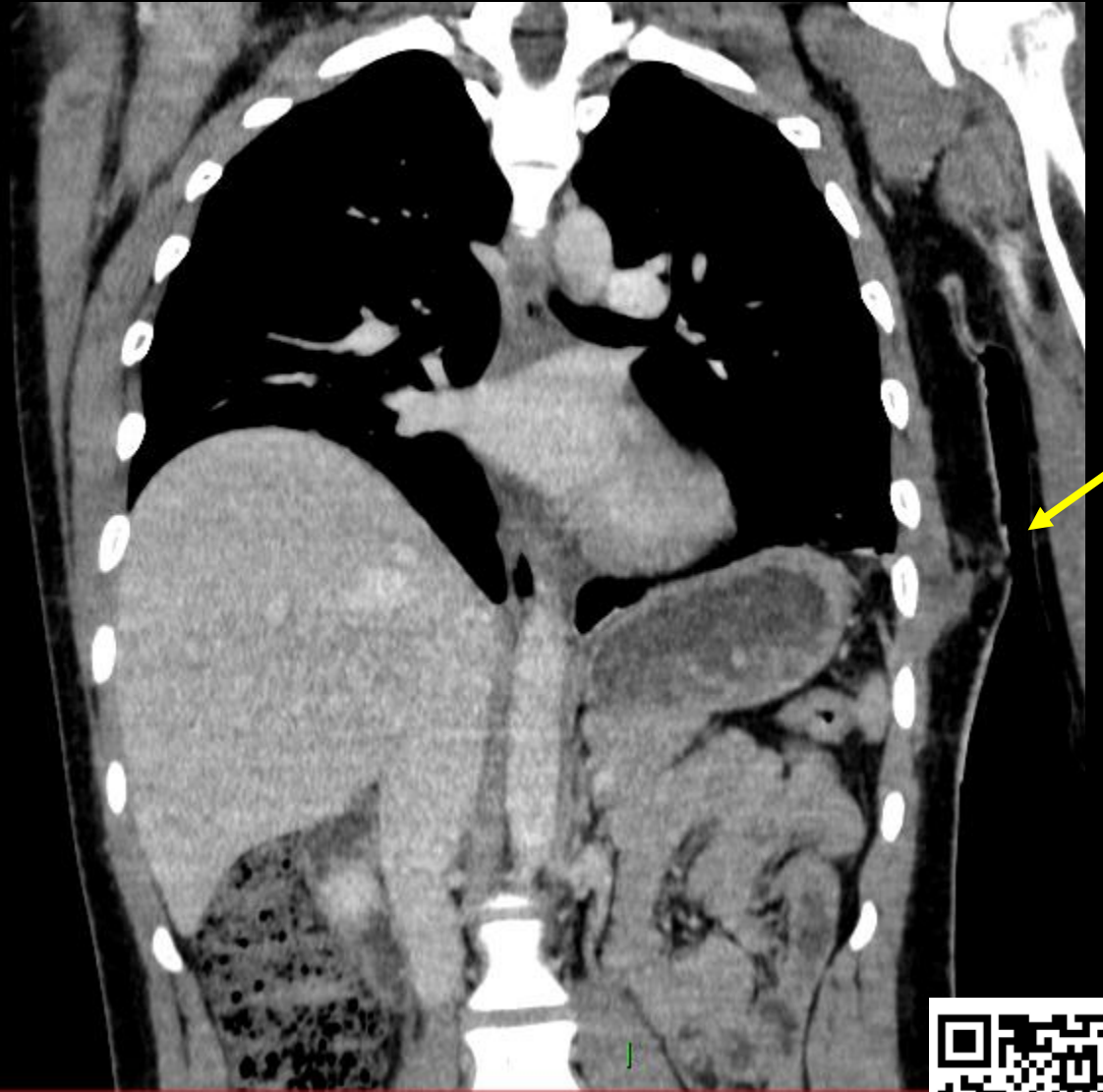
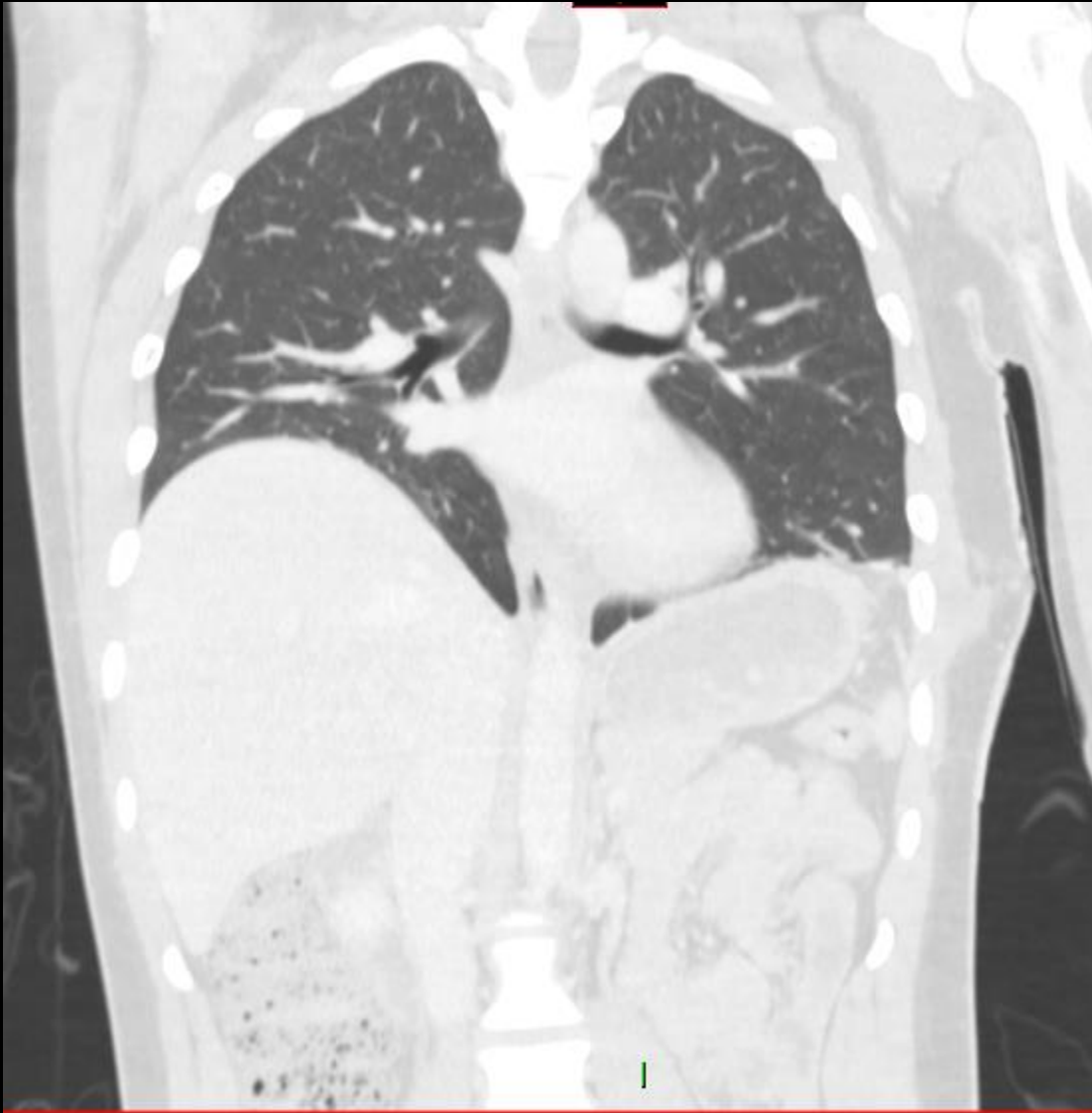


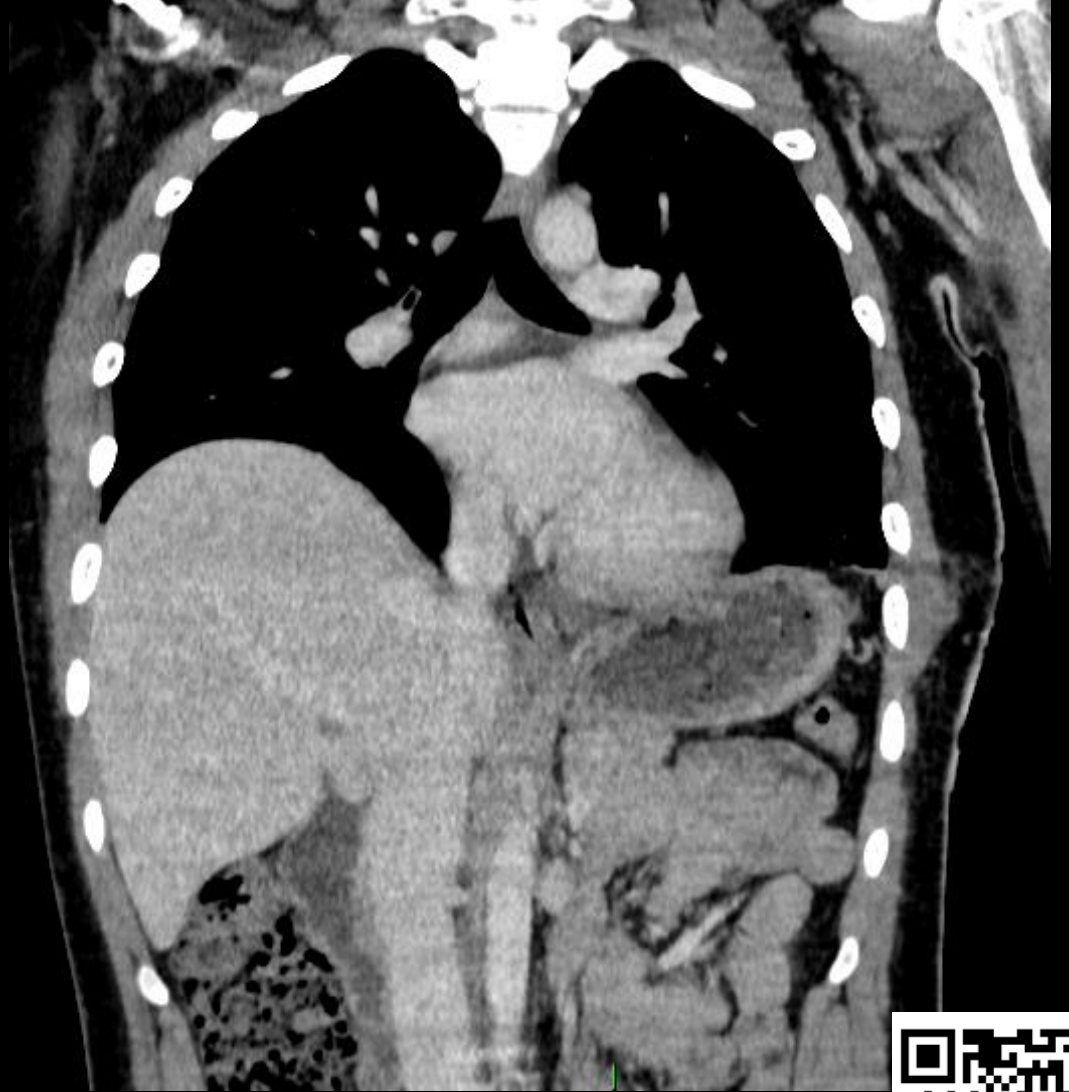
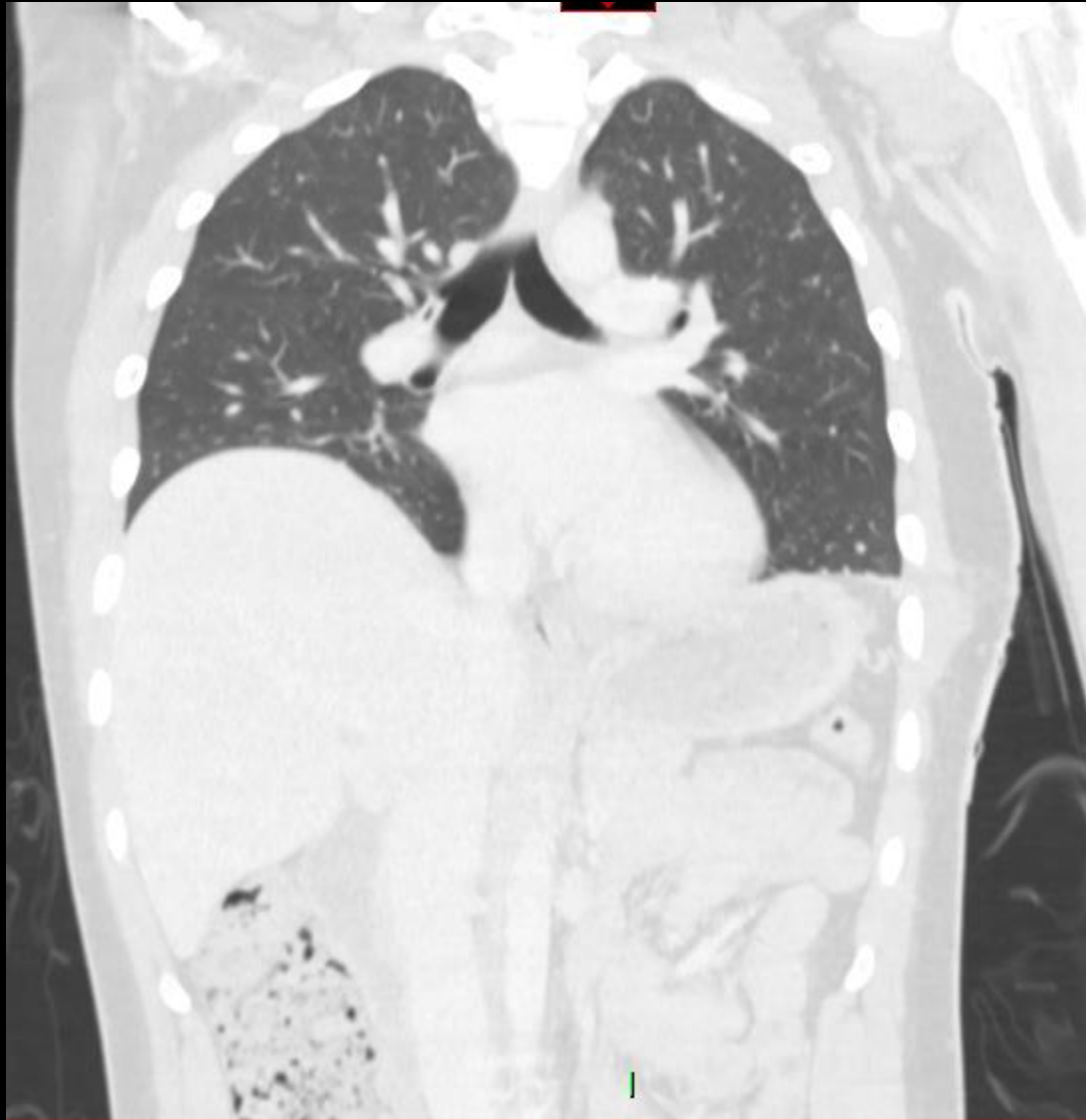pollEv.com/edick900



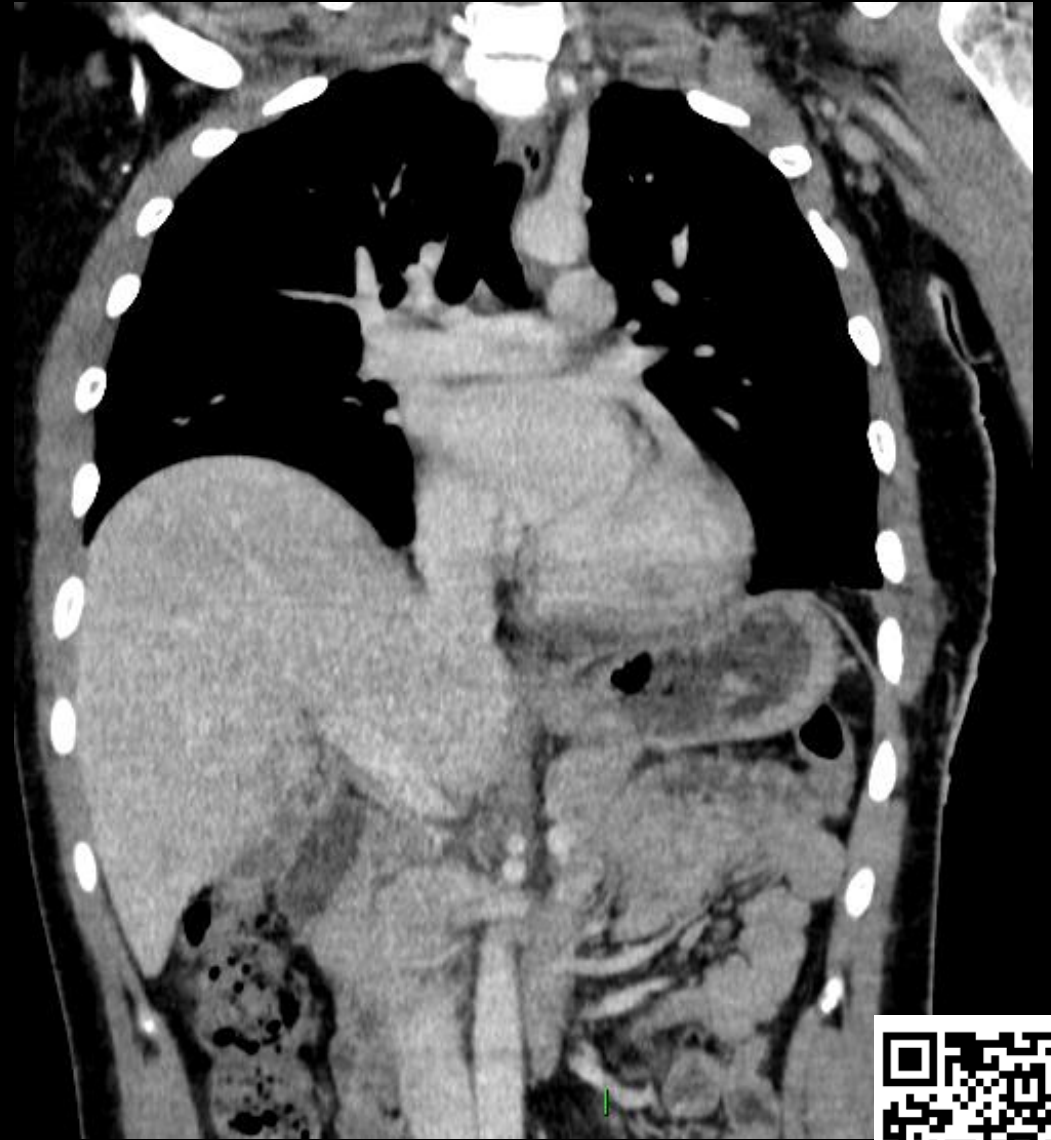
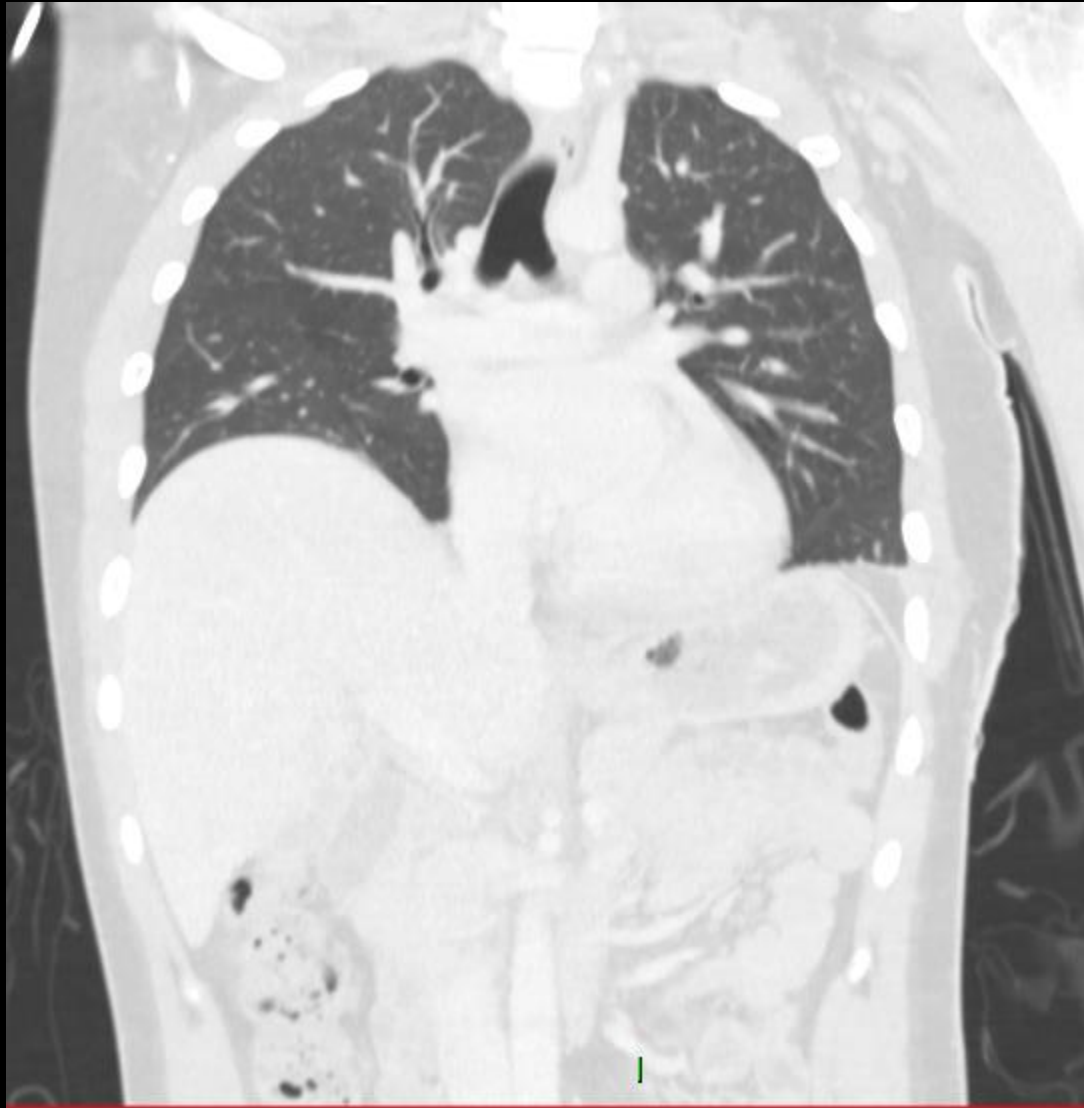




pollEv.com/edick900

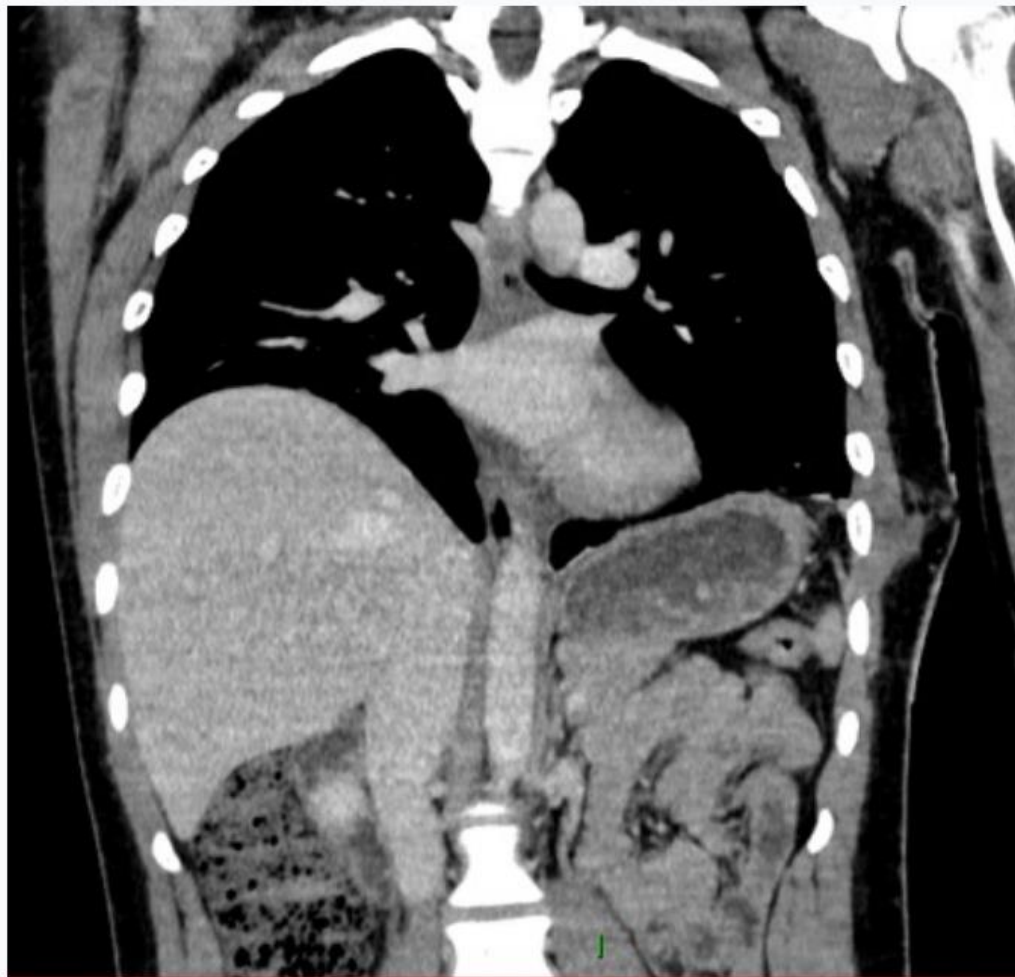


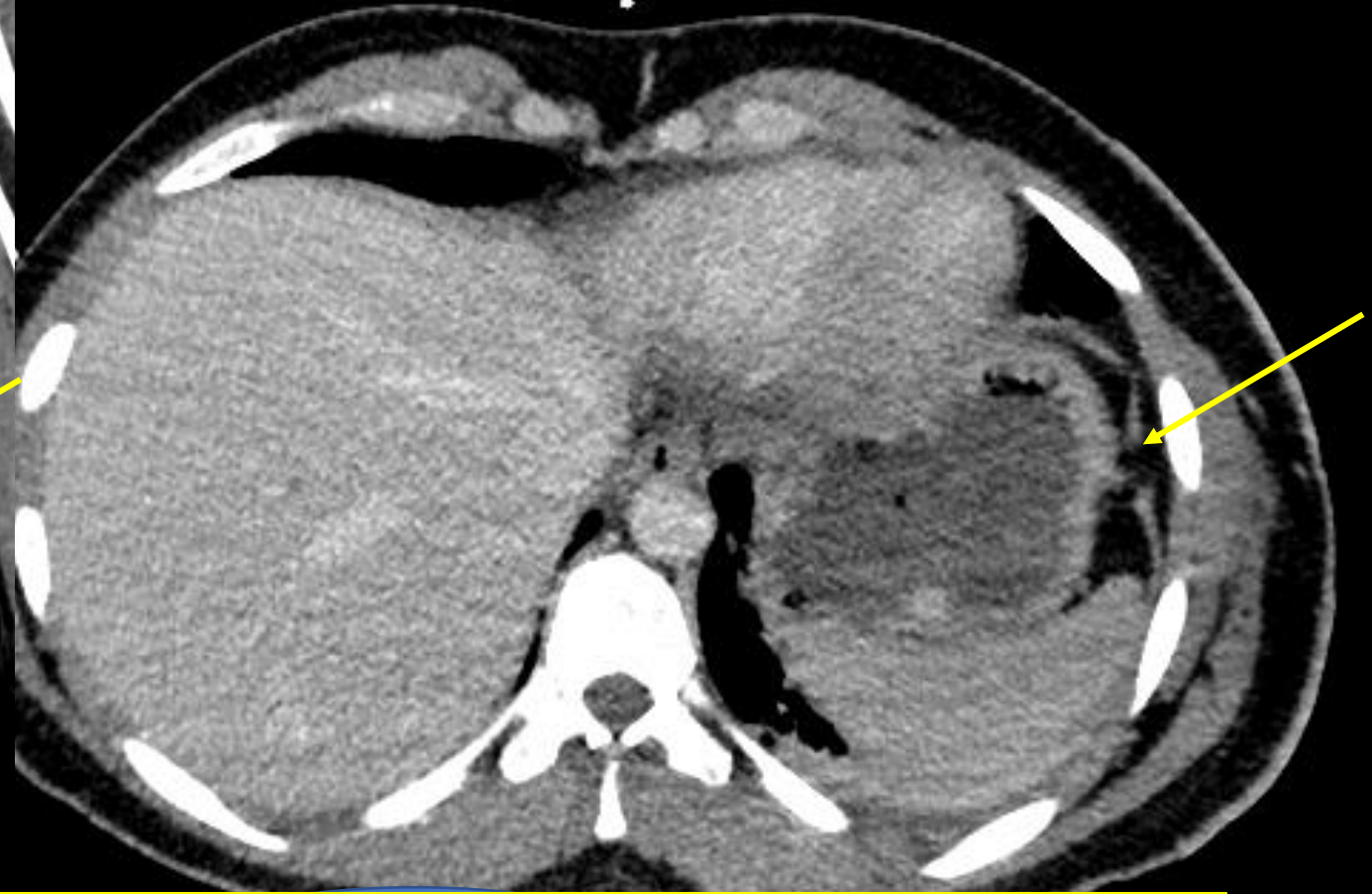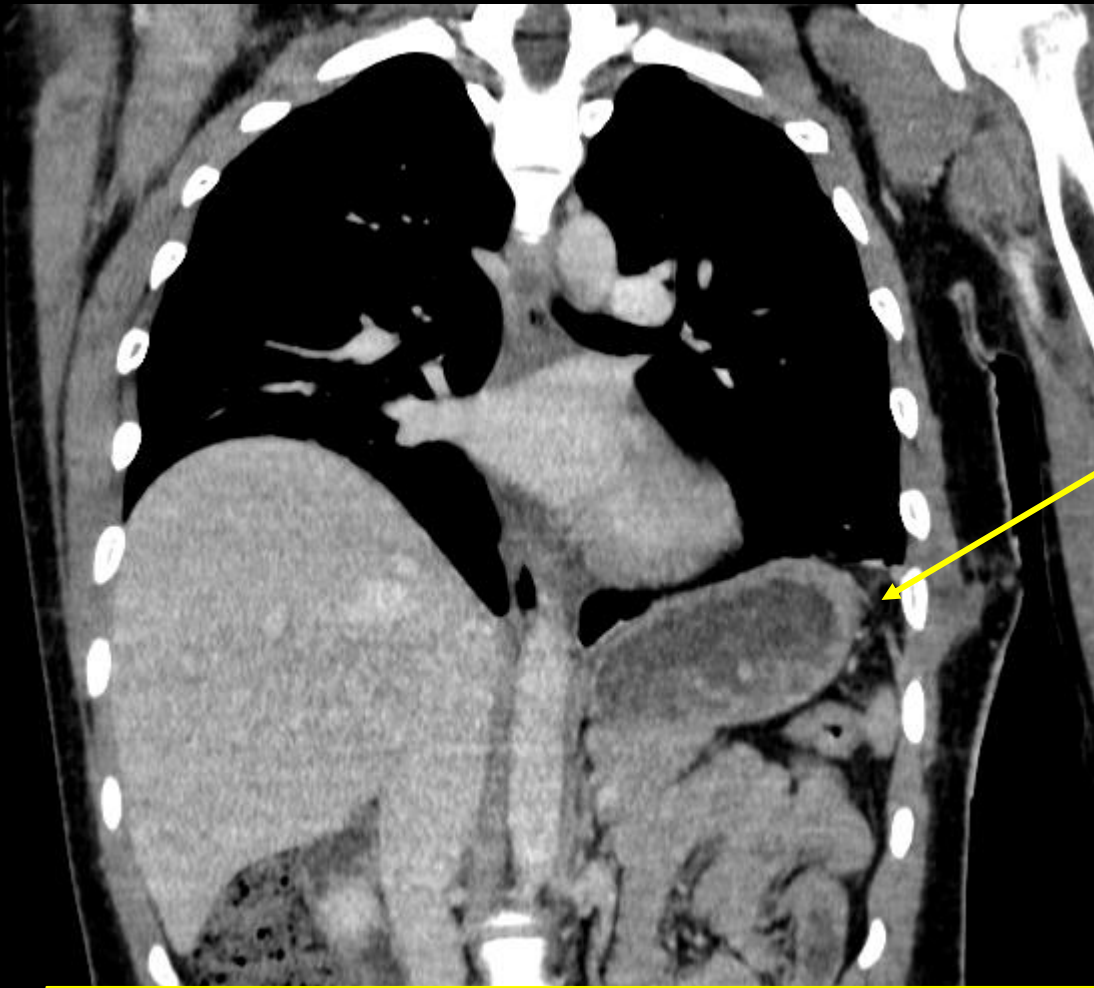


pollEv.com/edick900



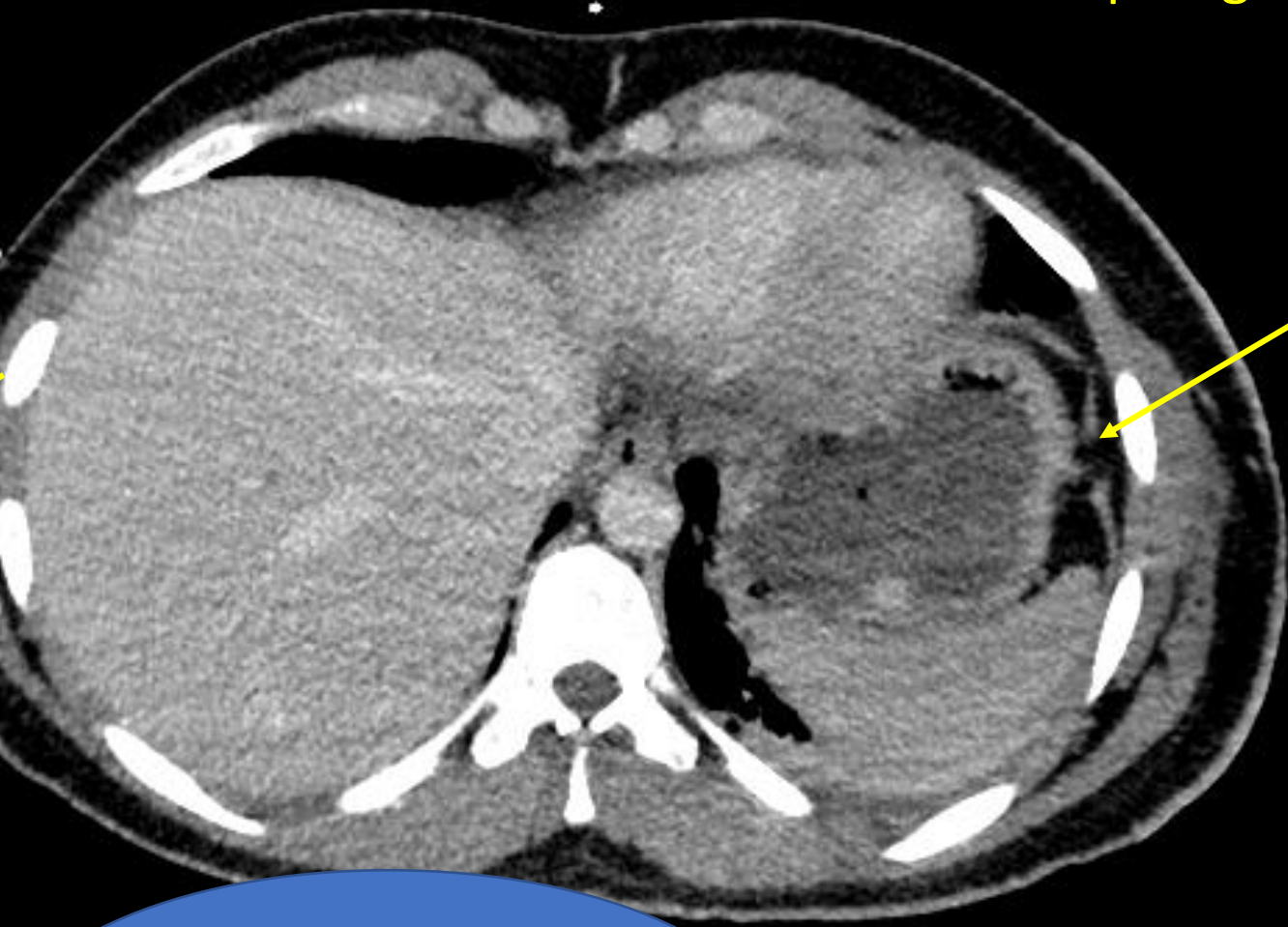
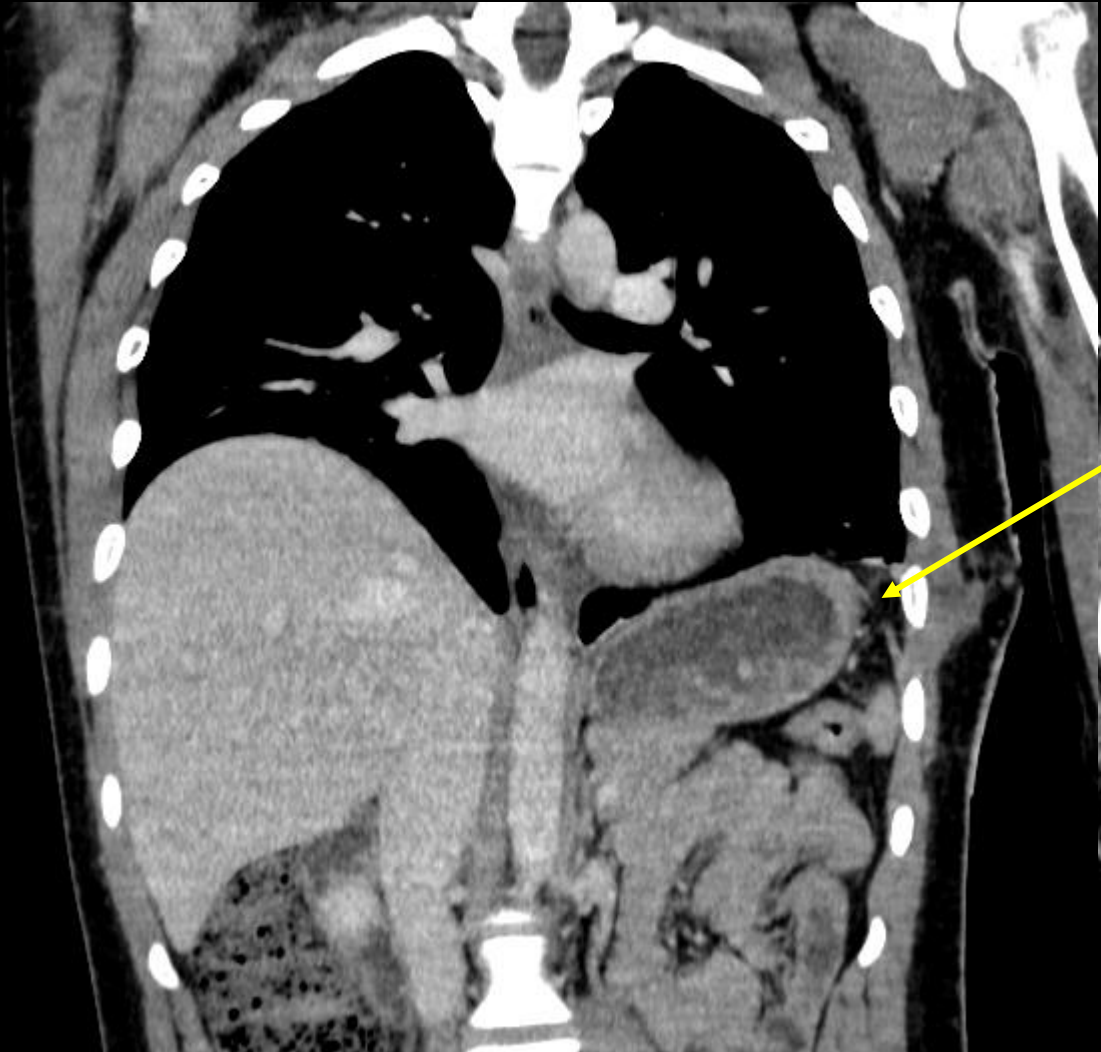
Where is the diaphragmatic defect?





Learning Point:

1. Junctional Zone injury = think about diaphragm injury
2. Diaphragm should be interrogated in all 3 planes



Defect left diaphragm

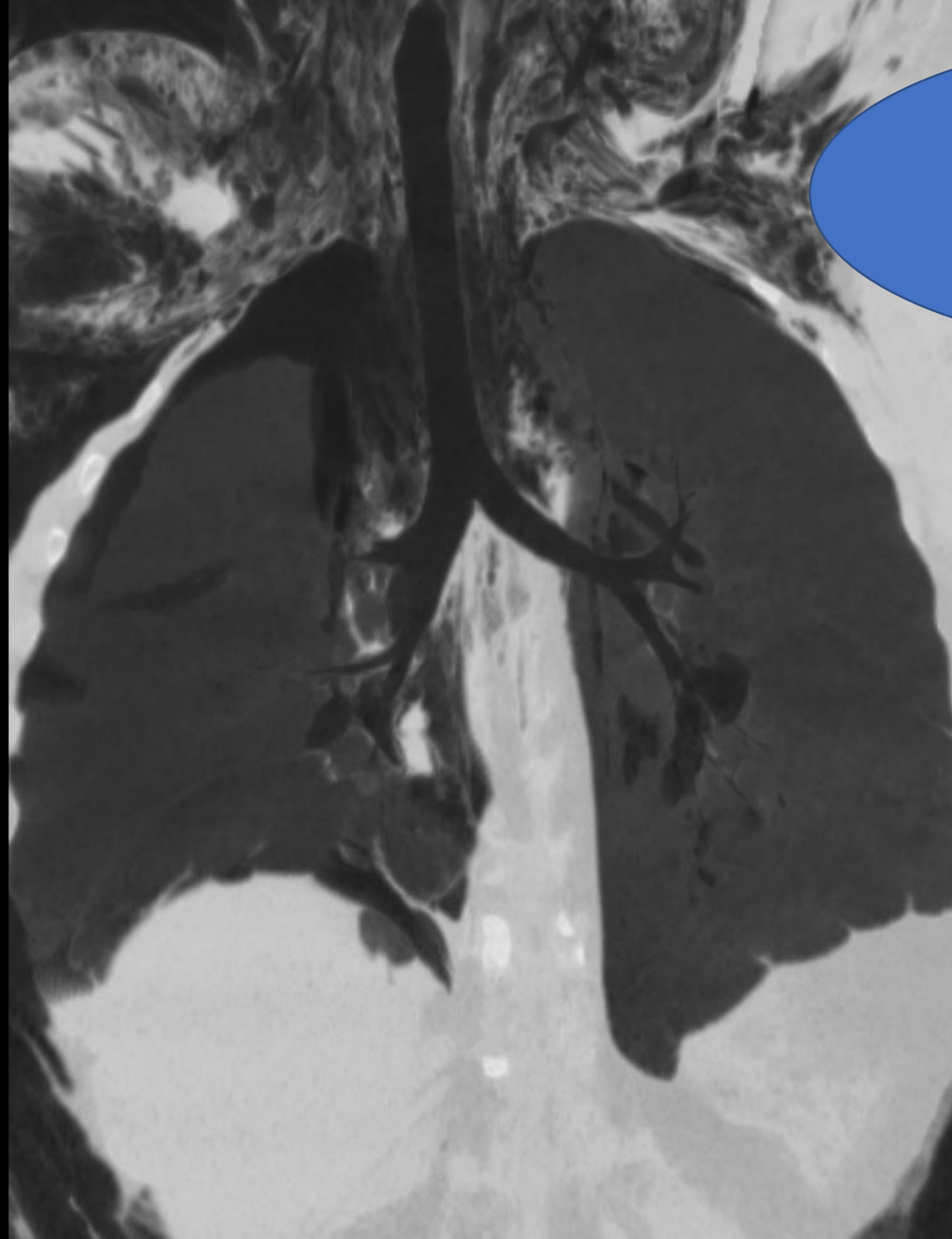
Learning Point: L diaphragm always need repair

Mechanism of Injury
PENETRATING

Case 1

Blunt Trauma

R Pneumothorax,
surgical
emphysema, rib
fractures



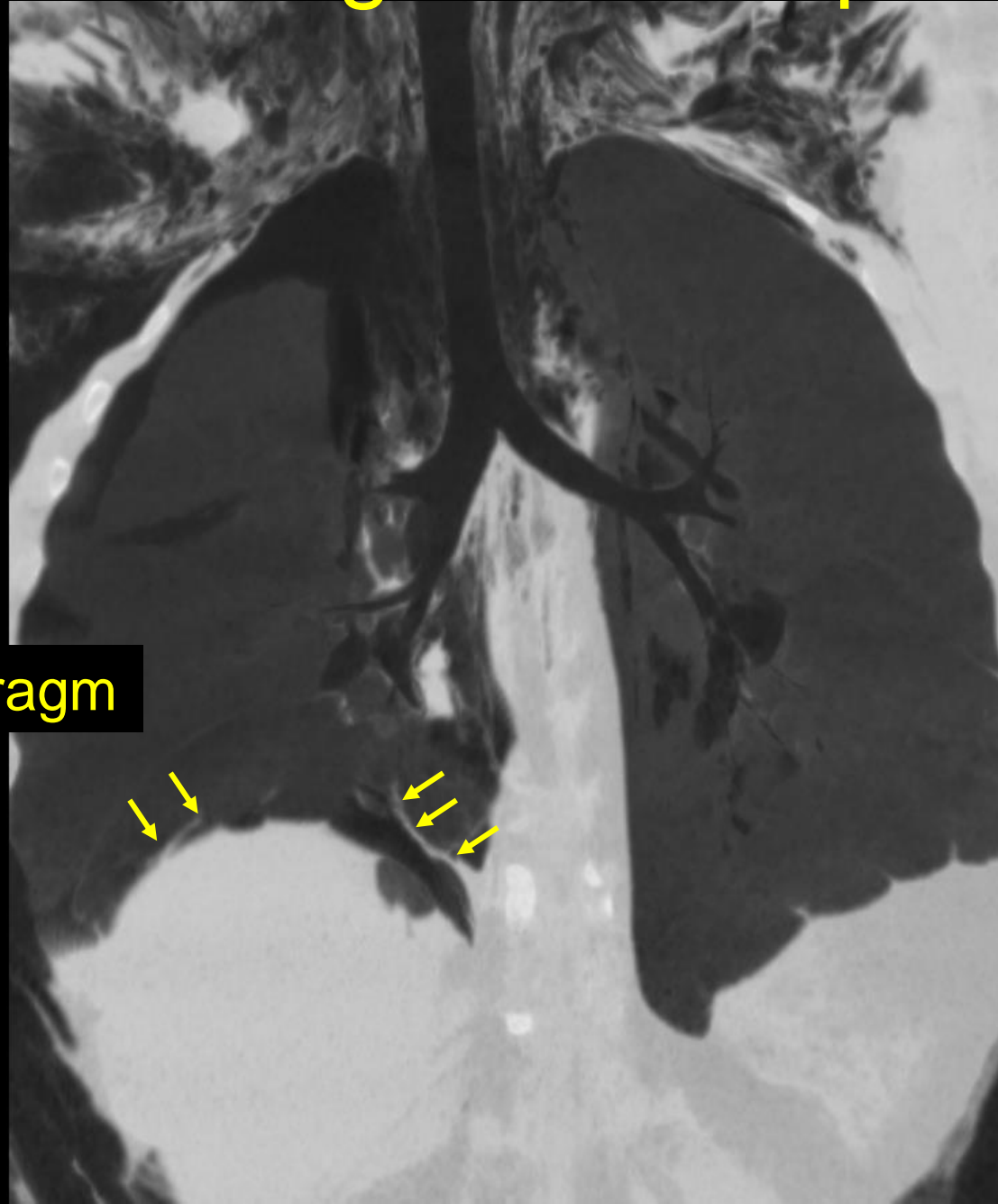
Mechanism of
Injury
BLUNT TRAUMA

Case 1

Ruptured right hemidiaphragm

Blunt Trauma

R Pneumothorax,
surgical
emphysema, rib
fractures



Free edge R hemidiaphragm

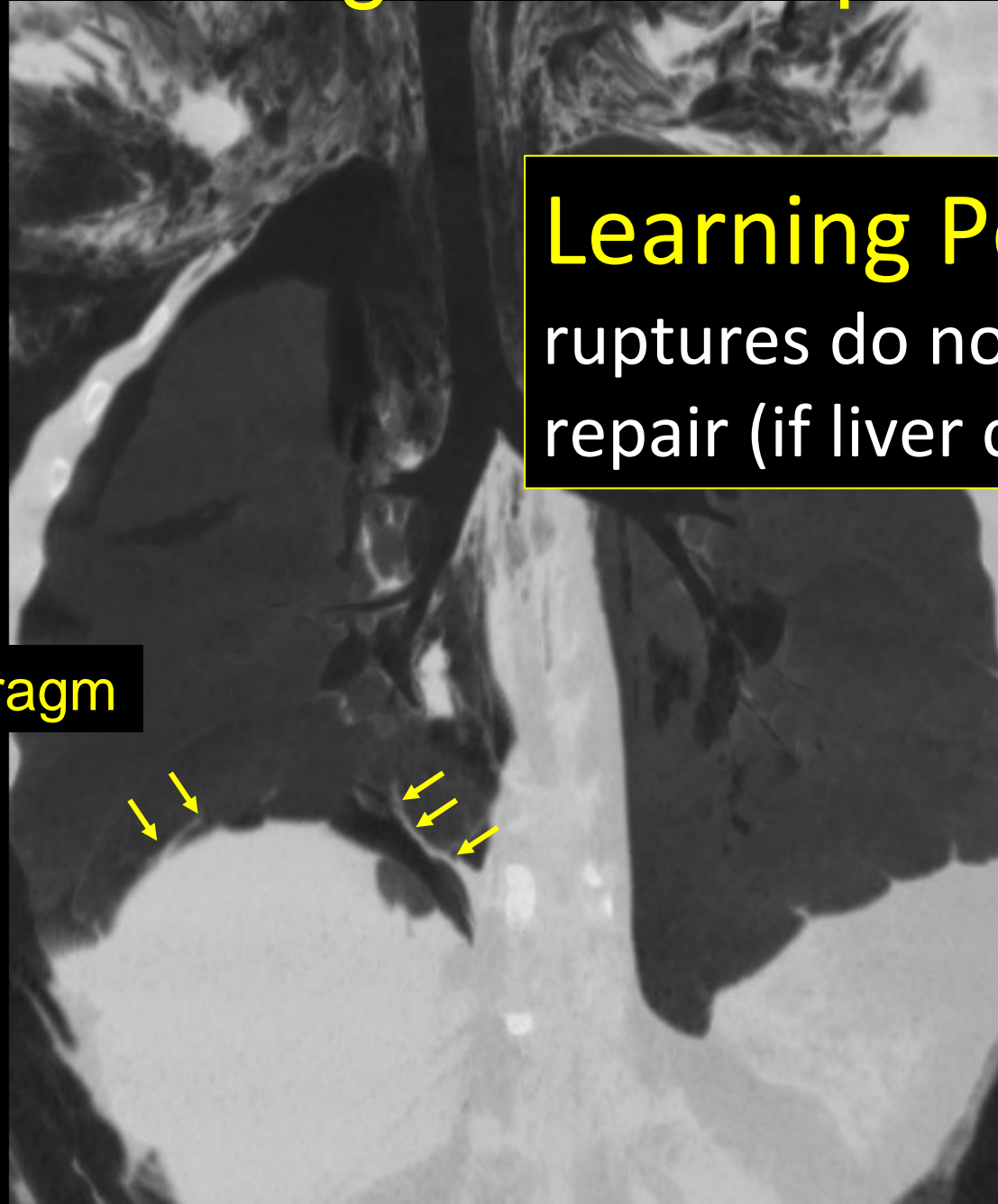
Case 1

Ruptured right hemidiaphragm

Blunt Trauma

R Pneumothorax,
surgical
emphysema, rib
fractures

Learning Point: R diaphragm ruptures do not always need repair (if liver covers rupture)



Free edge R hemidiaphragm

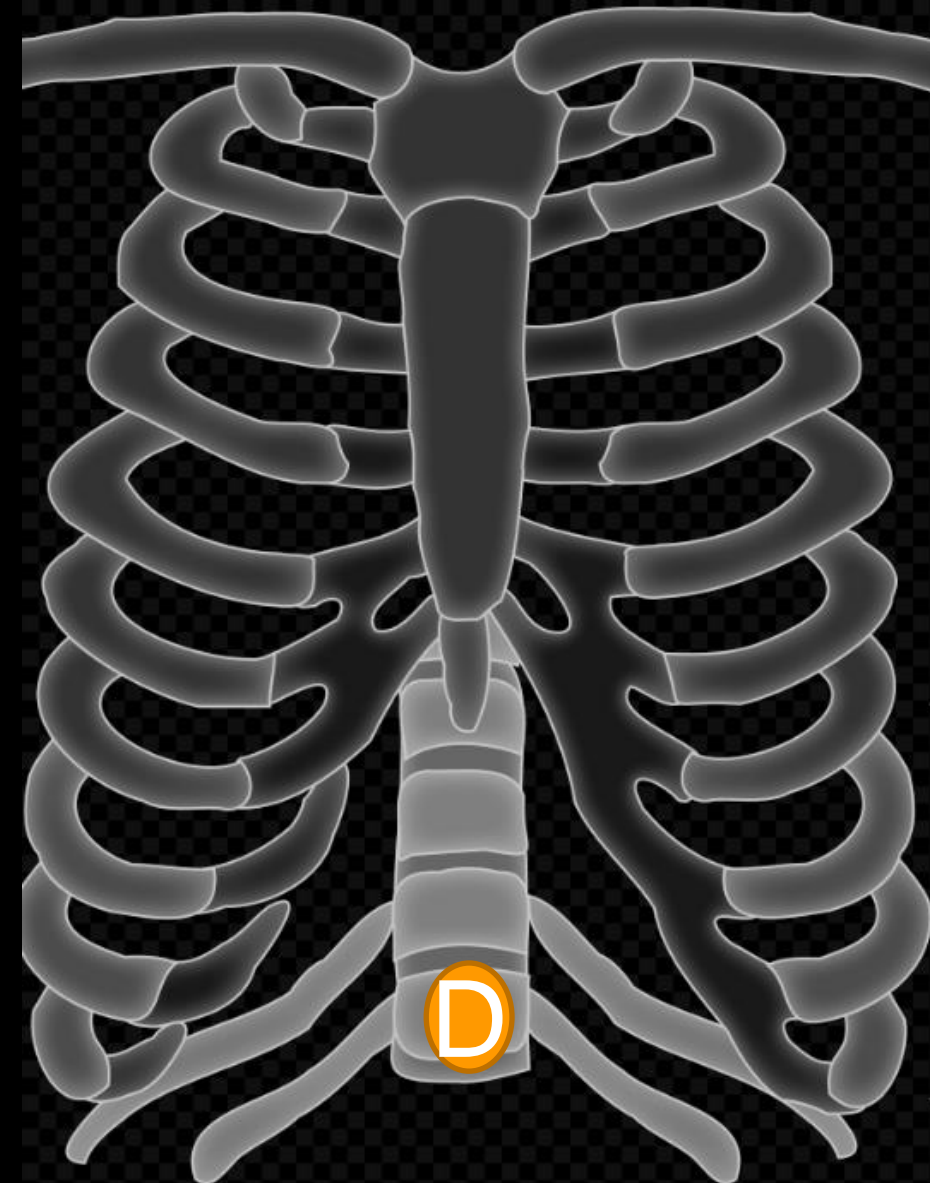
CHECKLIST

A airway

B breathing

C chest wall, costal cartilage

(3)D diaphragm, **disability**

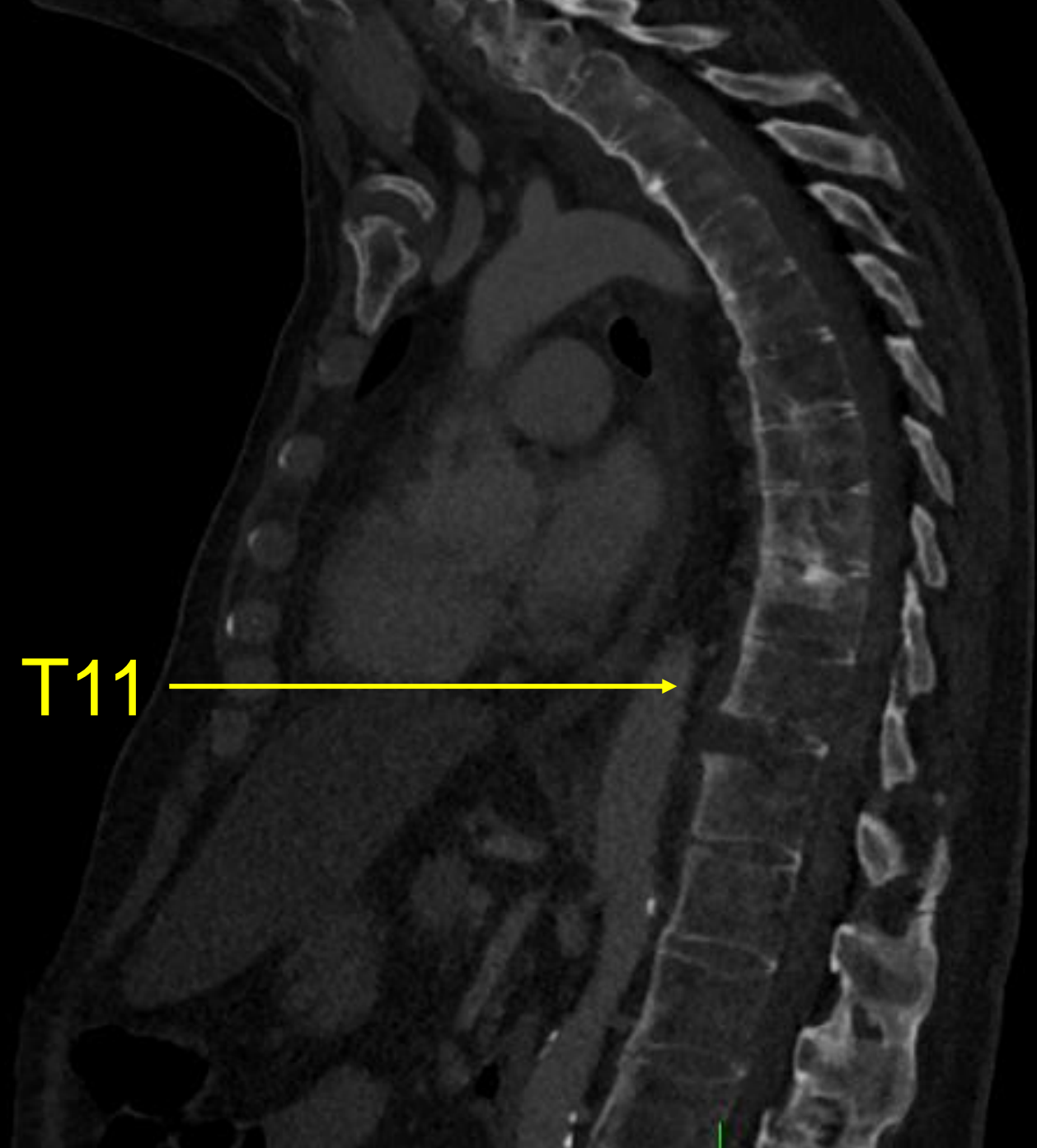


Disability

Pedestrian versus Car

T11/T12 #

Patient
Physiology:
Ankylosing
Spondylitis
RIGID spine

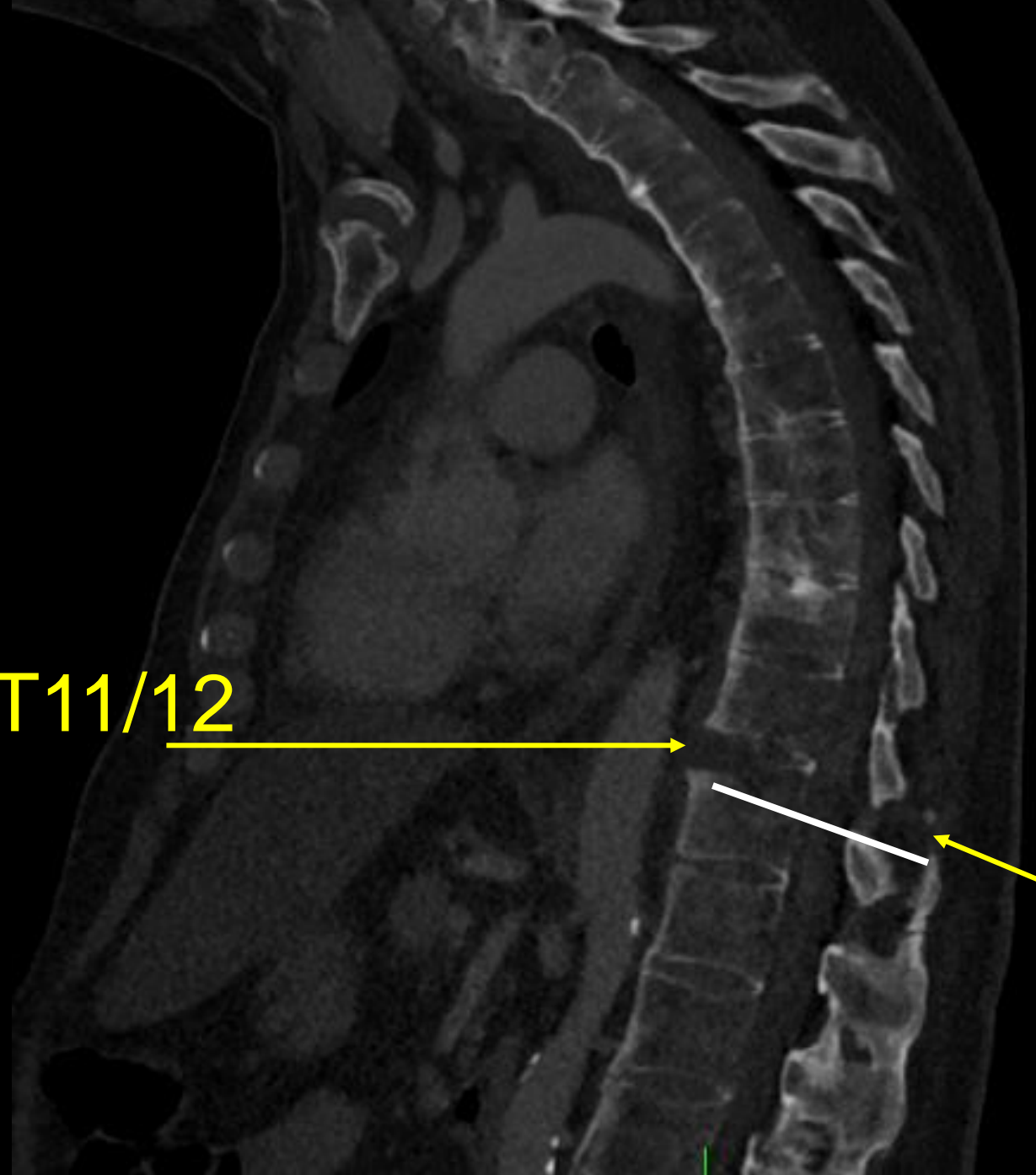


Pedestrian versus Car

T11/T12 #

Hyperextension injury
(‘Chance’)
3 column
Unstable

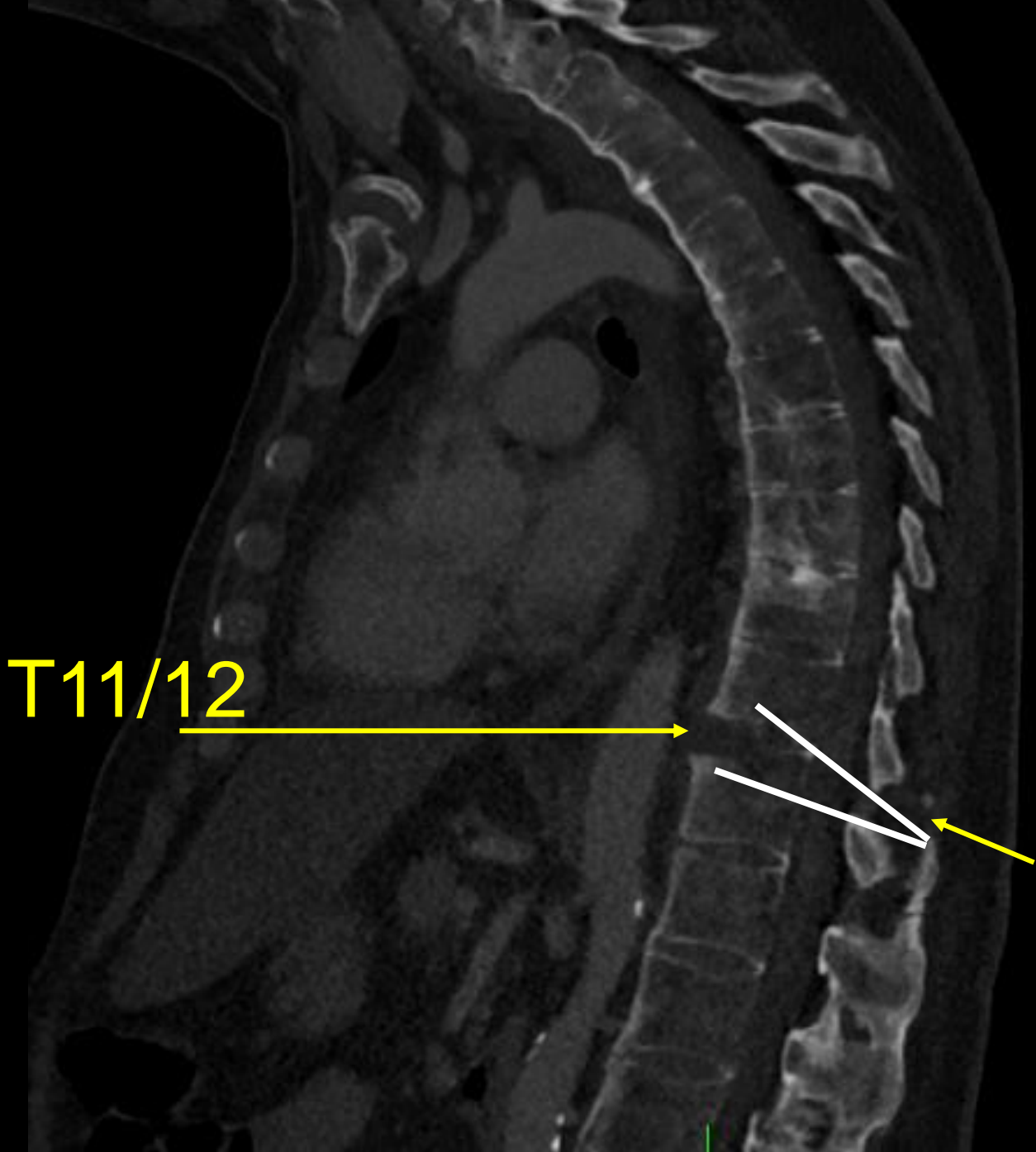
T11/12



Always look at the spine

Hyperextension injury
(‘Chance’)
3 column
Unstable

T11/12



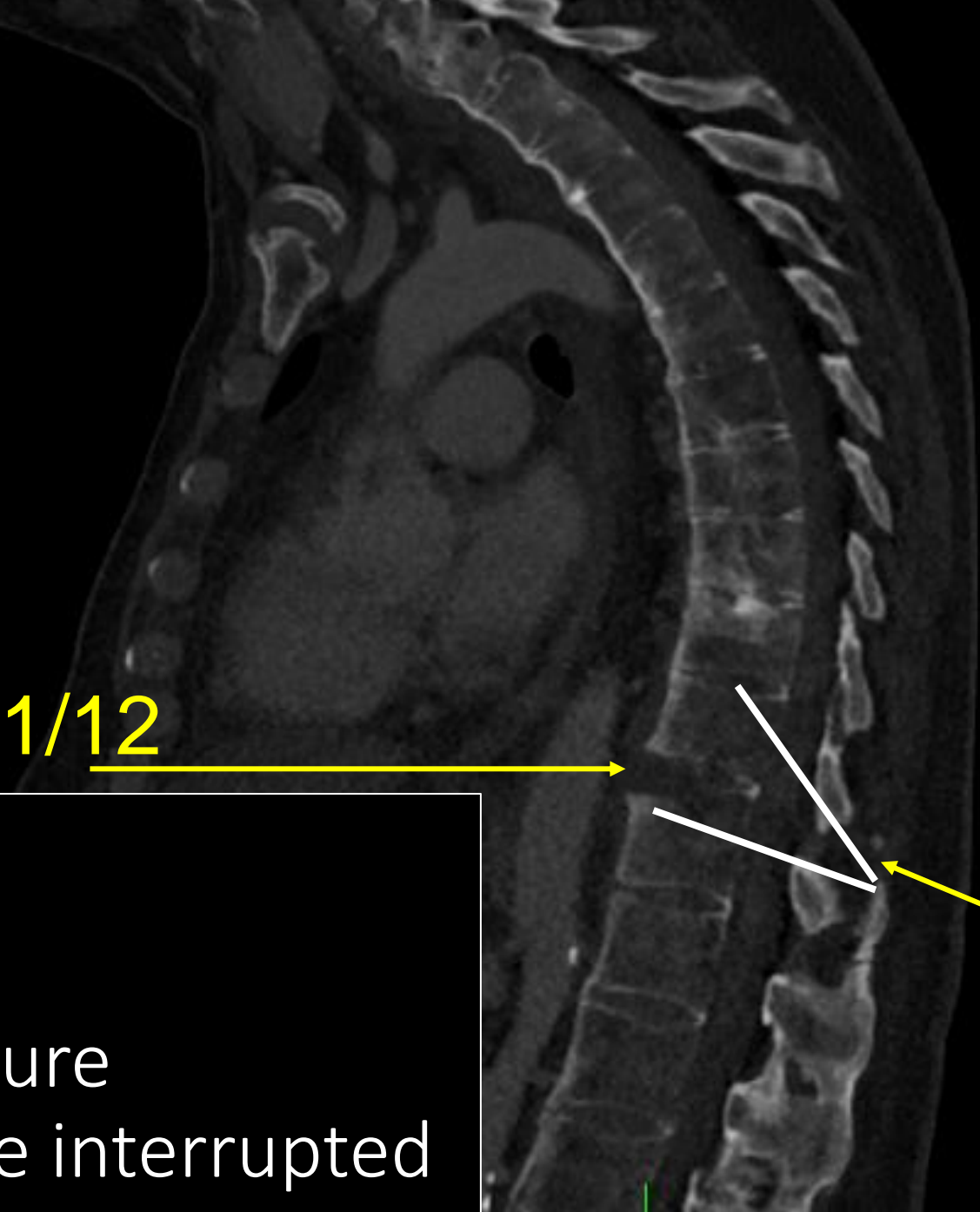
Always look at the spine

Hyperextension injury
(‘Chance’)
3 column
Unstable

T11/12

Learning Points:

1. Always look at the spine
2. Rigid Spine? Higher risk of fracture
3. Look where the osteophytes are interrupted



CHEST -CHECKLIST

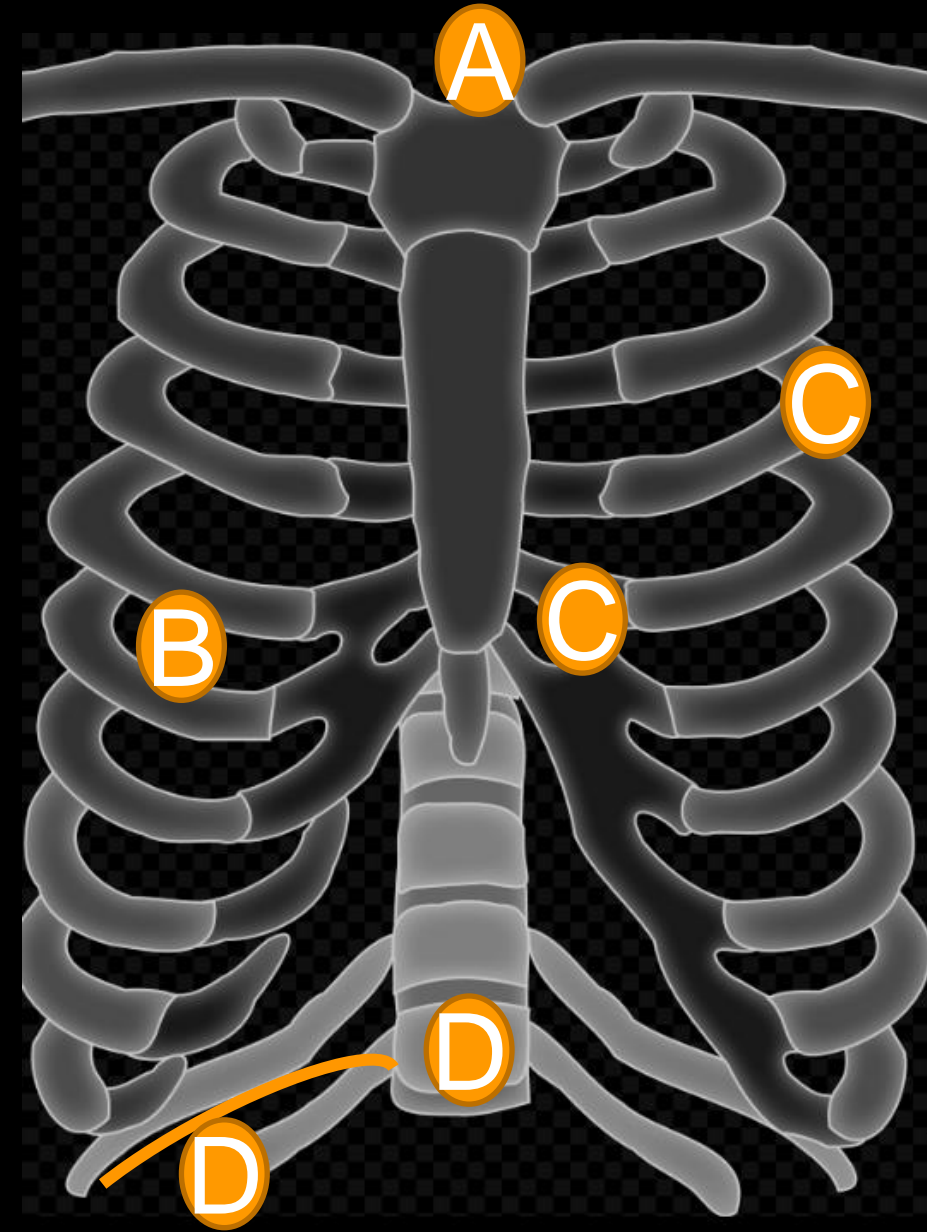
Checklist

A airway

B breathing

C circulation, chest wall,
costal cartilage

(3)D diaphragm, disability



Name one useful thing you have learnt or re-learnt today

Nobody has responded yet.

Hang tight! Responses are coming in.

Thank you

Dr Sadie Syed

Dr Yassir Al-Radhi

Dr Marcela delaHoz Polo

Dr John Curtis

Dr Nicola Batrick

Dr Elika Kashef

Mr Reza Mobasheri

Prof David Nott

Mr Chris Aylwin

Dr Sarah Sheard

Dr Samir Mahboobani

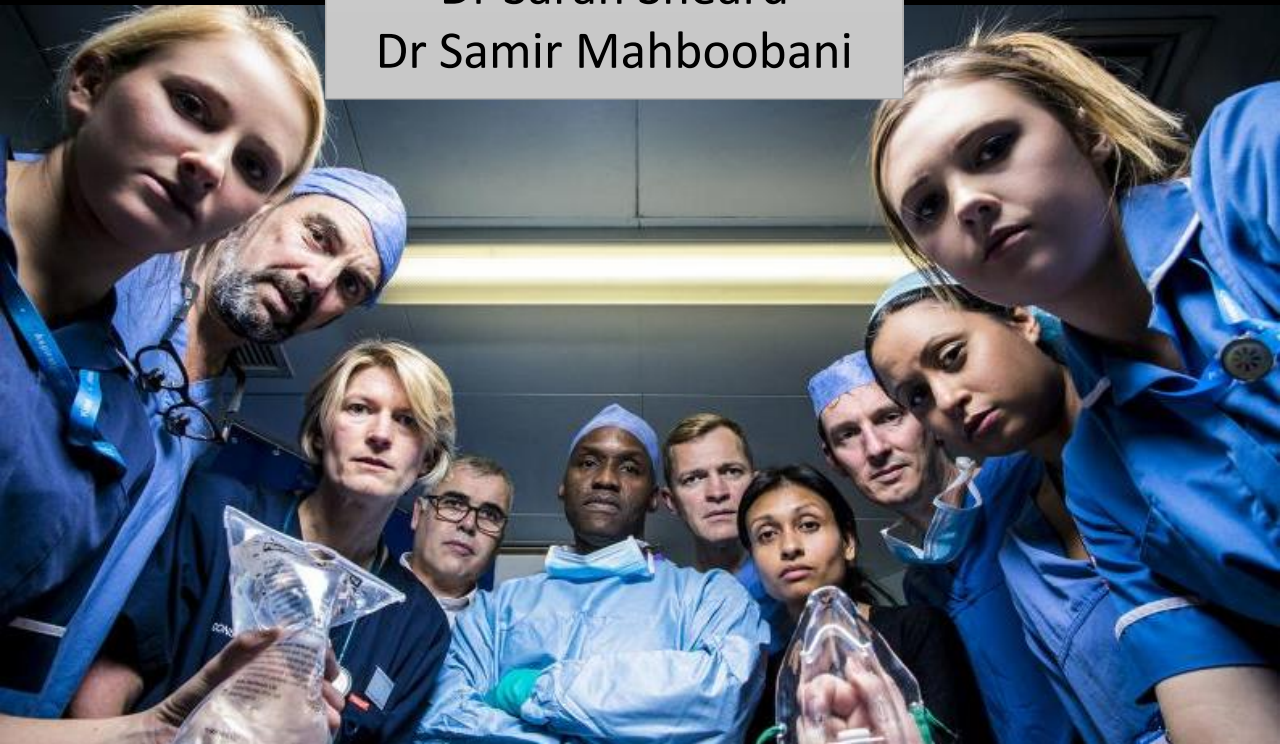


ESER
ANNUAL SCIENTIFIC MEETING 2024
“Stronger, Together”


14-16 October 2024
Valencia - Spain

Join us !

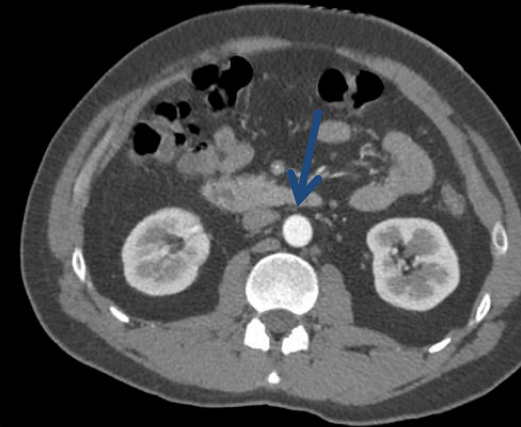www.eser2024.org



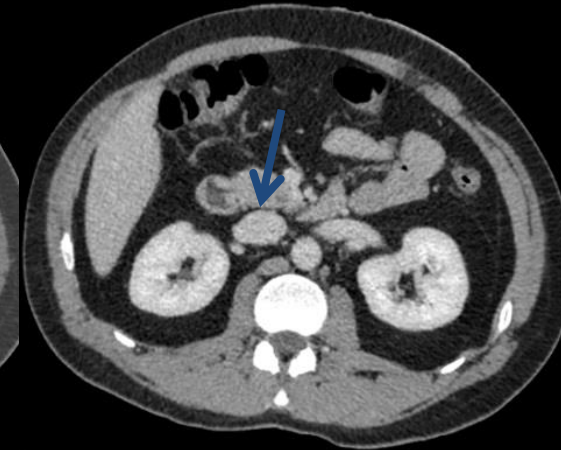
1 bolus contrast, 2 x scans



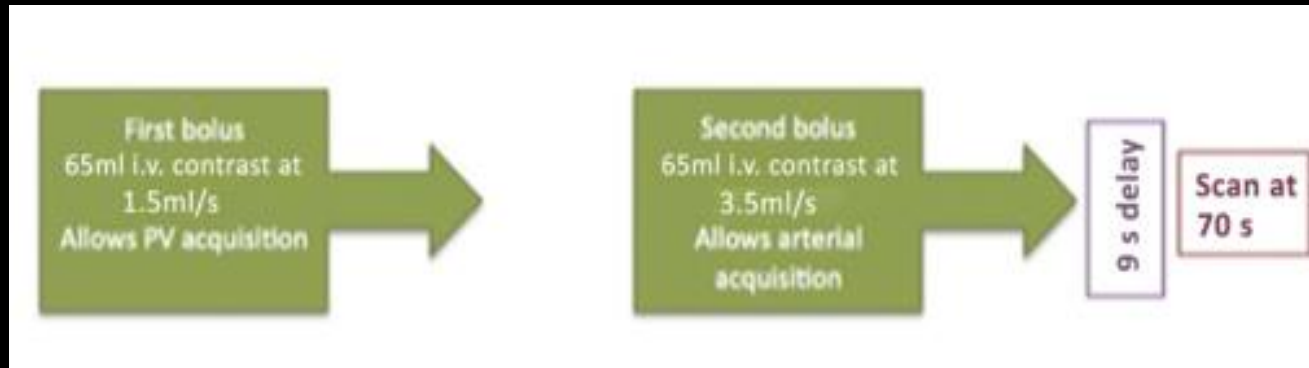ARTERIAL



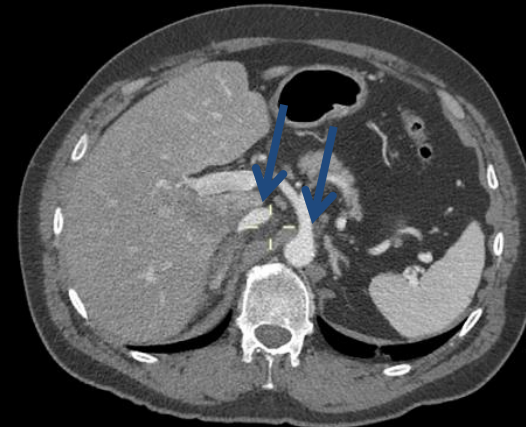VENOUS



2 bolus contrast, 1 x scans



ARTERIAL AND VENOUS COMBI



**BIPHASIC
COMBI
CAMP BASTION**