

Initial Case Experience: Diagnosis of Left Upper Lobe 3 cm Mass

Dr. Jason McClune

CASE STUDY

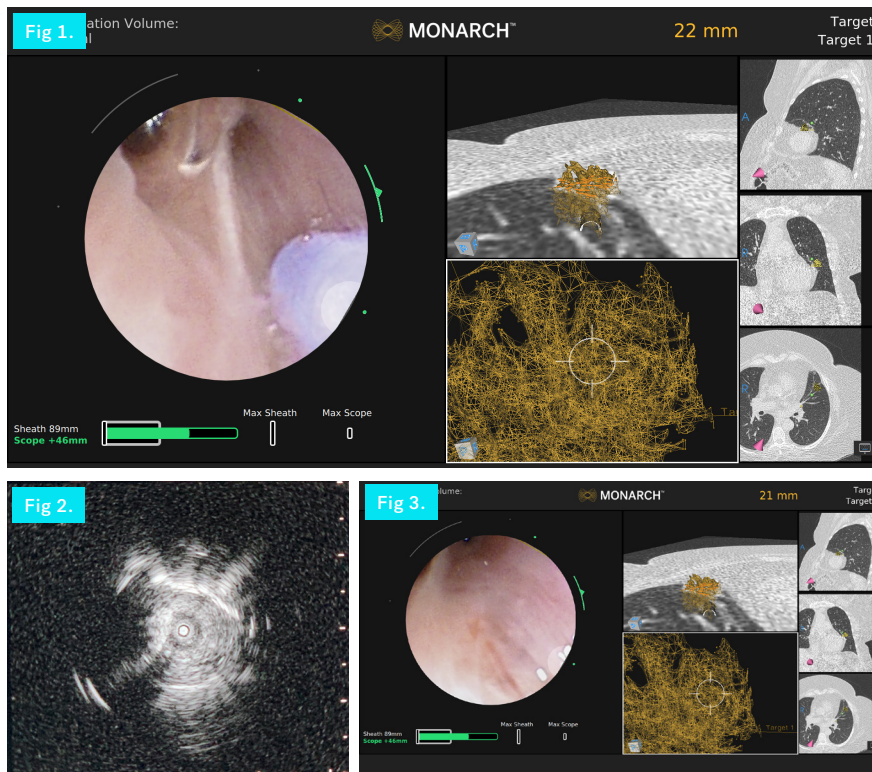


Fig 1. MONARCH® screen showing deployment of biopsy tools

Fig 2. REBUS Eccentric pattern

Fig 3. MONARCH® Platform within the targeted area

NODULE CHARACTERISTICS

Lobar Location

Left Upper Lobe, Lingula

Nodule Size

31 mm

Procedure Details

REBUS: Eccentric

Fluoro: Invisible

Time to targeted location:

6:00 minutes

Total procedure time:

72:00 minutes

Biopsy instruments used: 21G

FNA needle

Final Diagnosis:

Adenocarcinoma

Therapeutic Interventions:

Lobectomy

BACKGROUND

A 73-year-old female was referred by her primary care physician for a lung mass located in the left upper lobe. The patient was initially put on a CT surveillance protocol due to the granulomatous characteristics of the mass and the proximity to the heart. The patient was sent to pulmonary for a MONARCH® Robotic-Assisted Bronchoscopy. This was the physician's initial experience with the platform.

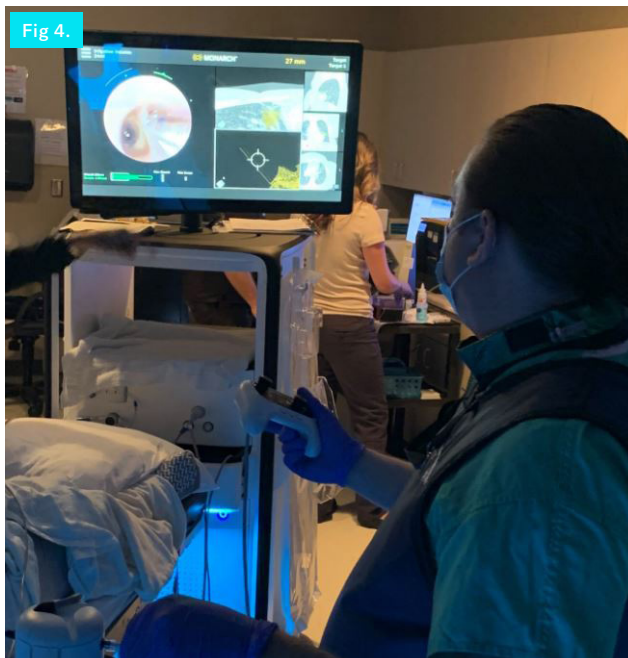PROCEDURE

Procedure initialization and navigation to the target were completed within 7 minutes of scope insertion. (**Fig. 1**) Radial EBUS (REBUS) was used to confirm the location and displayed an eccentric view of the targeted area. (**Fig. 2**) A 2 cm length, 21G flexible needle was inserted just distal to the end of the scope to penetrate the airway wall. (**Fig. 3**) Precise micro-adjustments were made with the MONARCH® scope to align the needle tip with the correct trajectory to the target. (**Fig. 4**) Direct visualization and fluoroscopy were used to confirm the needle traversed through the airway wall and instrument slippage was mitigated. Additional biopsies were attained using small positional changes in a grid-like fashion around the area in question.

The pre-procedure suspicion of granuloma was ruled when final pathology results confirmed a diagnosis of early stage adenocarcinoma. The patient was referred to surgery for a lobectomy of stage 1 cancer.

CONCLUSION

The integrated camera design of the MONARCH® Platform afforded the ability to make small controlled adjustments with the tip of the scope while also deploying tools to achieve the ideal trajectory and evaluate for tissue engagement. The MONARCH® controller allows for a seamless one-handed approach to passing instruments and making positional changes. These features played an integral role in obtaining a diagnosis for this patient.



A new biopsy optimization technique consisting of simultaneous scope manipulation & biopsy tool deployment with live vision achieved a diagnosis in our first MONARCH procedure.

Fig 4. Physician deploying biopsy tools into the MONARCH® Platform



Jason McClune, M.D. Memorial Health University Medical Center, Savannah, GA

Dr. Jason McClune is a Pulmonary Disease & Critical Care physician based in Savannah, GA. He has more than 15 years of experience in pulmonary disease and his clinical interest include diagnosing and treating lung and breathing problems.

Indications for Use: The MONARCH® Platform and its accessories are intended to provide bronchoscopic visualization of and access to patient airways for diagnostic and therapeutic procedures.

Important Safety Statement: Complications from bronchoscopy are rare and most often minor, but if they occur, may include breathing difficulty, vocal cord spasm, hoarseness, slight fever, vomiting, dizziness, bronchial spasm, infection, low blood oxygen, bleeding from biopsied site, or an allergic reaction to medications. It is uncommon for patients to experience other more serious complications (for example, collapsed lung, respiratory failure, heart attack and/or cardiac arrhythmia).

