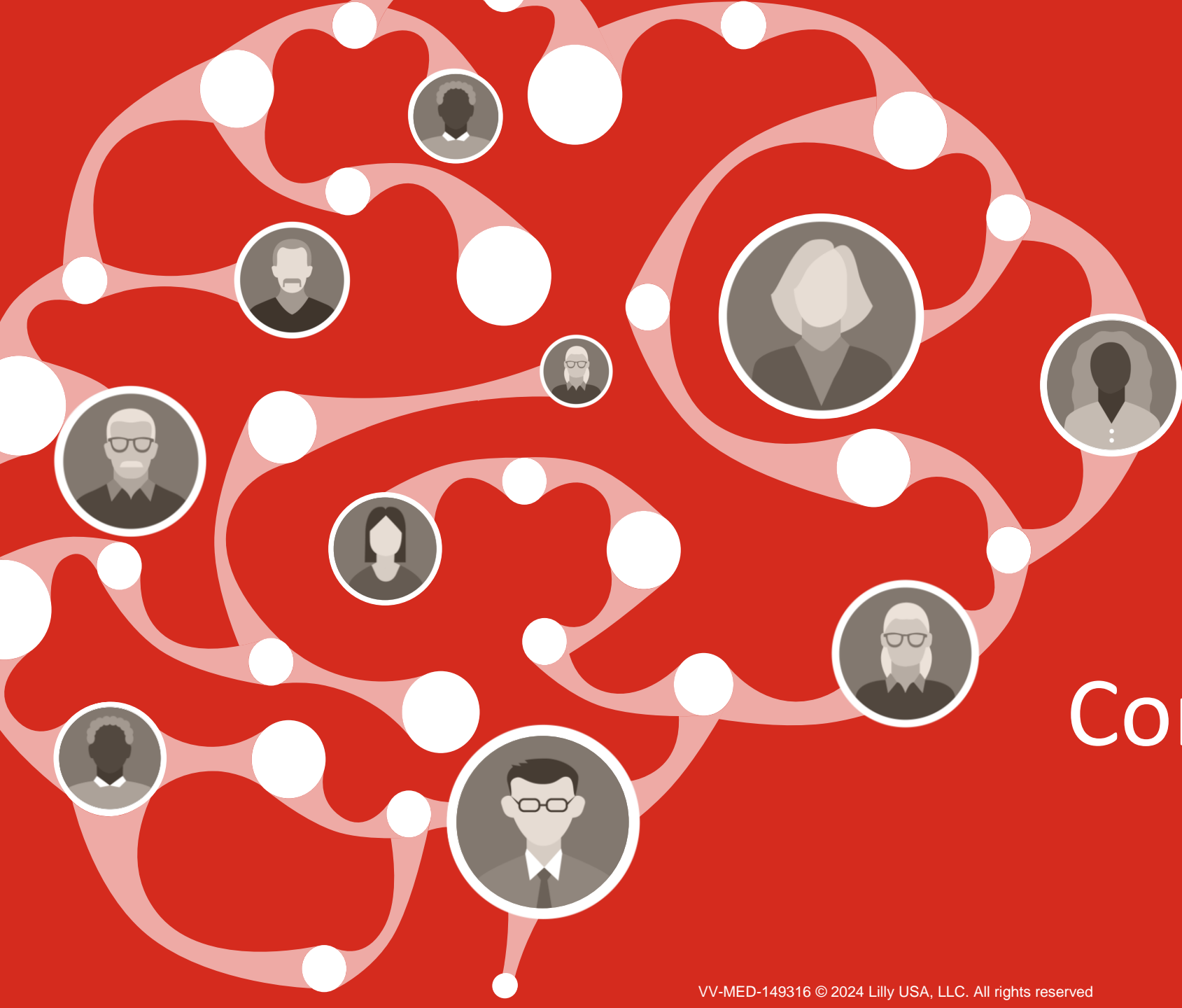

ConnectAD™



Welcome to **ConnectAD**[™], a clinical case series created by the Eli Lilly and Company Neuroscience medical education team. This series is intended to connect healthcare professionals to resources that help them detect, diagnose, and manage Alzheimer's disease.



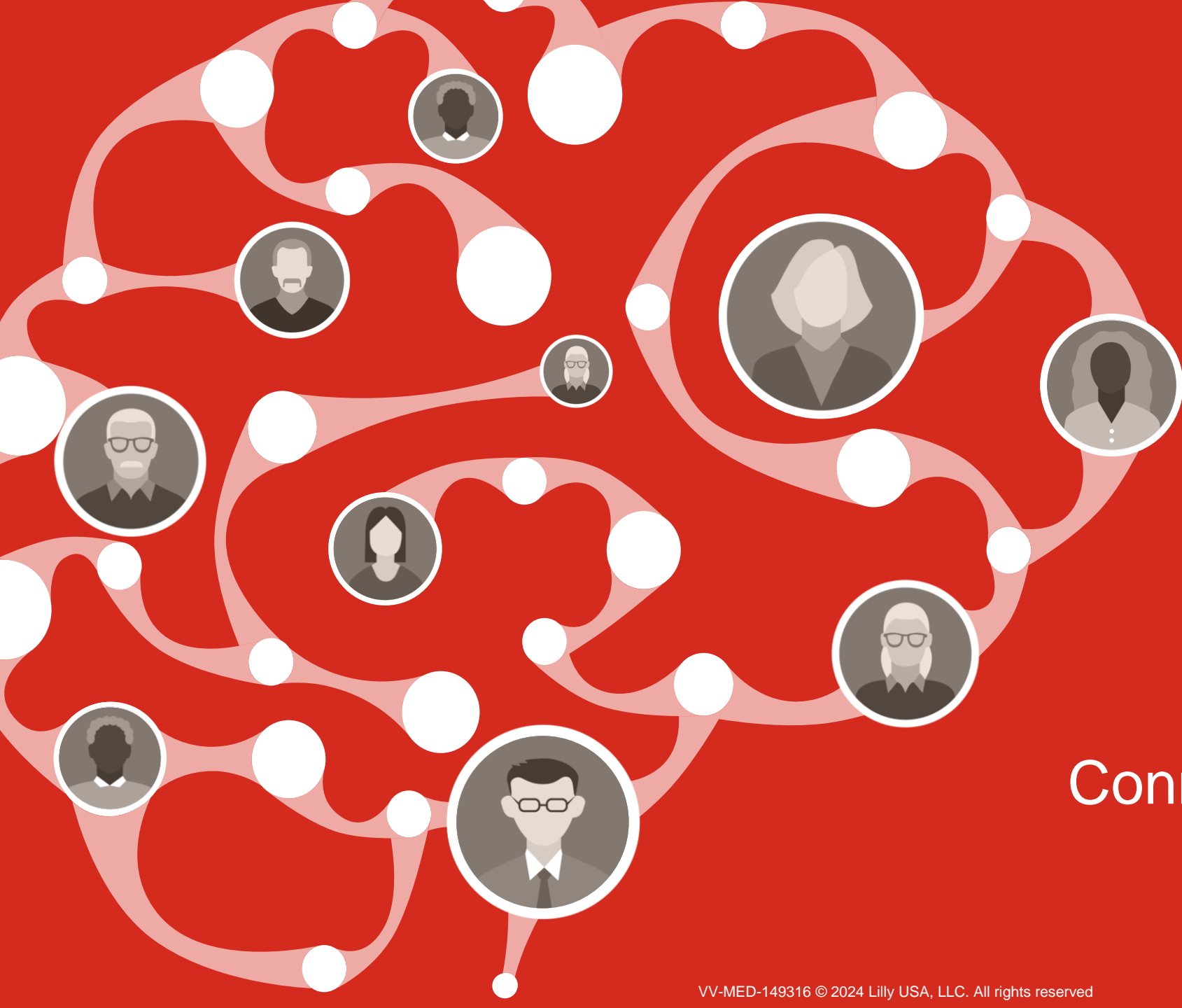
Disclaimer

The content for this case was created by Eli Lilly and Company and is inspired by scenarios clinicians may encounter while caring for patients with Alzheimer's disease.

A variety of cognitive and diagnostic tests can reasonably be used in the detection and diagnosis of Alzheimer's disease. Inclusion of specific cognitive and/or diagnostic tests in this case reflects the diversity of clinical preferences, and the use of particular diagnostic tools does not imply endorsement or recommendation by Lilly.

Learning Objectives

- Through completing this course, you will have a deeper understanding of:
 - The clinical presentation of Alzheimer's disease
 - How to integrate clinical and biomarker assessments to make an accurate diagnosis of Alzheimer's disease in the earliest stages



Connect with Beverly



Our Patient

Beverly



79 years old



Female



Black



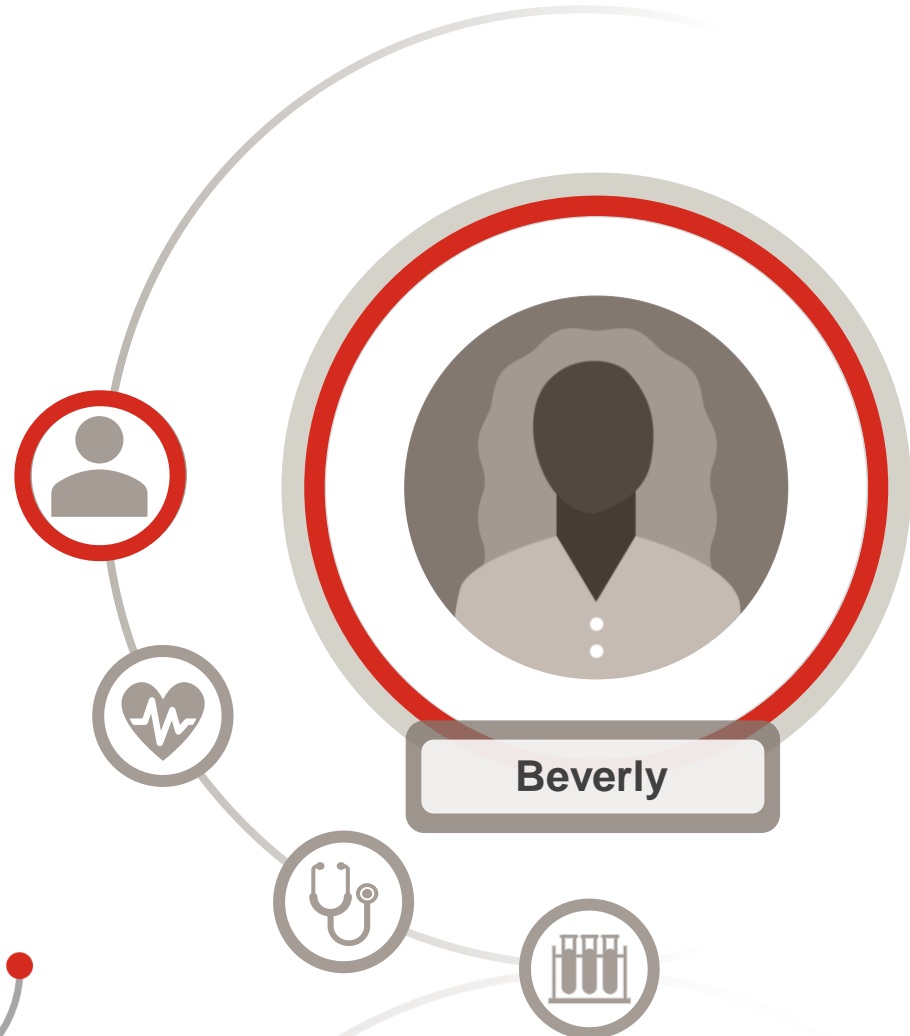Widowed



College degree



Retired schoolteacher



Clinical Information and History

Beverly was accompanied to her appointment by her adult daughter. Beverly denies having issues, but her daughter reports increasing difficulties with memory, particularly around financial matters



Clinical history

- Diabetes
- Hypertension
- Urinary incontinence
- High cholesterol



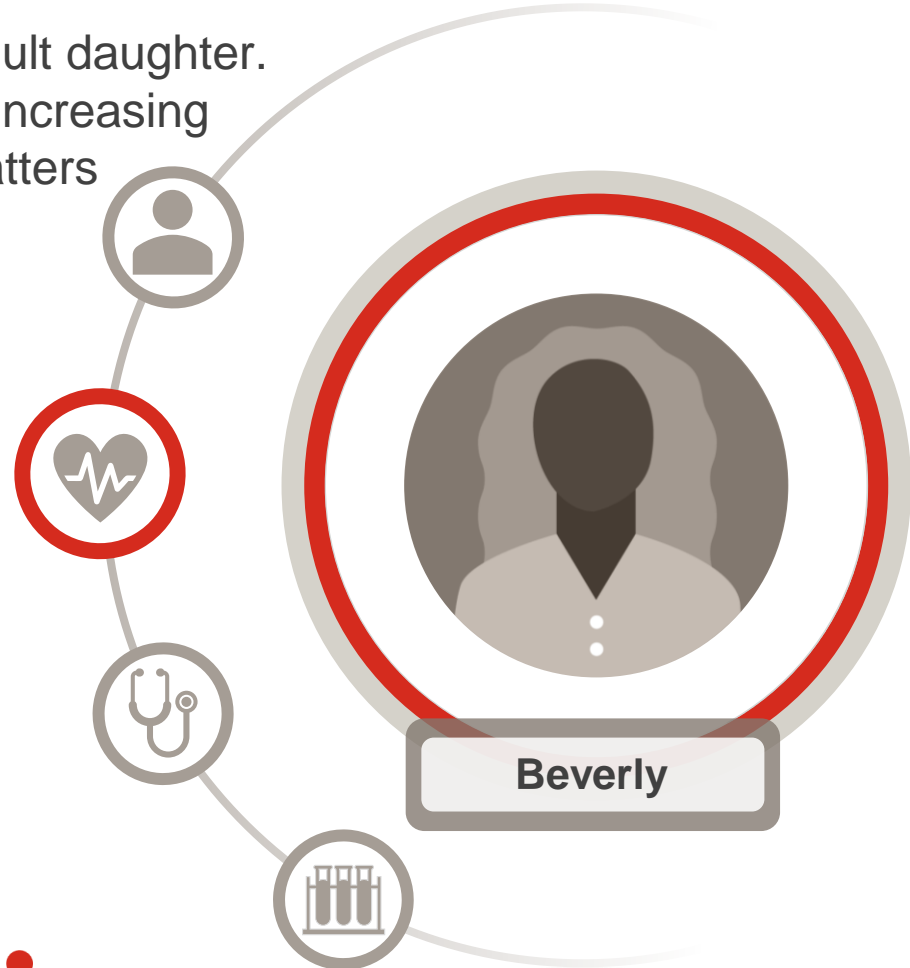
General health

- Heart rate: 79 bpm
- Blood pressure: 140/90 mmHg



Current medication (class):

- Statin
- Angiotensin receptor blocker (ARB)
- Calcium channel blocker
- Sulfonylurea



Initial Clinical Assessment



General neurological exam: Normal



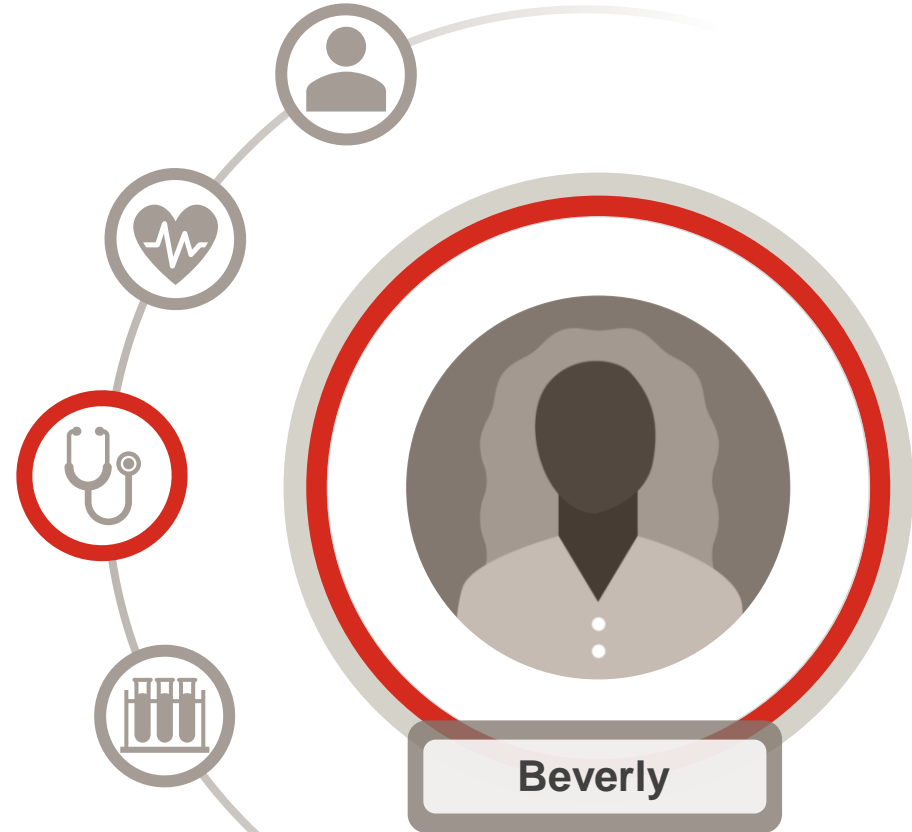Mental status

- Alert and responsive
- Beverly reports that she is capable of all activities of daily living and still drives
- Daughter reports Beverly:
 - Has been late with bills on a few occasions
 - Can no longer manage her finances
 - May not be taking her medications as prescribed
 - Was recently hospitalized with a UTI, and there were concerns regarding her hygiene habits



Cognition

- MoCA: 21/30 (normal ≥ 26)
- AD8 Questionnaire (daughter): 4 (normal 0-1; cognitive impairment likely >2)



Additional Findings



Blood work:

Normal:

- Complete blood count (CBC)
- Electrolytes
- Creatinine
- Thyroid stimulating hormone (TSH)
- Vitamin B12

Elevated:

- Glucose



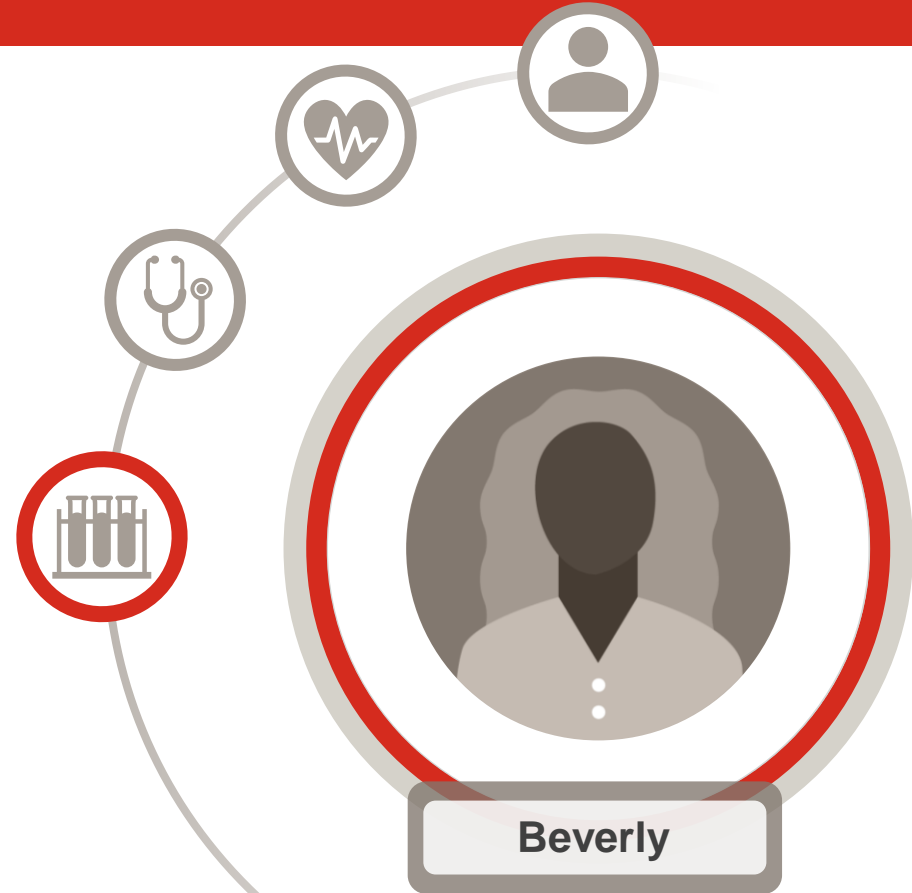Brain MRI

- Mild cortical atrophy
- Mild white matter hyperintensities
- No gross abnormalities



Amyloid PET

- Significant neocortical accumulation



Given the patient information presented, what is the diagnosis?

1. Normal Aging
2. Vascular Dementia
3. MCI due to AD
4. Mild Dementia due to AD
5. Other



*Given the patient information presented,
what is the diagnosis?*

Option 4:
Mild Dementia due to AD



Justification for Diagnosis

Why is Beverly diagnosed with Mild Dementia due to AD?

Beverly is presenting with clinical symptoms consistent with the mild dementia stage of AD, which are corroborated by clinical assessment.

While Beverly denies having issues with memory and performing everyday activities, her clinical assessment and the report from a close care partner raise concerns regarding her cognitive abilities; these are likely to be contributing to some of the reported functional impairments (mistakes with finances, missing medications and/or insufficient hygiene habits leading to health issues/hospitalization). The slow onset and gradual worsening of these issues are consistent with AD.

Importantly, pathology consistent with AD was seen within the amyloid PET assessment, which confirmed the suspicion that Beverly's mild dementia was caused by AD.



Key Learnings in Beverly's Case (1 of 2)

Beverly displays anosognosia, a lack of recognition or denial of problems,¹ and her daughter's contribution to the clinical history and symptoms was very important for understanding Beverly's level of functional independence

Anosognosia is very common in patients with early symptomatic AD²

- Anosognosia can be identified by comparing the ratings given by the patients on their own level of performance on tasks of daily living with answers provided by their care partners¹
- It is important for care partners to attend clinical appointments to get the full picture of a patient's capabilities
- It should be considered however, that the care partner may be influenced by several factors, such as emotional and cognitive state, and the amount of time they spend with the patient¹



AD=Alzheimer's Disease.

1. Starkstein SE, et al. *J Neurol Neurosurg Psychiatry*. 2006;77(6):719-725. 2. Tondelli M, et al. *Front Psychiatry*. 2021;12:658934.

VV-MED-149316 © 2024 Lilly USA, LLC. All rights reserved

Key Learnings in Beverly's Case (2 of 2)

Benefits of utilizing PET imaging to detect biomarkers of AD

Amyloid PET is a diagnostic imaging procedure in which a radioactive agent binds to A β in the brain^a allowing clinicians to estimate A β neuritic plaque density¹⁻³

- Advantages⁴:
 - A β plaques are one of the earliest known neuropathological hallmarks of AD
 - Radiotracer retention time matches the spreading pattern of A β plaques
- Limitations⁴:
 - No standard method for quantifying A β plaques
 - Weak correlation between A β deposition and AD clinical severity
 - A β accumulation stabilizes in late-stage AD




^aFlorbetapir F 18 binds to β -amyloid aggregates; florbetaben F 18 and flutemetamol F 18 bind to β -amyloid plaques.¹⁻³

A β =Amyloid Beta; AD=Alzheimer's Disease; PET=Positron Emission Tomography.

1. Amyvid (florbetapir F 18) [US Prescribing Information]. Indianapolis, IN: Eli Lilly and Company, 2019. 2. Vizamyil (flutemetamol F 18) [US Prescribing Information].

3. Neuraceq (florbetaben F 18) [US Prescribing Information]. Warwick, UK: Life Molecular Imaging Ltd., 2021. 4. van Oostveen WM, de Lange ECM. *Int J Mol Sci.* 2021;22(4):2110.



Thank you for connecting
with Beverly

