

ConnectAD™



Welcome to **ConnectAD**TM, a clinical case series created by the Eli Lilly and Company Neuroscience medical education team. This series is intended to connect healthcare professionals to resources that help them detect, diagnose, and manage Alzheimer's disease.



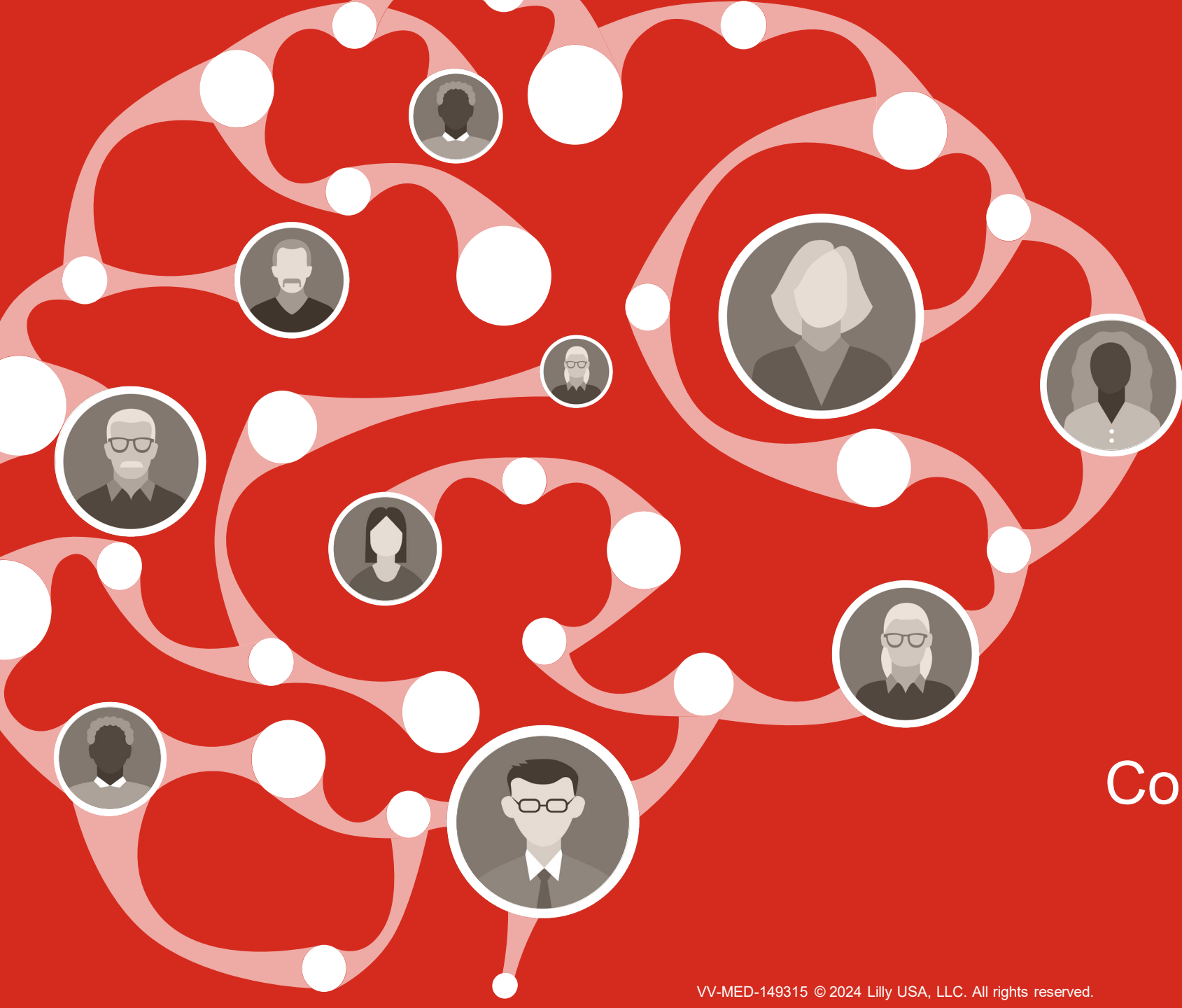
Disclaimer

The content for this clinical case was developed in collaboration between a group of global clinicians who care for patients with Alzheimer's disease and Eli Lilly and Company.

A variety of cognitive and diagnostic tests can reasonably be used in the detection and diagnosis of Alzheimer's disease. Inclusion of specific cognitive and/or diagnostic tests in this case reflects the diversity of clinical preferences, and the use of particular diagnostic tools does not imply endorsement or recommendation by Lilly.

Learning Objectives

- Through completing this course, you will have a deeper understanding of:
 - The clinical presentation of Alzheimer's disease
 - How to integrate clinical and biomarker assessments to make an accurate diagnosis of Alzheimer's disease in the earliest stages



Connect with John



Our Patient

John



61 years old



Male



White



Married, 1 child



College degree



Graphic designer



Family history

- Mother and grandmother diagnosed with dementia in their 60s (cause unknown)



Clinical Information and History

Over the past few years, John has manifested progressive behavioral changes and difficulties in language.

- John reports feeling angrier and more irritable, mistreating colleagues at work
- He can no longer:
 - Organize or plan projects
 - Work without an assistant
 - Communicate effectively – speaks in abbreviated sentences and chooses the incorrect words
- His work supervisor has encouraged him to pursue evaluation to address these issues




General health

- Heart rate: 67 bpm
- Blood pressure: 124/77 mmHg



Current medication

- None



Initial Clinical Assessment



General neurological exam: Normal




Mental status

- Alert, aloof, limited insight, mildly argumentative, anomic, reduced speech initiation
- John reports:
 - He can perform activities of daily living independently
 - He can commute to work without issue
 - Issues at work are mostly due to changes in software
- John's wife reports:
 - He is at risk of losing his job or being forced to retire



Cognition

- MMSE: 20/30
- NPI-Q severity: 7/36
 - Apathy; irritability; disinhibition



Additional Findings



Blood work within normal limits, including:

- Complete blood count (CBC)
- Electrolytes
- Glucose
- Creatinine
- Thyroid stimulating hormone (TSH)
- Vitamin B12



Brain MRI

- Moderate atrophy with left frontoparietal predilection



Amyloid PET

- The scan is negative, indicating sparse-to-no neuritic plaques



Given the patient information presented, what is the diagnosis?

1. Vascular dementia
2. MCI due to AD
3. Frontotemporal dementia (FTD)
4. Corticobasal degeneration
5. Other



*Given the patient information presented,
what is the diagnosis?*

Option 3:
Frontotemporal dementia (FTD)



Justification for Diagnosis

Why is John diagnosed with frontotemporal dementia?

John's clinical profile is consistent with FTD

- Symptom presentation:
 - Predominantly behavioral and emotional dysfunction
 - Early onset
 - Quick progression
- Strong family history of early-onset dementia

Additionally, biomarker assessment is not consistent with a diagnosis of AD

- Amyloid PET imaging: The scan is negative and demonstrates sparse-to-no A β deposition

Brain FDG PET could be considered for additional biomarker testing to support the diagnosis of FTD.



Key Learnings in John's Case (1 of 3)

What is frontotemporal dementia (FTD)?

- FTD is a neurodegenerative disorder characterized by changes in behavior and/or language due to selective atrophy of the frontal and temporal lobes^{1,2}
- FTD is often misdiagnosed as AD³ and is the second leading cause of early-onset dementia after AD²

FTD

Onset	<ul style="list-style-type: none">• Typically early-onset (<65 years old)¹
% familial cases	<ul style="list-style-type: none">• 30-50%¹
Typical early symptoms	<ul style="list-style-type: none">• Changes in behavior and/or language³
Heritability	<ul style="list-style-type: none">• Varies across subtypes; 48% for bvFTD¹
Genetics	<ul style="list-style-type: none">• Causative genes: <i>MAPT</i>, <i>GRN</i>, <i>C9orf72</i>, <i>TBK1</i>¹• Key risk genes: <i>TMEM106B</i>, <i>RAB8</i>, <i>HLA</i>, <i>GFRA2</i>¹
Biomarkers	<ul style="list-style-type: none">• CSF/plasma biomarkers: Vary according to underlying disease mechanism, but include elevated p-Tau, reduced Aβ₄₂/Aβ₄₀ ratio, and presence of GFAP¹• Neuroimaging biomarkers: MRI, FDG-PET¹



A β =Amyloid Beta; AD=Alzheimer's Disease; bvFTD=Behavioral Variant Frontotemporal Dementia; C9orf72=Chromosome 9 Open Reading Frame 72; CSF=Cerebrospinal Fluid; FDG=Fluorodeoxyglucose; FTD=Frontotemporal Dementia; GFAP=Glial Fibrillary Acidic Protein; GFRA2=Glial Cell-derived Neurotrophic Factor Family Receptor Alpha 2; GRN=Progranulin; HLA= Human Leucocyte Antigen; MAPT=Microtubule-Associated Protein Tau; MRI=Magnetic Resonance Imaging; PET=Positron Emission Tomography; p-Tau=Phosphorylated Tau; RAB8=Ras-Associated Binding Protein 8; TBK1=TANK Binding Kinase 1; TMEM106B=Transmembrane protein 106B.

1. Antonioni A, et al. *Int J Mol Sci.* 2023;24(14):11732. 2. Leroy M, et al. *Alzheimers Res Ther.* 2021;13(1):19. 3. <https://altoida.com/blog/frontotemporal-dementia-different-from-alzheimers/> (Accessed January 2024).

Key Learnings in John's Case (2 of 3)

In John's case, age of onset and family history suggest early AD or FTD. Genetic testing could have been used to support diagnosis

Family history and genetic risk factors alone do not confirm diagnosis for AD nor FTD.^{1,2} Enough information was available to diagnose FTD without genetic testing in John's case.

	FTD	AD
Onset	Typically early-onset (<65 years old) ¹	Typically late-onset (>65 years old) ^{3,4}
% familial cases	30-50% ¹	<1% ⁵
Typical early symptoms	Changes in behavior and/or language ³	Memory impairment ³
Heritability	Varies across subtypes; 48% for bvFTD ¹	Estimates vary between 38 and 84% ⁶
Genetics	Causative genes: <i>MAPT</i> , <i>GRN</i> , <i>C9orf72</i> , <i>TBK1</i> ¹ Key risk genes: <i>TMEM106B</i> , <i>RAB8</i> , <i>HLA</i> , <i>GFRA2</i> ¹	Causative genes: <i>APP</i> , <i>PSEN1</i> , <i>PSEN2</i> ⁴ Key risk gene: <i>APOE</i> ⁴
Biomarkers	CSF/plasma biomarkers: Vary according to underlying disease mechanism ¹ Neuroimaging biomarkers: MRI, FDG-PET ¹	Hallmark biomarkers are A β and tau in CSF/neuroimaging ¹



A β =Amyloid Beta; AD=Alzheimer's Disease; APOE=Apolipoprotein E; APP=Amyloid Precursor Protein; bvFTD=Behavioral Variant Frontotemporal Dementia; C9orf72=Chromosome 9 Open Reading Frame 72; CSF=Cerebrospinal Fluid; FDG=Fluorodeoxyglucose; FTD=Frontotemporal Dementia; GFAP=Glial Fibrillary Acidic Protein; GFRA2=Glial Cell-derived Neurotrophic Factor Family Receptor Alpha 2; GRN=Progranulin; HLA= Human Leucocyte Antigen; MAPT=Microtubule-Associated Protein Tau; MRI=Magnetic Resonance Imaging; PET=Positron Emission Tomography; PSEN=Presenilin; p-Tau=Phosphorylated Tau; RAB8=Ras-Associated Binding Protein 8; TBK1=TANK Binding Kinase 1; TMEM106B=Transmembrane protein 106B. 1. Antonioni A, et al. *Int J Mol Sci.* 2023;24(14):11732. 2. <https://alz.org/media/Documents/scientific-conferences/Figures-and-Tables-Clinical-Criteria-for-Staging-and-Diagnosis-for-Public-Comment-Draft-2.pdf> (Accessed January 2024). 3. <https://altoida.com/blog/frontotemporal-dementia-different-from-alzheimers/> (Accessed January 2024). 4. Hoogmartens J, et al. *Alzheimers Dement (Amst).* 2021;13(1):e12155. 5. <https://www.rarementiasupport.org/familial-alzheimers-disease/understanding-fad/> (Accessed January 2024). 6. Baker E, et al. *PLoS ONE.* 2023;18(4):e0281440.

Key Learnings in John's Case (3 of 3)

John's case is challenging, but assessment of biomarkers helps to confirm or reject a diagnosis of AD. In this case, an amyloid PET scan was utilized to assess the level of amyloid plaque present in the brain

Amyloid PET is a diagnostic imaging procedure in which a radioactive agent binds to A β in the brain^a allowing clinicians to estimate A β neuritic plaque density¹⁻³

- Advantages:
 - A β plaques are one of the earliest known neuropathological hallmarks of AD⁴
 - Amyloid PET Imaging indicates presence or absence of pathological insoluble plaques¹⁻³
- Limitations⁴:
 - Weak correlation between A β deposition and AD clinical severity
 - A β accumulation stabilizes in late-stage AD




^aFlorbetapir F 18 binds to A β aggregates; florbetaben F 18 and flutemetamol F 18 bind to A β plaques.¹⁻³

A β =Amyloid Beta; AD=Alzheimer's Disease; PET=Positron Emission Tomography.

1. Amyvid (florbetapir F 18) [US Prescribing Information]. Indianapolis, IN: Eli Lilly and Company, 2019. 2. Vizamyil (flutemetamol F 18) [US Prescribing Information].

3. Neuraceq (florbetaben F 18) [US Prescribing Information]. Warwick, UK: Life Molecular Imaging Ltd., 2021. 4. van Oostveen WM, de Lange ECM. *Int J Mol Sci.* 2021;22(4):2110.



Thank you for connecting
with John

