

The image features the Lilly ConnectAD logo centered on a textured, light-colored background with a red border. The word "Lilly" is written in a red, cursive script font, while "ConnectAD" is in a bold, red, sans-serif font. A small "TM" trademark symbol is positioned to the upper right of the "D" in "ConnectAD".

*Lilly* ConnectAD™

Detect · Diagnose

VV-MED-156574 © 2025 Eli Lilly and Company. All rights reserved.

# *Lilly* ConnectAD™

Welcome to ConnectAD™, a clinical case series created by the Eli Lilly and Company Neuroscience medical education team. This series is intended to connect healthcare professionals to resources that help them detect, diagnose, and manage Alzheimer's disease.

# Disclaimer

The content for this clinical case was developed in collaboration between a group of global clinicians who care for patients with Alzheimer's disease and Eli Lilly and Company.

A variety of cognitive and diagnostic tests can reasonably be used in the detection and diagnosis of Alzheimer's disease. Inclusion of specific cognitive and/or diagnostic tests in this case reflects the diversity of clinical preferences, and the use of particular diagnostic tools does not imply endorsement or recommendation by Lilly.

# Learning Objectives

Through completing this course, you will have a deeper understanding of:

①

The clinical presentation of Alzheimer's disease

②

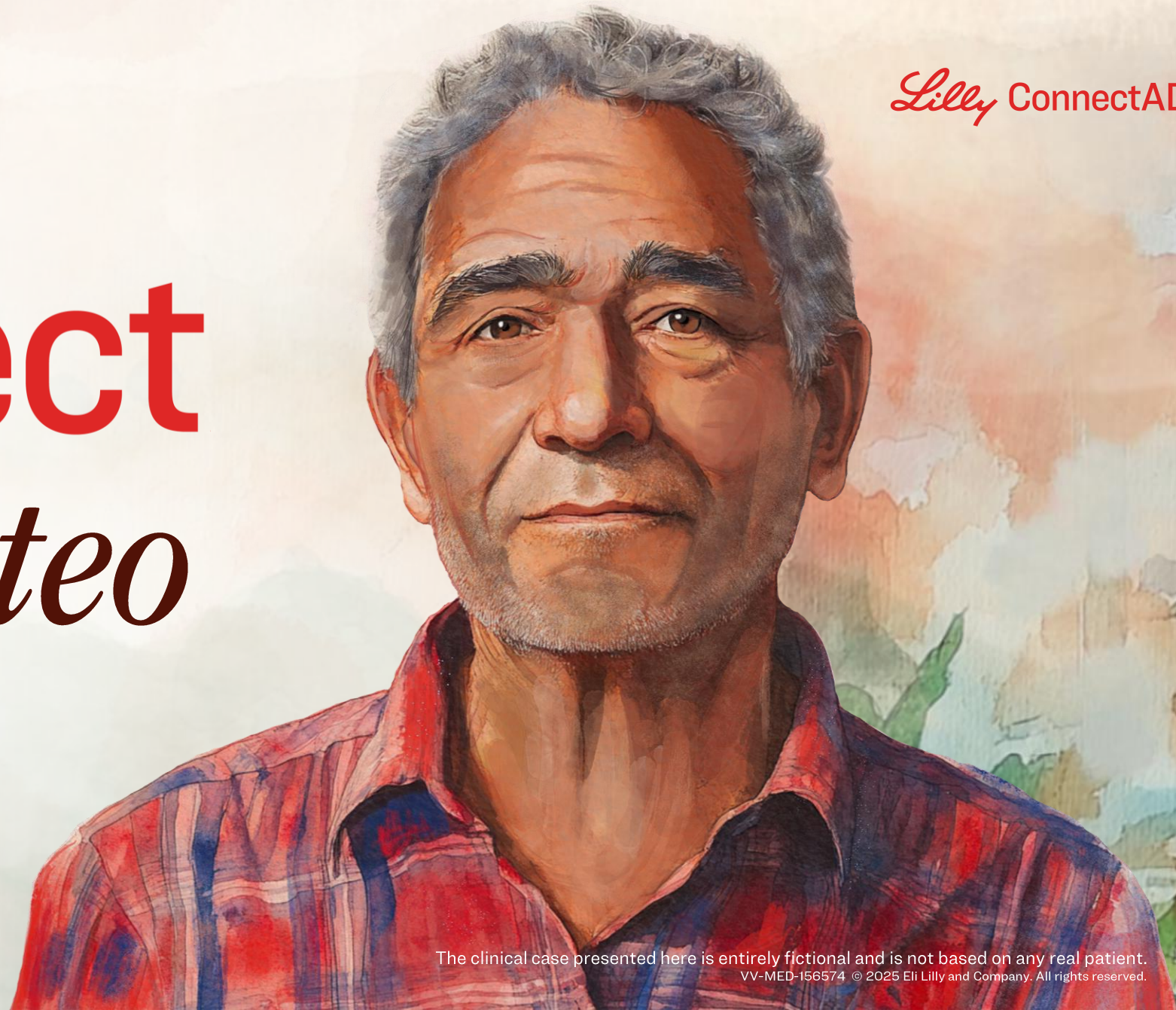How to integrate clinical and biomarker assessments to make an accurate diagnosis of Alzheimer's disease in the earliest stages

Lilly ConnectAD™

# Connect *with Mateo*


Detect · Diagnose

The clinical case presented here is entirely fictional and is not based on any real patient.  
VV-MED-156574 © 2025 Eli Lilly and Company. All rights reserved.



# Our Patient Mateo

- 73 years old
- Male
- Hispanic
- Married, 2 children, 2 grandchildren
- College degree
- High school teacher (retired)
- Family history
  - Colon cancer
  - Grandfather diagnosed with dementia (cause unknown)




# Clinical Information and History

Mateo has experienced progressive worsening of the following symptoms over the past 2.5 years:

- Difficulty remembering plans, dates, and events
- Repetition of questions in conversations

In the past year, he has required assistance from his wife in handling family finances, medical appointments, and medications.



# Clinical Information and History


## General health

- Heart rate: 82 bpm
- Blood pressure: 124/72 mmHg
- Adenomatous colon polyps (undergoing colonoscopy surveillance)

## Current medication


- Angiotensin receptor blocker (ARB)

bpm=Beats per Minute.



VV-MED-156574 © 2025 Eli Lilly and Company. All rights reserved.

# Initial Clinical Assessment



## **General neurological exam:** Normal **Mental status**

- Alert, diminished insight (no reports of memory concerns)
- Instrumental activities of daily living: Impaired (finances, medications, appointments)

## **Cognition**

- MMSE: 24/30 (normal  $\geq 25$ )
  - Time orientation: 3/5 (does not know date or day of the week)
  - Word recall: 0/3
  - Figure copy: Incorrect

# Additional Findings

## Blood work within normal limits, including:

- Complete blood count (CBC)
- Electrolytes
- Glucose
- Creatinine
- Thyroid stimulating hormone (TSH)
- Vitamin B12

## Brain MRI:

- No evidence of global or focal cortical atrophy
- No evidence of infarct, hemorrhage, or mass lesion

## CSF assay:

- $A\beta_{42}/A\beta_{40}$ : Low
- P-tau: High
- T-tau: High

# Given the Patient Information Presented, What is the Diagnosis?


① Mild dementia due to AD

② MCI due to AD

③ Preclinical AD

④ Normal cognitive aging

⑤ Other



**Mateo**

# Given the Patient Information Presented, What is the Diagnosis?


**1** Mild dementia due to AD

2 MCI due to AD

3 Preclinical AD

4 Normal cognitive aging

5 Other



**Mateo**

## Why is Mateo Diagnosed with Mild Dementia Due to AD?

Mateo is presenting with clinical symptoms consistent with mild dementia due to AD (including functional impairment). His symptoms are corroborated by clinical assessment.

Although Mateo's MRI results showed no other potential cause for his cognitive dysfunction, the assessment of AD-specific biomarkers in CSF confirms the presence of A $\beta$  fibrils and plaques in the brain, consistent with the pathology of AD.<sup>1</sup>

Evidence of functional impairment (requiring assistance for instrumental activities of daily living such as managing finances and medications) leads to the diagnosis of mild dementia due to AD.<sup>2</sup>

# Key Learnings in Mateo's Case (1 of 3)

**AD is the most common form of dementia. Although clinical presentations with memory impairment are suggestive of AD, presence of AD biomarkers is required to formulate a neuropathology-proven diagnosis.**

1. The diagnosis of AD has evolved; today, AD can be defined by clinical symptoms and neuropathological biomarkers of AD.<sup>1,2</sup>
2. Potential diagnostic AD biomarkers include<sup>1</sup>:
  - CSF A $\beta$  and tau
  - A $\beta$  or tau PET neuroimaging
3. AD neuropathology biomarkers are important for timely and accurate diagnosis, especially in earlier clinical stages of disease.<sup>1-3</sup>

A $\beta$ =Amyloid Beta; AD=Alzheimer's Disease; CSF=Cerebrospinal Fluid; PET=Positron Emission Tomography.

1. Jack CR Jr, et al. *Alzheimers Dement.* 2018;14:535-562. 2. Dubois B, et al. *Lancet Neurol.* 2021;20:484-496. 3. Porsteinsson AP, et al. *J Prev Alzheimers Dis.* 2021;8(3):371-386.

# Key Learnings in Mateo's Case (2 of 3)

## **MRI can be a useful assessment to<sup>1</sup>:**

- **Rule out non-AD conditions that can cause cognitive decline**
- **Provide information suggestive of AD; for example, observed hippocampal atrophy**

**MRI does not provide information on A $\beta$  and tau pathology, and therefore cannot be used as a standalone test for the diagnosis of AD.<sup>2</sup>**

## **Structural neuroimaging (MRI)**

- Is useful in evaluation of cognitive impairment by:
  - Ruling out several causes (eg, vascular lesions, mass lesions)<sup>1</sup>
  - Detecting atrophy (especially in the hippocampus/medial temporal lobe), which correlates with cognitive status and is a marker of neurodegeneration<sup>2</sup>
- MRI has limited sensitivity (~80%) for neuropathology-proven AD diagnosis and should therefore not be considered a stand-alone test to diagnose AD.<sup>1,2</sup> Patients with no notable MRI abnormalities could still potentially be positive for A $\beta$  and tau pathology and thus be on the AD continuum<sup>3</sup>

A $\beta$ =Amyloid Beta; AD=Alzheimer's Disease; MRI=Magnetic Resonance Imaging.

1. Park M, et al. *Korean J Radiol.* 2016;17(6):827-845. 2. Aramadaka S, et al. *Cureus.* 2023;15(5):e38544. 3. Jack CR Jr, et al. *Alzheimers Dement.* 2018;14:535-562.

# Key Learnings in Mateo's Case (3 of 3)

**The CSF biomarker assay can be used to confirm the presence of pathology consistent with AD.<sup>1</sup>**

## **CSF assays:**

1. Quantitatively measure the levels of A $\beta$  and tau protein within the fluid of the lumbar sac.<sup>2</sup>
2. Reflect the rates of A $\beta$  and tau protein production and clearance.<sup>2</sup>

### **Advantages include:**

- Less expensive than PET by 10- to 15-fold<sup>3</sup>
- Simultaneous information on A $\beta$  and tau biomarkers<sup>4</sup>

### **Limitations include:**

- CSF is obtained via lumbar puncture; this is invasive and can be uncomfortable for patients<sup>5</sup>
- Limited availability outside of specialized clinics<sup>6</sup>
- Do not detect regional A $\beta$  or tau deposition<sup>2,3</sup>

A $\beta$ =Amyloid Beta; AD=Alzheimer's Disease; CSF=Cerebrospinal Fluid; PET=Positron Emission Tomography.

1. Jack CR Jr., et al. *Alzheimers Dement.* 2024;20(8):5143-5169. 2. Jack CR Jr, et al. *Alzheimers Dement.* 2018;14:535-562. 3. Hansson O, et al. *Alzheimers Res Ther.* 2019;11(1):34. 4. Dubois B, et al. *Lancet Neurol.* 2021;20(6):484-496. 5. Lee JC, et al. *Exp Mol Med.* 2019;51(5):1-10. 6. Zetterberg H, et al. *Alzheimers Dement (Amst).* 2019;784-786.

Lilly ConnectAD™

Thank you for  
**Connecting**  
*with Mateo*

Detect · Diagnose

