

ConnectAD™



Welcome to **ConnectAD**[™], a clinical case series created by the Eli Lilly and Company Neuroscience medical education team. This series is intended to connect healthcare professionals to resources that help them detect, diagnose, and manage Alzheimer's disease.



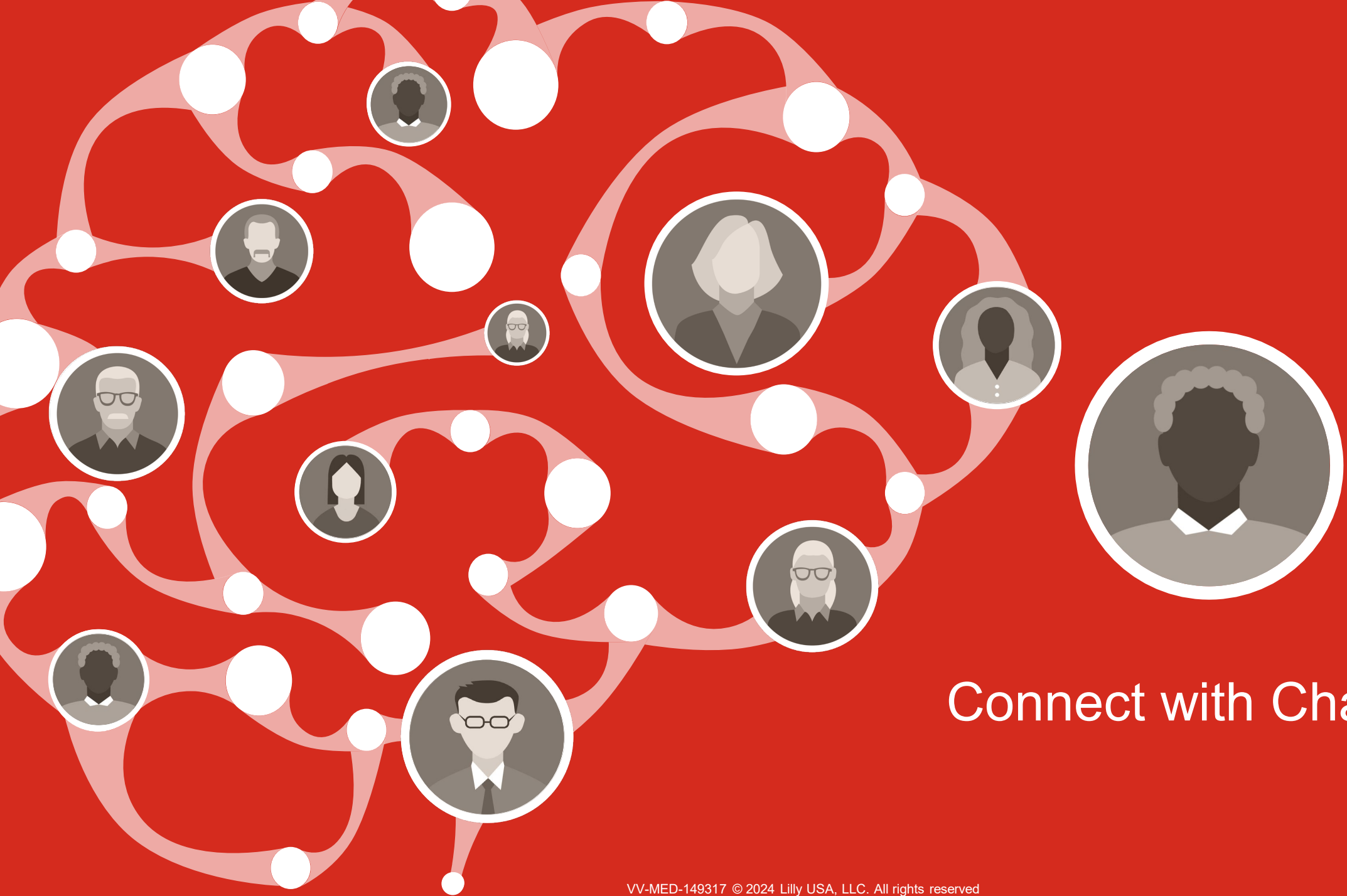
Disclaimer

The content for this case was created by Eli Lilly and Company and is inspired by scenarios clinicians may encounter while caring for patients with Alzheimer's disease.

A variety of cognitive and diagnostic tests can reasonably be used in the detection and diagnosis of Alzheimer's disease. Inclusion of specific cognitive and/or diagnostic tests in this case reflects the diversity of clinical preferences, and the use of particular diagnostic tools does not imply endorsement or recommendation by Lilly.

Learning Objectives

- Through completing this course, you will have a deeper understanding of:
 - The clinical presentation of Alzheimer's disease
 - How to integrate clinical and biomarker assessments to make an accurate diagnosis of Alzheimer's disease in the earliest stages



Connect with Charles



Our Patient

Charles



81 years old



Male



Black




Widowed



High school diploma



Retired electrician



Clinical Information and History

Charles attended his appointment with his adult son. His wife of 60 years passed away suddenly 7 months ago, and his family is concerned about him.

He has not been socializing with friends at their morning coffee group or card games, and is struggling to keep up with laundry, housework, and cooking. He used to love to read but reports that he can't seem to retain the information anymore.



Clinical history

- Hypertension (15 years)
- Left knee replacement 7 years ago



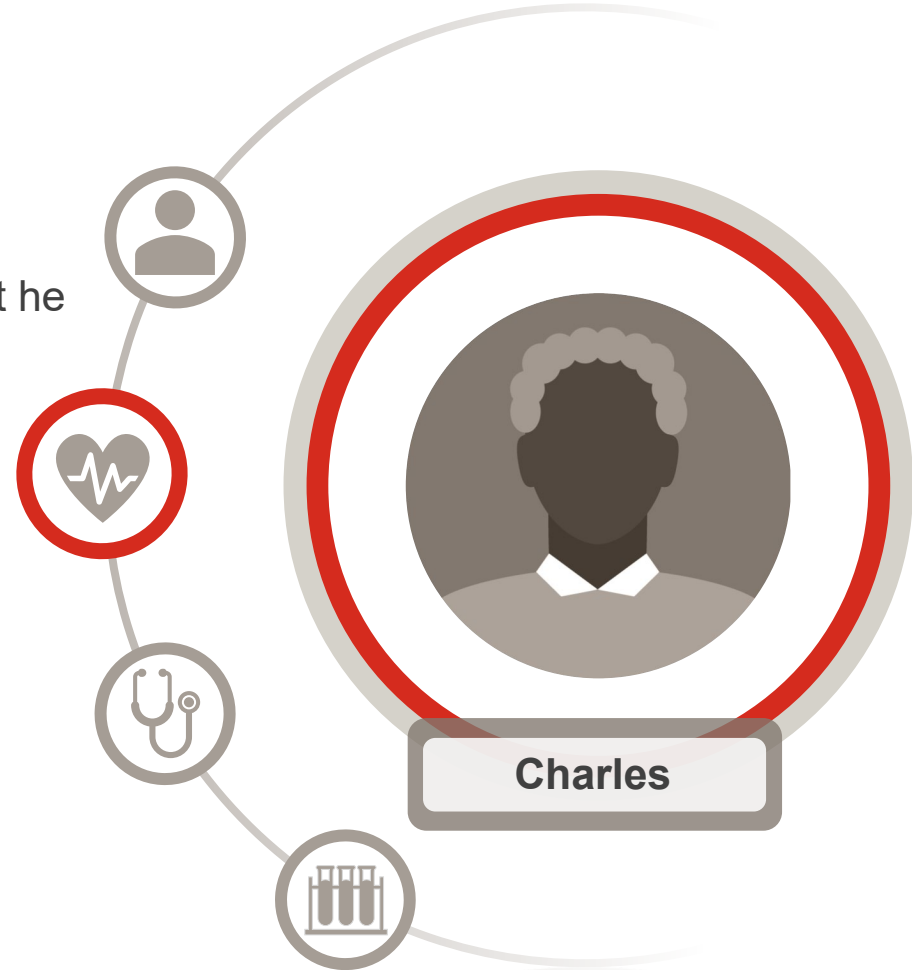
General health

- Heart rate: 65 bpm
- Blood pressure: 130/80 mmHg



Current medication (class)

- Analgesic PRN for occasional knee pain
- ACE inhibitor 5 mg once daily



Initial Clinical Assessment



General neurological exam: Normal




Mental status

- Alert and responsive; tearful when speaking of his wife
- Reports that he is capable of all activities of daily living, but that he hadn't realized how much his wife had done for him and their family
- No significant driving issues or other safety concerns



Cognition

- Mini-Cog: 5/5 (normal ≥ 3)
- Patient Health Questionnaire-9: 9/27 (normal ≤ 4 , mild depression 5-9)



Additional Findings



Blood work within normal limits, including:

- Complete blood count (CBC)
- Electrolytes
- Glucose
- Creatinine
- Thyroid stimulating hormone (TSH)
- Vitamin B12



Brain MRI

- Mild cortical atrophy
- Mild white matter hyperintensities
- No gross abnormalities



CSF Testing

- Negative for biomarkers consistent with AD



Given the patient information presented, what is the diagnosis?

1. Major depressive disorder
2. Adjustment disorder NOS
3. MCI due to AD
4. Mild dementia due to AD
5. Other



*Given the patient information presented,
what is the diagnosis?*

Option 1:
Major depressive disorder



Justification for Diagnosis

Why is Charles diagnosed with major depressive disorder?

For the past 7 months, Charles has been grieving the loss of his wife and has been struggling to keep up with the housekeeping and other activities that she previously managed. In addition, he has not been participating in social activities that he previously enjoyed.

Charles has not reported any gradual onset of issues with memory or other cognitive impairment. While he does report some issues concentrating and with retaining information after reading, these problems are also consistent with the more likely diagnosis of major depressive disorder.

Additionally, assessment of Charles' CSF did not reveal any pathology consistent with a diagnosis of AD.



Key Learnings in Charles' Case (1 of 3)

Charles presented with multiple symptoms consistent with major depressive disorder. Depressive disorders are common in the elderly and have some symptoms that overlap with early stages of AD, such as difficulty with memory or concentration.^{1,2} However, differentiating factors may include the following:

- Depressive disorders

- Cognitive impairment has a clear onset and rapid deterioration²
- Awareness of decline in abilities²
- Symptoms may remain constant regardless of environment²
- Psychomotor retardation observed²
- Persistent negative feelings that may last from weeks to months³

- Dementia

- Gradual onset of cognitive impairment²
- Denial of diminished capacity²
- Symptoms vary based on environment²



AD=Alzheimer's Disease.

1. Lanza C, et al. *Brain Commun.* 2020;2(2):fcaa206. 2. Tetsuka S. *Aging Dis.* 2021;12(8):1920-1934. 3. <https://www.alzheimers.org.uk/about-dementia/symptoms-and-diagnosis/depression-dementia> (Accessed February 2024).

VV-MED-149317 © 2024 Lilly USA, LLC. All rights reserved

Key Learnings in Charles' Case (2 of 3)

White matter hyperintensities and cortical atrophy are common in cognitively healthy elderly individuals, as well as those at risk of cognitive decline.^{1,2} They have also been shown to be associated with depressive disorders, and therefore are not diagnostically conclusive of AD on their own³

Structural neuroimaging (MRI)

- Can detect atrophy, which correlates with cognitive status and is a marker of neurodegeneration⁴
- Advantages include:
 - Noninvasive and widely available⁵
 - No ionizing irradiation^{6,7}
 - Excellent soft tissue contrast and high spatial resolution^{6,7}
- Disadvantages include:
 - Some patients find the scanner claustrophobic^{7,8}
 - Patients with magnetic metal implants should not receive MRI exams⁷
 - Atrophy patterns seen are not specific to AD⁸



AD=Alzheimer's Disease; MRI=Magnetic Resonance Imaging.

1. Alber J, et al. *Alzheimers Dement (N Y)*. 2019;5:107-117. 2. Blinkouskaya Y, et al. *Mech Ageing Dev*. 2021;200:111575. 3. Salo KI, et al. *Front Psychol*. 2019;10:1241.

4. Park M, Moon WJ. *Korean J Radiol*. 2016;17(6):827-845. 5. McEvoy LK, Brewer JB. *Expert Rev Neurother*. 2010;10(11):1675-1688. 6. Pysz MA, et al. *Clin Radiol*. 2010;65(7):500-516.

7. <https://www.fda.gov/radiation-emitting-products/mri-magnetic-resonance-imaging/benefits-and-risks> (Accessed January 2024). 8. Johnson KA, et al. *Cold Spring Harb Perspect Med*. 2012;2:a006213.

Key Learnings in Charles' Case (3 of 3)

The CSF biomarker assay can be helpful in the overall differential diagnosis of AD^{1,2}


CSF assays

- Quantitatively measure the levels of A β and tau protein within the fluid of the lumbar sac³
- Reflect the rates of A β and tau protein production and clearance³
- Advantages include:
 - Less expensive than PET by 10-15-fold⁴
 - Simultaneous information on A β and tau biomarkers⁵
- Limitations include:
 - CSF is obtained via lumbar puncture; this is invasive and can be uncomfortable for patients⁶
 - Limited availability outside of specialized clinics⁷
 - Do not detect regional A β or tau deposition^{3,4}



A β =Amyloid Beta; AD=Alzheimer's Disease; CSF=Cerebrospinal Fluid; PET=Positron Emission Tomography.

1. <https://alz.org/media/Documents/scientific-conferences/figures-and-tables-clinical-criteria-for-staging-and-diagnosis-for-public-comment-draft-2.pdf>. (Accessed January 2024). 2. Lanza C, et al. *Brain Commun.* 2020;2(2):fcaa206. 3. Jack CR Jr, et al. *Alzheimers Dement.* 2018;14:535-562. 4. Hansson O, et al. *Alzheimer's Res Ther.* 2019;11(1):34. 5. Dubois B, et al. *Lancet Neurol.* 2021;20(6):484-496. 6. Lee JC, et al. *Exp Mol Med.* 2019;51(5):1-10. 7. Zetterberg H, et al. *Alzheimer's Dement (Amst).* 2019;784-786.



Thank you for connecting
with Charles

