

The logo features the word "Lilly" in a red cursive script, followed by "ConnectAD" in a red sans-serif font with a trademark symbol. The background is a textured, light-colored surface with faint floral patterns, all enclosed in a red rectangular border.

Lilly ConnectAD™

Treat · Monitor

MMAT-00452 © 2025 Eli Lilly and Company. All rights reserved.

Lilly ConnectAD™

Welcome to ConnectAD™, a clinical case series created by the Eli Lilly and Company Neuroscience medical education team. This series is intended to connect healthcare professionals to resources that help them detect, diagnose, and manage Alzheimer's disease.

Disclaimer

The content for this case was created by Eli Lilly and Company and is inspired by scenarios clinicians may encounter while caring for patients with Alzheimer's disease.

Inclusion of a specific approach to treatment and monitoring in this clinical case does not imply endorsement or recommendation by Lilly.

Learning Objective

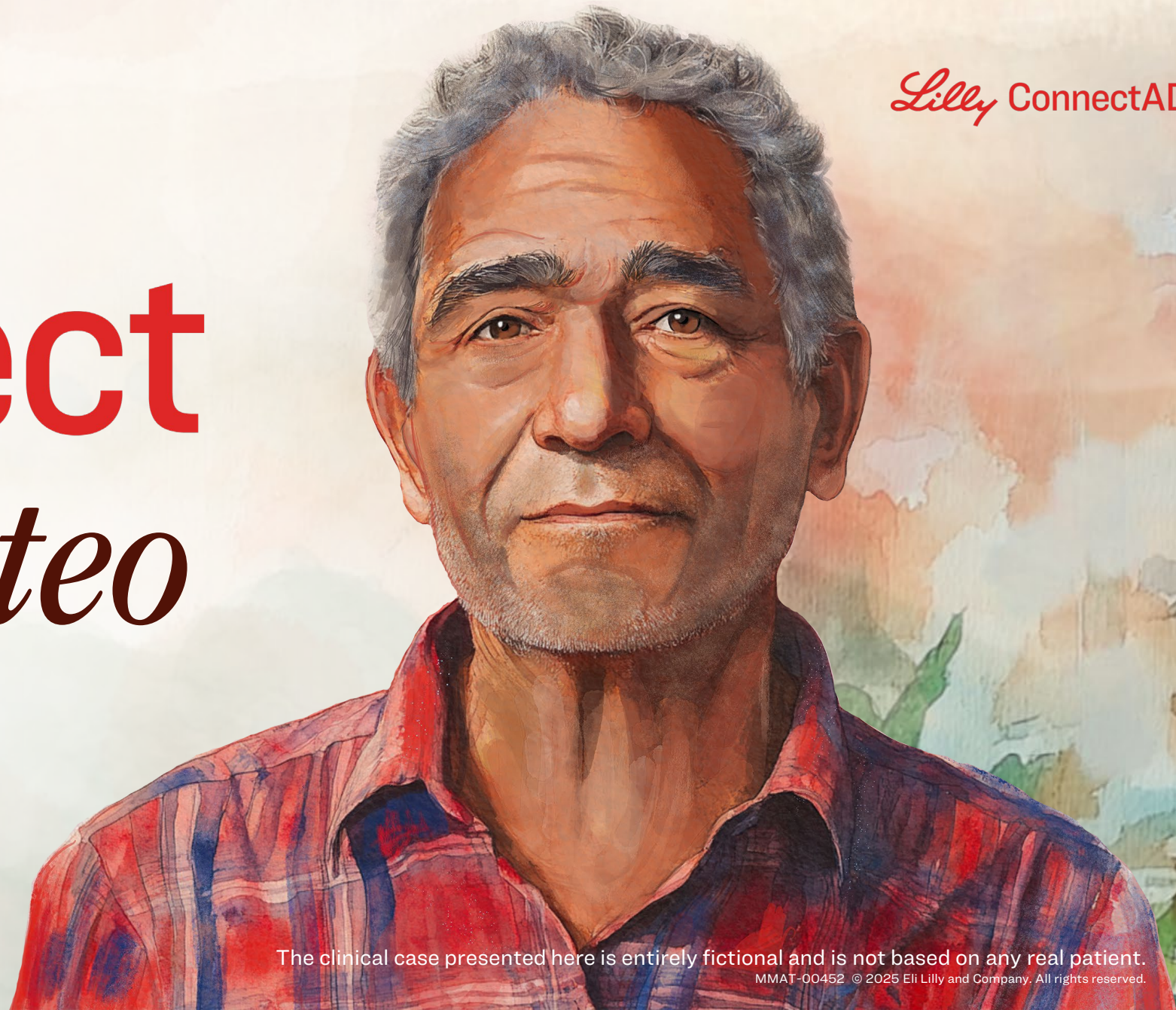Through completing this course, you will have a deeper understanding of:

Potential options to approach treatment initiation and monitoring in Alzheimer's disease

Lilly ConnectAD™

Connect *with Mateo*

Treat · Monitor



The clinical case presented here is entirely fictional and is not based on any real patient.

MMAT-00452 © 2025 Eli Lilly and Company. All rights reserved.

Diagnosis: Mild Dementia Due to AD

Click here to access Mateo's **detection and diagnosis case** to learn more about his path to diagnosis

Patient overview:

Mateo is a 73-year-old Hispanic male with:

- Controlled hypertension
- Adenomatous colon polyps

Initial clinical assessment:

- Alert, diminished insight (no reports of memory concerns)
- Impaired in activities of daily living (finances, medications, appointments)
- Cognitive impairment, eg, does not know date or day of the week (MMSE below threshold)

Additional testing:

Mateo's clinical history and cognitive assessment warranted further testing. The additional tests selected included:

- Blood work
- Brain MRI
- CSF testing

CSF testing

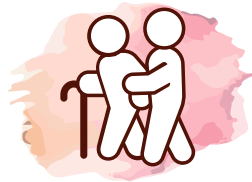Low A β 42/A β 40, high P-tau and high T-tau

- Findings consistent with amyloid deposits in the brain (low A β 42/A β 40) and tau neuropathology (high P-tau, high T-tau), supporting a diagnosis of Alzheimer's disease¹

Treatment Options

Non-pharmacologic or behavioral interventions:

- Non-pharmacologic interventions that may improve or maintain cognition/function, help to support independence in usual activities of daily living, or address behavioral symptoms¹
- Eg, cognitive therapy, physical exercise, nutrition



Symptomatic therapy:

- Pharmacotherapy that may improve cognitive and behavioral symptoms, but does not alter the course of the disease²



Disease-modifying therapy:

- Pharmacotherapy that modifies the clinical course of disease but does not stop or reverse the disease³
- Eg, Amyloid-targeting therapy (ATT)



Note: The treatment plan is under the discretion of the HCP and patient via shared decision making and a combination of treatments may be chosen

Could Mateo Be Considered an Appropriate Candidate for an ATT?

1 Diagnosis of mild dementia due to AD with confirmed $A\beta$ pathology

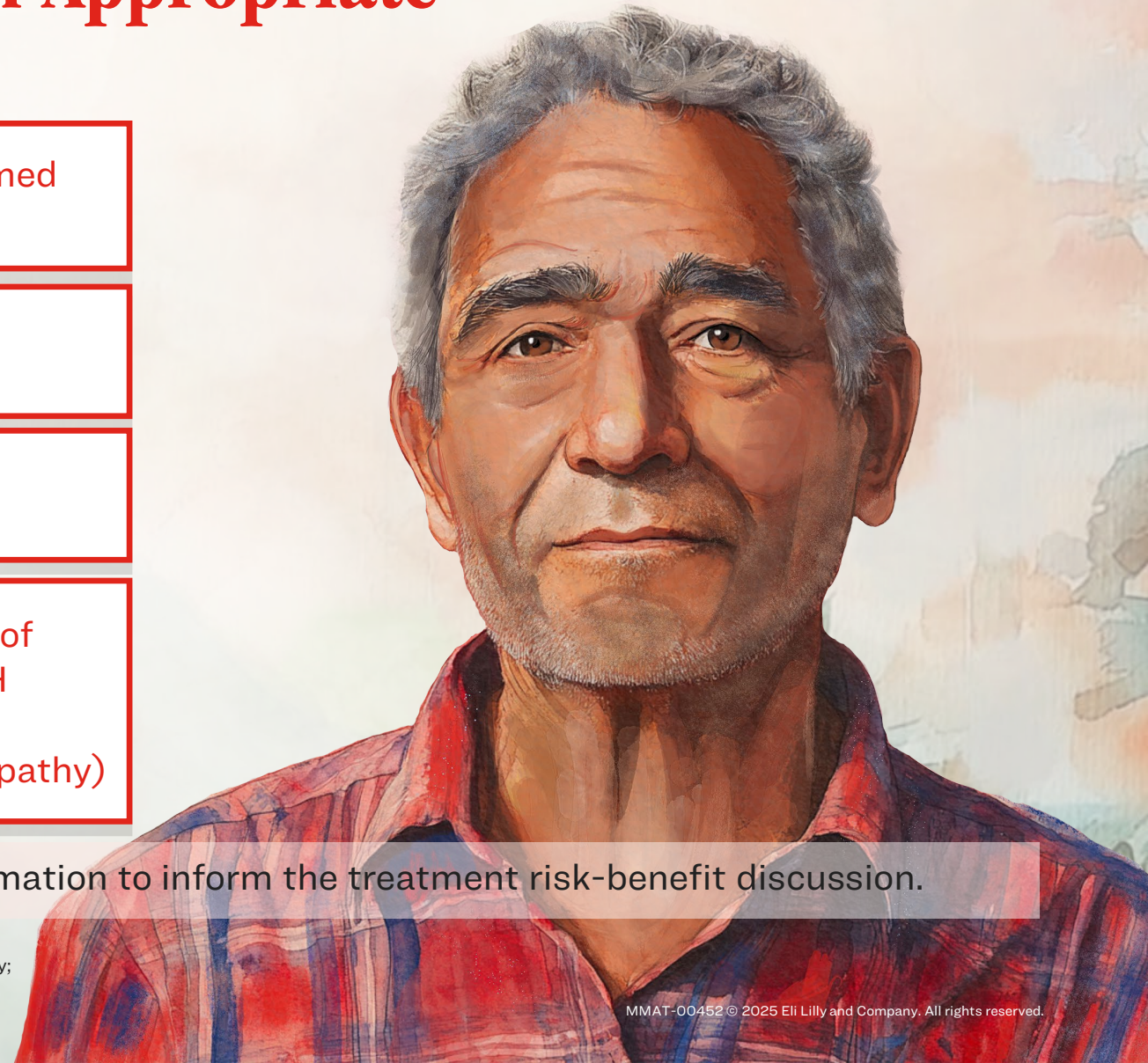
2 No other known cause for cognitive decline

3 No contraindications to treatment

4 Brain MRI has no evidence of ARIA-E (in the form of cerebral edema and/or sulcal effusions) or ARIA-H (microhemorrhages and/or superficial siderosis consistent with underlying cerebral amyloid angiopathy)

Note: *APOE* ϵ 4 genotyping would provide additional information to inform the treatment risk-benefit discussion.

$A\beta$ = Amyloid Beta; AD = Alzheimer's Disease; APOE = Apolipoprotein E; ARIA=Amyloid-Related Imaging Abnormalities; ARIA-E=ARIA-Edema; ARIA-H=ARIA-Hemosiderin Deposition; ATT= Amyloid-targeting Therapy; MRI = Magnetic Resonance Imaging.
Ramanan VK, et al. Neurology. 2023;101(19):842-852.



ATT Class Boxed Warning: Risk of ARIA

ATTs are monoclonal antibodies directed against aggregated forms of A β and can cause ARIA, as ARIA with edema (ARIA-E) and ARIA with hemosiderin deposition (ARIA-H). Incidence and timing of ARIA vary among treatments. ARIA usually occurs early in treatment and is usually asymptomatic, although serious and life-threatening events can occur. ARIA can be fatal.^{1,2}

Serious intracerebral hemorrhages >1 cm, some of which have been fatal, have been observed in patients treated with this class of medications. Because ARIA-E can cause focal neurologic deficits that can mimic an ischemic stroke, treating clinicians should consider whether such symptoms could be due to ARIA-E before giving thrombolytic therapy in a patient being treated with an ATT.^{1,2}

Patients who are *APOE* ϵ 4 homozygotes (approximately 15% of Alzheimer's disease patients) treated with the ATT class of medications, have a higher incidence of ARIA, including symptomatic, serious, and severe radiographic ARIA, compared to heterozygotes and noncarriers.^{1,2}

Testing for *APOE* ϵ 4 status should be performed prior to initiation of treatment to inform the risk of developing ARIA. Prior to testing, the risk of ARIA across genotypes and the implications of genetic testing results should be discussed with patients. Prescribers should inform patients that if genotype testing is not performed, they can still be treated with an ATT; however, it cannot be determined if they are *APOE* ϵ 4 homozygotes and at higher risk for ARIA. Consider the benefit of an ATT for the treatment of Alzheimer's disease and potential risk of serious adverse events associated with ARIA when deciding to initiate treatment with an ATT.^{1,2}

After Discussion of Treatment Options with Mateo and His Loved Ones, Mateo Expressed an Interest in ATT¹

Mateo is an appropriate candidate for ATT as he:

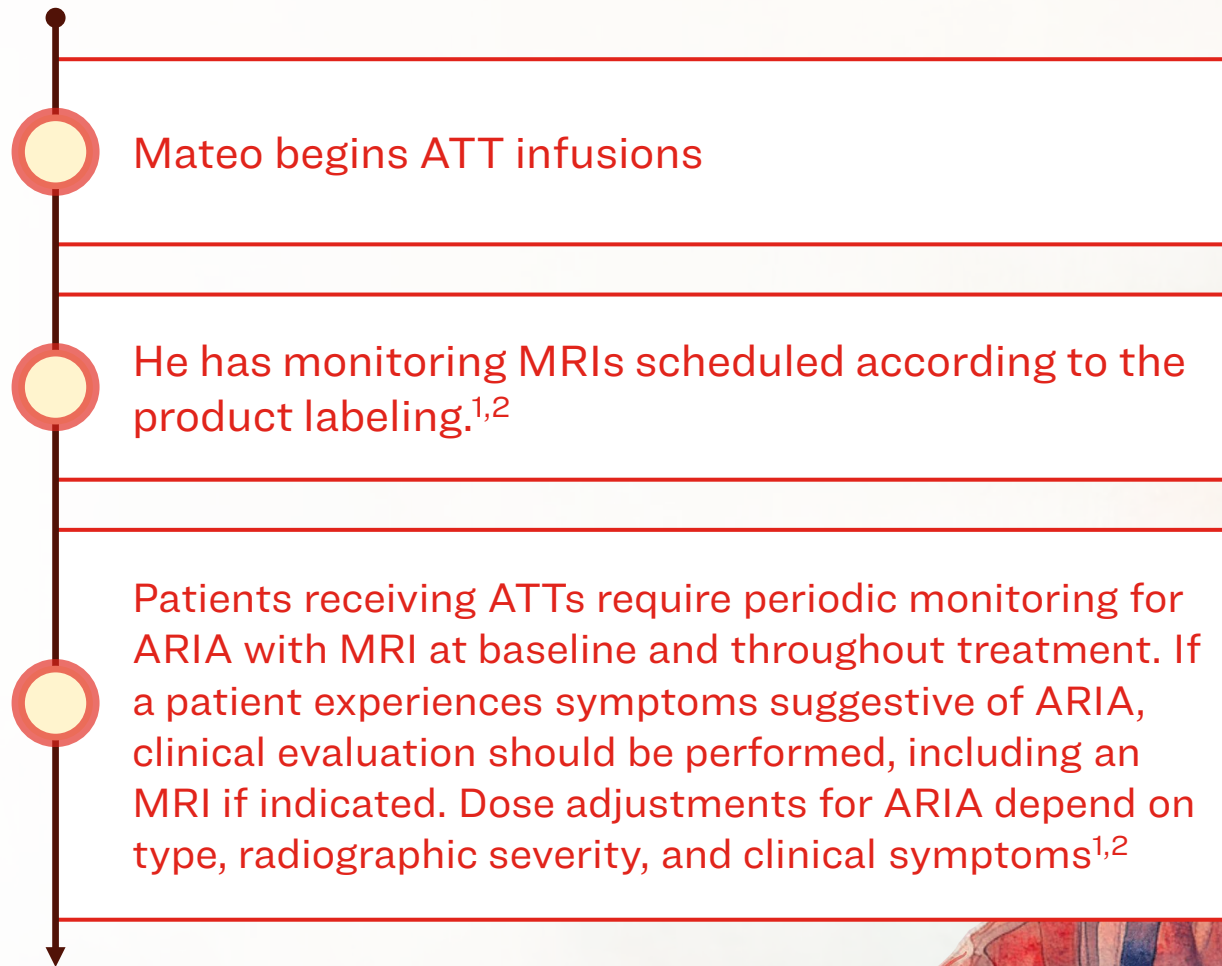
- Has a diagnosis of mild dementia due to AD with confirmed A β pathology¹
- Has no contraindications¹
- Understands the potential risks and benefits of treatment, including the rationale, process, and resulting impact of APOE ϵ 4 genotype testing¹
- Understands the requirements for treatment and monitoring, including infusion and MRI schedule, and the need to communicate new symptoms to the clinician ^{1,2}
- Has support from loved ones

A β = Amyloid Beta; AD = Alzheimer's Disease; APOE = Apolipoprotein E; ATT = Amyloid-targeting Therapy; MRI = Magnetic Resonance Imaging.

1. Ramanan VK, et al. *Neurology*. 2023;101(19):842-852.

2. Rentz DM, et al. *Alzheimers Dement*. 2024;20(11):8162-8171

Initiation of an ATT and Monitoring



ARIA = Amyloid-related Imaging Abnormalities; ATT = Amyloid-targeting Therapy; MRI = Magnetic Resonance Imaging.

1. https://www.accessdata.fda.gov/drugsatfda_docs/label/2025/761248s004lbl.pdf (Accessed November 3, 2025)

2. https://www.accessdata.fda.gov/drugsatfda_docs/label/2025/761269s013lbl.pdf (Accessed November 3, 2025)

Note: ATTs carry warnings and precautions about the risk of developing serious hypersensitivity and infusion-related reactions during and after completion of the infusion.^{1,2} In addition, ATTs are contraindicated in patients with a known serious hypersensitivity to the active ingredient or to any of the excipients.¹

Monitoring of the Patient on an ATT

Neurologists and radiologists face several communication obstacles when monitoring for ARIA including, but not limited to¹:

- Separate healthcare system(s)
- Separate radiology reading queues
- Time constraints

Some potential solutions to address these challenges in practice include¹:

- Clear reporting of relevant findings of ARIA in MRI scans
- Standardized MRI orders/protocols
- Cross-communication between neurologists and radiologists

Note: ATTs carry warnings and precautions about the risk of developing serious hypersensitivity and infusion-related reactions during and after completion of the infusion.^{2,3} In addition, ATTs are contraindicated in patients with a known serious hypersensitivity to the active ingredient or to any of the excipients²

ARIA = Amyloid-related Imaging Abnormalities; ATT = Amyloid-targeting Therapy; MRI = Magnetic Resonance Imaging.

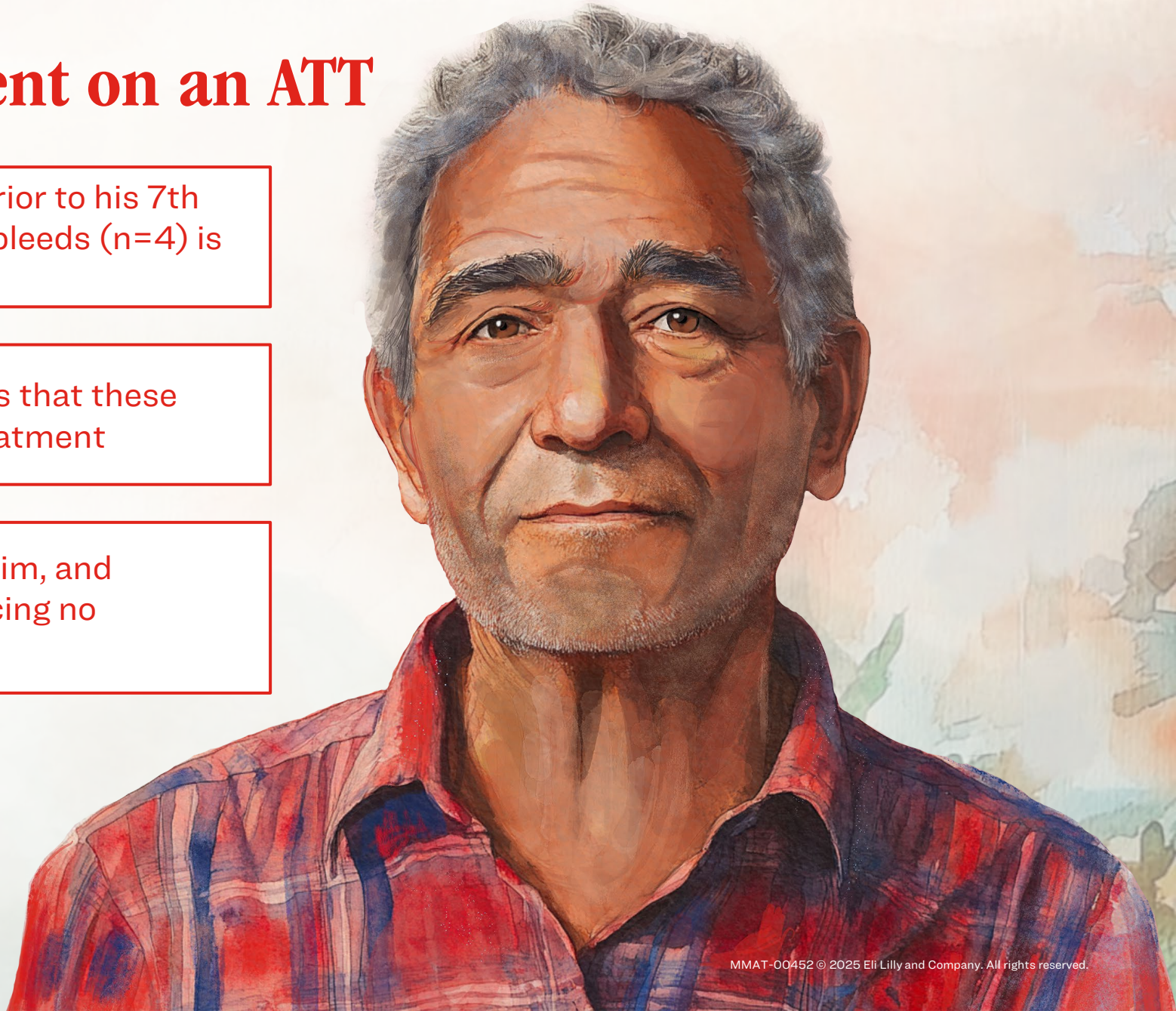
1. Cogswell PM, et al. Am J Neuroradiol. 2025;46(1):24-32.

2. https://www.accessdata.fda.gov/drugsatfda_docs/label/2025/761248s004lbl.pdf (Accessed November 3, 2025)

3. https://www.accessdata.fda.gov/drugsatfda_docs/label/2025/761269s013lbl.pdf (Accessed November 3, 2025)

Monitoring of the Patient on an ATT

- During a monitoring MRI obtained prior to his 7th infusion, evidence of cerebral microbleeds (n=4) is observed
- Comparison to baseline scans shows that these microbleeds are new during ATT treatment
- Mateo's neurologist connects with him, and determines he is currently experiencing no symptoms



ARIA Severity Assessment

ARIA Type		Radiographic Severity		
		Mild	Moderate	Severe
ARIA-E		FLAIR hyperintensity confined to sulcus and/or cortex/subcortex white matter in one location, <5 cm	FLAIR hyperintensity 5 to 10 cm in single greatest dimension, or >1 site of involvement, each measuring <10 cm	FLAIR hyperintensity >10 cm with associated gyral swelling and sulcal effacement ≥ 1 separate/independent sites of involvement may be noted
ARIA-H	Microhemorrhage	≤ 4 new incident microhemorrhages	5-9 new incident microhemorrhages	≥ 10 new incident microhemorrhages
	Superficial siderosis	1 focal area of superficial siderosis	2 focal areas of superficial siderosis	>2 areas of superficial siderosis

Clinical Symptom Advancement

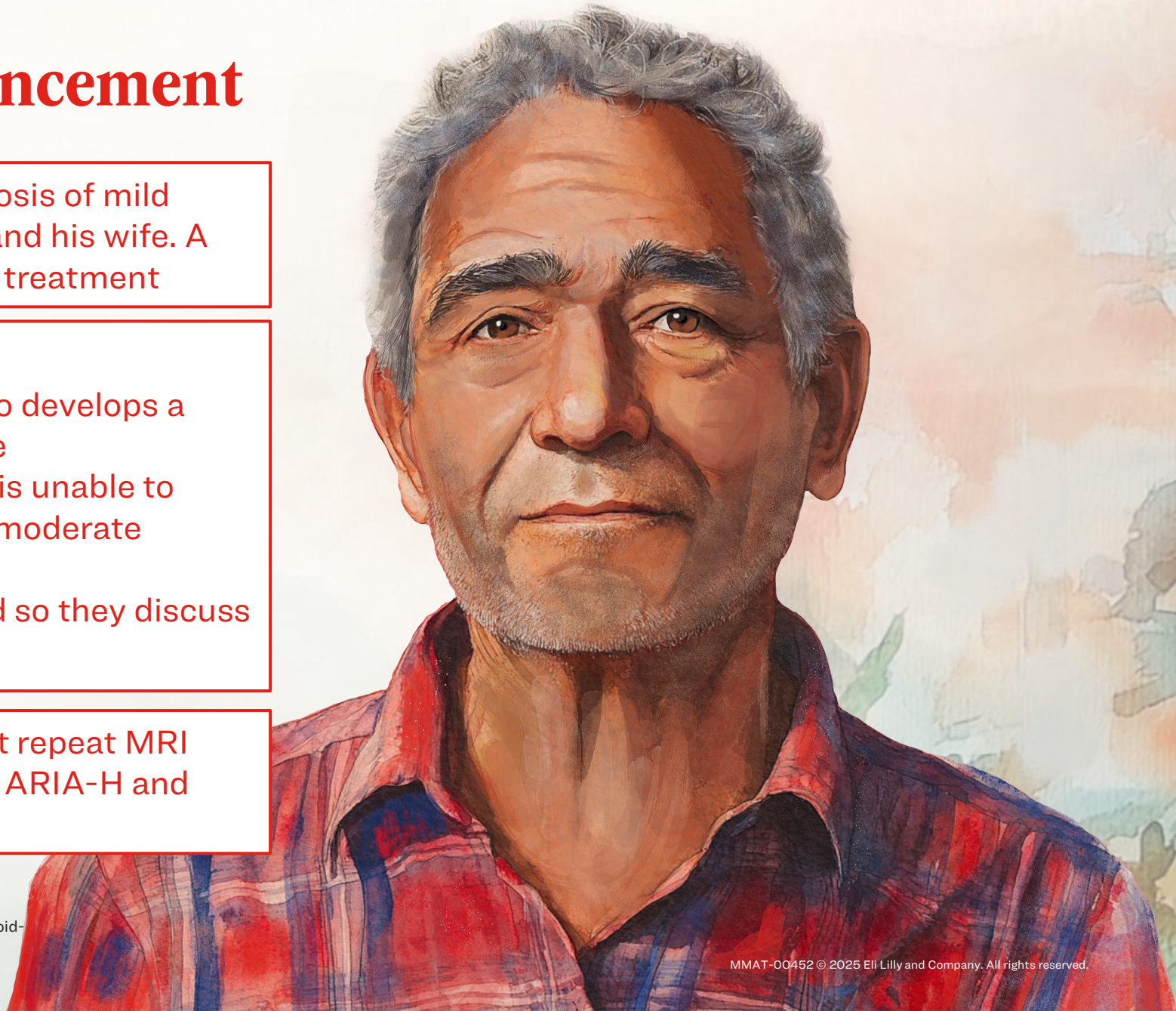
The neurologist discusses the diagnosis of mild asymptomatic ARIA-H with Mateo and his wife. A shared decision is made to continue treatment

Clinical symptoms update:

- Between infusions 7 and 8, Mateo develops a headache and mentions it to his wife
- Because of the headache, Mateo is unable to carry on with his daily activities (ie, moderate clinical severity)
- Mateo and his wife are concerned so they discuss it with his neurologist

Mateo's neurologist orders an urgent repeat MRI

- The results of the MRI show mild ARIA-H and mild ARIA-E

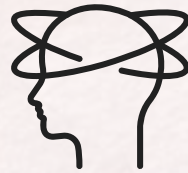

ARIA Clinical Manifestations

Common¹⁻³



Headache



Confusion



Nausea/
Dizziness

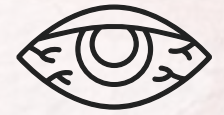Less Frequent¹⁻³



Gait
disturbance



Neuropsychological
symptoms



Visual
symptoms

Rare symptoms¹⁻³:

- Seizure/status epilepticus
- Focal neurological deficits
- Encephalopathy
- Stupor

Severity rating of clinical symptoms²

None

No symptoms noted
No disruption of
daily activities

Mild

Discomfort noted
No disruption of
daily activities

Moderate

Discomfort sufficient to affect
normal
daily activities

Severe

Symptoms incapacitating
Unable to perform normal daily
activities

ARIA=Amyloid-related Imaging Abnormalities.

1. Salloway S, et al. *JAMA Neurol.* 2022;79(1):13-21. 2. Cummings J, et al. *J Prev Alzheimers Dis.* 2023;10(3):362-377. 3. Zimmer JA, et al. *JAMA Neurol.* 2025;82(5):461-469.

Dosing ATT in Response to ARIA 1,2

ARIA Type	Severity on MRI	Clinical Symptom Severity		
		Asymptomatic	Mild ^a	Moderate/Severe ^b
ARIA-E	Mild	May continue dosing	May continue dosing based on clinical judgment	Suspend dosing ^c
	Moderate	Suspend dosing ^c	Suspend dosing ^c	Suspend dosing ^c
	Severe	Suspend dosing ^c	Suspend dosing ^c	Suspend dosing ^c
		Asymptomatic	Symptomatic	
ARIA-H	Mild	May continue dosing	Suspend dosing ^d	
	Moderate	Suspend dosing ^d	Suspend dosing ^d	
	Severe	Suspend dosing ^e	Suspend dosing ^e	

^aMild: Discomfort noticed, but no disruption of normal daily activities. ^bModerate: Discomfort sufficient to reduce or affect normal daily activities. Severe: Incapacitating, with inability to work or to perform normal daily activities. ^csuspend until MRI demonstrates radiographic resolution and symptoms, if present, resolve; consider a follow-up MRI to assess for resolution 2 to 4 months after initial identification. Resumption of dosing should be guided by clinical judgment. ^dSuspend until MRI demonstrates radiographic stabilization and symptoms, if present, resolve; resumption of dosing should be guided by clinical judgment; consider a follow-up MRI to assess for stabilization 2 to 4 months after initial identification. ^esuspend until MRI demonstrates radiographic stabilization and symptoms, if present, resolve. Use clinical judgment when considering whether to continue treatment or permanently discontinue ATT. ARIA=Amyloid-related Imaging Abnormalities; ARIA-E=ARIA-Edema; ARIA-H= ARIA-Hemosiderin Deposition; ATT=Amyloid-targeting Therapy; MRI=Magnetic Resonance Imaging.

1. https://www.accessdata.fda.gov/drugsatfda_docs/label/2025/761248s004lbl.pdf (Accessed November 3, 2025)

2. https://www.accessdata.fda.gov/drugsatfda_docs/label/2025/761269s013lbl.pdf (Accessed November 3, 2025)

Dosing ATT in Response to ARIA

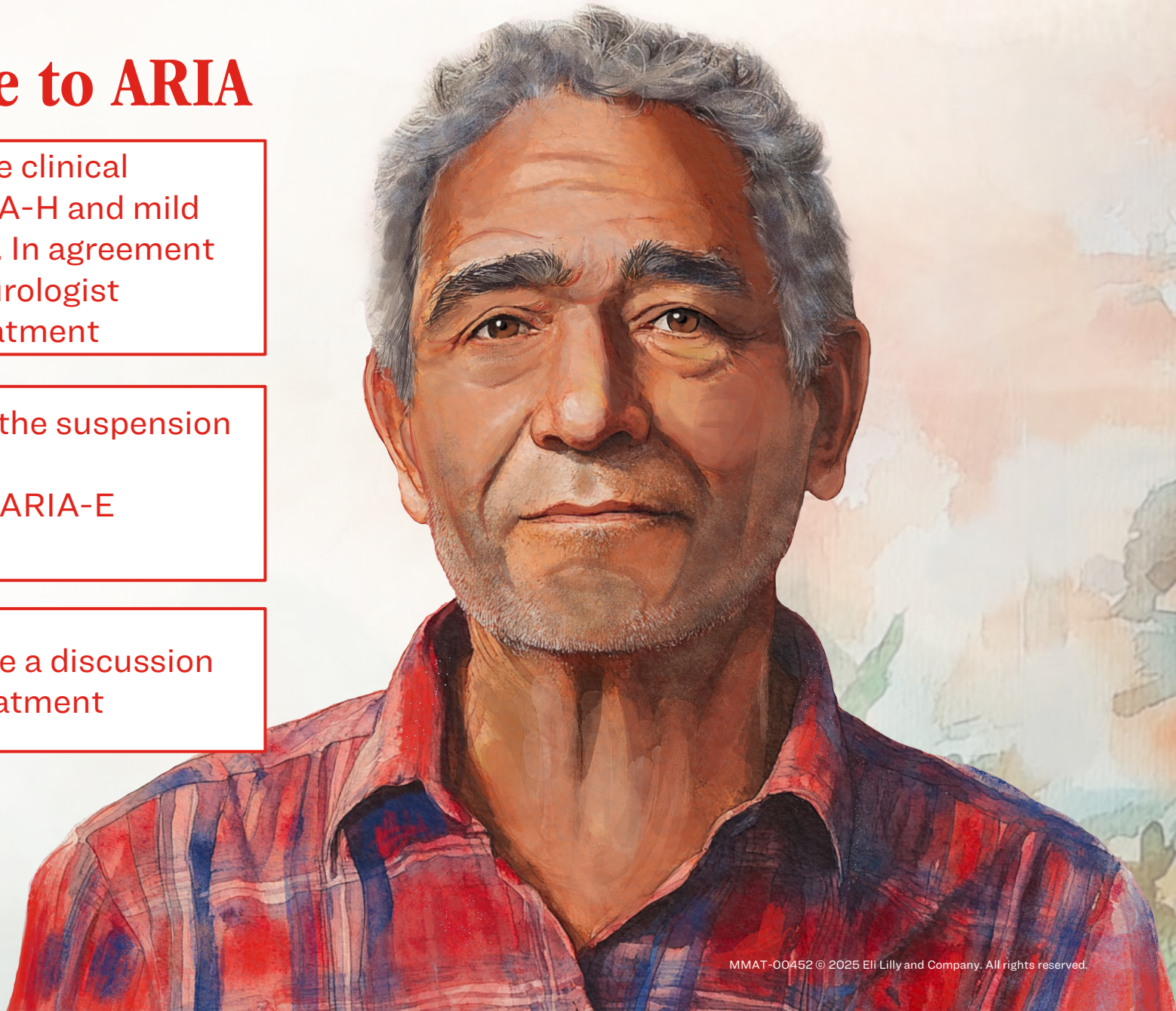
Mateo displays evidence of moderate clinical symptoms, consistent with mild ARIA-H and mild ARIA-E identified on the urgent MRI. In agreement with prescribing information, his neurologist recommends suspension of ATT treatment

Another MRI is performed following the suspension of treatment

- This subsequent MRI shows that ARIA-E resolved and ARIA-H stabilized

Mateo, his family, and care team have a discussion and collectively decide to restart treatment

ARIA=Amyloid-related Imaging Abnormalities; ARIA-E=ARIA-edema or effusion; ARIA-H=ARIA-Microhemorrhages or Localized Superficial Siderosis; ATT=Amyloid-targeting Therapy; MRI=Magnetic Resonance Imaging.



Key Learnings in Mateo's Case

Treatment with ATTs requires adherence to scheduled MRIs to monitor for ARIA.

- Adherence to scheduled brain MRI scans prior to infusions is necessary to identify ARIA and to modify dosing if needed¹
- Multidisciplinary collaboration between the prescribing clinician, radiologist, infusion center, and the primary care provider is necessary for optimal treatment monitoring^{1,2}
- Patients and their loved ones should be educated about symptoms associated with ARIA and should communicate new symptoms to the prescribing clinician and infusion clinicians^{1,3,4}
- Because ARIA-E can cause focal neurologic deficits that can mimic an ischemic stroke, clinical evaluation should be performed, including MRI scanning if indicated.^{5,6}
- Patients should be advised to carry information with them indicating that they are being treated with an ATT.^{5,6}

ARIA=Amyloid-related Imaging Abnormalities; ATT=Amyloid-targeting Therapy; MRI=Magnetic Resonance Imaging.

1. Agarwal A, et al. Radiographics. 2023;43(9):e230009. 2. Turk KW, et al. Neurol Clin Pract. 2024;14(6):e200346. 3. Ramanan VK, et al. Neurology.

2023;101(19):842-852. 4. Rentz DM, et al. Alzheimers Dement. 2024;20(11):8162-8171.

5. https://www.accessdata.fda.gov/drugsatfda_docs/label/2025/761248s004lbl.pdf (Accessed November 3, 2025)

6. https://www.accessdata.fda.gov/drugsatfda_docs/label/2025/761269s013lbl.pdf (Accessed November 3, 2025)

Lilly ConnectAD™

Thank you for
Connecting
with Mateo

Treat · Monitor

