

# Oxford® Partial Knee

Microplasty® Instrumentation Complete

Cemented and Cementless  
Surgical Technique





## Table of Contents

<b>Oxford Partial Knee</b> .....	2
Introduction	
Femoral Components	
Tibial Components	
Meniscal Bearings	
<b>Patient Selection</b> .....	3
The Learning Curve	
Preoperative X-ray Template	
Open vs. Minimally Invasive Technique	
<b>Positioning the Limb</b> .....	7
<b>Incision</b> .....	7
<b>Osteophyte Excision</b> .....	8
<b>Tibial Plateau Resection</b> .....	9
<b>The Femoral Drill Holes and Alignment</b> .....	12
<b>Femoral Saw Cut</b> .....	14
<b>First Milling of the Condyle</b> .....	16
<b>Equalizing the Flexion and Extension Gaps</b> .....	17
<b>Confirming Equality of the Flexion and Extension Gaps</b> .....	19
<b>Preventing Impingement</b> .....	20
<b>Final Preparation of the Tibial Plateau</b> .....	22
<b>Final Trial Reduction</b> .....	24
<b>Cementing the Components</b> .....	26
<b>Cementless Procedure</b> .....	28
Cementless Components	
Tibial Preparation	
The Femoral Drill Holes and Alignment	
First Milling of the Condyle	
Final Preparation of the Tibial Plateau	
Implanting the Components	
<b>Appendix</b> .....	33
Postoperative Treatment	
Postoperative Radiographic Assessment	
Radiographic Technique	
Radiographic Criteria	
Position and Size of Components	
Follow-up Radiographs	
<b>Ordering Information</b> .....	36

## Oxford Partial Knee

### Introduction

The Oxford Partial Knee is the natural evolution of the original meniscal arthroplasty, which was first used in 1976.<sup>1</sup> It continues to offer the advantage of a large area of contact throughout the entire range of movement for minimal polyethylene wear, as seen in the Oxford Partial Knee Phase I and II.<sup>2-4</sup>

Since 1982, the Oxford Partial Knee has been successfully used to treat anteromedial osteoarthritis.<sup>4-5</sup> If performed early in this disease process, the operation can slow the progression of arthritis in the other compartments of the joint and provide long-term symptom relief.<sup>6</sup>

The Oxford implant is based on its clinically successful predecessors (Phase 1 and Phase 2) which achieved survivorship rates of 98 percent at 10 years,<sup>5,7</sup> with an average wear rate of 0.03 mm per year.<sup>2,3</sup>

### Femoral Components

The distinct, spherically designed femoral components are made of cast cobalt chromium molybdenum alloy for strength, wear resistance and biocompatibility. The design is available in five sizes to provide an optimal fit. The sizes are parametric and have corresponding radii of curvature.

The articulating surface of the femoral component is spherical and polished to a very high tolerance. The appropriate size of femoral component is chosen based on the patient size, pre-operative templating of lateral radiographs and intra-operative measurement confirmed with sizing spoons.

### Tibial Components

The tibial components, also made of cast cobalt chromium molybdenum alloy, are available in seven sizes, both right and left. Their shapes are designed to provide optimal bone coverage while avoiding component overhang anteriomedially.

### Meniscal Bearings

The bearings are direct compression molded ultra high molecular weight polyethylene (UHMWPE), manufactured from ArCom<sup>®</sup> direct compression molded polyethylene for increased wear resistance.<sup>8,9</sup>

There are five bearing sizes to match the radii of curvature of the five femoral component sizes. For each size, there is a range of seven thicknesses, available from 3 mm to 9 mm.

## Patient Selection

There are well-defined circumstances in which the Oxford Partial Knee for medial arthroplasty is appropriate and certain criteria must be fulfilled for success:

- The operation is indicated for the treatment of anteromedial osteoarthritis.<sup>4</sup>

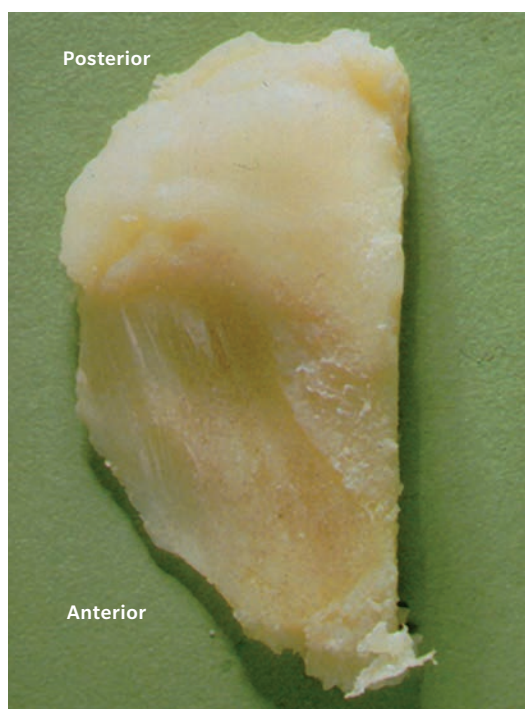


Figure 1

- There must be full thickness cartilage loss on both sides of the medial compartment with bone on bone contact (Figure 1). This may be demonstrated radiographically (weight bearing A/P, Rosenberg or varus stress) or arthroscopically. The results of replacement for partial thickness cartilage loss are unpredictable.<sup>9</sup>
- Both cruciate ligaments must be functionally intact. The posterior cruciate is seldom diseased in osteoarthritic knees, but the anterior cruciate is often damaged and is sometimes absent. This deficiency is a contraindication to the procedure.
- Posterior bone loss on a lateral radiograph or mediolateral subluxation that does not correct on valgus stress radiographs strongly suggests damage to the anterior cruciate ligament (ACL).<sup>10</sup> If there is doubt about the integrity of the ACL it should be assessed with a hook during the operation.
- The lateral compartment should be well preserved, with an intact meniscus and full thickness of articular cartilage. This is best demonstrated by the presence of a full thickness 'joint space' visible on an A/P radiograph taken with the joint stressed into valgus.<sup>11</sup> However, a grade 1 cartilage defect, marginal osteophytes and localized areas of erosion of the cartilage on the medial side of the lateral condyle are frequently seen during surgery and are not contraindications to medial compartment arthroplasty.
- The intra-articular varus deformity must be passively correctable to pre-disease status and not beyond. A good way to confirm this is to take valgus stressed radiographs.
- The degree of intra-articular deformity is not as important as its ability to be passively corrected by the application of a valgus force. Varus deformity of more than 15 degrees can seldom be passively corrected to neutral; therefore, this figure represents the outer limit. Soft tissue release should never be performed. If the medial collateral ligament has shortened and passive correction of the varus is impossible, the arthritic process has progressed beyond the suitable stage for this procedure, and thus the procedure is contraindicated.
- Flexion deformity should be less than 15 degrees. If it is greater than 15 degrees the ACL is usually ruptured.
- The knee must be able to flex to at least 110 degrees under anesthetic to allow access for preparation of the femoral condyle.
- The state of the patello-femoral joint (PFJ) is not a contraindication provided that the damage to the patellofemoral joint is limited to (or greater on) the medial facets and there is not severe damage to the lateral part of the PFJ with bone loss, grooving or subluxation. Neither the presence of pre-operative anterior knee pain or cartilage loss in the PFJ compromises the outcome.<sup>12</sup> Similar arthritis in the medial part of the PFJ, however severe, or early arthritis in the lateral part of the PFJ do not compromise the outcome.<sup>12-14</sup>

- Neither the patient's age, weight nor activity level are contraindications, nor is the presence of chondrocalcinosis.<sup>13–15</sup>
- Unicompartmental arthroplasty is contraindicated in all forms of inflammatory arthritis. (The pathological changes of early rheumatoid arthritis can be confused with those of medial compartment osteoarthritis). The high success rates that were reported for Oxford Partial Knee<sup>5,6</sup> were achieved in patients with anteromedial osteoarthritis, and they may not be achieved with other diagnoses. The Oxford implant has also been used successfully in the treatment of primary avascular necrosis, which has been included as a main indication for use of the Oxford Partial Knee.<sup>16</sup>
- The Oxford medial arthroplasty is not designed for and is contraindicated for lateral compartment replacement. The ligaments of the lateral compartment are more elastic than those of the medial, and a 10 percent rate of early dislocation of the bearing has been reported.<sup>17</sup> Access through a small incision is more difficult laterally than medially. The Oxford Fixed Lateral fixed bearing unicompartmental knee replacement is indicated for lateral compartment arthroplasty.
- The final decision whether or not to perform unicompartmental arthroplasty is made when the knee has been opened and directly inspected.

## The Learning Curve

This surgical technique should be used in association with the instructional video of the operation. As with other surgical procedures, errors of technique are more likely when the method is being learned. **To reduce these to a minimum, surgeons are required by the FDA in the United States, and strongly recommended throughout the world, to attend an Advanced Instructional Course on the Oxford Partial Knee before attempting the operation. Masters Courses are also offered to enhance skills through round-table discussions, technical tips, surgical issues, case studies and presentations.**

## Preoperative X-ray Template

The size of femoral component can be chosen preoperatively based on the patient's height using X-ray templates (Figure 2). A true lateral radiograph is required to accurately template.

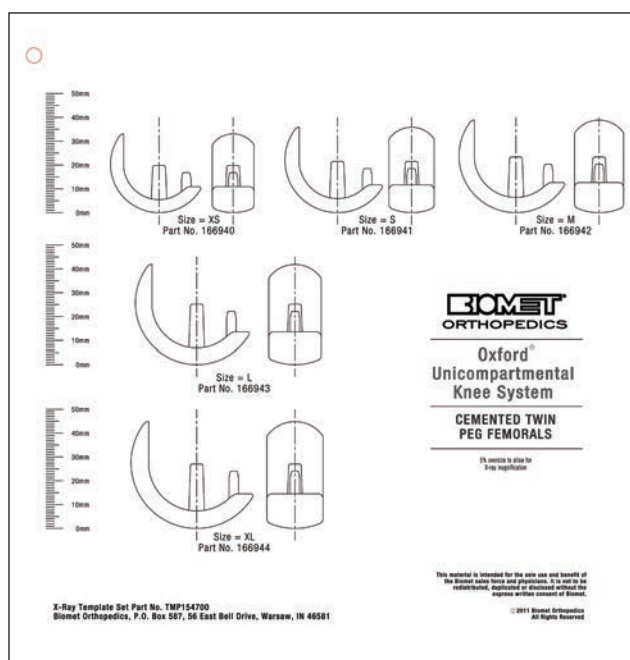


Figure 2

A medium size femoral component is appropriate for most patients. In fact, it was the only size used in the Phase I and II implants. However, the small size is typically utilized for small women (typically less than 5 ft 5 in, 165 cm tall)<sup>23</sup> and the large size in large men (typically more than 5 ft 7 in, 170 cm tall<sup>23</sup>). The extra large is only needed in very large men and the extra small in very small women. If there is doubt about the size it is usually best to tend towards the medium size. Available templates allow for magnification of 105 and 115 percent. To achieve this the patient should lie on their side with the affected knee resting against the X-ray plate and the X-ray tube being about 1 mm away.

Apply the outlines on the template to the X-ray image of the medial femoral condyle. The line along the central peg of the implant should be 10 degrees flexed compared to the long axis of the femoral shaft. The outer surface of the diagrammatic component should lie about 2 mm outside the radiographic image to allow for the thickness of articular cartilage. For a correctly sized implant the proximal part of the prosthesis should be approximately 2 mm outside the bone surface of the proximal part of the condyle so the implant surface and retained proximal cartilage are flush (Figure 3).

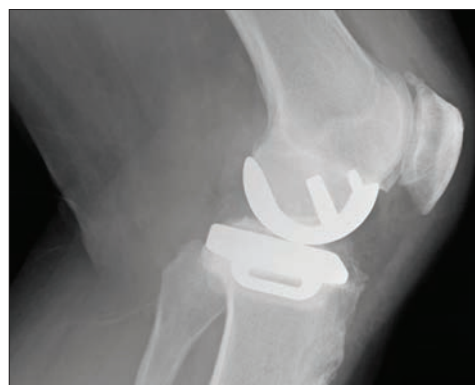

Figure 3

## Open vs. Minimally Invasive Technique

One advantage of unicompartmental arthroplasty is that it can be performed through a small incision without dislocating the patella, thus avoiding damage to the synovial reflections of the suprapatellar pouch. This can reduce postoperative pain and allow a more complete and rapid recovery of flexion.<sup>18</sup> With proper use of the Oxford Partial Knee instrumentation, the operation can be performed through a small incision with great precision. However, surgeons learning the procedure can extend the soft tissue incision beyond the limits described here with very little increase in postoperative morbidity as long as the integrity of the suprapatellar pouch is preserved.

The open approach, with dislocation of the patella, is not recommended. The Oxford Partial Knee instrumentation is designed for use through a small incision, and intraoperative dislocation of the patella distorts the ligaments, possibly making the operation more difficult.



## Surgical Technique

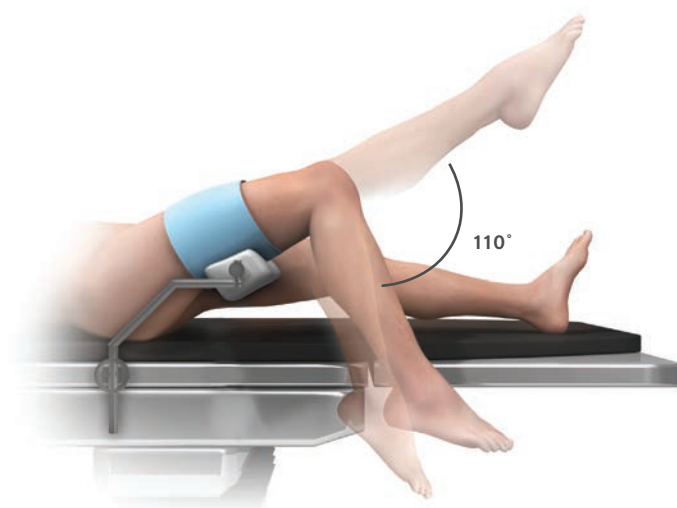


Figure 4

### Positioning the Limb

Inflate a thigh tourniquet and place the draped leg on a thigh support, with the hip flexed to about 30 degrees and the leg dependent. The knee must be free to flex fully and the leg should hang with the knee flexed about 110 degrees (Figure 4). The thigh support must not be placed in the popliteal fossa as this will increase the risk of damage to the popliteal vessels.

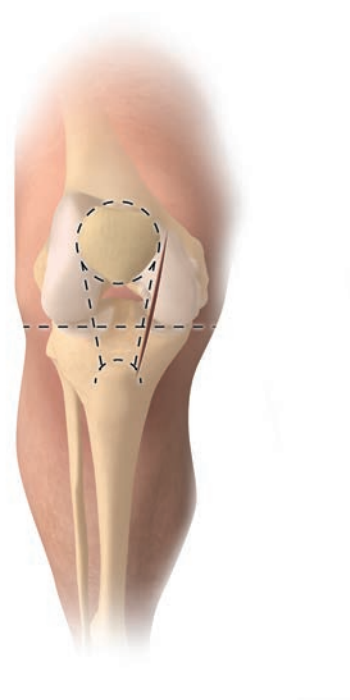


Figure 5

### Incision

With the knee flexed to 90 degrees, make a medial parapatellar skin incision from the medial margin of the patella to a point 3 cm distal to the joint line (Figure 5). Deepen the incision through the joint capsule. At its upper end, the capsular incision should extend proximally about 2 cm into the vastus medialis. It should pass around the patella and down beside the patella tendon.

Expose the front of the tibia in the lower part of the wound from the tibial tubercle to the antero-medial rim of the plateau. Excise as much of the medial meniscus as possible. Do not 'release' any of the fibres of the medial collateral ligament.

Surgeons who are learning the technique should make a larger incision to increase the exposure. The patella should be subluxed but not dislocated.

Excise part of the retropatellar fat pad and insert retractors into the synovial cavity. The ACL can now be inspected to ascertain that it is intact. (Absence of a functioning ACL is a contraindication. If this is found, the operation should be abandoned in favor of a total knee replacement).

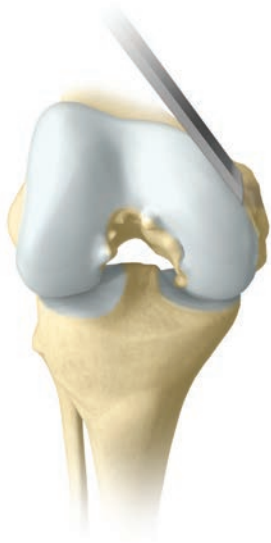

Figure 6

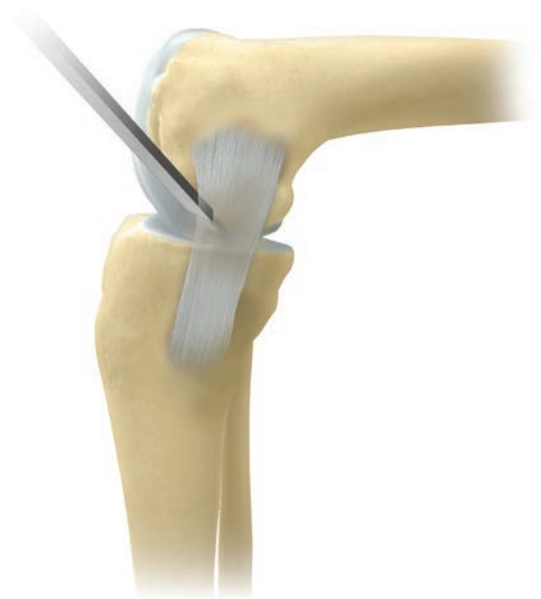


Figure 7

## Osteophyte Excision

All osteophytes must be removed from the medial margin of the medial femoral condyle and from both margins of the intercondylar notch (Figure 6). The assistant extends and flexes the knee, moving the incision up and down, allowing the various osteophytes to come into view. Osteophytes on the tibial plateau in front of the insertion of the ACL and in the top of the notch must be removed to allow the fixed flexion deformity to correct. Osteophytes on the tibia in front of the medial compartment should be removed, but medial tibial osteophytes should not be removed as this may damage the deep fibres of the medial collateral ligament. If there are large osteophytes around the patella they should also be removed.

With a narrow chisel (6 mm), remove the osteophytes from beneath the medial collateral ligament (Figure 7) and from the posterolateral margin of the medial condyle. This creates room to insert the saw blade into the intercondylar notch during the next step.

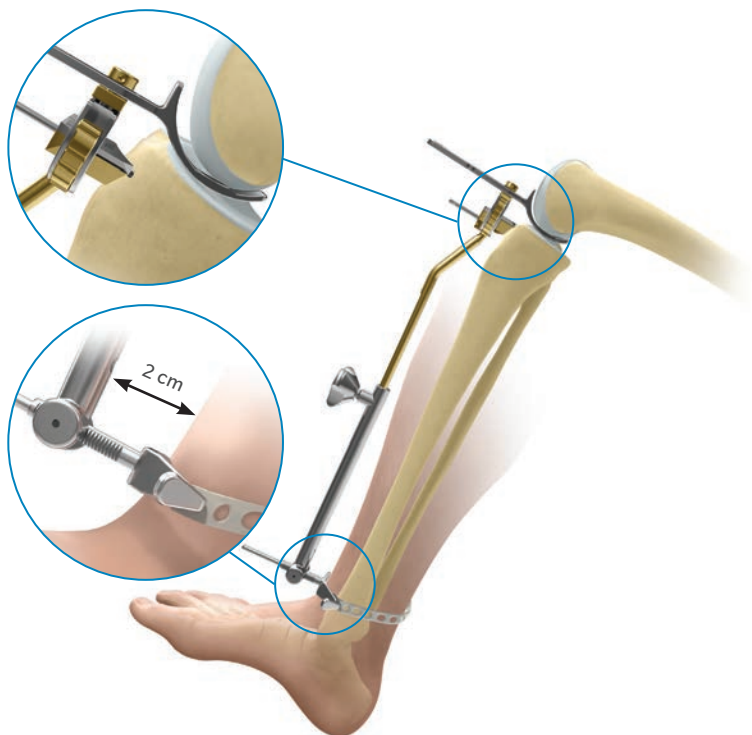


Figure 8

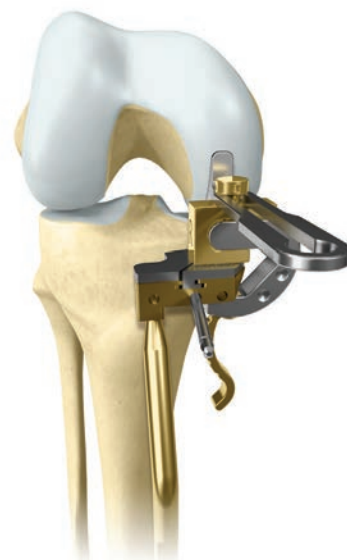

Figure 9

## Tibial Plateau Resection

With the knee in flexion, insert the femoral sizing spoon centrally on the condyle (based on pre-operative estimate sizing) starting with 1 mm thick spoon. With all retraction removed, assess the ligament tension. Ideally it should twist up to 20 degrees in both directions. Usually the 1 mm thick femoral sizing spoon achieves the proper ligament tension. If not, replace with the 2 or 3 mm generic sizing spoon until the proper ligament tension is achieved. The optimal size of the femoral component is confirmed by examining the relationship of the front of the spoon and an estimate of where the cartilage surface would have been before the arthritis. The correct sizing spoon should be inserted centrally in the medial compartment.

Apply the tibial saw guide with its shaft parallel with the long axis of the tibia in both planes (Figures 8 and 9). The ankle piece should be pointing towards the anterior superior iliac spine and the standard 0 mm tibial shim should be used. The tibial saw guide has 7 degrees of posterior slope built in.

The femoral sizing spoon, tibial saw guide and G-clamp, when used together, will accurately establish the bony resection. Select either the 3 or the 4 G-clamp and apply to the femoral sizing spoon and to the medial side of the tibial saw guide to ensure access to pin holes.

Manipulate the upper end of the guide so that its face lies against the exposed bone. A recess accommodates the skin and the patellar tendon laterally (Figure 9). Engage the cam, by pulling the lever downwards, to lock the three components together.

Once the G-clamp is locked holding the femoral sizing spoon and tibial saw guide in place, pin the guide in place. When pinning the guide one or two pins, or drills may be used.

Once the tibial saw guide is pinned in place, unlock the G-clamp and remove along with the femoral sizing spoon.

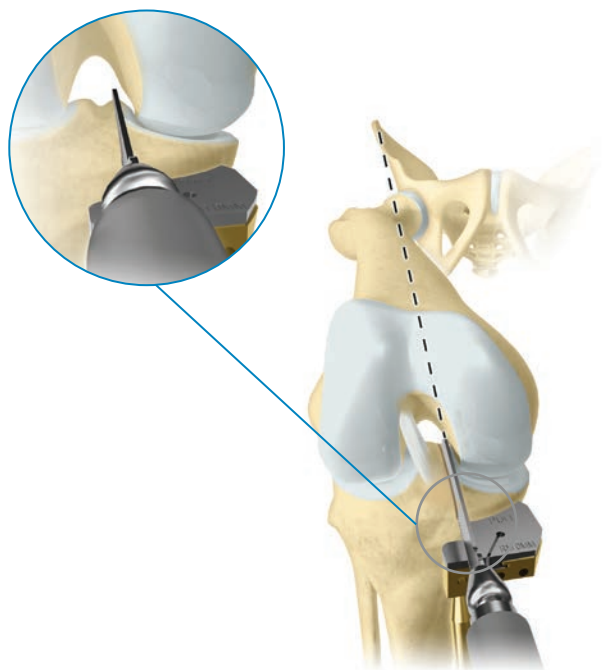


Figure 10

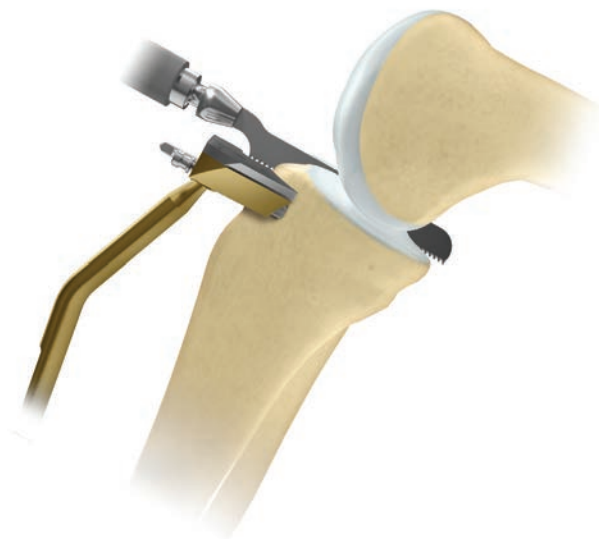

Figure 11

### Tibial Plateau Resection (cont.)

Confirm the proposed level of resection is correct. The saw cut should pass 2 or 3 mm below the deepest part of the erosion, unless the erosion is very deep in which case the cut should be above the bottom of the defect. If it seems that too much bone is being removed the zero shim can be replaced by the +2 shim which will remove 2 mm less bone.

Use a reciprocating saw with a stiff narrow blade to make the vertical tibial saw cut. The Oxford Saw Blade Kit contains blades with markings to indicate the depth to safely divide the posterior cortex. Push the blade into the intercondylar notch close to the lateral margin of the medial femoral condyle, from which the osteophytes were removed previously. The saw cut should be just medial to the apex of the medial tibial spine it will pass through the edge of the ACL insertion. Point the blade toward the anterior superior iliac spine or flexion plane (Figure 10), the position that is demonstrated by the assistant.

The saw must reach the back of the tibial plateau and a little beyond. This is achieved by lining up the appropriate mark on the saw with the anterior cortex. Advance the saw vertically down until it rests on the surface of the saw guide (Figure 11). The saw must remain parallel to the guide. Do not lift the saw handle as this will over resect posteriorly and increase the risk of tibial plateau fracture.

ⓘ **Note:** When performing a cementless procedure, the vertical resection should stop just above the tibial resection shim. It is imperative not to over resect.

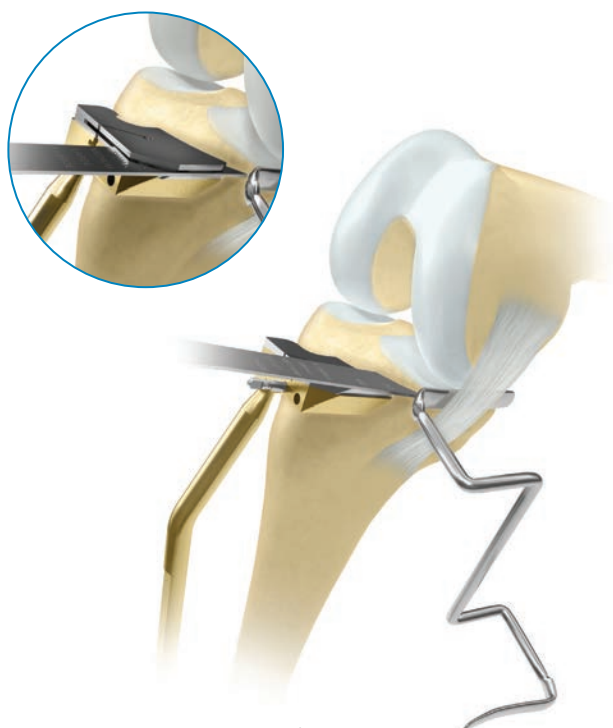


Figure 12




Figure 13

Before making the horizontal cut, insert a medial collateral ligament (MCL) retractor. Ensure this retractor is between the saw and the MCL.

Remove the 0 mm uncaptured shim from the tibial resection guide and insert the 0 mm captured shim (Figure 12 inset). This is especially important when performing a cementless procedure as the capture will help create a smooth horizontal resection.

Use a 12 mm wide oscillating saw blade with appropriate markings to excise the plateau (Figure 12). Ensure the saw blade is guided along the MCL retractor to completely cut the medial cortex. To cut the posterior cortex, deepen the cut until the appropriate mark on the saw blade is aligned with the anterior cortex. When the plateau is loose, lever it up with a broad osteotome and remove. Soft tissue attachments posteromedially may need to be cut with a knife. If cementless is to be utilised, smooth the vertical resection with a chisel.

**Note:** When making the horizontal cut a slotted shim may be used. This can be done by replacing the standard shim with the corresponding slotted shim. The slotted shim helps maintain the 7 degree posterior slope during the resection.

The excised plateau should show the classical lesion of anteromedial osteoarthritis, erosion of cartilage and bone in its mid and anterior parts and preserved cartilage posteriorly (Figure 13). Osteophytes around the edge of the plateau remain attached after its removal.

Lay templates of the opposite side on the cut surface of the excised plateau to choose the component with the appropriate width.

If the component of the appropriate width appears short, consider repeating the vertical cut 2 or 3 mm further lateral so that a wider (and longer) component may be used.

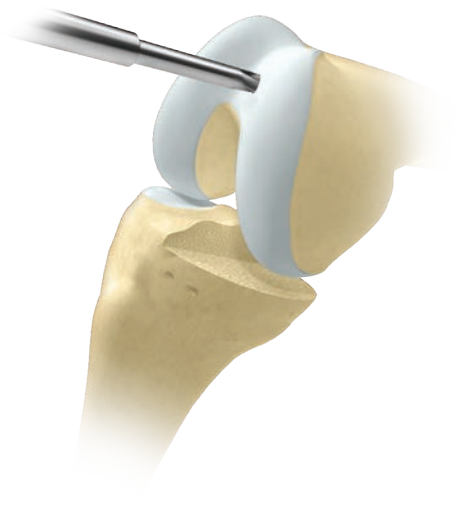

Figure 14

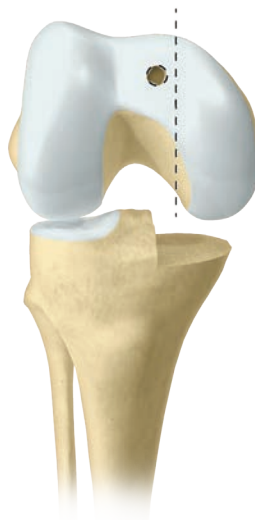


Figure 15

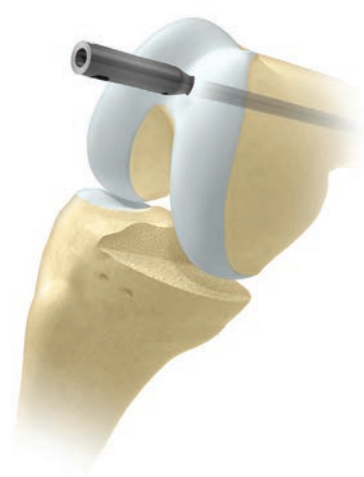

Figure 16

## The Femoral Drill Holes and Alignment

With the knee in about 45 degrees flexion, make a hole in the intramedullary canal of the femur with the 4mm drill. This should be completed with the 5mm awl (Figure 14).

The hole must be situated approximately 1 cm anterior to the insertion of the PCL and 2-3 mm lateral to the medial wall of the intercondylar notch (Figure 15). It should aim for the anterior superior iliac spine.

Insert the intramedullary (IM) rod until it stops against the bone (Figure 16).

Flex the knee to 90 degrees. This must be done with care, as the medial border of the patella abuts the IM rod. Using methylene blue or diathermy, draw a line down the center of the medial condyle.

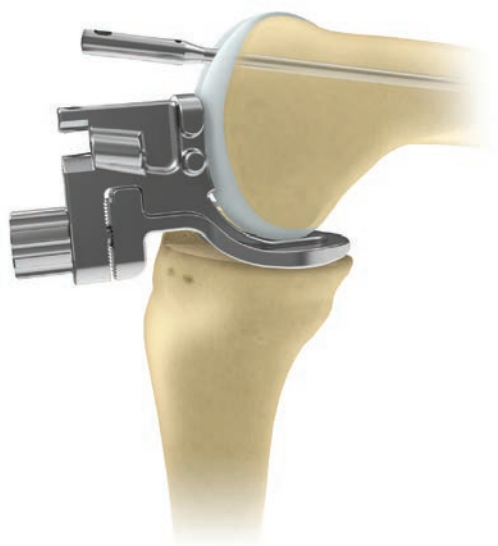


Figure 17

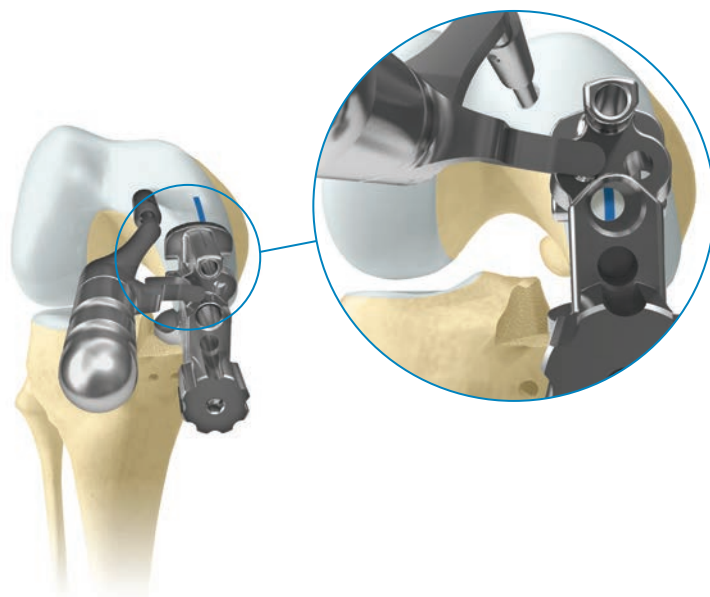


Figure 18

Set the femoral drill guide to the same setting as the G-Clamp. Insert the femoral drill guide (Figure 17). If the guide is very tight or loose it can be adjusted to be 1 mm thicker or thinner. If the guide set to 3 cannot be inserted more bone must be excised from the tibia. To do this, remove the initial 0 mm shim from the guide using the small nub on the Oxford IM Rod Removal Hook. If a +2 mm shim was used, exchange this for the 0 mm shim. This will remove 2 mm of additional bone. Reinsert the drill guide.

Insert the IM link into the IM rod and into the nearside/lateral hole of the femoral drill guide. This will ensure correct alignment of the guide.

There are two alignment requirements for the femoral drill guide:

1. The femoral drill guide must lie in the center of the medial condyle. This is done by ensuring the most medial and lateral bollards adjacent to the 6 mm hole are equidistant from the condyle edges. It can be confirmed by looking into the 6 mm hole and verifying the position of the methylene blue line. If the line is not central adjust the guide position.
2. The femoral drill guide must be placed against the bone of the medial femoral condyle.

Pass the 4 mm drill through the upper hole in the guide. Drill into the bone up to its stop and leave in place. Confirm all alignments ensuring the guide does not move medially or laterally. Advance the 6 mm drill through the lower guide hole until it stops (Figure 18). Remove drill and femoral drill guide.



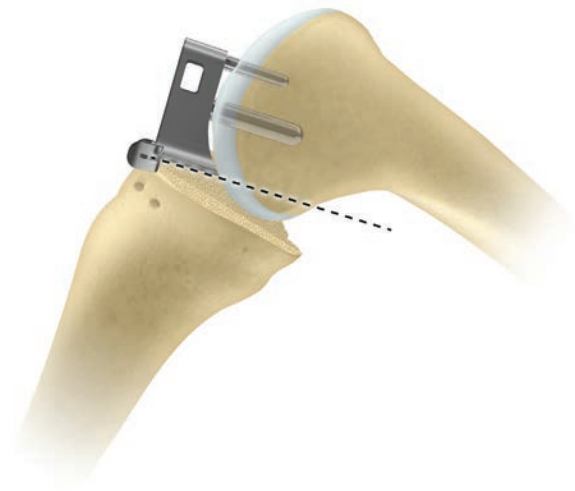


Figure 19

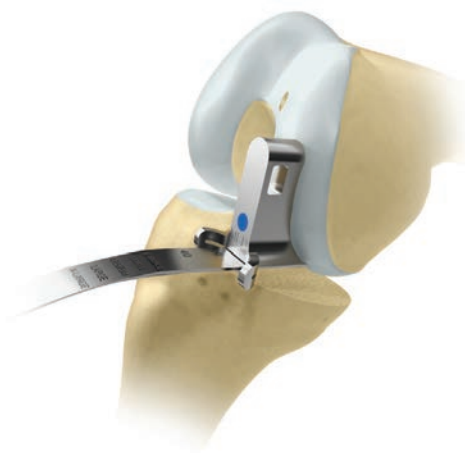

Figure 20

## Femoral Saw Cut

Insert the posterior resection guide into the drilled holes and tap home (Figure 19).

Insert a retractor to protect the MCL. Using the 12 mm broad sagittal saw, excise the posterior facet of the femoral condyle. The saw blade should be bent slightly by dropping the saw to ensure it is guided by the underside of the posterior resection guide (Figure 20). Take care to avoid damage to the medial collateral and anterior cruciate ligaments.

Remove the guide with the slap hammer, ensuring that it is withdrawn in line with the femoral drill guide holes as to not damage them. Remove the bone fragment.

There is now good access to the back of the joint and any remnants of the medial meniscus should be removed. In the region of the MCL, a small cuff of meniscus should be left to protect the MCL from the tibial component. The posterior horn should be completely removed.



Before advancing to the following surgical steps, consult the special note below.

### Special Note

The numbers marked on the feeler gauges and the meniscal bearings represent their least thicknesses in millimeters.

The scale of numbers of the spigots is in 1 mm increments, in an inverse ratio to the thickness of their flanges.

The spigots must be used as described below:

- **First Milling**

The 0 spigot is designed to automatically remove sufficient bone to allow the femoral component to seat. This amount varies with the degree of arthritic erosion of the condyle.

- **Second Milling**

Spigots 1 to 7 allow bone to be removed in measured quantities (in mm) from the level of the first mill cut. Thus, the number 3 spigot removes 3 mm, the number 4 spigot removes 4 mm, etc.

- **Subsequent Milling**

If the last spigot used was a number 3, a number 4 spigot will remove an additional 1 mm of bone (i.e. a total of 4 mm since the first milling). However, if the last spigot used was a number 4, a number 5 spigot is required to remove 1 mm of bone (i.e. a total thickness of 5 mm since the first milling).

**Remember:** The spigot number represents the total thickness of bone it removes from the level of the first mill cut.

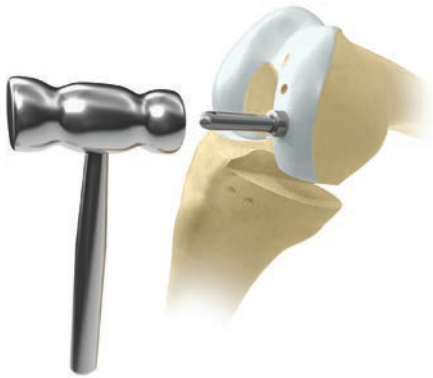

Figure 21

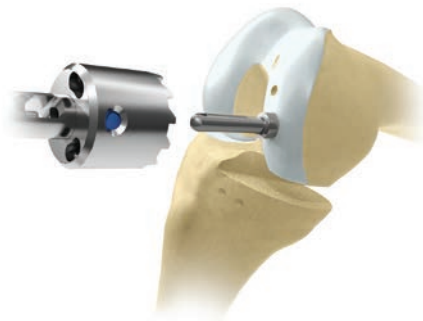

Figure 22

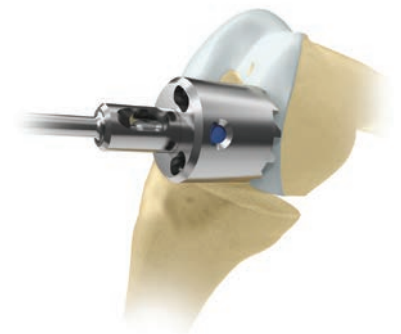

Figure 23

## First Milling of the Condyle

Insert the 0 spigot, which has the thickest flange, into the large drill hole and tap until the flange abuts the bone (Figure 21). The 0 spigot is the only spigot that may be tapped into place. All other spigots should be placed and seated by finger pressure or twisted into place with the universal removal hook.

By extending the knee slightly and retracting the soft tissues, maneuver the spherical mill onto the spigot (Figure 22) and into the wound so that the teeth touch the bone (Figure 23). Take care to avoid trapping soft tissues.

When milling, push firmly in the direction of the spigot axis, taking care not to tilt the mill. Mill until the mill will no longer advance and the spigot can be seen, in the window, to have reached its end stop.

If in doubt, continue to mill; the mill cannot continue beyond the amount permitted by the collar of the selected spigot.

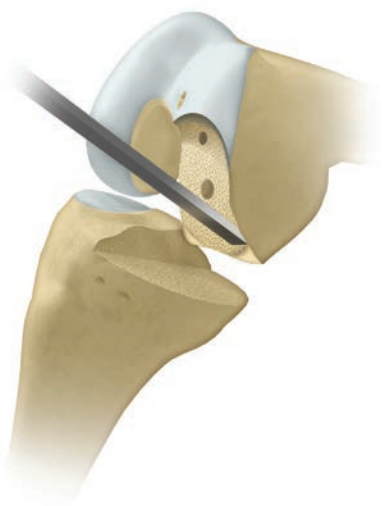

Figure 24

Remove the mill and the spigot and trim off the bone protruding from the posterior corners of the condyle that lie outside the periphery of the cutting teeth (Figure 24). These corners should be removed tangentially to the milled surface, taking care not to damage the flat posterior surface of the condyle.

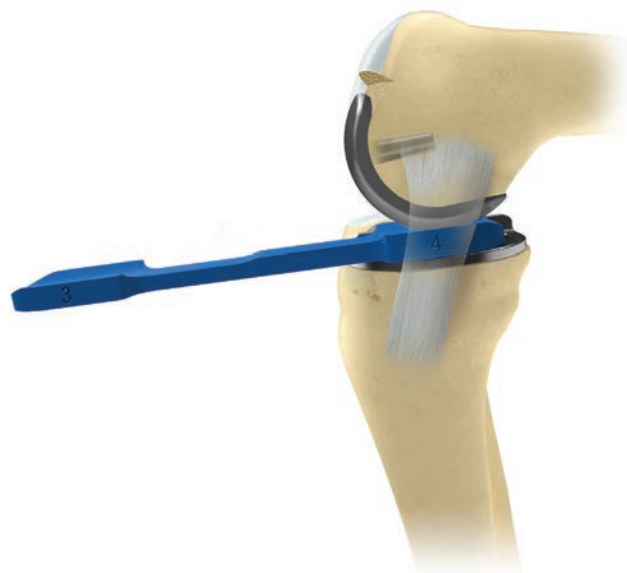

Figure 25

## Equalizing the Flexion and Extension Gaps

With the leg in 100 degrees of flexion, insert the tibial template and apply the single peg femoral trial component to the milled condyle, tapping it home with the femoral impactor angled at 45 degrees to the femoral axis.

**Note:** Due to the extended anterior flange of the twin peg femoral component, the single peg femoral trial should be used for equalizing the flexion and extension gaps. The twin peg femoral trial will not seat fully until the anti-impingement guide has been utilized.

### Part A

With the knee in about 100 degrees of flexion carefully measure the flexion gap with the feeler gauges (Figure 25). (A previous step has already ensured that the gap is wide enough to accept at least the 4 mm gauge, 3 mm in smallest patients). The gauge thickness is correct when natural tension in the ligaments is achieved. Under these circumstances, the feeler gauge will easily slide in and out, but will not tilt. Confirmation of the correct size is obtained by confirming that a 1 mm gauge thicker is firmly gripped and a 1 mm gauge thinner is loose.

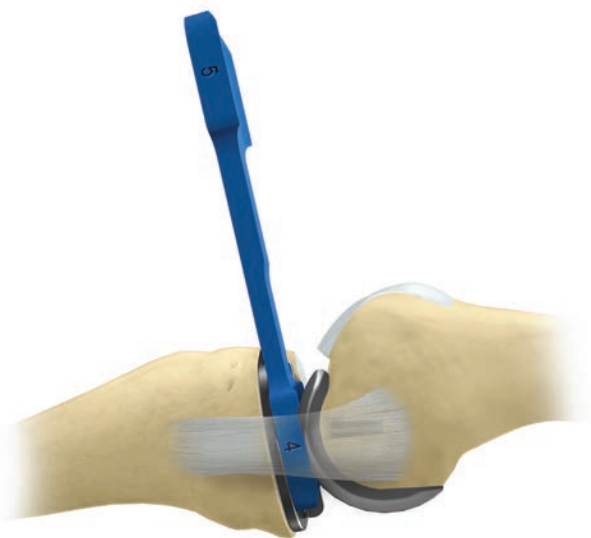

Figure 26

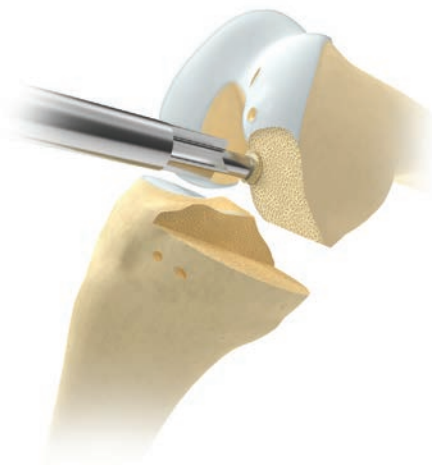


Figure 27

## Equalizing the Flexion and Extension Gaps (cont.)

### Part B

**Remove the feeler gauge.** It is important to remove the gauge before extending the knee because the extension gap is always narrower than the flexion gap at this stage. If it is left in place, the gauge may stretch or rupture the ligaments as the knee extends.

### Part C

Measure the extension gap (Figure 26) in 20 degrees of flexion, not full extension. In full extension, the posterior capsule is tight, and its influence gives a false under-measurement. The extension gap is usually less than 4 mm, if the thinnest (1 mm feeler gauge) cannot be inserted, the gap is assumed to be 0 mm.

Subtract the extension gap from the flexion gap to calculate additional bone removal. For instance, if the flexion gap measured 4 mm and the extension gap 1 mm, then the amount of bone to be milled is 3 mm. To achieve this, insert a 3 spigot and mill until the mill will not advance further.

After each milling, it is necessary to remove the remaining bone on the posterior corners of the condyle. Also, if the circular disc of bone left under the flange of the spigot is more than 1/2 mm thick, it should be removed by using the bone collar remover taking care not to damage the 6 mm hole (Figure 27). The reference for the spigot will not be lost, as its tip continues to reference off the bottom of the drill hole.

**The formula for balancing the flexion and extension gaps is as follows:**

$$\begin{aligned} \text{Flexion Gap (mm)} - \text{Extension Gap (mm)} &= \text{Thickness of bone to be milled from femur (mm)} \\ &= \text{Spigot number to be used} \end{aligned}$$

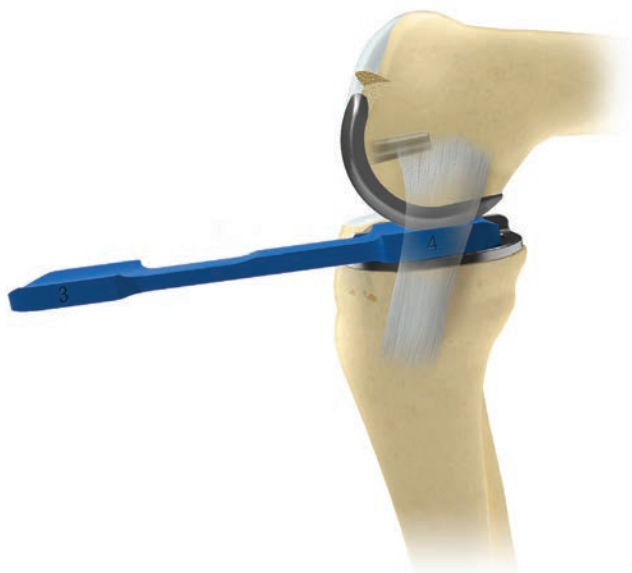

Figure 28

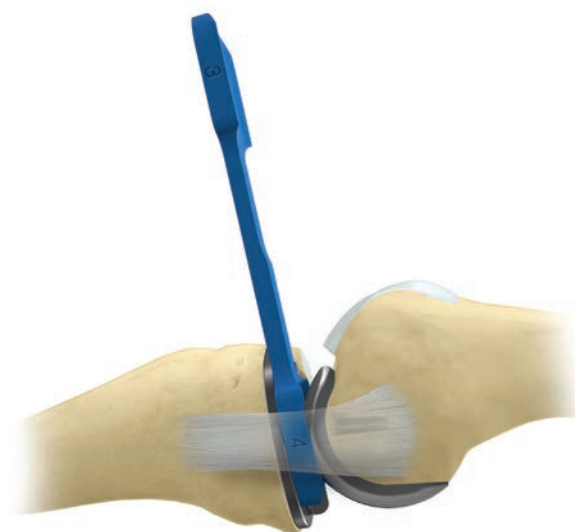


Figure 29

## Confirming Equality of the Flexion and Extension Gaps

With the tibial template and the single peg femoral trial component in place, re-measure the flexion and extension gaps (20 degrees flexion). They will usually be found to be the same (Figures 28 and 29).

If the extension gap at 20 degrees of flexion is still smaller than the flexion gap, remove more bone with the mill. This can be done, 1 mm at a time, by using the sequence of spigots. In the example above, an additional 1 mm of bone could be removed by using a 4 spigot.

Usually the knee is balanced with a 3, 4, or 5 spigot.

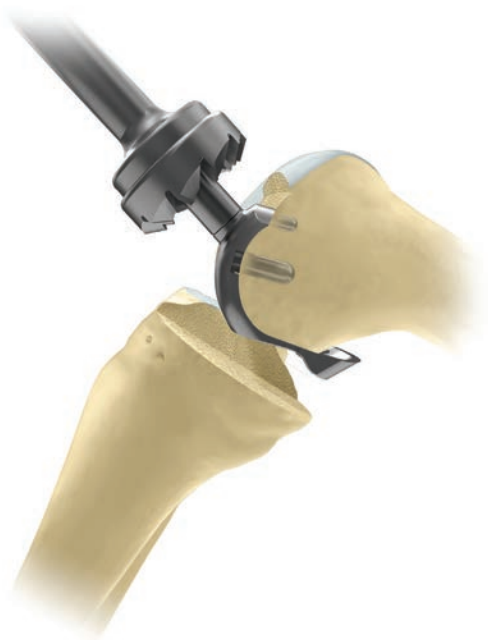

Figure 30

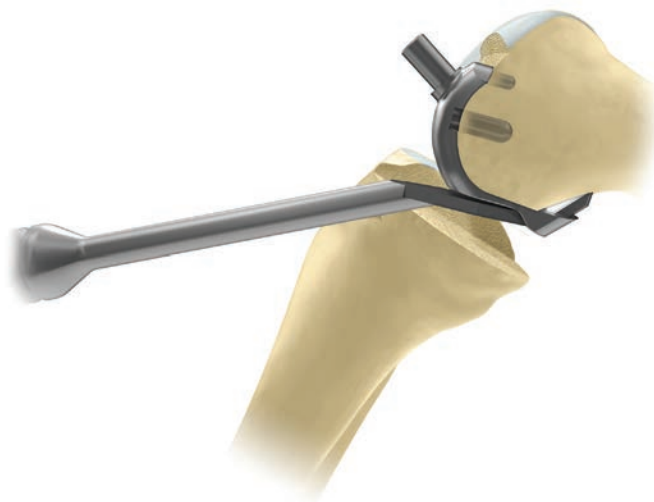

Figure 31

## Preventing Impingement

Trim the anterior and posterior condyle of the femur to reduce the risk of impingement of bone against the bearing in full extension and full flexion.

Apply the anti-impingement guide to the condyle and use the anterior mill to remove anterior bone and create clearance for the front of the bearing in full extension. When milling, push firmly in the direction of the peg axis, taking care not to tilt the mill. Mill until the mill will not advance further (Figure 30).

Ensure that impingement does not occur between the mill and tibia by adjusting flexion.

Leave the anti-impingement guide in place and use the osteophyte chisel to remove any posterior osteophytes (Figure 31). This should be done medially and laterally as well as centrally. Remove the guide and any detached osteophytes. Palpate, with a finger, the proximal part of the condyle to ensure all osteophytes are removed.



Figure 32

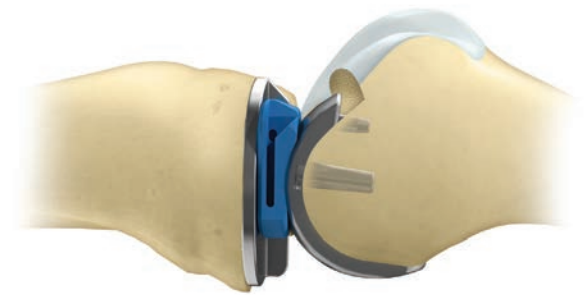


Figure 33

Insert tibial template, twin peg femoral trial component and a trial bearing of appropriate size. With the trial components in place, manipulate the knee through full range of motion to ensure there is no impingement of bone against the bearing in full extension and full flexion (Figures 32 and 33).

Ensure the bearing is not hitting the vertical wall. If a narrow dissector put between the bearing and the wall is gripped by the bearing, consider redoing the vertical cut laterally.

Remove the trial components using the appropriate extractors.

ⓘ **Note:** Previously, feeler gauges have been used to measure the gaps because they do not stretch the ligaments. The meniscal bearings have a 3 mm high posterior lip which, after multiple insertions, may stretch the ligaments.

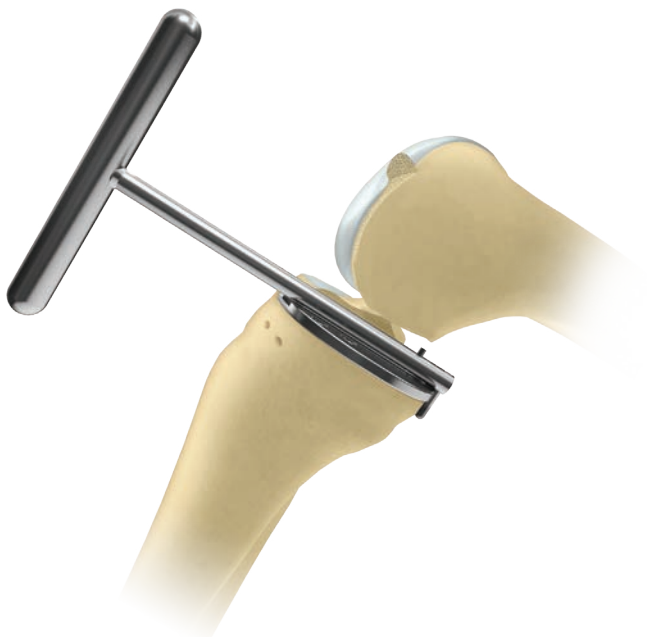

Figure 34

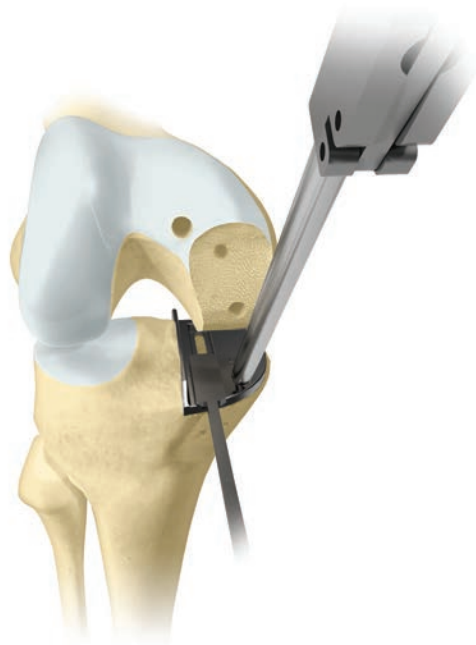

Figure 35

### Final Preparation of the Tibial Plateau

Insert the appropriate size tibial template. To ensure the correct size, position the tibial template with its posterior margin flush with the posterior tibial cortex. This is facilitated by passing the universal removal hook over the posterior cortex of the tibia (Figure 34). The tibial template should be flush with the medial cortex or overhanging slightly. If it overhangs by 2 mm or more use a smaller size tibial component.

Force the tibial plateau laterally against the vertical cut and pin in place. Hold the pin throughout sawing to prevent movement.



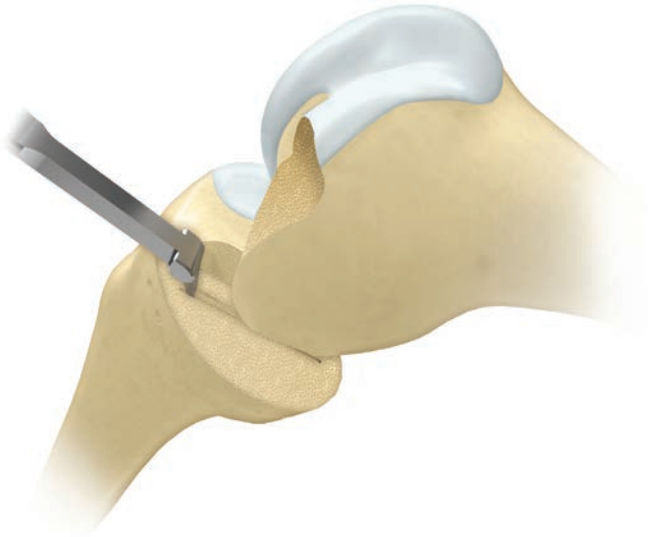


Figure 36

After removing the tibial template, excavate the groove to the correct depth by scooping out the bone with the blade of the cemented tibial keel pick, taking care not to damage the anterior and posterior cortices (Figure 36).

The safest way to prepare the back of the groove is to feel the posterior cortex with the tibial keel pick and then move it anteriorly by 5 mm before pushing down and bringing forward to empty the groove.

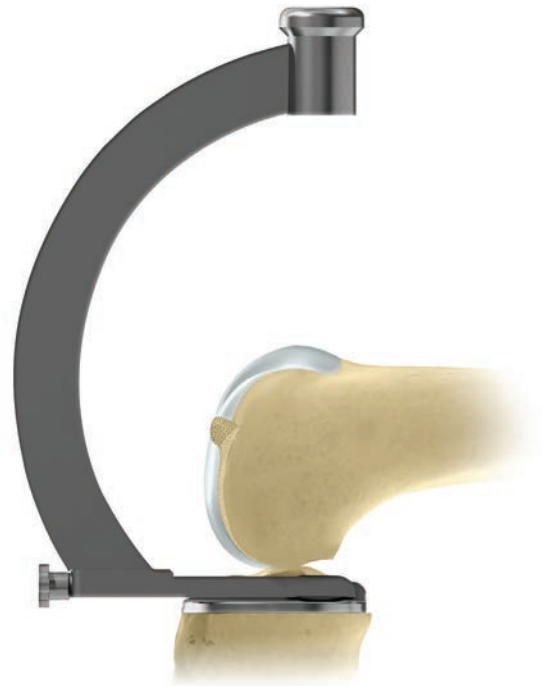

Figure 37

Insert the trial tibial component and tap with the tibial impactor until fully seated (Figure 37).

Ensure component is flush with the bone and the posterior margin extends to the back of the tibia. If the component does not seat fully remove it and clean the keel slot out again with the cemented tibial keel pick.

Use only the toffee hammer to avoid the risk of plateau fracture.

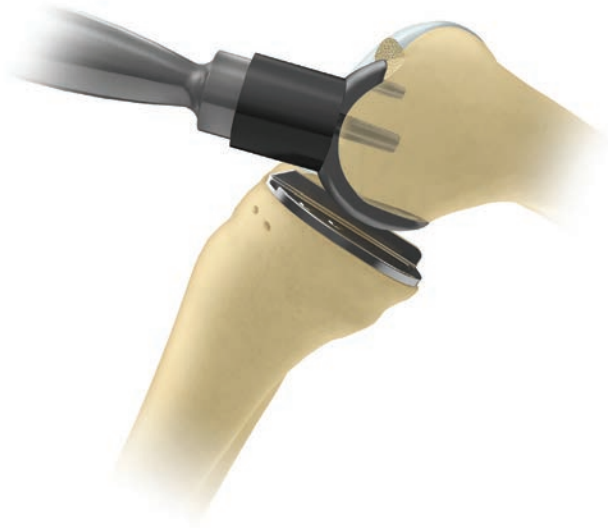

Figure 38

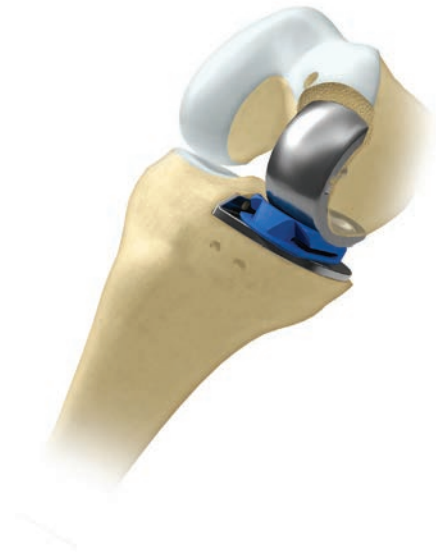

Figure 39

### Final Trial Reduction

Insert the twin peg femoral trial component and ensure it is fully seated by tapping home with the femoral impactor at 45 degrees to the femoral axis (Figure 38).

Insert a trial meniscal bearing of the chosen thickness (Figure 39).

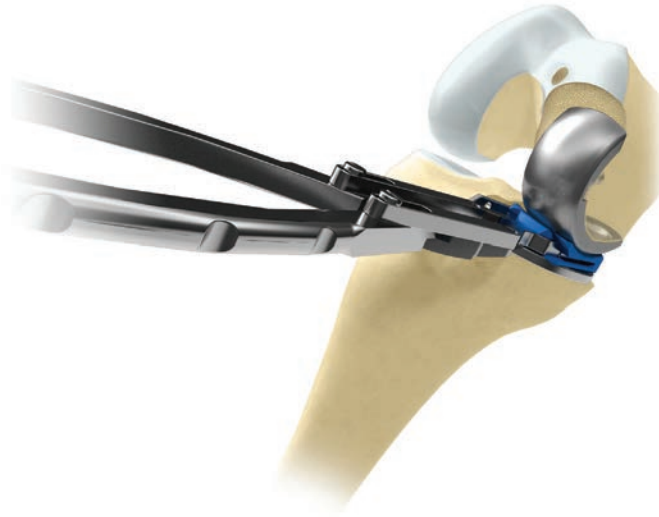


Figure 40

With the bearing in place, manipulate the knee through a full range of motion to demonstrate stability of the joint, security of the bearing and absence of impingement. The thickness of the bearing should be such as to restore the ligaments to their natural tension. This is best demonstrated by inserting the bearing extractor and gently lifting its handle. The front of the bearing should lift about 2 mm. Alternatively, when a valgus force is applied to the knee, the artificial joint surfaces distract a millimeter or two.

This test should be done with the knee in 20 degrees of flexion. In full extension, the bearing will be firmly gripped because of the tight posterior capsule.

Remove the bearing with the bearing extractor (Figure 40).

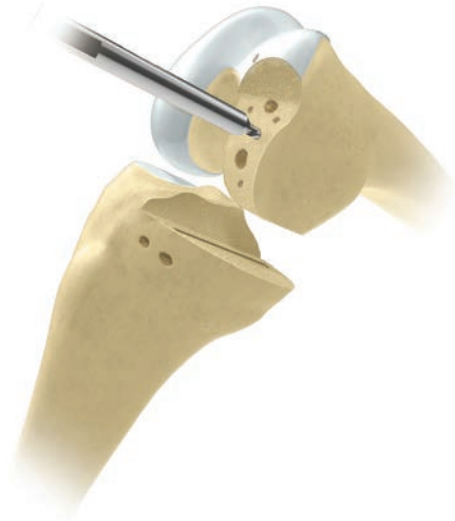

Figure 41

## Cementing the Components

Roughen the femoral and tibial surfaces including the posterior condyles, by making multiple small drill holes with the cement key drill (Figure 41).

The components are fixed with two separate mixes of cement.

### The Tibial Component

Place a small amount of cement on the tibial bone surface and flatten to produce a thin layer covering the whole under surface. Insert the component and press down, first posteriorly and then anteriorly, to squeeze out excess cement at the front.

Use the right-angled tibial impactor with a small mallet to complete the insertion. Ensure there is no soft tissue under the component. Remove excess cement with a Woodson cement curette from the margins of the component. Insert the femoral trial component and pressurize cement by inserting the appropriate feeler gauge. With the feeler gauge inserted, hold the leg in 45 degrees of flexion while the cement sets. Do not fully extend or flex the leg, as this may rock the component.

Once the cement has set, remove the feeler gauge and trial femoral component and look carefully for cement that may have extruded. Slide the flat plastic probe along the tibial articular surface, feeling for cement at the edges and posteriorly.



Figure 42



Figure 43

### The Femoral Component

From the second mix, force cement into the large femoral drill hole and fill the concave surface of the femoral component with cement. Apply the loaded component to the condyle and impact with the punch held at 45 degrees to the long axis of the femur. Remove excess cement from the margins with a Woodson cement curette. Pressurize the cement by inserting the appropriate feeler gauge with the knee at 45 degrees of flexion and holding the leg in this position. Do not fully extend or flex the knee or this may rock the components and may loosen them.

Once the cement has set, remove the feeler gauge. Clear the medial and lateral margins of the component of any extruded cement. The posterior margin cannot be seen but can be palpated with a curved dissector.

Reassess the gap by inserting a trial bearing. Occasionally a smaller size is needed due to gap closure from the cement mantle.

Complete the reconstruction by snapping the chosen bearing into place (Figures 42 and 43).

Close the wound in a routine manner.

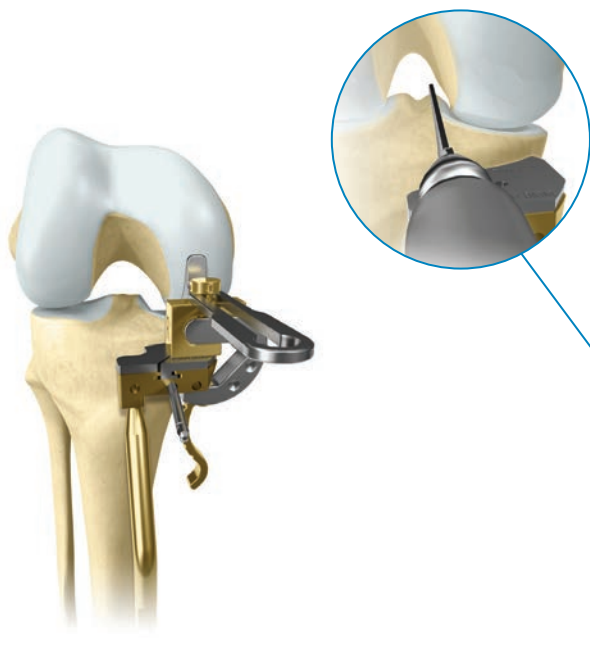


Figure 44

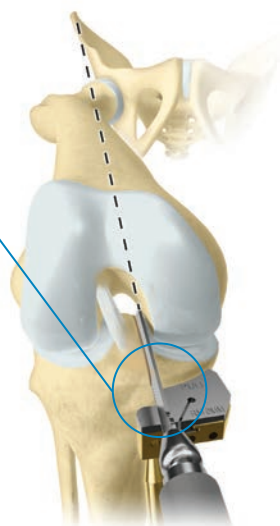


Figure 45

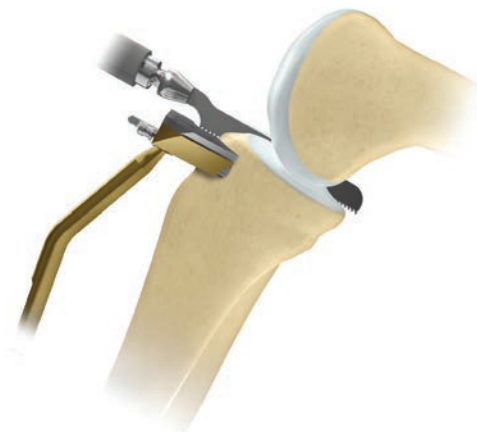

Figure 46

## Cementless Procedure Cementless Components

The pockets of the twin peg femoral components are filled with PPS® Porous Plasma Spray (PPS) and hydroxyapatite (HA) coating. The tibial components have PPS and HA coating on all bone/implant interfaces. The tibial components have PPS and HA on all bone/implant interfaces. In a randomized controlled trial they have been shown to have a similar clinical outcome to the cemented although there is a lower incidence of radiolucent lines.<sup>19</sup> In a 5 year follow up study, Pandit, *et al* found no increase of radiolucent lines in the cementless group.<sup>20</sup> The bone surfaces have to be carefully prepared for cementless fixation to minimize the risk of loosening and fracture.

## Tibial Preparation for Cementless Fixation

To optimize cementless tibial fixation and minimize the risk of fracture it is important to achieve flat bone surfaces, with no stress risers and to use the largest component possible.

To avoid recutting the tibia, which may result in an uneven surface, use the 4 G clamp (Figure 44). For small patients the 3 G clamp is acceptable, but ensure to use a spoon that is not tightly gripped. Do not use the +2 shim. Only recut if, at trial reduction with a trial template, a 3 bearing is too tight.

The vertical saw cut should be made just medial to the apex of the medial tibial spine and must not be too deep (Figure 45). To prevent the cut from being too deep the saw blade should be parallel to the tibial resection guide and the surgeon must not lift his hand whist sawing (Figure 46).




Figure 47

The slotted zero shim must be used for the horizontal cut.

Alternatively, the horizontal resection can be made first. Mark the position of the vertical cut using bovie and extend the line in the flexion plane. This line should be just medial to the apex of the tibial spine. With the slotted zero shim assembled to the tibial resection guide, make the horizontal resection first. This resection can slightly undermine the ACL insertion of the tibia up to 5 mm.

After the resection is complete, replace the slotted zero shim with the unslotted zero shim. A saw blade or Vertical Resection Shim can be inserted into the horizontal resection and positioned laterally. This instrument serves as a reciprocating saw stop. With the reciprocating saw, make the vertical resection on the line identified with the bovie. The vertical cut is complete when the reciprocating saw blade comes into contact with the retained saw blade or the Vertical Resection Shim that was positioned in the horizontal resection. This may help minimize over-resection of the posterior tibial cortex.

The excised tibial plateau should be compared with a tibial template. If a template of an appropriate width is too short the vertical cut should be repeated so that a larger tibial component can be inserted. The component should fit the tibia and reach the posterior medial and anterior cortex.

Avoid recutting the tibia if possible: If it is found that the femoral drill guide set to 3 mm cannot be inserted easily it should be pushed in instead of recutting the tibia (assuming the zero shim was used). This will either compress or remove some of the cartilage of the back of the femur, which will elevate the joint line slightly. It is preferable to elevate the joint line rather than recut the tibia.

## Femoral Preparation

Care must be taken not to damage the 6 mm hole during femoral preparation. If the hole is damaged femoral fixation will be compromised. The most common step in which the hole is damaged is during milling. It is essential that during milling force is applied along the axis of the mill and not to the drill handle (Figure 47).

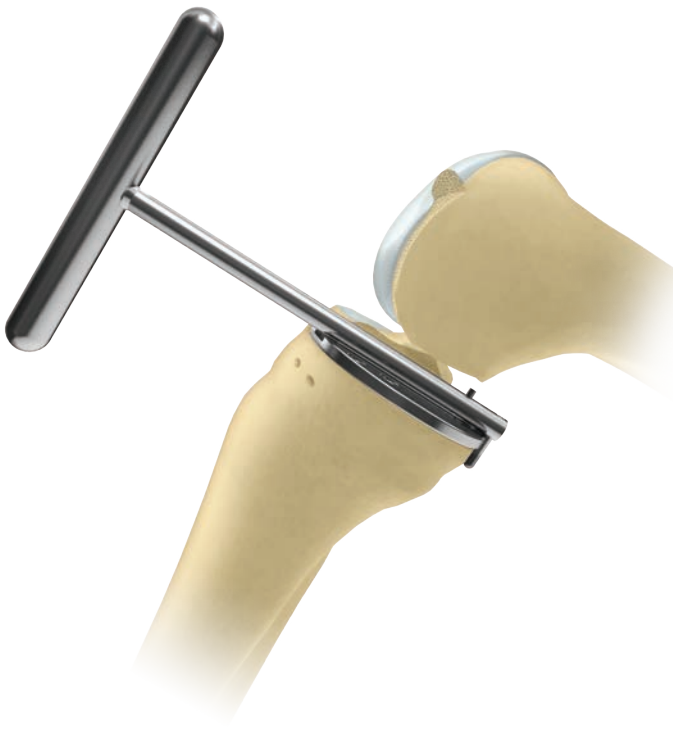

Figure 48

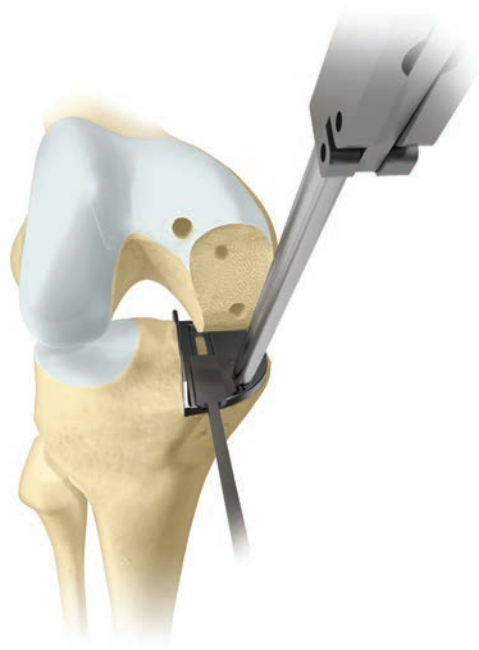

Figure 49

## Final Preparation of the Tibial Plateau

Insert the appropriate size tibial template. To ensure the correct size, position the tibial template with its posterior margin flush with the posterior tibial cortex. This is facilitated by passing the universal removal hook over the posterior cortex of the tibia (Figure 48). The tibial template should be flush with the medial cortex or overhanging slightly. If it overhangs by 2 mm or more use a smaller size tibial component. If it is 3 mm or more from the anterior cortex redo the vertical cut 2 mm more laterally so a larger size component can be used.

Force the tibial plateau laterally against the vertical cut and pin in place using the most posterior of the 2 holes. The surgeon should hold the pin throughout sawing to ensure that the tibial template does not move. If it does move the posterior cortex may be damaged.

Introduce the cementless keel-cut saw into the front of the slot and saw until sunk to its shoulder (Figure 49). The saw blade is lifted up and down as it is advanced posteriorly. Confirm the cut is complete by holding the pin and feeling the saw hit the front and back of the keel slot. Once the saw cuts are complete, remove the tibial template.

**Note:** The cementless keel-cut saw must be used with the cementless tibial templates.

The keel-cut saw should remove all the bone necessary for cementless fixation. As a result the keel pick should not be used at this stage.



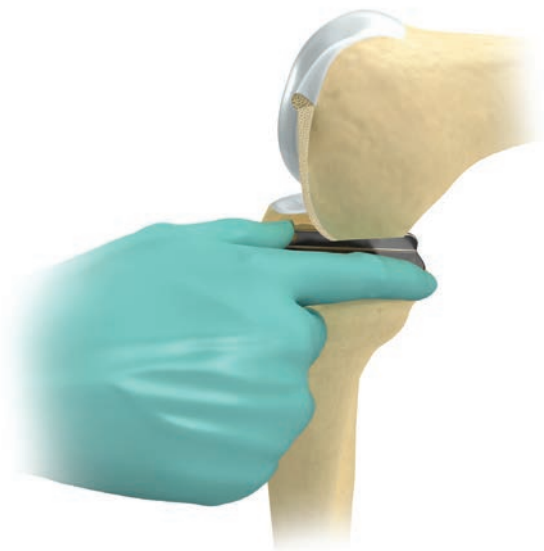

Figure 50



Figure 51

Thoroughly wash the tibial plateau and keel slot and then insert the trial tibial component by hand (Figure 50). If the trial does not fully seat in the identical position to the template ensure there is no soft tissue obstructing it and give it a gentle tap with the Toffee Mallet. If the trial still does not fit, use the cemented pick without the tibial template to widen the keel slot and to ensure that there are no small bone fragments that are preventing the component from seating. **Care should be taken when using the cemented pick especially in the posterior cortex region.**

**In addition, if preparation of the keel slot is difficult, and the keel looks as though it may hit the cortex, the Oxford Cemented Partial Knee should be considered.**

## Implanting the Components

The tibial implant is assembled into the introducer/impactor by locating it into the recesses on the underside and tightening the thumb wheel (Figure 51).

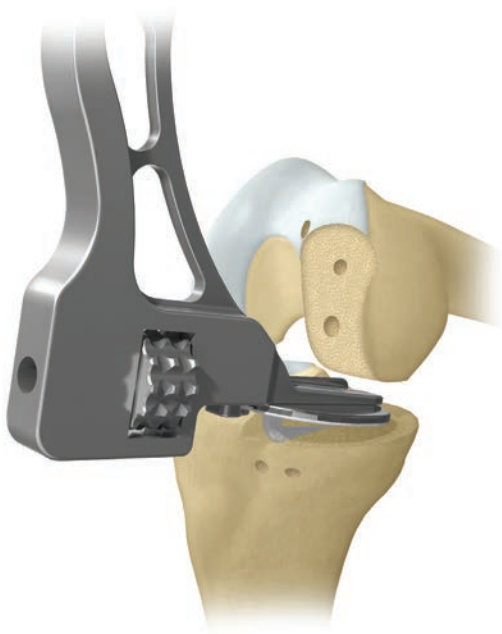

Figure 52

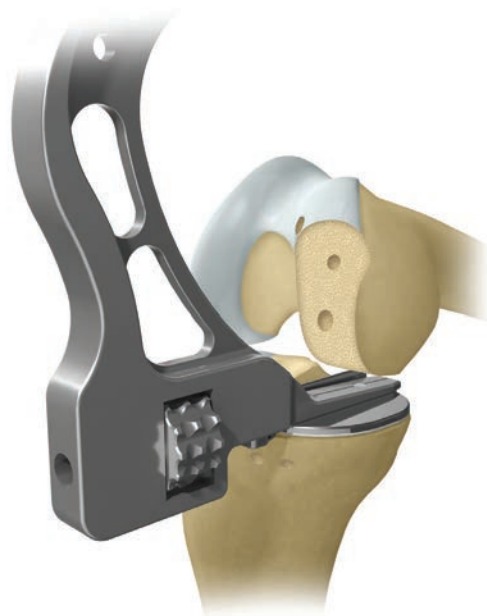

Figure 53

### Implanting the Components (cont.)

The knee is flexed fully and, using the Toffee Mallet, the component is then carefully impacted, with the keel passing obliquely at an angle into the keel slot (Figures 52 & 53).

Before it is fully seated, the introducer/impactor is removed by unscrewing the thumb wheel. Using a small dissector, any soft tissue interposed between the implant and bone is pushed out. The AP position of the component is adjusted until correct by impacting the component posteriorly. Final impaction of the tibial component is achieved with the Toffee Mallet and the standard impactor placed centrally over the keel. If the component does not fully seat it is better to accept this rather than impact it with a heavy mallet, it will subside into place in time.

The femoral component is inserted and impaction of the femoral component is achieved with the standard femoral impactor. Both components are examined to ensure they are fully seated.

Reassess the gap by inserting a trial bearing. Once thickness is confirmed, complete the reconstruction by swapping the chosen bearing into place.

Close the wound in a routine manner.

## Appendix

### Postoperative Treatment

Forcing flexion of the knee during the first postoperative week often causes pain and is unnecessary since movements are almost always recovered spontaneously.

### Postoperative Radiographic Assessment

Postoperative radiographs can be used to measure the technical success of the operation. For this purpose, as well as to facilitate their comparison with follow-up radiographs, the films should be taken in a reproducible manner. Even small variations in the angle of incidence of the X-ray beam can distort the images of the components and make accurate assessment of their positions and bone/cement interfaces difficult.<sup>21</sup>

### Radiographic Technique

Accurately aligned radiographs are best taken with an image intensifier (fluoroscope). If this is not available, a digital system can be used. Low dose images are taken and then adjusted until the optimal image is obtained.

#### Anterior Projection

The shape of the tibial component allows it to be used to center the X-ray beam and to align it in all three planes. Position the patient supine on a standard fluoroscopic screening table with an undercouch tube and an image intensifier. Before taking the film, adjust the position of the limb by flexing/extending the knee and internally/externally rotating the leg until the tibial component appears on the screen directly 'end-on.'

#### Lateral Projection

With the leg flexed 40 degrees, internally/externally rotate the thigh until the tibial component appears on the screen directly 'edge-on.'

The components ideally implanted are shown in Figure 54.

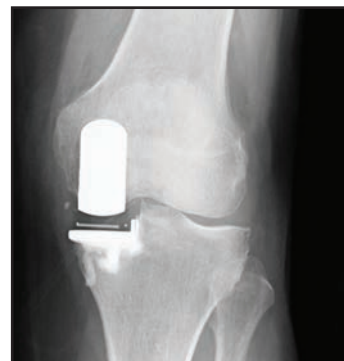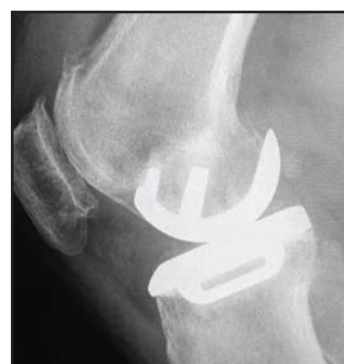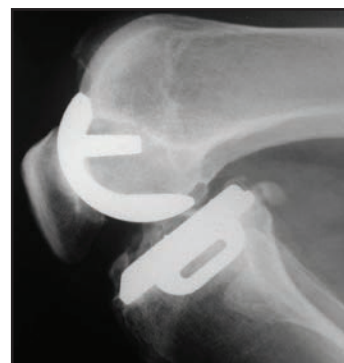


Figure 54

Appendix

Radiographic Criteria

If all steps have been followed as described in this surgical technique, the postoperative appearances should be as shown in Figure 55.

Position and Size of Components

Femoral Component (Relative to the Femur)

A/A	Varus/valgus angle	< 10 degrees varus — < 10 degrees valgus
B/B	Flexion/extension angle	15 degrees flexion — < 0 degrees extension
C/C	Medial/lateral placement	Central
D	Posterior fit	Flush or < 4 mm overhang

Tibial Component (Relative to the Tibia)

E/E	Varus/valgus angle	< 5 degrees varus — < 5 degrees valgus
F/F	Posteroinferior tilt	7 degrees +or- 5 degrees
G	Medial fit	Flush or < 2 mm overhang
H	Posterior fit	Flush or < 2 mm overhang
J	Anterior fit	Flush or < 5 mm short
K	Lateral fit	Flush — No gap

Meniscal Bearing  
(Relative to the Tibial Component)

L	X-ray marker central and parallel with the tibial component	
---	---	--

Bone Interfaces

M	Posterior femoral	Parallel surfaces: Cement OK
N	Tibial	Parallel surfaces: Cement OK

Other

O	Posterior osteophytes	None visible
P	Depth of tibial saw cuts	Minimal ingress of cement
Q	Intact posterior cortex	No extruded cement posteriorly
R	No anterior impingement	Adequate bone removed; no cement

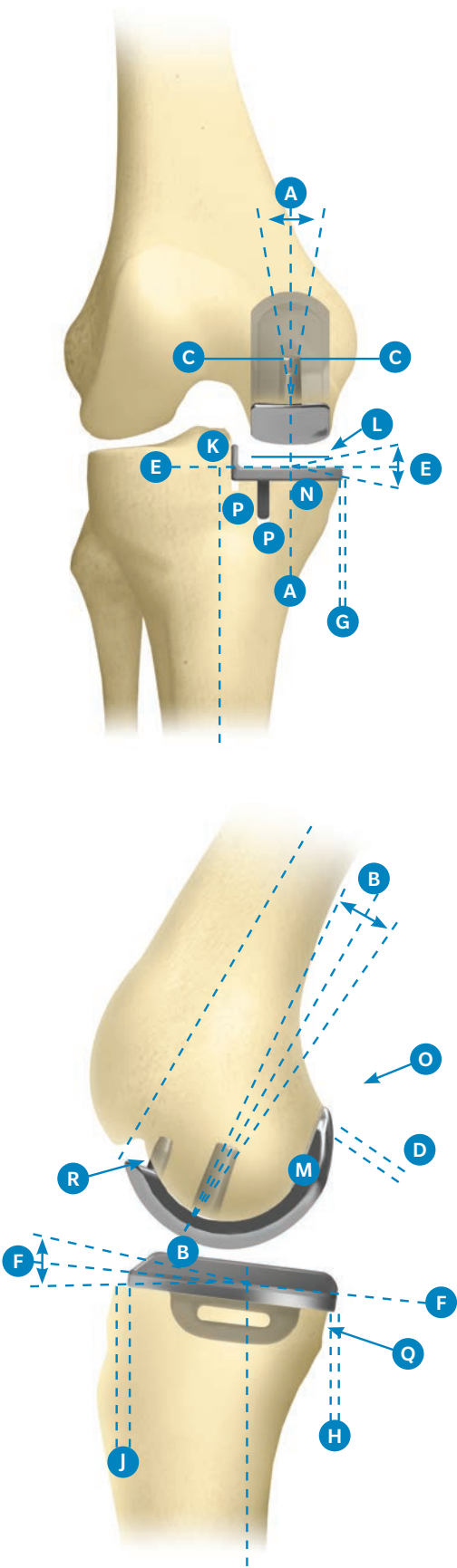


Figure 55

## Appendix

### Follow-up Radiographs

All subsequent radiographs should be taken in the same manner as the immediate postoperative films to allow comparison. Fluoroscopically centered films are particularly appropriate for demonstrating the state of the interface beneath the tibial plateau.

This interface changes gradually during the first year after implantation, after which it should remain unaltered. The typical appearances, at one year and at ten years, are shown in figure 56. A thin radiolucent line (ca 1 mm) is almost always seen, defined on its deep surface by a thin radiodense line. Histologically, the radiolucent line represents a layer of fibrocartilage, with its collagen organized parallel with the plateau. The radiodense line represents a new 'subchondral bone plate.' The trabeculae, which were cut at the operation, attach to this plate and support it. The collagen fibres of the cartilage layer insert into its upper surface.<sup>17</sup> There are some areas within the radiolucency in which there is direct contact between cement and bone.

The appearances under the femoral component are the same, but are not easily demonstrated because of the non-planar form of the femoral interface.

The radiographic changes which occur during the first postoperative year result from healing of the cut bone and its remodeling to sustain the new pattern of compressive load applied to it by the rigid implant.

Mature interfaces of this type have proven stable for as long as 15 years in 95 percent of cases (Phase II).<sup>22</sup> Therefore it is important not to ascribe clinical symptoms to these 'normal' appearances or to interpret them as evidence of implant loosening.

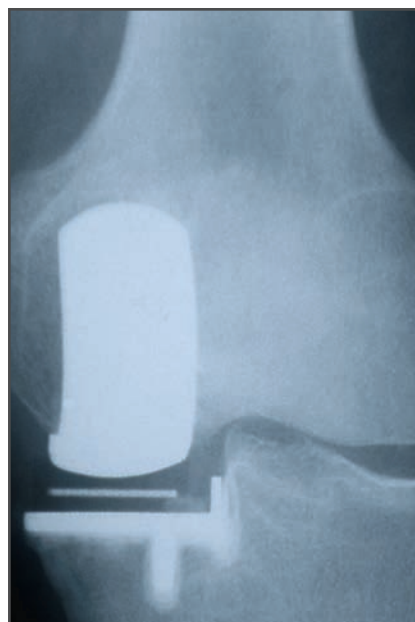




Figure 56

# Implants


## Cemented Femoral Components

Product	Part Number	Description	Size
	166940	Oxford Twin Peg Femoral Component	Extra Small
	166941		Small
	166942		Medium
	166943		Large
	166944		Extra Large

## Cementless Femoral Components


Product	Part Number	Description	Size
	154912	Femoral Components - PPS/HA Coated	Extra Small
	154925		Small
	154926		Medium
	154927		Large
	154928		Extra Large

## Cemented Tibial Components


Product	Part Number	Description	Size
	159531	Oxford Tibial Component, Left Medial	AA
	159532	Oxford Tibial Component, Right Medial	AA
	154718	Oxford Tibial Component, Left Medial	A
	154719	Oxford Tibial Component, Right Medial	A
	154720	Oxford Tibial Component, Left Medial	B
	154721	Oxford Tibial Component, Right Medial	B
	154722	Oxford Tibial Component, Left Medial	C
	154723	Oxford Tibial Component, Right Medial	C
	154724	Oxford Tibial Component, Left Medial	D
	154725	Oxford Tibial Component, Right Medial	D
	154726	Oxford Tibial Component, Left Medial	E
	154727	Oxford Tibial Component, Right Medial	E
	154775	Oxford Tibial Component, Left Medial	F
	154776	Oxford Tibial Component, Right Medial	F

## Implants

### Cementless Tibial Components


Product	Part Number	Description	Size
	166570	Oxford Cementless Tibial Component, Left Medial	AA
	166571	Oxford Cementless Tibial Component, Right Medial	AA
	166845	Oxford Cementless Tibial Component, Left Medial	A
	166846	Oxford Cementless Tibial Component, Right Medial	A
	166572	Oxford Cementless Tibial Component, Left Medial	B
	166573	Oxford Cementless Tibial Component, Right Medial	B
	166574	Oxford Cementless Tibial Component, Left Medial	C
	166575	Oxford Cementless Tibial Component, Right Medial	C
	166576	Oxford Cementless Tibial Component, Left Medial	D
	166577	Oxford Cementless Tibial Component, Right Medial	D
	166578	Oxford Cementless Tibial Component, Left Medial	E
	166579	Oxford Cementless Tibial Component, Right Medial	E
	166580	Oxford Cementless Tibial Component, Left Medial	F
	166581	Oxford Cementless Tibial Component, Right Medial	F

### Bearings





Product	Part Number					Description	
	Extra Small	Small	Medium	Large	Extra Large	Thickness	Side
	159790	159540	159547	159554	159561	3 mm	Left
	159791	159541	159548	159555	159562	4 mm	
	159792	159542	159549	159556	159563	5 mm	
	159793	159543	159550	159557	159564	6 mm	
	159794	159544	159551	159558	159565	7 mm	
	159795	159545	159552	159559	159566	8 mm	
	159796	159546	159553	159560	159567	9 mm	
	160790	159568	159575	159582	159589	3 mm	Right
	160791	159569	159576	159583	159590	4 mm	
	160792	159570	159577	159584	159591	5 mm	
	160793	159571	159578	159585	159592	6 mm	
	160794	159572	159579	159586	159593	7 mm	
	160795	159573	159580	159587	159594	8 mm	
	160796	159574	159581	159588	159595	9 mm	







Instrumentation




32-423532 Tibial Case 1—Upper Insert Tray

Product	Label	Part Number	Description	Size
		32-423539	Oxford Microplasty Instrument Tray (Tray Only)	–
	A	32-422849	Oxford Tibial Template Right Medial	AA
		32-422850	Oxford Tibial Template Left Medial	AA
		32-422851	Oxford Tibial Template Right Medial	A
		32-422852	Oxford Tibial Template Left Medial	A
		32-422853	Oxford Tibial Template Right Medial	B
		32-422854	Oxford Tibial Template Left Medial	B
		32-422855	Oxford Tibial Template Right Medial	C
		32-422856	Oxford Tibial Template Left Medial	C
		32-422857	Oxford Tibial Template Right Medial	D
		32-422858	Oxford Tibial Template Left Medial	D
		32-422859	Oxford Tibial Template Right Medial	E
		32-422860	Oxford Tibial Template Left Medial	E
		32-422861	Oxford Tibial Template Right Medial	F
		32-422862	Oxford Tibial Template Left Medial	F
	B	32-467619†	Quick-Release Drill Bit (PK/2)	–
	C	32-420802	Tibial Resector Headless Pin (PK/2)	–
	D	32-347911†	Bone Pin (PK/2)	–













Product	Label	Part Number	Description	Size
	E	32-420160†	Pin Inserter/Extractor	–
	F	32-422455	Oxford Tibial Template Nail	–
	G	32-421064	Oxford Tibial Trial Left Medial	AA
		32-421065	Oxford Tibial Trial Right Medial	AA
		32-420820	Oxford Tibial Trial Left Medial	A
		32-420821	Oxford Tibial Trial Right Medial	A
		32-420730	Oxford Tibial Trial Left Medial	B
		32-420731	Oxford Tibial Trial Right Medial	B
		32-420732	Oxford Tibial Trial Left Medial	C
		32-420733	Oxford Tibial Trial Right Medial	C
		32-420734	Oxford Tibial Trial Left Medial	D
		32-420735	Oxford Tibial Trial Right Medial	D
		32-420736	Oxford Tibial Trial Left Medial	E
		32-420737	Oxford Tibial Trial Right Medial	E
		32-420822	Oxford Tibial Trial Left Medial	F
		32-420823	Oxford Tibial Trial Right Medial	F
	H	32-467618†	AGC® Quick Release Drill Chuck	–

Instrumentation




32-423532 Tibial Case 1—Lower Insert Tray







Product	Label	Part Number	Description	Size
		32-423539	Oxford Microplasty Instrument Tray (Tray Only)	–
	A	32-422365	Oxford Femoral Slap Hammer	–
	B	32-422457	Oxford Tibial Groove Cutter (Cementless)	–
	C	32-422991**	Woodson Cement Curette	–
	D	32-420932	Oxford Tibial Impactor	–
	E	32-420804	Oxford Cement Removal Chisel	–
	F	32-401111	Oxford IM Rod Removal Hook	–




Product	Label	Part Number	Description	Size
	G	32-422718	Oxford Trial Bearing Extractor	–
	H	32-422097	Cementless Tibial Inserter	–
	I	32-420660	Oxford Hexagon Driver	–
	J	32-422936	Oxford Cemented Tibial Groove Cutter	–

Instrumentation




32-423533 Tibial Case 2—Upper Insert Tray

Product	Label	Part Number	Description	Size
		32-423540	Oxford Microplasty Instrument Tray (Tray Only)	–
	A	3000-02**	MCL Retractor	–
	B	32-422985	Tibial Resection Guide Shim, Right Medial, Unslotted	0 mm
		32-423223	Tibial Resection Guide Shim, Right Medial, Slotted	0 mm
		32-422987	Tibial Resection Guide Shim, Right Medial, Unslotted	2 mm
		32-423230	Tibial Resection Guide Shim, Right Medial, Slotted	2 mm
		32-423231	Tibial Resection Guide Shim, Left Medial, Slotted	2 mm
		32-422990	Tibial Resection Guide Shim, Left Medial, Unslotted	2 mm
		32-423222	Tibial Resection Guide Shim, Left Medial, Slotted	0 mm
		32-422988	Tibial Resection Guide Shim, Left Medial, Unslotted	0 mm
	C	32-423200	Oxford Microplasty Tibial Resection Body Tube	–
	D	32-422778	Oxford Silicone Ankle Strap	–
	E	32-422828	Oxford Sizing Spoon	1 mm
		32-422792		1 mm
		32-422795		1 mm
		32-422798		1 mm
		32-422839		1 mm
		32-423285		2 mm
		32-423286		3 mm
	F	32-422848	Oxford IM Rod Pusher	–

Product	Label	Part Number	Description	Size
	G	32-422777	Ankle Yoke	–
	H	32-422822	Oxford IM Rod Link	–
	I	32-422846 32-422863	Oxford G-Clamp	3 mm 4 mm










Instrumentation



32-423533 Tibial Case 2—Lower Insert Tray


Product	Label	Part Number	Description	Size
		32-423540	Oxford Microplasty Instrument Tray (Tray Only)	–
	A	32-423232	Oxford Anterior Bone Removal Shaft (Outer)	–
	B	32-422984	IM Rod	300 mm
	C	32-422847	IM Rod	200 mm
	D	32-420127	Femoral Impactor	–
	E	32-423233	Oxford Anterior Bone Removal Shaft (Inner)	–
	F	32-423226	Oxford IM Awl	5 mm
	G	32-422760	Toffee Hammer	–
	H	32-423287	Bone Collar Remover	–










Product	Label	Part Number	Description	Size
	I	32-420333	Oxford Spigot	7
		32-420334		6
		32-420335		5
		32-420336		4
		32-420337		3
		32-420338		2
		32-420339		1
		32-420340		0
	J	32-420663	Oxford Shim	1 mm
		32-420664		2 mm
		32-420665		3 mm
	K	32-423227	Oxford Cement Key Drill	–
	L	32-423228	Oxford Quick Release Femoral Drill Bit	4 mm
	M	32-422845	Oxford Quick Release Femoral Drill Bit	6.35 mm
	N	42-411400†	Signature™ Alignment Rod*	–
	O	42-411402†	Oxford Signature Tibial Alignment Checker Left*	–
		42-411403†	Oxford Signature Tibial Alignment Checker Right*	–
	P	42-411420†	Oxford Signature Tibial Drill Guide*	–
	Q	42-411401†	Oxford Signature Femoral Alignment Checker*	–
	-	32-423197 †	Vertical Resection Shim	–

\* Not photographed, not a part of standard set definition





Instrumentation



32-423527 Femoral Instruments — Extra Small

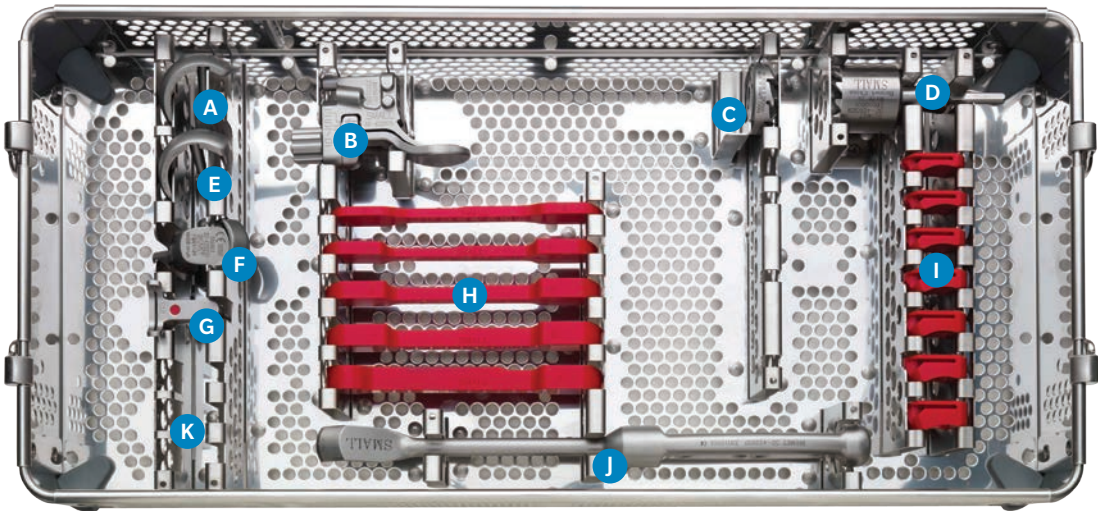
Product	Label	Part Number	Description	Size
		32-423534	Oxford Microplasty Instrument Tray (Tray Only)	–
	A	32-421050	Oxford Single Peg Femoral Trial	Extra Small
	B	32-422974	Oxford Femoral Drill Guide	Extra Small
	C	32-423234	Oxford Anterior Bone Mill	Extra Small
	D	32-421062	Oxford Spherical Mill	Extra Small
	E	32-421430	Oxford Twin Peg Femoral Trial	Extra Small
	F	32-423235	Oxford Anti-impingement Guide	Extra Small
	G	32-422979	Oxford Posterior Cutting Guide	Extra Small










Product	Label	Part Number	Description	Size
	H	32-422766	Oxford Feeler Gauge, Extra Small	1/2 mm
		32-422767		3/4 mm
		32-422768		5/6 mm
		32-422769		7/8 mm
	I	32-422693	Oxford Trial Bearing, Extra Small	3 mm
		32-422694		4 mm
		32-422695		5 mm
		32-422696		6 mm
		32-422697		7 mm
	J	32-422938	Oxford Posterior Osteophyte Chisel	Extra Small
	K	42-411430†	Oxford Signature Drill Guides*	Extra Small
		42-411431†		Small





\* Not photographed, not a part of standard set definition

Instrumentation



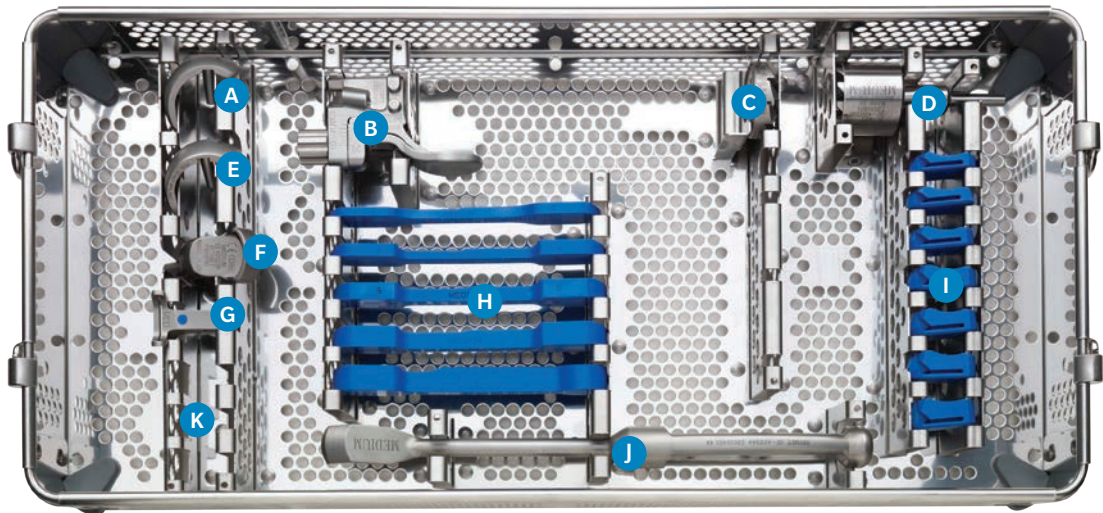
32-423528 Femoral Instruments — Small

Product	Label	Part Number	Description	Size
		32-423535	Oxford Microplasty Instrument Tray (Tray Only)	–
	A	32-420341	Oxford Single Peg Femoral Trial	Small
	B	32-422975	Oxford Femoral Drill Guide	Small
	C	32-423236	Oxford Anterior Bone Mill	Small
	D	32-420329	Oxford Spherical Mill	Small
	E	32-421431	Oxford Twin Peg Femoral Trial	Small
	F	32-423237	Oxford Anti-impingement Guide	Small
	G	32-422980	Oxford Posterior Resection Guide	Small








Product	Label	Part Number	Description	Size
	H	32-422771	Oxford Feeler Gauge, Small	1/2 mm
		32-422801		3/4 mm
		32-422802		5/6 mm
		32-422803		7/8 mm
		32-422804		9 mm
	I	32-422698	Oxford Trial Bearing, Small	3 mm
		32-422699		4 mm
		32-422700		5 mm
		32-422701		6 mm
		32-422702		7 mm
		32-422721		8 mm
		32-422722		9 mm
	J	32-422937	Oxford Posterior Osteophyte Chisel	Small
	K	42-411434 †	Oxford Signature Drill Guides*	Small Downsize
		42-411435 †		Small
		42-411436 †		Small Upsize





\* Not photographed, not a part of standard set definition

Instrumentation




32-423529 Femoral Instruments — Medium

Product	Label	Part Number	Description	Size
		32-423536	Oxford Microplasty Instrument Tray (Tray Only)	–
	A	32-420342	Oxford Single Peg Femoral Trial	Medium
	B	32-422976	Oxford Femoral Drill Guide	Medium
	C	32-423238	Oxford Anterior Bone Mill	Medium
	D	32-420330	Oxford Spherical Mill	Medium
	E	32-421432	Oxford Twin Peg Femoral Trial	Medium
	F	32-423239	Oxford Anti-impingement Guide	Medium
	G	32-422981	Oxford Posterior Cutting Guide	Medium







Product	Label	Part Number	Description	Size
	H	32-422805	Oxford Feeler Gauge, Medium	1/2 mm
		32-422806		3/4 mm
		32-422807		5/6 mm
		32-422808		7/8 mm
		32-422809		9 mm
	I	32-422703	Oxford Trial Bearing, Medium	3 mm
		32-422704		4 mm
		32-422705		5 mm
		32-422706		6 mm
		32-422707		7 mm
		32-422723		8 mm
		32-422724		9 mm
	J	32-422344	Oxford Posterior Osteophyte Chisel	Medium
	K	42-411439 †	Oxford Signature Drill Guides*	Medium Downsize
		42-411440 †		Medium
		42-411441 †		Medium Upsize

\* Not photographed, not a part of standard set definition






Instrumentation



32-423530 Femoral Instruments — Large


Product	Label	Part Number	Description	Size
		32-423537	Oxford Microplasty Instrument Tray (Tray Only)	–
	A	32-420343	Oxford Single Peg Femoral Trial	Large
	B	32-422977	Oxford Femoral Drill Guide	Large
	C	32-423240	Oxford Anterior Bone Mill	Large
	D	32-420331	Oxford Spherical Mill	Large
	E	32-421433	Oxford Twin Peg Femoral Trial	Large
	F	32-423241	Oxford Anti-impingement Guide	Large









Product	Label	Part Number	Description	Size
	G	32-422982	Oxford Posterior Cutting Guide	Large
	H	32-422810 32-422811 32-422812 32-422813 32-422814	Oxford Feeler Gauge, Large	1/2 mm 3/4 mm 5/6 mm 7/8 mm 9 mm
	I	32-422708 32-422709 32-422710 32-422711 32-422712 32-422725 32-422726	Oxford Trial Bearing, Large	3 mm 4 mm 5 mm 6 mm 7 mm 8 mm 9 mm
	J	32-422935	Oxford Posterior Osteophyte Chisel	Large
	K	42-411444 † 42-411445 † 42-411446 †	Oxford Signature Drill Guides*	Large Downsize Large Large Upsize

\* Not photographed, not a part of standard set definition






Instrumentation



32-422759 Femoral Instruments — Extra Large

Product	Label	Part Number	Description	Size
		32-423538	Oxford Microplasty Instrument Tray (Tray Only)	–
	A	32-420344	Oxford Single Peg Femoral Trial	Extra Large
	B	32-422978	Oxford Femoral Drill Guide	Extra Large
	C	32-423242	Oxford Anterior Bone Mill	Extra Large
	D	32-420332	Oxford Spherical Mill	Extra Large
	E	32-421434	Oxford Twin Peg Femoral Trial	Extra Large
	F	32-423243	Oxford Anti-impingement Guide	Extra Large



Product	Label	Part Number	Description	Size
	G	32-422983	Oxford Posterior Cutting Guide	Extra Large
	H	32-422815 32-422816 32-422817 32-422818 32-422819	Oxford Feeler Gauge, Extra Large	1/2 mm 3/4 mm 5/6 mm 7/8 mm 9 mm
	I	32-422713 32-422714 32-422715 32-422716 32-422717 32-422727 32-422728	Oxford Trial Bearing, Extra Large	3 mm 4 mm 5 mm 6 mm 7 mm 8 mm 9 mm
	J	32-422939	Posterior Osteophyte Chisel	Extra Large
	K	42-411449† 42-411450†	Oxford Signature Drill Guides*	Extra Large Downsize Extra Large

\* Not photographed, not a part of standard set definition

## Notes



## References

- Goodfellow, J. *et al.* The Mechanics of the Knee and Prosthesis Design. *The Journal of Bone and Joint Surgery* [Br]. 60-B:358–69, 1978.
- Argenson, J. *et al.* Polyethylene Wear in Meniscal Knee Replacement. A One to Nine-year Retrieval Analysis of the Oxford Knee. *The Journal of Bone and Joint Surgery* [Br]. 74-B:228–32, 1992.
- Psychoyios, V. *et al.* Wear of Congruent Meniscal Bearings in Unicompartamental Knee Arthroplasty—A Retrieval Study of 16 Specimens. *The Journal of Bone and Joint Surgery* [Br]. 80-B:976–82, 1998.
- White, S. *et al.* Anteromedial Osteoarthritis of the Knee. *The Journal of Bone and Joint Surgery* [Br]. 73-B:582–86, 1991.
- Murray, D. *et al.* The Oxford Medial Unicompartamental Arthroplasty, a Ten Year Survival Study. *The Journal of Bone and Joint Surgery* [Br]. 80-B:983–9, 1998.
- Weale, A. *et al.* Does Arthritis Progress in the Retained Compartments after Oxford Medial Unicompartamental Arthroplasty? *Journal of Bone and Joint Surgery* [Br]. 81-B: 783–9, 1999.
- Bankston, A. *et al.* Comparison of Polyethylene Wear in Machined Versus Moulded Polyethylene. *Clinical Orthopaedics and Related Research*. 317:37–43, 1995.
- Kendrick, B. *et al.* Polyethylene Wear of Mobile-bearing Unicompartamental Knee Replacement at 20-years. *The Journal of Bone and Joint Surgery* [Br]. 93-B:470–5, 2010.
- Pandit, H. *et al.* Unicompartamental Knee Replacement for Patients with Partial Thickness Cartilage Loss in the Affected Compartment. *The Knee*. 18(3):168–71, 2011.
- Keyes, G. *et al.* The Radiographic Classification of Medial Gonarthrosis. Correlation with Operation Methods in 200 Knees. *Acta Orthopaedica Scandinavica*. 63 (5):497–501, 1992.
- Gibson, P. *et al.* Stress Radiography in Degenerative Arthritis of the Knee. *The Journal of Bone and Joint Surgery* [Br]. 68-B:608–9, 1986.
- Berend, K. *et al.* Does Preoperative Patellofemoral Joint State Affect Medial Unicompartamental Arthroplasty Survival? AAOS Poster No. P204. February 2011.
- Berend, K. *et al.* Obesity, Young Age, Patellofemoral Disease and Anterior Knee Pain: Identifying the Unicondylar Arthroplasty Patient in the United States. *Orthopedics*. 30(Suppl 5):19–23, 2007.
- Kang, S. *et al.* Pre-operative Patellofemoral Degenerative Changes Do Not Affect the Outcome After Medial Oxford Unicompartamental Knee Replacement. *The Journal of Bone and Joint Surgery* [Br]. 93-B:476–8, 2010.
- Pandit, H. *et al.* Unnecessary Contraindications for Mobile-bearing Unicompartamental Knee Replacement. *The Journal of Bone and Joint Surgery* [Br]. 93-B:622–8, 2011.
- Langdown, AL, *et al.* Oxford Medial Unicompartamental Arthroplasty for Focal Spontaneous Osteonecrosis of the Knee. *Acta Orthop* 2005; 76: 688-92.
- Gunther TV, *et al.* Lateral Compartment Arthroplasty with the Oxford Meniscal Knee. *Knee* 1996; 3:33-39.
- Price, A. J., *et al.* “Rapid recovery after Oxford unicompartamental arthroplasty through a short incision.” *The Journal of arthroplasty* 16.8 (2001): 970-976.
- Pandit, H *et al.* Cementless Oxford unicompartamental knee replacement shows reduced radiolucency at one year. *JBJS (Br.)* Vol. 91-B, No.2. February 2009.
- Pandit, *et al.* Improved Fixation in Cementless Unicompartamental Knee Replacement. Five Year Results of a RCT. *J Bone Joint Surg Am.* 2013;95:1365-72
- Tibrewal, S. *et al.* The Radiolucent Line Beneath the Tibial Components of the Oxford Meniscal Knee. *The Journal of Bone and Joint Surgery*. 66-B:523–8, 1984.
- Svärd, U. C. G., and A. J. Price. “Oxford medial unicompartamental knee arthroplasty a survival analysis of an independent series.” *Journal of Bone & Joint Surgery, British Volume* 83.2 (2001): 191-194.
- Fawzy, E, *et al.* Determination of femoral component size in unicompartamental knee replacement. *The Knee* 15 (2008) 403–406.

† (cross symbol) Items supplied by Biomet Orthopedics

\*\* Devices supplied by third-party manufacturers

Zimmer Biomet does not practice medicine. This technique was developed in conjunction with health care professionals. This document is intended for surgeons and is not intended for laypersons. Each surgeon should exercise his or her own independent judgment in the diagnosis and treatment of an individual patient, and this information does not purport to replace the comprehensive training surgeons have received. As with all surgical procedures, the technique used in each case will depend on the surgeon's medical judgment as the best treatment for each patient. Results will vary based on health, weight, activity and other variables. Not all patients are candidates for this product and/or procedure.

All content herein is protected by copyright, trademarks and other intellectual property rights, as applicable, owned by or licensed to Zimmer Biomet or affiliates unless otherwise indicated, and must not be redistributed, duplicated or disclosed, in whole or in part, without the express written consent of Zimmer Biomet.

This material is intended for health care professionals, Zimmer Biomet employees and the Zimmer Biomet sales force. Distribution to any other recipient is prohibited.

Check for country product clearances and reference product specific instructions for use.

Not intended for use in the United States. Not intended for surgeons practicing medicine in France.

For indications, contraindications, warnings, precautions, potential adverse effects and patient counseling information, see the package insert or contact your local representative; visit [www.zimmerbiomet.com](http://www.zimmerbiomet.com) for additional product information.

©2021 Zimmer Biomet



0338.2-OUS-en-Issue Date 2021-10-05



**Legal Manufacturer**  
Biomet Orthopedics  
56 East Bell Drive  
P.O. Box 587  
Warsaw  
IN 46581  
USA



**Legal Manufacturer**  
Biomet UK Limited  
Waterton Industrial Estate,  
Bridgend  
CF31 3XA  
UK



CE mark on a surgical technique is not valid unless there is a CE mark on the product label.



**Authorized Representative**  
Netherland GSCC  
Biomet GSCC B.V.  
Hazeldonk 6530  
4836 LD Breda  
The Netherlands

[www.zimmerbiomet.com](http://www.zimmerbiomet.com)  
[www.oxfordpartialknee.net](http://www.oxfordpartialknee.net)