



## Veterinary Specialists of Alaska, P.C. Client Information Sheet: General Information on Fracture Repair

### **Fracture Repair – General Information for Animal Owners**

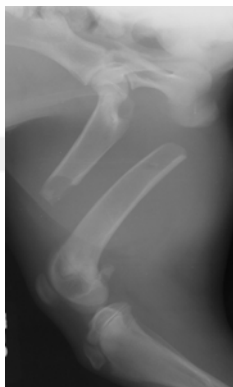Dirsko J.F. von Pfeil, Dr.med.vet., DVM, DACVS, DECVS; Mike Edwards, DVM, MS, DACVS

Unfortunately, fractures occur commonly in dogs and cats. Appropriate repair of these fractures is essential for return to function and to an active, pain free life. Fracture repair is a significant portion of the specialized training that board certified surgeons receive during residency training. The surgeons at Veterinary Specialists of Alaska are highly trained in all methods of fracture repair and have access to a vast inventory of specialized equipment and implants. We can provide your pet with state of the art treatment and with the best chance possible for a return to normal function.

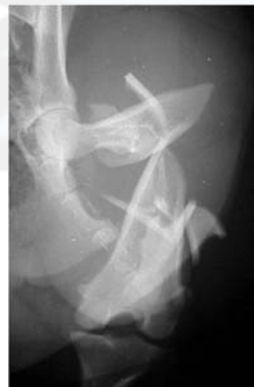Most fractures are the result of trauma, such as being hit by a car, falling from a height, being stepped on, or from a fight. Some fractures occur as a result of relatively minor trauma. In these cases, the bone is abnormally weak due to underlying disease processes such as cancer, hyperparathyroidism, or severe nutritional imbalances.

Fractures are described and classified depending on a variety of factors, including the location of the fracture within the bone, the number of fragments present, and whether the skin over the fracture is intact or not. Fractures in young animals are classified separately. Fractures are divided into several subcategories. The area of the bone where the fracture occurs is important, as it determines how much healthy bone the surgeon has to work with. Midshaft fractures are well suited to repair with bone plates as plenty of bone is available on either side of the fracture for screw placement. Fractures occurring close to, or extending into, a joint are more challenging to repair and require more expertise for a successful outcome. When a bone breaks into two pieces the fracture is described as a “simple fracture”. When there are several pieces, it is a “comminuted fracture”. The fracture line is also used to describe a fracture: It can be oblique, transverse, or spiral. It is important to determine if the skin over the fracture is intact. In most cases the skin is intact. This is known as a closed fracture. If the skin is open it is considered an open fracture. Open fractures can be severely contaminated. Proper management of these injuries is essential in order to achieve an acceptable outcome.

In young, growing animals, there is a zone of cartilage near each end of each long bone. This zone of cartilage is where growth occurs and is referred to as a growth plate. Growth plates are inherently weak, relative to the surrounding bone. Consequently, fractures in young, growing animals often occur at, or through, the growth plates. These fractures are referred to as Salter-Harris fractures and are categorized according to the configuration of the fracture). Surgical repair of Salter-Harris fractures is covered separately.



Simple fracture



Comminuted fracture



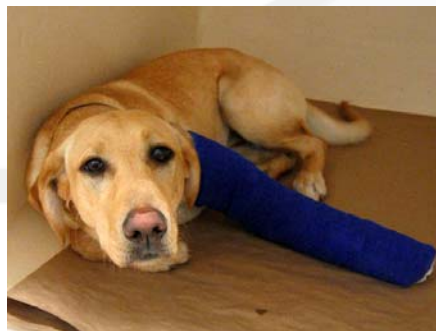## Veterinary Specialists of Alaska, P.C. Client Information Sheet: General Information on Fracture Repair

Most patients with fractures have suffered significant trauma. Consequently, it is imperative that these patients are thoroughly evaluated to ensure that they are free of potentially life-threatening injuries. For example, when a dog is hit by a car, there may be damage to the lungs, urinary bladder, or the vertebral column (back bone). In addition to a thorough physical examination, radiographs (x-rays) of the chest and belly, laboratory tests, an electrocardiogram (ECG), and a complete neurological examination may be indicated prior to anesthesia for fracture repair. In many cases, fracture repair is postponed to allow resolution of more life-threatening problems.

### **Fracture repair options**

Fracture repair is performed once the animal is stable enough to undergo anesthesia safely. Depending on the specific fracture, various stabilization methods are available. Your surgeon will explain the various repair options appropriate for your pet and will make recommendations based on thorough consideration of all factors. It is important to realize that stabilization of the fracture is only the first step in a long process. Proper postoperative care is essential in order to achieve a successful outcome. Your surgeon, and the hospital staff at Veterinary Specialists of Alaska P.C. will make specific recommendations for the postoperative management and care of your pet. Please follow these instructions closely and be sure to call us if you have questions or concerns. The following paragraphs will explain some of the most common methods of fracture fixation.

**External Coaptation** (splint or cast): In some cases, the bone is only cracked. This is referred to as a fissure or greenstick fracture. Many patients with greenstick fractures can be successfully treated with a cast or splint. Some patients suffer complete fractures, however, the fragments remain in place. Many of these patients, especially very young or very small patients can be successfully treated with a cast or splint. Fractures of the metacarpal or metatarsal bones (long bones of the feet) often can be treated in this fashion. A cast is first applied by wrapping the leg with cast padding. Fiberglass cast material is then wrapped around the padded leg. In some cases a splint is applied, rather than a cast. With splinting, the leg is padded the same as for a cast. The difference is that a splint is typically applied to one surface of the leg, rather than being wrapped around it. Splints can be made of fiberglass, moldable plastic, or aluminum rods. The cast or splint should extend above the joint above the fracture and down to the toes. Pressure sores are a common complication associated with external coaptation. If the cast slips or is chewed by the patient, it can act like a fulcrum and actually apply more stress on the fracture. In some cases, the bandage can act like a tourniquet and create severe complications. Consequently, animals with casts or splints require constant close supervision.



Patients with casts or splints should return to the hospital at least once weekly for evaluation by your surgeon.



## Veterinary Specialists of Alaska, P.C. Client Information Sheet: General Information on Fracture Repair

**Intramedullary (IM) Pin:** An intramedullary pin is a stainless steel pin introduced into the medullary cavity of a long bone and utilized to stabilize a fracture. IM pinning is one of the oldest forms of fracture fixation in use today. These pins can be applied through a limited approach, require minimal specialized training to apply, and are very inexpensive. They provide excellent resistance to bending forces and to shear forces. They do not neutralize compression, rotation, or distraction forces. There is a high complication rate associated with the use of IM pins as the sole form of fixation. Consequently IM pins usually are used in conjunction with cerclage wire, bone plates, or an external fixator. IM pins alone, have limited application in veterinary medicine. Because of the high complication rate and the high failure rate associated with IM pins, we typically recommend alternative forms of fracture fixation. However, the surgeons at Veterinary Specialists of Alaska, P.C. are well versed in the correct application of IM pins and can determine if this form of repair is appropriate for your pet.

**Bone plate:** Bone plating has been shown to be an extremely effective means of fracture repair. The potential forces acting on the bone at the fracture site include bending, rotation, compression, shear, and tension. Properly applied bone plates are capable of counteracting all these forces thus ensuring a very stable fracture repair. A stable repair increases the likelihood of uncomplicated bone healing and a successful outcome. In the traditional form of plating for fracture repair, the bone fragments are exposed through an open approach. The fragments are then reduced (put back in place) and held together with a combination of bone holding forceps and wires while a plate is contoured to match the shape of the bone. The plate is then applied to the surface of the bone and secured with screws. In some cases the configuration of the fracture prevents placement of screws in certain locations. Cerclage wire can be used to stabilize these regions of bone. Thorough knowledge of the regional anatomy is crucial to a successful outcome. Care must be taken to avoid damage to local nerves and major blood vessels. Care must also be taken to avoid unnecessary damage to the surrounding musculature. Consequently, the surgeon must be well trained in the approach to the affected bone. The plate must be accurately contoured to match the shape of the bone and it must be applied to the proper surface of the bone in order to effectively neutralize the forces acting on the fracture site. Bone plates are usually left in the patient unless problems occur. Some patients experience discomfort during cold weather after bone plate application. In these cases, or if a plate becomes loose, or there appears to be infection, we recommend removal of the bone plate after the fracture is adequately healed. In very young dogs it may be beneficial to remove a bone plate once bone healing has occurred. One disadvantage to bone plate application using the traditional approach is that it usually requires an extensive approach for exposure of the fracture site. Creating this approach compromises blood supply to the region and may slow bone healing. In select cases, it may be possible to reduce the fracture and apply a bone plate or screws and wires using a minimally invasive approach. This is accomplished through the use of a video style X-ray unit (fluoroscope) and other specialized equipment. We currently utilize these techniques wherever possible. Bone plating in a minimally invasive manner preserves the soft tissues around the injured bone, and has been shown to provide faster healing than traditional plating. As with any type of fracture repair, bone plate application can be technically demanding. The surgeons at Veterinary Specialists of Alaska, P.C. are highly experienced and have been specifically trained in this technique.

**Bone plate and rod combination:** Severely comminuted fractures are often treated with a combination of bone plate and rod. In some severely comminuted fractures, small fragments are present which can not be effectively reduced and incorporated into the fracture repair. Excessive manipulation of these fragments results in unnecessary compromise of blood supply. In cases like this, it is preferable to minimize manipulation of the fragments. These fractures can be treated with a combination of an intramedullary pin and a bone plate.



## Veterinary Specialists of Alaska, P.C. Client Information Sheet: General Information on Fracture Repair

The pin is used to align the proximal and distal fragments of the bone and to provide resistance to bending forces acting on the fracture site. A bone plate is then contoured to the shape of the proximal and distal fragments and is secured with screws to the major fragments. Biomechanical studies have shown that this technique provides a significant increase in strength of the repair. When using this method of repair, manipulation of the fragments is avoided. The blood supply is minimally disrupted in most cases, thus resulting in earlier callus (healing bone tissue) formation, and earlier healing than may otherwise occur. This technique is most commonly utilized on fractures of the femur. The femur is the bone between the hip and the knee. This technique is most appropriate for fractures involving a significant portion of bone. One challenge inherent in the treatment of this particular type of fracture is to accurately align the hip and the knee and to restore the leg to an acceptable length. This can be extremely challenging when a significant portion of the bone can not be reconstructed. The surgeons at Veterinary Specialists of Alaska, P.C. have had extensive training and experience with this technique.

External fixator: An external fixator consists of several pins driven through the skin, into the bone, and sometimes exiting on the other side of the leg. The ends of the pins, protruding out of the skin, are connected by a series of clamps to a side bar or ring. An external fixator is applied to a fracture when there is a large open soft-tissue wound in concurrence with the fracture, or if there is severe comminution, which cannot be reconstructed. External fixators can be applied to a variety of fractures. They are probably most appropriate for open fractures because they can be applied without spreading the contamination further. Similarly, since they can often be applied without exposing the affected bone, the healing process is not interrupted and may progress more rapidly. Some surgeons prefer external fixation over bone plate application because it does not require shaping the implant to match the shape of the bone. The external fixator is removed after the fracture has healed. External fixators can also be applied across joints. This means that they can be used to treat fractures present in the joint or to provide additional support for joint fractures stabilized with pins and screws. The main disadvantage to an external fixator is the fact that your pet will have a bulky, metallic apparatus present on his or her leg for at least 8 weeks. This apparatus can injure other pets or people in your house and can damage furniture. There is the potential for the device to get caught on furniture and vegetation. The potential exists for contamination of the pin tracts from environmental sources. Drainage from the pin tracts is a common occurrence. Careful attention to detail during application and postoperative care is necessary in order to maximize the potential for an excellent outcome. If your pet is treated by external fixation, your surgeon will most likely recommend re-evaluation here at least once a week. These rechecks will allow us to evaluate the progress your pet is making toward healing and to assess integrity of the fixator. Occasionally, it is necessary to tighten clamps, remove pins, or add pins. The surgeons at Veterinary Specialists of Alaska, P.C. are well trained in the application and maintenance of external fixators.

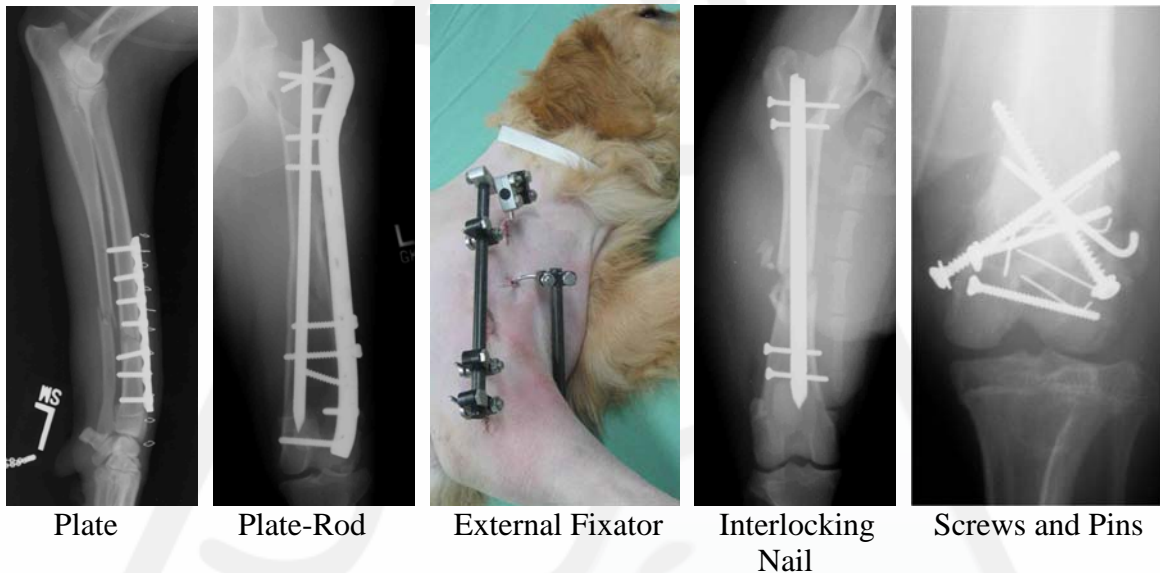
Interlocking nail: An interlocking nail is a form of intramedullary pin that accommodates screws in each end. These screws are intended to lock the pin in place and to allow resistance to compression and rotation. The advantages of interlocking nails are that they can be applied through small incisions. Thus, this method of repair is less invasive and more cosmetic, compared to a traditional open approach. Some reports show that healing occurs more rapidly than with other implants. This is most likely because the surgical procedure is less invasive. However, biomechanical studies have shown that some of the repaired fractures in animals may be exposed to too much motion after implantation of an interlocking nail, thus leading to a decreased amount of healing. Occasionally, additional stabilization may need to be provided, such as an external fixator. To date, there is no interlocking nail system available on the veterinary market, which is practical and shows a high applicability,



## Veterinary Specialists of Alaska, P.C. Client Information Sheet: General Information on Fracture Repair

and which has shown consistently good results. Therefore interlocking nails are not currently utilized at Veterinary Specialists of Alaska.

Screws, pins, and wires: Some fractures, especially those near joints, create fragments too small to accommodate a bone plate or external fixator. In these cases the small fragments can be stabilized with implants such as cerclage wire, screws or pins. Cerclage wire is stainless steel, surgical grade wire that is used to encircle bone and stabilize a fracture. Kirschner –wires (K-wires) are small, typically smooth, pins that can be used to secure small bone fragments. In many cases a combination of screws, pins, wires and bone plates are used to stabilize a fracture.



### Postsurgical care after fracture repair

After surgery it is important to limit your pet's activity in order to maximize the likelihood of proper healing. In most cases bone healing occurs within 6-8 weeks. This is the average time required for bones to heal in a mature, healthy animal. There is nothing we can do to speed this process up. However, a number of things can slow it down. If your pet is too active during the postoperative period, the surgical implants may loosen. This will create motion at the fracture site and will delay bone healing. If the fracture was open and contaminated or infected, bone healing will be delayed. Older patients exhibit slower bone healing. Highly comminuted fractures and fractures with gaps between the fragments require longer to heal. It is important that your pet be confined inside the house during this healing period. He/she should be separated from other pets and should not be allowed to run, jump, play or roughhouse during this time. Short leash walks, for bathroom breaks only, are allowed. Your surgeon will explain to you in detail what the best post operative activity level for your pet will be at the time of discharge from the hospital.

The incision should be inspected twice daily for excessive redness, pain, swelling, odor, or discharge. Please contact either VSOA or your regular veterinarian if you notice any of these signs.

The first three days after surgery, cold compresses should be applied to the surgical site. This will help to reduce the post-surgical inflammation. A clean and dry cotton cloth is placed over the incision, and an ice bag is applied to the area for 5-10 minutes, if possible three times daily.



## Veterinary Specialists of Alaska, P.C. Client Information Sheet: General Information on Fracture Repair

During days three to five a warm pack can be applied in a similar manner. Fill a stockinet with dry rice grains, put the pack into the microwave to heat it up until it is “hand-warm”, and then apply this pack to the surgical site for 5-10 minutes. This will help to increase the blood supply to the area, which in turn results in faster healing.

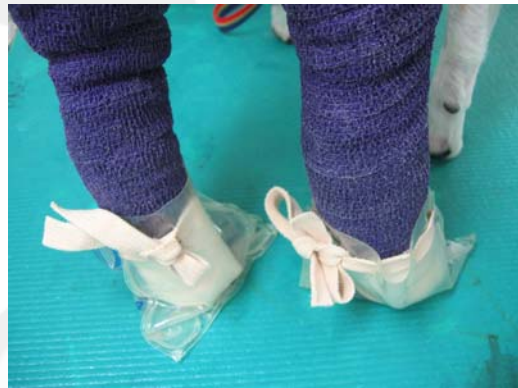Bandage care is imperative to prevent problems during the recovery period. The bandage must be kept dry and clean. Place a sturdy plastic bag over the bandage when going outside, and remove it when back inside. Do not allow your pet to step into a water puddle. Do not allow your pet to lick or chew on the bandage. The bandage material works like a wick in an oil-lamp, and any moisture that is apparent on one end of the bandage, is likely to move up on the inside of the bandage, possibly leading to skin infection. Please contact us immediately if the bandage becomes wet, loose, or damaged. Even if there is no damage to the bandage, frequent bandage changes may be necessary to minimize the risk of complications, such as pressure sores underneath the bandage.



Check the toes for swelling 2x/day

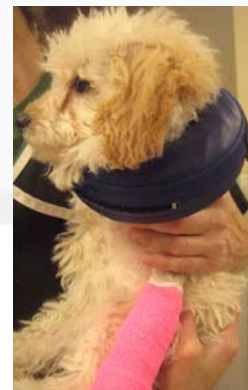
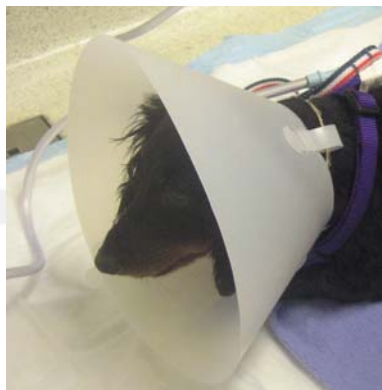
Keep bandage dry



Protect bandage when going outside

An Elizabethan collar is used to prevent the animal from licking or chewing the bandage or incision. Contact us if your pet does not tolerate the Elizabethan collar. We can make suggestions for alternative forms of restraint for your pet. It is, however, important to prevent licking or chewing the bandage or incision line.



An Elizabethan or similar collar has to be on for at least two weeks. It is used to prevent the animal from licking the incision or bandage. Licking or chewing at the surgical site may lead to severe complications.



## Veterinary Specialists of Alaska, P.C. Client Information Sheet: General Information on Fracture Repair

Staples or skin stitches typically are removed at the 2-week recheck. In some cases, the incision is closed with absorbable suture, which is placed underneath the skin surface. These sutures do not need to be removed. In some cases the suture knots buried under the skin create small bumps which you will be able to feel. These will resolve over time.

Follow up radiographs (x-rays) are taken in most cases after 8 weeks. In young animals, or with specific fracture types, this may be done earlier. At that time bone healing is evaluated, and a plan will be created for rehabilitation to ensure the best outcome possible. If the fracture remains unhealed, we will recommend an additional 4 weeks of activity restriction and radiographs will be repeated.

After the surgery: As indicated above, fracture repair is only the first step on the road to recovery. During the postoperative period, it is important to work closely with the surgeons at Veterinary Specialists of Alaska and with your regular veterinarian. This will help reduce the risk of a complication. Even more importantly, it may allow early detection of a potential complication. Typically speaking, it is easier to address a complication if it is detected early.

We hope that this information pamphlet was helpful to help you understand more about fracture treatment in small animal surgery. Please do not hesitate to call or ask at your next appointment if you have any questions or concerns.

Your VSOAK Team