



## CASE STUDY: OZZIE THE MAINE COON'S INTESTINAL FOREIGN BODY REMOVAL



### PATIENT OVERVIEW

- **Patient:** Ozzie
- **Breed:** Maine Coon
- **Presenting Complaint:** Vomiting for 24 hours
- **Age/Sex:** Not specified

### PRESENTATION AND DIAGNOSIS

Ozzie, a charming and photogenic Maine Coon, presented to the emergency service with a 24-hour history of persistent vomiting. **Dr. Laura Lowe** performed abdominal radiographs, revealing a small, round object within the intestines, suspicious for a gastrointestinal foreign body.

### STABILIZATION & INITIAL SURGERY

Ozzie was hospitalized overnight and stabilized on intravenous fluids. The following morning, surgical veterinarian **Dr. Kara Berke** ordered an abdominal ultrasound, confirming the object was fully obstructive and unlikely to pass naturally. Ozzie was then transferred to surgeon **Dr. Patti Sura**, who performed an enterotomy to remove the small metal object. The procedure was successful, and Ozzie was discharged the next day.

### COMPLICATIONS

A couple of weeks later, Ozzie developed severe complications. He returned with signs consistent with a septic abdomen, requiring emergency re-admission. Further investigation revealed that his previous intestinal surgical site had developed an adhesion to his body wall, leading to a muscular abscess.

### SECOND EMERGENCY SURGERY

**Dr. Patti Sura** performed a second surgery, which included:

- Resection of the affected intestinal segment
- Debridement of infected tissue
- Placement of a surgical drain to promote healing and clear infection

This additional procedure was critical in resolving Ozzie's infection and preventing further systemic illness.

### OUTCOME

Thanks to prompt recognition of complications and decisive surgical care, Ozzie recovered well from his second operation. His dedicated medical team and attentive family ensured he received the intensive monitoring and treatment needed for a successful outcome.

### LESSONS LEARNED

Ozzie's journey underscores the importance of:

- **Close post-surgical monitoring:** Complications can arise unexpectedly, even after a seemingly routine recovery.
- **Rapid intervention in emergencies:** A fast return to the hospital allowed for life-saving treatment.
- **Team communication and continuity of care:** From diagnostics to multiple surgeries, collaboration between specialists was key to his survival.



(843) 614-8387



charlestonvrc.com



3484 Shelby Ray Court,  
Charleston, SC, 29414

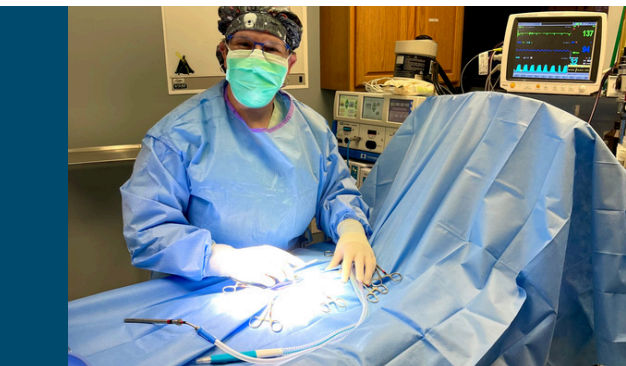

## LIFE AFTER SURGERY

Today, Ozzie is back to his normal routine, lounging in his cat tree, sipping his beloved “catppuccinos,” and charming his many fans online. His resilience and larger-than-life personality continue to inspire.



OSZIE WITH DR. PATTI SUR.



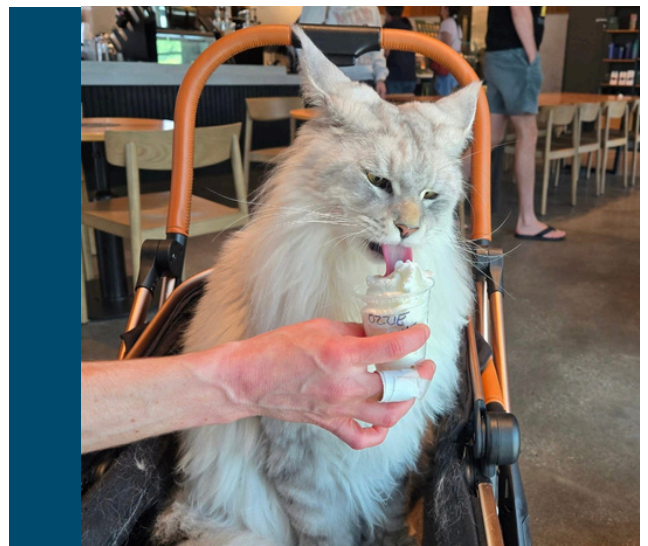
DR. SUR PERFORMING SURGERY ON OSZIE



OSZIE WITH DR. KARA BERKE




OSZIE WAS WELL LOVED BY OUR TEAM AT CVRC!



OSZIE ENJOYING HIS RECOVERY “CATPUCCHINO”

## VETERINARY TEAM ACKNOWLEDGMENTS

- Dr. Laura Lowe – CVRC Emergency Department
- Dr. Kara Berke – CVRC Surgical Services
- Dr. Patti Sura - CVRC Surgical Services



## Ozzie the Maine Coon

497 likes • 747 followers

## FOLLOW OSZIE'S ADVENTURES!

Follow **Ozzie the Maine Coon** on Facebook to keep up with his daily adventures, fluffy photoshoots, and life as a very pampered feline. His journey from ER patient to social media sensation is one you won't want to miss!