

Advanced Diagnostic Approaches and Current Management of Thyroid Pathologies in Guinea Pigs

Jörg Mayer, DMV, MSc, DABVP (ECM)^{a,*}, Robert Wagner, DVM, PhD, DECVDI^b, Olivier Taeymans, VMD, DABVP-Exotics^a

KEYWORDS

- Thyroid pathologies • Hyperthyroidism
- Hypothyroidism • Guinea pig

Primary pathology of the thyroid in the guinea pig was described in the literature more than 40 years ago.^{1,2} Recently, a relatively high incidence of thyroid pathology in guinea pigs has been reported.³ The relative prevalence was reported to be 4.6% at one pathology facility, making thyroid pathology the second most commonly reported after lymphoma (Garner, personal communication, 2006); however, there is no scientific report that describes the clinical case of a confirmed hyperthyroid state of a guinea pig in the English literature. Contrary to this observation, the German literature states that hyperthyroidism is a relatively commonly observed clinical presentation in guinea pigs.⁴ This might be attributable to several factors. One observation is that hyperthyroidism is not currently listed as a disease in the major clinical textbooks dealing with exotic companion mammals and clinicians might not include the condition in the differential diagnosis list when confronted with an animal that displays typical signs. Until very recently, there was no good clinical resource that provided validated reference values for thyroid hormone levels in the guinea pig and clinicians had problems interpreting the results of a hormone profile if it was run. In addition, surgery to remove the affected gland or to take a biopsy of the affected tissue is relatively difficult; therefore, there is no fast or easy diagnostic process.

The authors have encountered multiple clinical cases of clinical hyperthyroidism in the guinea pig, which responded positively to clinical treatment. Hyperactive thyroids

^a Department of Clinical Sciences, Tufts University Cummings School of Veterinary Medicine, 200 Westboro Road North Grafton, MA 01536, USA

^b Division of Laboratory Animal Resources, University of Pittsburgh, S 1049 Biomedical Science Tower, 200 Lothrop Street, Pittsburgh, PA 15261, USA

* Corresponding author.

E-mail address: joerg.mayer@tufts.edu

in the guinea pig appear to exist causing typical clinical signs. An early accurate diagnosis of this pathologic state is important in the clinical setting. One of the authors (R.W.) has encountered a few clinical cases of hypothyroidism in guinea pigs. Hypothyroidism appears to be a rare condition and has been described anecdotally in the German literature.⁴ Because of the rarity of hypothyroidism, the text focuses mainly on the guinea pig as a hyperthyroid case. A short description of the clinical presentation of the hypothyroid animal is included at the end of the text.

THE TYPICAL CLINICAL PRESENTATION

It appears that hyperthyroidism can affect guinea pigs of all ages. Most reported cases are in guinea pigs older than 3 years. It has been reported that the prevalence of thyroid pathology can reach up to 30% in some groups of guinea pigs after 3 years of age.⁵ Thyroid hyperplasia, adenoma, and carcinoma all have been responsible for clinical problems; unfortunately, the exact numbers of the distribution of malignant versus benign lesions are not known and further research is needed to link the pathologic and clinical findings. In the authors' experiences, there may be a slight predilection for females but statistical confirmation of any gender predilection is lacking. In the dog it is common that clinically detectable thyroid neoplasias represent mostly carcinomas and less frequently adenomas.⁶ A relatively high incidence for carcinomas in the guinea pig was also observed in a recent review of thyroid pathology in the guinea pig. It was found that approximately 55% of thyroid neoplasms of the guinea pig were adenocarcinomas.⁷ Further studies are needed to determine if the hyperthyroid guinea pig patient behaves more like the cat or the dog in regard to the distribution of carcinoma versus adenoma and functional pathology versus nonfunctional enlargement of the thyroid gland.

TYPICAL CLINICAL SIGNS

In reviewing multiple cases, clinical signs vary significantly; however, some changes are consistently found and can be considered key clinical signs. These include hyperactivity and hyperesthesia combined with the observation that the animals often are polyphagic but appear thin or are losing weight. Other common but inconsistent clinical findings include diarrhea or soft stool, polyuria/polydipsia, and a palpable mass in the neck. Progressive alopecia has also been reported (**Fig. 1**).⁴ Occasionally, the

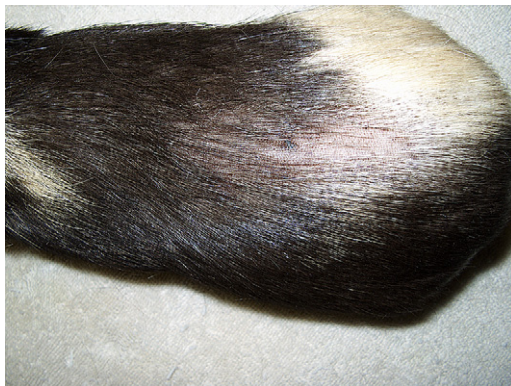

Fig. 1. A guinea pig with confirmed hyperthyroidism, note the alopecia over the dorsum.

patient has tachycardia and should be examined for cardiovascular abnormalities. In a recent review of the pathology of the thyroid gland in guinea pigs, the most common co-condition was pulmonary congestion, followed by atrophy of fat.⁷

DIAGNOSIS

The diagnosis of this condition can be difficult, as results from various diagnostic tests can often be inconclusive. In guinea pigs, the T4 and T3 blood concentrations can be unreliable for both disease diagnosis and treatment monitoring. It is possible to encounter an animal with severe clinical signs without significant elevations in T4/T3 levels. As a baseline for normal values, recently published material on serum thyroxine concentrations in clinically healthy pet guinea pigs is now available,⁸ making the diagnosis a bit easier. The investigators concluded that normal thyroxine concentrations in the healthy guinea pig ranged from 14.2 to 66.9 nmol/L (1.1–5.2 mg/dL) with a median value of 27.0 nmol/L (2.1 mg/dL) (**Tables 1** and **2**). If a swelling of the neck is noted during the physical examination, a fine-needle aspirate with cytologic evaluation can aid in the diagnosis of thyroid tumor but it cannot assess endocrine activity. One author (R.W.) found that fluid aspirated from the neck mass often reveals extremely high T4 concentrations and correlates well with systemic T4 elevation (**Fig. 2**). In rare cases in which T4/T3 levels fall below expected normal values, keep in mind that advanced stages of hypothyroidism can mimic hyperthyroidism as mentioned later in the text.

DIAGNOSTIC IMAGING

In human medicine the thyroid imaging approach is based on the preliminary clinical evaluation. If lesions are smaller than 2 cm it is recommended that lesions are evaluated by ultrasound (US), if possible in combination with a US-guided fine-needle aspirate for cytology (**Fig. 3**). More advanced imaging, such as computed tomography (CT) and magnetic resonance imaging (MRI), is not routine and is more restricted to specific indications such as the evaluation of the extent of substernal goiters, characterization of large neck masses, estimation of local invasiveness of thyroid carcinomas, and detection of local and distant metastases.⁶

In cats, nuclear medicine is considered the imaging modality of choice in the diagnosis and treatment of hyperthyroidism. A benefit of this technique in cases of neoplasia is the potential to detect local and distant metastases. Most thyroid tumors in dogs, however, are not hypersecreting thyroid hormones and therefore do not result in increased radiopharmaceutical uptake of the radioisotope as compared with cats.^{9–11} The use of nuclear medicine in cases of canine primary hypothyroidism remains controversial, as false negative results and variation in normal uptake have been reported.^{6,11–14} A benefit of this technique in cases of neoplasia is the potential

Table 1

Gender-specific values for thyroid hormone in the guinea pig (n = 6)²⁸

T4 male: 2.9 ± 0.6 µg/dL	T3 male: 39 ± 17 ng/dL
T4 female: 3.2 ± 0.7 µg/dL	T3 female: 44 ± 10 ng/dL
Free T4 male: 1.26 ± 0.41 ng/dL	Free T3 male: 257 ± 35 pg/dL
Free T4 female: 1.33 ± 0.25 ng/dL	Free T3 female: 260 ± 59 pg/dL

Data from Castro MI, Alex S, Young RA, et al. Total and free serum thyroid hormone concentrations in fetal and adult pregnant and nonpregnant guinea pigs. *Endocrinology* 1986;118(2):533–7.

Sex	N	Thyroxine ($\mu\text{g/dL}$)		
		Median	Minimum	Maximum
Females	16	2	1.1	5
Males	16	2.2	1.1	4.5
Castrated male	8	2.7	1.5	5.2
All animals	40	2.1	1.1	5.2

Data from Müller K, Müller E, Klein R, et al. Serum thyroxine concentrations in clinically healthy pet guinea pigs (*Cavia porcellus*). *Vet Clin Pathol* 2009; 38:507–10.

to detect local and distant metastases. Although the availability of testing equipment and of this diagnostic test are not widespread, the interested clinician should try to locate a local veterinary or human medical facility that is equipped with a gamma camera.

Hyperactive thyroid tissue and potential metastatic tissue were demonstrated in a guinea pig using nuclear scintigraphy. In this case, diagnostic images were obtained 60 to 80 minutes after injection (Fig. 4).¹⁵ The role of thyroid scintigraphy as a specific tool for the identification of hyperthyroidism in guinea pigs still has to be determined; however, it appears that it is one of the most precise diagnostic tools to document the function of a potentially abnormal thyroid gland.

As an alternative choice of imaging, an ultrasound examination of the thyroid can be performed to detect any anatomic changes in the gland. Because of its very superficial location, high-frequency transducers of at least 10 MHz should be used to examine the thyroid gland (see Fig. 4). The location of the thyroid gland in the guinea pig has been reported to be at a significantly different location than in the dog or cat. According to the anatomic drawings by Popesko and Rajtova,¹⁶ the gland is located between the rami mandibulae and is therefore located significantly more cranially than when compared with other species (Fig. 5A). In the clinical setting, however, a nodule in the neck is often palpated where one would expect the thyroid in other species.

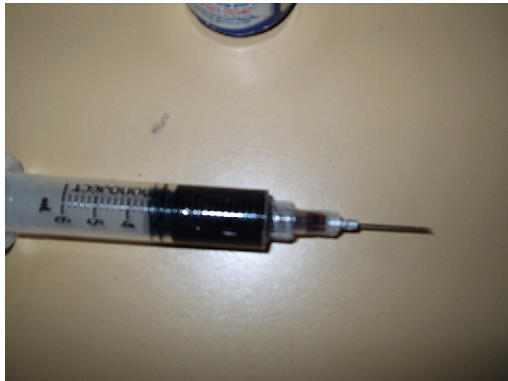

Fig. 2. Fluid aspirated from a swelling on the ventral neck in a guinea pig with typical clinical signs of hyperthyroidism.

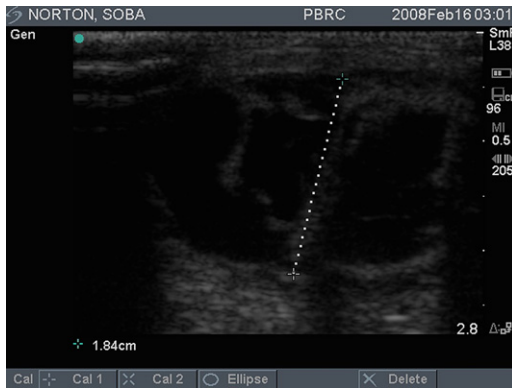


Fig. 3. An ultrasound examination of the thyroid gland in the guinea pig, note the cystic compartment.

A thorough anatomic review with histologic analysis will be required to confirm anatomic location of the gland. Please refer to **Fig. 5, B and C**, as examples of the anatomic location of a confirmed thyroid tumor in a guinea pig.

Analogous to dogs, carcinoma in the guinea pig may potentially benefit from an MRI study. This imaging technique has the potential to better define local tissue invasion, as it has a higher contrast resolution than US. This technique is also not hampered by gas when trying to visualize tissue invasion dorsal to the trachea and is less operator dependant than US.¹⁷

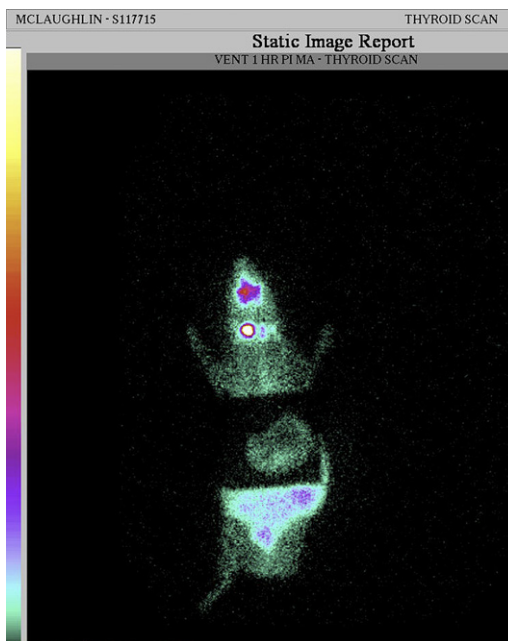


Fig. 4. A ventral color scintigram of the abnormal guinea pig taken 60 minutes after administration of the radiopharmaceutical illustrates a subjectively increased pattern of uptake of the right thyroid.

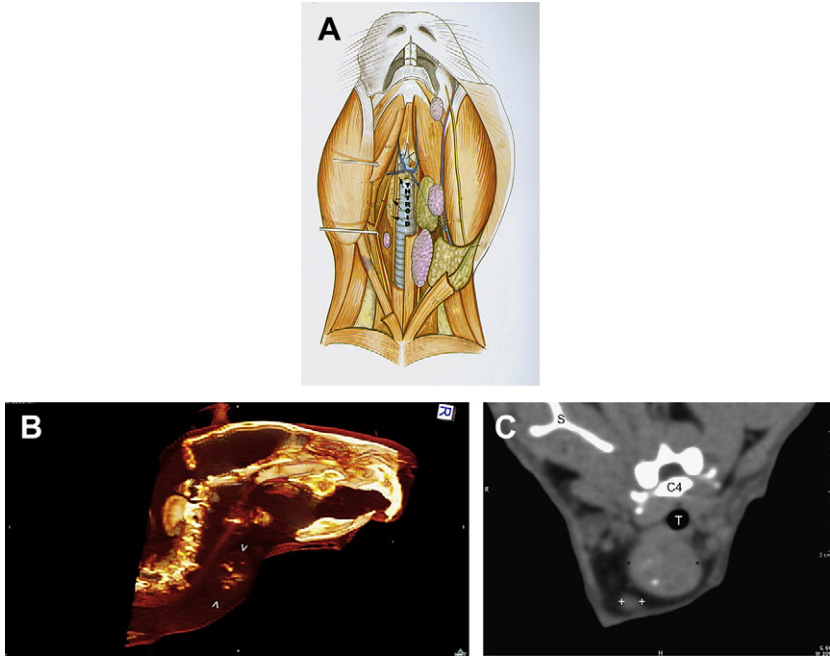


Fig. 5. (A) An anatomic sketch of the location of the thyroid in the guinea pig, note the rostral location of the gland when compared with other species. (B) Three-dimensional maximum intensity projection (3D-MIP) reconstructed CT image showing the enlarged left thyroid lobe of the same guinea pig as in Fig. 4. The left thyroid lobe (between white arrowheads) is moderately enlarged and shows multiple central areas of mineralization. (C) Transverse CT image of the thyroid gland of the same guinea pig as in Figs. 4 and 5B displayed in a soft tissue window. The left thyroid lobe (between black asterisks) is moderately enlarged and shows multiple central areas of mineralization. The right thyroid lobe (between white plus signs), is unremarkable. C4, fourth cervical vertebra; S, right scapula; T, trachea.

CT could also have a potential benefit, as thyroid tissue is expected to be hyperattenuating because of the presence of iodine (high atomic number) and therefore should result in easy detection of normal thyroid tissue. CT also has the advantage to be simultaneously able to look for pulmonary metastatic disease¹⁷ (Fig. 5B, C).

However, if no access to specialized imaging is available or the owner declines imaging, the tentative diagnosis can be made by the combination of history, clinical presentation, physical examination, and blood work. In suspect cases, a trial therapy of methimazole can be started, as the response to medical treatment is usually very fast and obvious (ie, weight gain or behavior change within 48 hours after start of trial therapy).

During the diagnostic process, it is important to avoid a “thyroid storm,” which can be triggered by any stressful event such as excessive handling or the mechanical (ie, surgical) manipulation of the gland. Keeping the animal in a calm environment and handling it gently is the best way to prevent an adverse event. It is important to remember that the condition is chronic and urgent acute treatment is often not needed. If secondary pathologic problems exist, such as congestive heart failure, it is important to address these issues immediately to prevent complications during the thyroid therapy (for a list of potential complications see the Medical Treatment).

THERAPY

Once the clinical diagnosis has been established, multiple treatment therapies exist for hyperthyroidism. Each treatment has distinct advantages and disadvantages. The owner should be made aware of all these factors when deciding which treatment option to choose. The goal of treatment is to return thyroid hormone levels to normal with a subsequent resolution of the clinical signs. Optimally, the owner should be informed about all different treatment options and should be educated about the positive and negative attributes of each treatment option. A significant factor in the decision-making process is often the cost involved with the treatment along with the potential risks associated with the treatment. To provide the owner with accurate information about treatment options, it is important to locate certain specialty clinics (eg, specialty surgery service, I-131 treatment facility). Exact costs associated with each procedure should be detailed so as to provide a realistic estimate and avoid disappointment later on.

As outlined in the following section, treatment can range from oral medication to invasive surgery to remove the pathologic tissue.

Medical Treatment

The medical treatment of choice in the guinea pig is extrapolated from clinical feline medicine. To the authors' knowledge, no pharmacologic study has been published on the therapeutic use of antithyroid drug in the guinea pig; however, some data are available on the use of propylthiouracil (PTU) in guinea pigs. PTU is a thioamide drug used to treat hyperthyroidism and pharmacologically is similar to methimazole. Studies have shown that pharmacokinetic behavior of PTU in the guinea pig is similar to that in humans. Plasma levels are reached after 2 hours in guinea pigs and within 1 to 2 hours in humans.¹⁸ Therefore, extrapolation of the pharmacokinetic data of methimazole from humans to guinea pigs appears adequate.

The drugs of choice are methimazole or carbimazole, as these drugs are used in cats with the same problem. These antithyroid drugs directly suppress thyroid hormone production. Drug dosages for methimazole have been extrapolated from cat dosages and successful anecdotal use ranges from 0.5 to 2.0 mg/kg orally once to twice a day. Carbimazole is now also available in the United States and drug dosages for guinea pigs are reported at 1 to 2 mg/kg orally once a day.⁴ The appropriate dose would be determined by repeated assays of serum thyroid hormone levels. Because methimazole is available only in 5- and 10-mg tablets, it is often prepared by a compounding pharmacy. One author (J.M.) suggests compounding it into a liquid of 10 mg/kg to avoid large or small dosing volumes and also to accomplish good drug distribution in compounded liquids. The use of transdermal methimazole in premium lecithin organogel gel has been reported to have therapeutic success in cats that do not tolerate oral dosing. One author (R.W.) has had clinical success with transdermal methimazole in guinea pigs; however, transdermal application has been shown to cause depigmentation of brown guinea pig skin.¹⁹ The depigmentation effect is also observed in humans, where the dermal application of methimazole can be used in hyperpigmentation disorders.²⁰ Caution should be used with this delivery method in any animal other than cats because of this side effect.

Advantage

Oral medical treatment is considered the least invasive option to treat patients. The clinical response is usually seen very fast, ie, within 48 hours, and the drugs are not very expensive. The drug is usually given orally once daily, which aids medication and owner compliance significantly. A few refractory cases require twice-daily dosing. Because of

the ease of treatment with minimal side effects, the drug can be used as a trial therapy in suspect cases, where appropriate diagnostics are not an option. If clinical signs improve significantly on the drug and return once medication is stopped, there is a strong clinical suspicion for hyperthyroidism and a tentative diagnosis can be made.

Disadvantage

The main drawback of the oral treatment is that the medication needs to be given for life, as the discontinuation of the medication will result in return of clinical signs very fast (ie, 24–48 hours). As mentioned previously, it can be difficult to monitor the effect of the medication based on hormone levels; the efficacy of the treatment often needs to be guided by the clinical response. In dogs and cats, the drug has been reported to cause some minor side effects such as vomiting, anorexia, and depression. Eosinophilia, leukopenia, and lymphocytosis may be seen with drug administration. When observed in cats, these clinical pathology changes are usually transient and do not require cessation of therapy.²¹ Cases of toxicity because of an accidental overdose, agranulocytosis, hepatopathy, and thrombocytopenia are deleterious side effects reported in other domestic species.²¹

It is unclear to what extent these potential side effects affect guinea pigs. To date, no side effects during the therapeutic use of methimazole have been reported in the guinea pig.

Surgical Excision

Surgery to excise the affected gland is possible and a technical paper on the procedure was published more than 30 years ago.²² Multiple articles exist in the scientific literature where a complete thyroidectomy in guinea pigs was performed experimentally.²³ Before surgery is attempted, the authors strongly suggest having diagnostic imaging performed to evaluate if the disease is uni- or bilateral. The 2 imaging techniques of choice are US examination or scintigraphy. Although the US examination will reveal morphologic abnormalities and vascular involvement, scintigraphy will locate functional, ectopic tissue if present.

Advantage

Surgical removal of all pathologic tissue can be curative. After a successful surgery there is no need to medicate the animal long term; however, frequent rechecks of the hormone levels are still recommended as the disease has the potential to recur. It is advisable to submit the removed tissue to a pathologist for histopathologic evaluation.

Disadvantage

Surgical excision can be complicated because of the anatomic location of the thyroid gland. Possible complications include recurrent laryngeal nerve damage and the stimulation of aberrant thyroid tissue. The surgery should be performed by a specialist with access to microsurgical instruments. One of the authors (R.W.) encountered several thyroid carcinomas that could not be surgically excised because of the extensive vascular nature and other vital tissue involvement. Surgery should ideally not be attempted before the animal is medically stabilized so as to avoid postsurgical complications, such as a thyroid storm (C. Orcutt, personal communication, 2008).²⁴ It is interesting to note that human patients with hyperthyroidism (and those receiving exogenous thyroid replacement) may be susceptible to developing severe hypertension and tachycardia when given ketamine. However, the veterinary significance of this potential complication is unknown.²¹

The total removal of all thyroid gland in a guinea pig involves also removing the parathyroid glands, as they are embedded throughout the thyroid tissue. To prevent

postoperative hypocalcemia, which would be fatal immediately after surgery, it is important to provide a source of calcium, such as 1.0% calcium lactate or calcium gluconate orally once a day. Calcium should be provided at least for 7 to 10 days post-operatively before a weaning trial of the calcium can be started.

Percutaneous Ethanol Injection

In cats, the destruction of abnormal tissue by the direct injection with alcohol has been published.²⁴ The injected alcohol will necrotize the glandular tissue and leave it nonfunctional. Alcohol ablation was attempted 2 times on the same guinea pig with only transient improvement; eventually the guinea pig died 1 month after the last alcohol injection (R.W.). The authors do not recommend the percutaneous use of ethanol to treat this disease.

Radioactive Treatment with I-131

Two authors (R.W., J.M.) have each treated one patient with I-131 and the patients had a good quality of life after radiation treatment. Both animals weighed approximately 700 g at the time of diagnosis and received 1 mCi of I-131 subcutaneously once. One patient lived for 14 months after the treatment and then died of chronic renal failure. The second guinea pig is doing well 6 months after treatment. Both patients rapidly regained weight after the treatment with the radioactive iodine. Hyperactive behavior ceased and hormone levels returned to normal.

There was no indication of azotemia in the affected guinea pigs before the treatment; neither of the guinea pigs diagnosed had elevated blood urea nitrogen (BUN) at the time of diagnosis. Renal problems might not be a common clinical finding in hyperthyroid guinea pigs.

Advantage

In one author's (J.M.) opinion this can be considered the best treatment option for different reasons (**Figs. 6–8**). First, the treatment can achieve long-term control of the disease and, second, it has the potential to be curative. The treatment with I-131 renders all hyperfunctional thyroid tissue, including ectopic tissue, nonfunctional. This treatment is less invasive than surgery, has a higher success rate, and can be given intravenously or subcutaneously. It appears that the dose of 1 mCi achieved good clinical results in 2 guinea pigs.



Fig. 6. Cages with signs of radiation after the animal has been injected with radioactive material for either a diagnostic scintigraphy or for treatment with I-131.

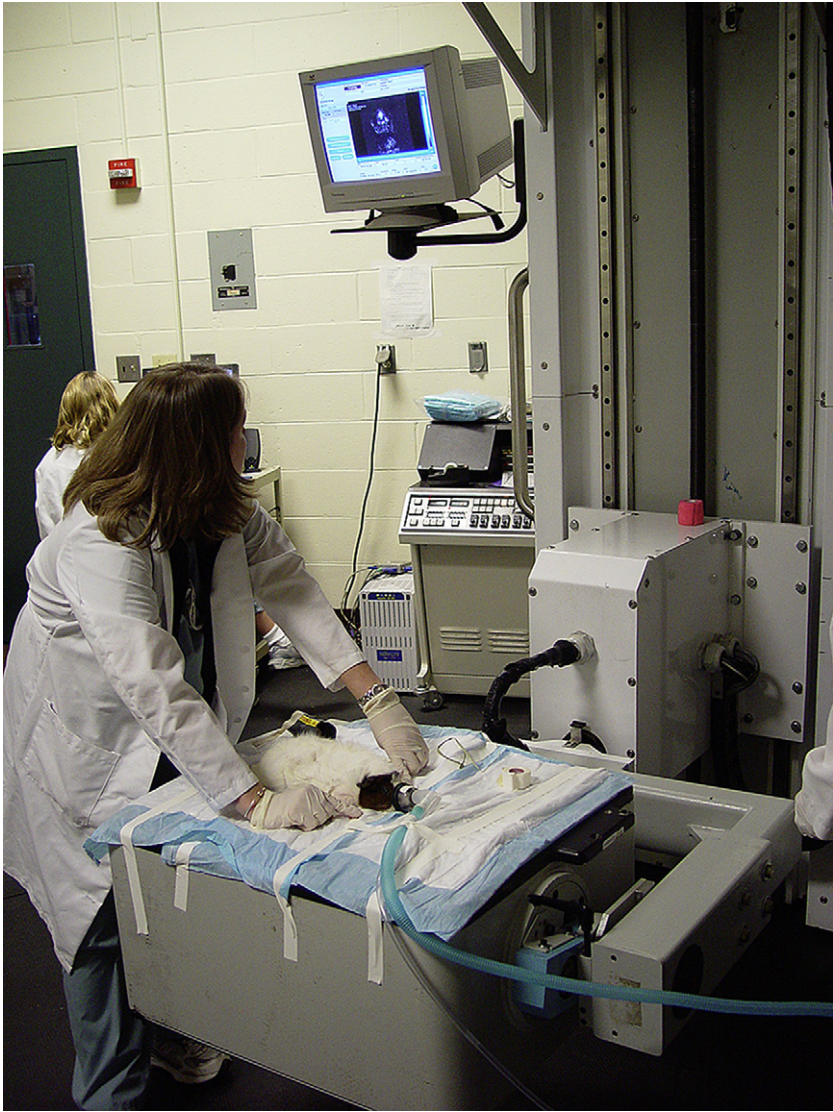
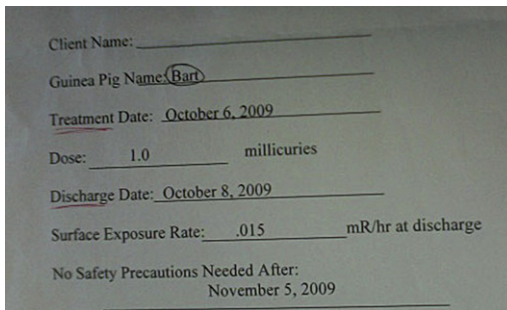


Fig. 7. The anesthetized guinea pig rests on top of the gamma camera for the scintigraphy procedure. Even minimal motion will result in an inaccurate capture of the image details obtained by the gamma camera.

Disadvantage

The patient needs to be brought to a special clinic that can perform this procedure. The clinic needs to be an approved specialty facility with state department of health and Nuclear Regulatory Commission permits for use of I-131. There are few clinics that are allowed to use radioactive materials; in addition, no clinical data on the use of this treatment in guinea pigs are available. Often state approval for individual cases has to be obtained if species other than dogs or cats are being treated. Relapse of the hyperthyroid status is possible. Isolation at the treatment facility for 1 to 7 days after



Client Name: _____
 Guinea Pig Name: Bart
 Treatment Date: October 6, 2009
 Dose: 1.0 millicuries
 Discharge Date: October 8, 2009
 Surface Exposure Rate: .015 mR/hr at discharge
 No Safety Precautions Needed After:
November 5, 2009

Fig. 8. Treatment sheet of a guinea pig receiving radioactive iodine treatment (I-131). As you can see, the animal was discharged within 48 hours after the treatment but the owner had to collect all waste products of the animal and store it for about 30 days before they can be discharged in the normal trash.

therapy is required, as treated animals will be radioactive. Proper radiation doses for guinea pigs still need to be determined. If the administered dose is too high, there is a risk of causing iatrogenic hypothyroidism in the animal.

RECOMMENDED MONITORING

The monitoring intensity for the treated animal depends on the method of treatment. The least critical side effects are expected with radioactive and medical treatment. The highest risks for complications are associated with surgical treatment. Monitoring the animal after treatment is important to judge and gauge the success of the therapy and to recognize potential complications early on to avoid a fatal outcome. The evaluation of the ionized calcium of postsurgical patients is of utmost importance to ensure that the parathyroid glands were not completely removed during the thyroidectomy.

Medical Therapy

Monitoring for side effects of medication is indicated but the authors have not noticed any significant side effects when using recommend doses. As a general routine for recheck examination, the following parameters should be monitored after medical treatment is started: complete physical examination, blood work, and T4/T3 blood levels at 2 weeks posttreatment. If the patient is normal, reassess the patient 6 months after treatment or earlier if adverse effects or recurrent signs of hyperthyroidism are noted.

Thyroidectomy

In addition to the monitoring mentioned previously for medical management, in a surgical case the blood work should include ionized calcium if a bilateral thyroidectomy was performed. Oral calcium supplementation is needed to avoid an immediate fatal hypocalcaemia. The ionized calcium would need to be checked immediately after surgery and then at 2 weeks after surgery.

Radioactive Iodine Therapy

The recheck should include what is done with medical therapy. Again, the physical examination and patient history are very important. Descriptions of changes in behavior or eating habits should be discussed in great detail.

PROGNOSIS

The prognosis can be good in cases where the problem was diagnosed early and response to treatment is good. In severe cases and in cases where the animal is debilitated, the prognosis is less favorable. Sometimes secondary complications can occur such as secondary pneumonia, or aspiration of food with a ravenous appetite.

HYPOTHYROIDISM IN THE GUINEA PIG

Hypothyroid conditions of the guinea pig appear much less frequently in the clinical setting than hyperthyroidism. The low end of the normal thyroxine level is reported to be 1 $\mu\text{g}/\text{dL}$.⁸ If the value falls significantly below this level and the animal shows typical signs of hypothyroidism, a thyroid-stimulating hormone (TSH) stimulation test is indicated.

Typical clinical signs that have been reported are a decrease in activity and increase in body weight. Often these changes are subtle and the gradual onset often goes

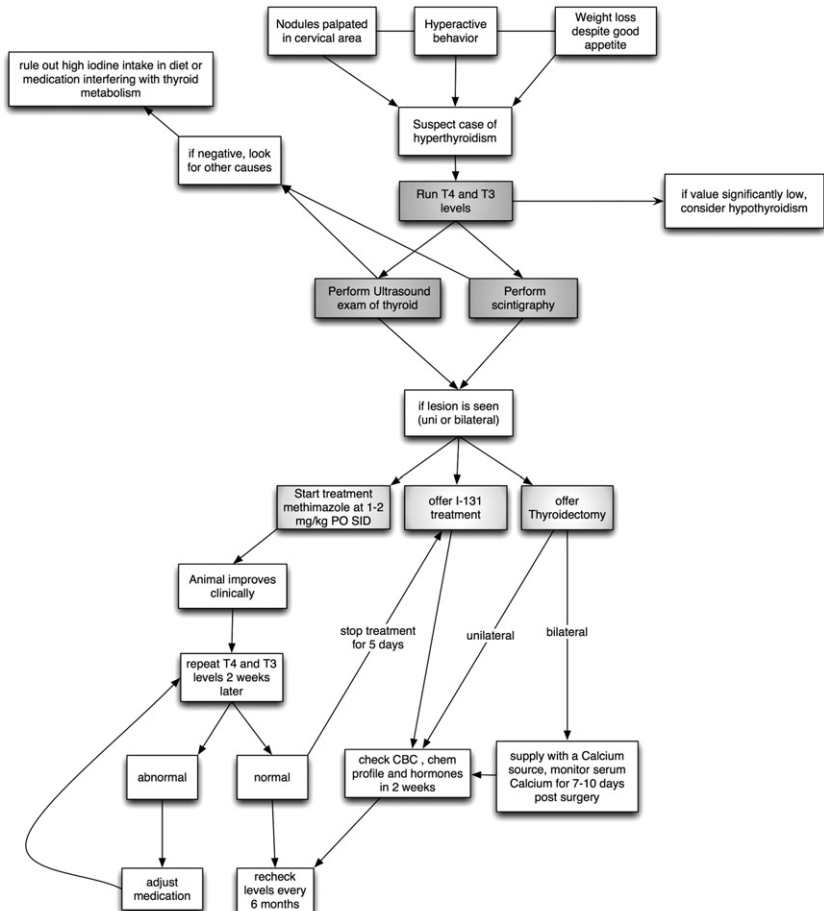


Fig. 9. Algorithm used as a guide for the diagnosis and treatment of hyperthyroidism in an exotic small mammal patient.

unnoticed by the owner. A detailed anamnesis with questions about a change in activity over a longer time period is important. In chronic cases, the clinical presentation can mimic the signs of hyperthyroidism; animals have been reported to lose weight and even lose hair. The alopecic areas are often observed in the dorsal area and the inner thighs. Sometimes bradycardia can also be ausculted.⁴

Diagnosis

One of the authors (R.W.) uses the following routine to diagnose hypothyroidism in the guinea pig: 100 µg of thyrogen, a recombinant human TSH (rhTSH) is given intramuscularly and plasma T4 concentrations are determined before and 4 hours after TSH injection. An increase of at least 1.5 times prestimulation T4 concentrations at 4 hours poststimulation is considered a normal response.

Therapy

If the animal is not presented in the late stage of the disease, medical management can be successful in controlling the condition. Oral L-thyroxine at a dosage of 10 µg/kg once a day can be given.⁴ Blood thyroxine levels should be rechecked 2 weeks and then 2 months after the initiation of the therapy.

SUMMARY

Diagnosing hyperthyroidism in nontraditional species is challenging because of multiple factors (Fig. 9). Interpretation of thyroid values can be considered to be difficult even in species for which tests have been validated (eg, dog and cats). In cats with early or mild forms of hyperthyroidism, the serum thyroid levels might fall well within described normal reference values. In addition, the presence of a concurrent secondary problem might lower the T4 value back into the reference value in a true hyperthyroid patient.²⁵ Because of these common problems, it has been suggested to perform a “free” T4 test or a TSH stimulation test, as these assays are considered more sensitive for the diagnosis of early stages of hyperthyroidism.²⁶ Another more reliable method to diagnose functional pathologies of the thyroid gland is nuclear medicine. For a more detailed discussion on how to perform and evaluate scintigraphy of suspect cases please see Mayer and colleagues.¹⁵

It appears that functional (clinical) hyperthyroidism truly exists in the guinea pig population. Although no clear pattern about the sex predilection can be seen in the examined cases here, it is interesting to note that in human medicine it is known that differences exist between the activity of the thyroid gland of males and females. A greater tendency to thyroid hypertrophy exists in the female.^{27,28} It has been discovered that a parallelism exists between the anatomic characteristics of the thyroid gland and the intensity of its metabolic activities and production of hormone. In the female guinea pig during the sexual cycle, the number of mitoses in the thyroid gland is therefore about 3 times higher than in the male. In human medicine, this would correspond to the predilection of hyperthyroidism in females.²⁷ In addition, it is mentioned that there is a female sex-linkage of mixed thyroid tumors in humans and canines.² It is speculative if this also applies to the guinea pig.

REFERENCES

1. Mosinger M. Sur la carcinoresistance du cobaye. Premiere partie. Les tumeurs spontanees du cobaye. Bulletin de l'Association Francaise pour l'etude du Cancer 1961;48:217 [in French].

2. Zarrin K. Thyroid carcinoma of a guinea pig: a case report. *Lab Anim* 1974;8(2): 145–8.
3. Gibbons P, Garner M. Pathological aspects of thyroid tumors in guinea pigs. *Proceedings of the AEMV Milwaukee (WI)*: 2009. Page 81.
4. Ewringmann A, Glöckner B. Leitsymptome bei Meerschweinchen, Chinchilla und Degu. *Diagnostischer Leitfaden und Therapie*. 1st edition. Stuttgart/Germany: Enke publishing; 2005. October 2005.
5. Percy DH, Barthold SW. *Pathology of laboratory rodents and rabbits*. 3rd edition. Ames (IA): Blackwell Publishing Professional; 2007.
6. Taeymans O, Peremans K, Saunders JH. Thyroid imaging in the dog: current status and future directions. *J Vet Intern Med* 2007;21:673–84.
7. Gibbons P, Garner M. Tumors of the thyroid gland in guinea pigs (*Cavia porcellus*). Manuscript in preparation 2009.
8. Müller K, Müller E, Klein R, et al. Serum thyroxine concentrations in clinically healthy pet guinea pigs (*Cavia porcellus*). *Vet Clin Pathol* 2009;38(4):507–10.
9. Kintzer PP, Peterson ME. Nuclear medicine of the thyroid gland. Scintigraphy and radioiodine therapy. *Vet Clin North Am Small Anim Pract* 1994;24:587–605.
10. Marks SL, Koblik PD, Hornof WJ, et al. ^{99m}Tc -pertechnetate imaging of thyroid tumors in dogs: 29 cases (1980–1992). *J Am Vet Med Assoc* 1994;204:756–60.
11. Daniel GB, Brawner WR. Thyroid scintigraphy. In: Daniel GB, Berry CR, editors. *Textbook of veterinary nuclear medicine*. North Carolina (NC): American College of Veterinary Radiology; 2006. p. 181–98.
12. Adams WH, Daniel GB, Petersen MG, et al. Quantitative ^{99m}Tc -pertechnetate thyroid scintigraphy in normal beagles. *Vet Radiol Ultrasound* 1997;38:323–8.
13. Ferguson DC. Update on diagnosis of canine hypothyroidism. *Vet Clin North Am Small Anim Pract* 1994;24:515–39.
14. Catherine J, Scott-Moncrieff R, Guptill-Yoran L. Endocrine disorders. Hypothyroidism. In: Ettinger SJ, Feldman EC, editors. *Textbook of veterinary internal medicine*. St. Louis (MO): Elsevier-Saunders; 2005. p. 1535–43.
15. Mayer J, Hunt K, Eshar D, et al. Thyroid scintigraphy in a guinea pig with suspected hyperthyroidism. *Exotic DVM* 2009;11(1).
16. Popesko P, Rajtova V. *A colour atlas of anatomy small laboratory animals: 2*. Bratislava, Mosby: Elsevier; July 1, 1992.
17. Taeymans O, Schwarz T, Duchateau L, et al. Computed tomographic features of the normal canine thyroid gland. *Vet Radiol Ultrasound* 2008;49:13–9.
18. Benker G, Reinwein D. Pharmacokinetics of antithyroid drugs. *Klin Wochenschr* 1982;60:531–9.
19. Kasraee B. Depigmentation of brown guinea pig skin by topical application of methimazole. *J Invest Dermatol* 2002;118(1):205–7.
20. Kasraee B, Handjani F, Parhizgar A, et al. Topical methimazole as a new treatment for postinflammatory hyperpigmentation: report of the first case. *Dermatology* 2005;211(4):360–2.
21. Plumb DC. *Plumb's veterinary drug handbook*. 5th edition. Ames (IA): Wiley-Blackwell; 2005.
22. Kromka MC, Hoar RM. An improved technique for thyroidectomy in guinea pigs. *Lab Anim Sci* 1975;25(1):82–4.
23. Moltke E, Lorenzen I. Effect of thyroidectomy and thyroxine on the mucopolysaccharides of wounds and skin. *Acta Endocrinol* 1960;34:407–10.
24. Goldstein RE, Long C, Swift NC, et al. Percutaneous ethanol injection for treatment of unilateral hyperplastic thyroid nodules in cats. *J Am Vet Med Assoc* 2001;218(8):1298–302.

25. Peterson ME, Gamble DA. Effect of nonthyroidal illness on serum thyroxine concentrations in cats: 494 cases. *J Am Vet Med Assoc* 1990;197(9):1203–8.
26. Peterson ME, Melian C, Nichols R. Measurement of serum concentrations of free thyroxine, total thyroxine, and total triiodothyronine in cats with hyperthyroidism and cats with nonthyroidal disease. *J Am Vet Med Assoc* 2001;218(4):529–36.
27. Chouke KS, Friedman H, Loeb L. Proliferative activity of the thyroid gland of the female guinea pig during the sexual cycle. *The Anatomical Record* 2005;63(2): 131–7.
28. Castro MI, Alex S, Young RA, et al. Total and free serum thyroid hormone concentrations in fetal and adult pregnant and nonpregnant guinea pigs. *Endocrinology* 1986;118(2):533–7.