

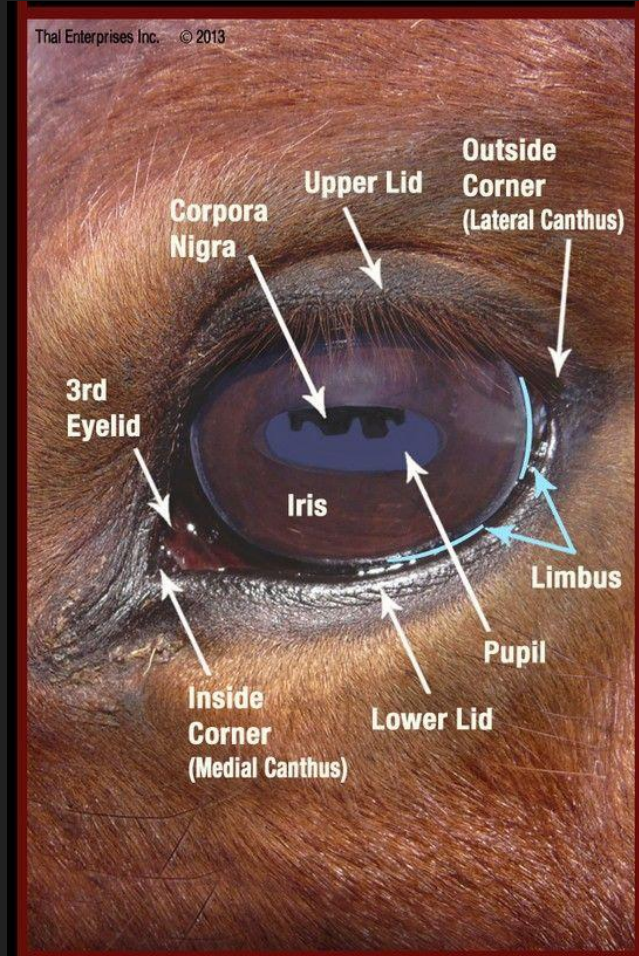


Common Eye Issues

Allegheny Equine Client Education
Dr. Nicolette Santercangelo

Eye Exam

- General Exam
 - Eyelashes
 - Eyelids
 - Conjunctiva
 - Foreign Bodies
 - Masses
- Cornea and Sclera
- Anterior Chamber
- Iris
- Lens
- Nasolacrimal Duct
- Fundus
- Neurologic Status



Quick Reference - Equine Eye

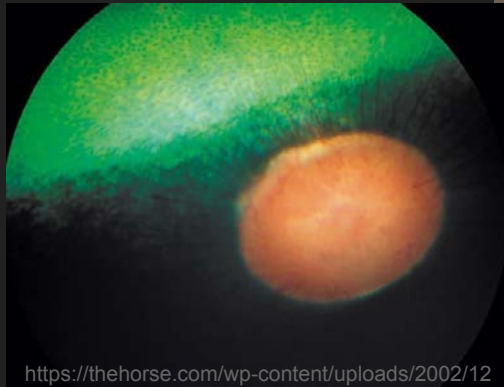HORSE SIDE VET GUIDE™

MOBILE APPLICATION FOR HORSE OWNERS
& EQUINE PROFESSIONALS


www.horsidevetguide.com

Eye Exam - Tools

- Sedation
- Ophthalmoscope
- Fluorescein Stain
- Tetracaine - numb the cornea
- Tropicamide 1% - dilate
- Cotton Swabs and Microscope Slide
- Tonometry
- Nerve Blocks

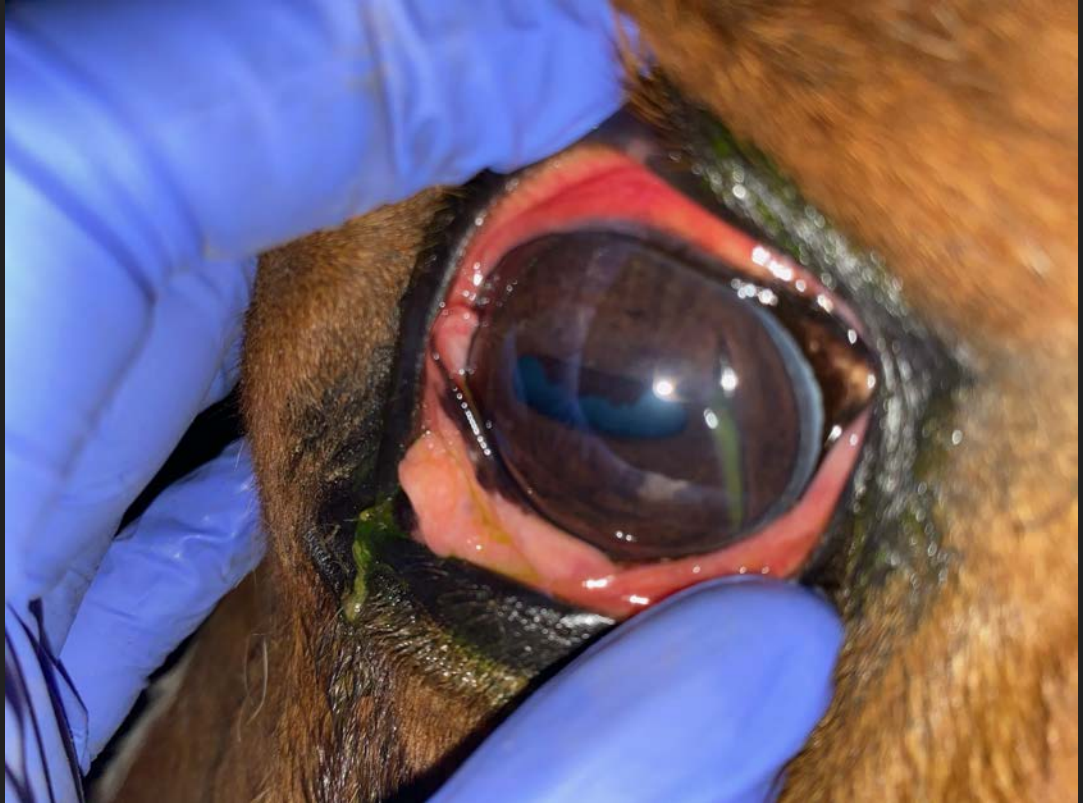

<https://thehorse.com/wp-content/uploads/2002/12/NormalRetina-Brooks.jpg>



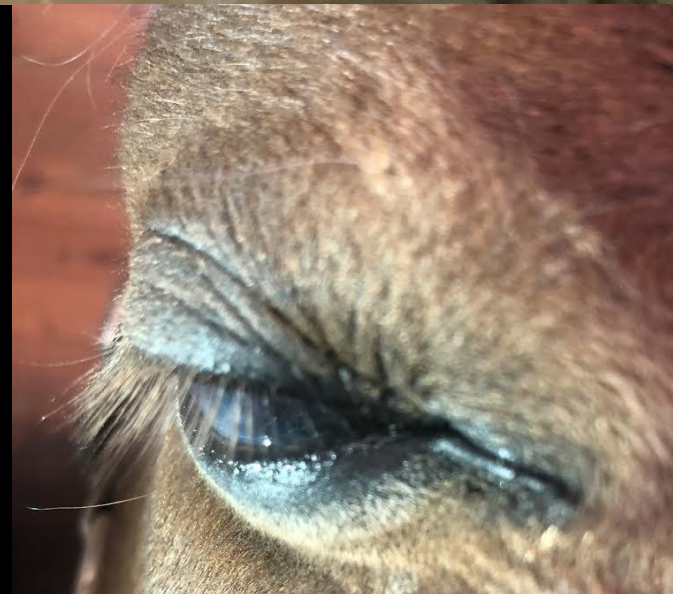Common Eye Issues

- Eyelid Lacerations & Abrasions
- Trauma
 - Foreign Bodies
- Corneal Ulcers & Abrasions
 - Corneal Lacerations
 - Complicated Ulcers:
 - Melting Ulcers
 - Descemetocelles
 - Fungal Keratitis
 - Stromal Abscesses
- Uveitis



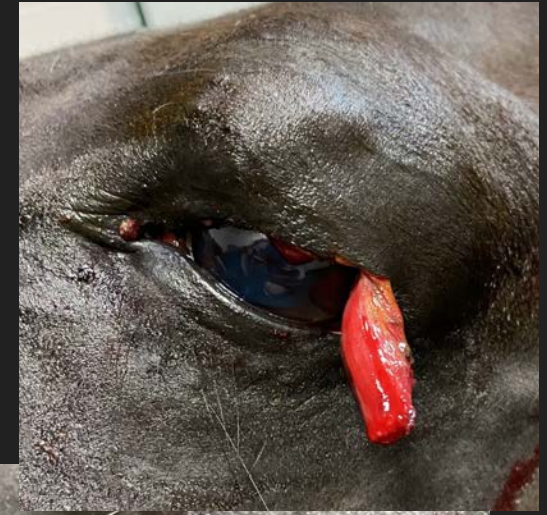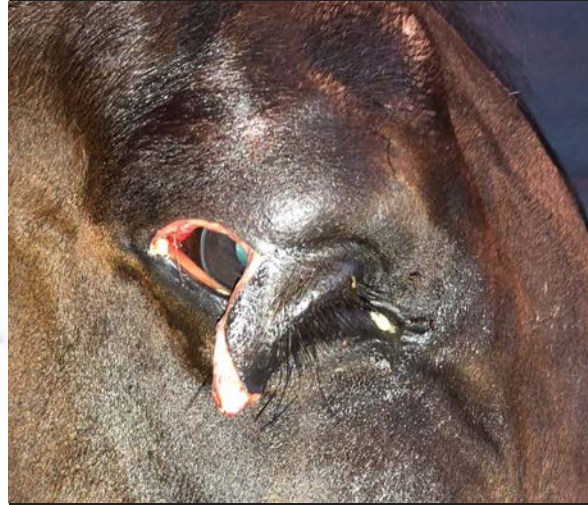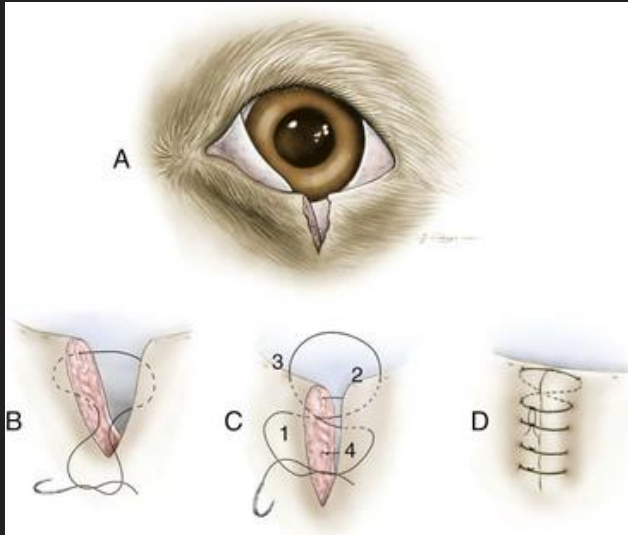


Eyelid and Eyelash Symmetry
Helpful in detecting small changes
Every horse is different



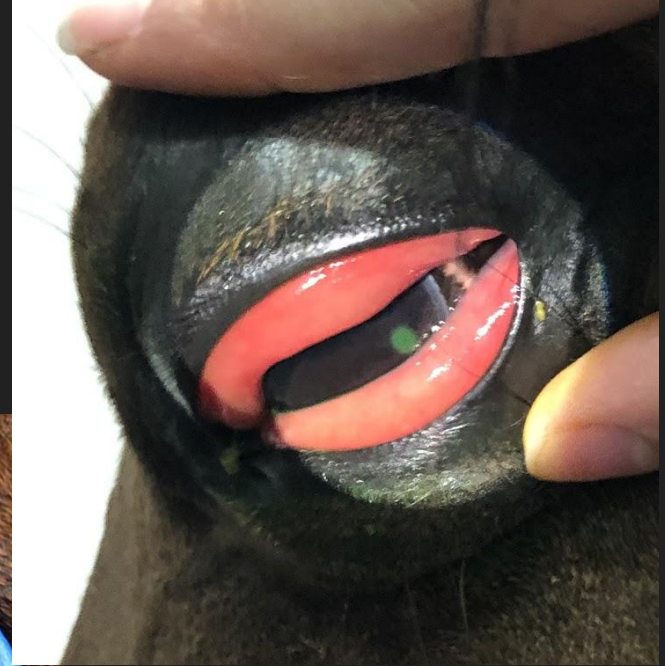
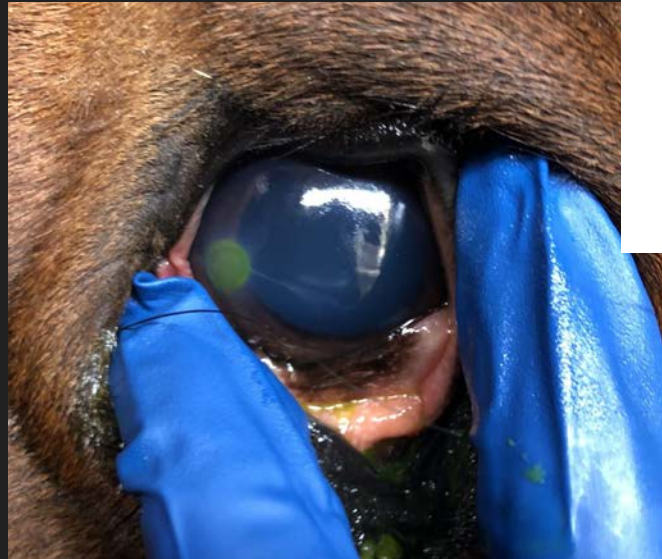Eyelid Lacerations

- Eyelid alignment!
- Ulcer Treatment
- NSAIDs - banamine, bute, Equioxx

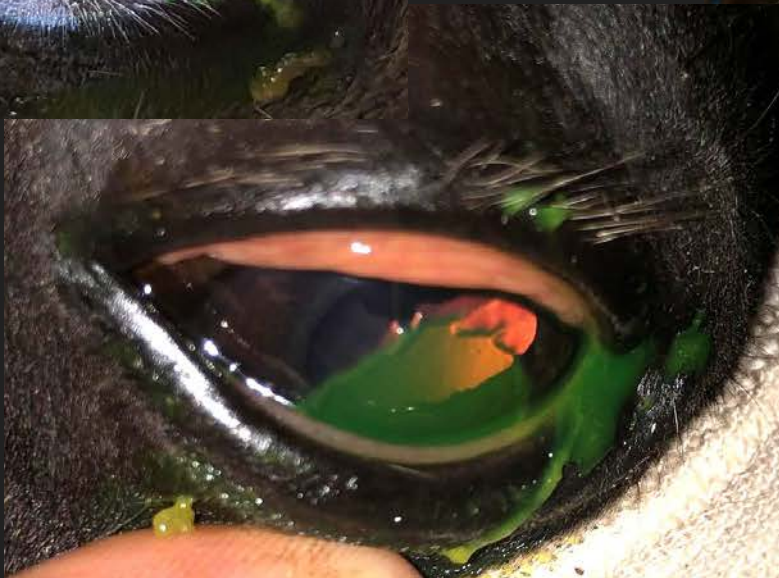
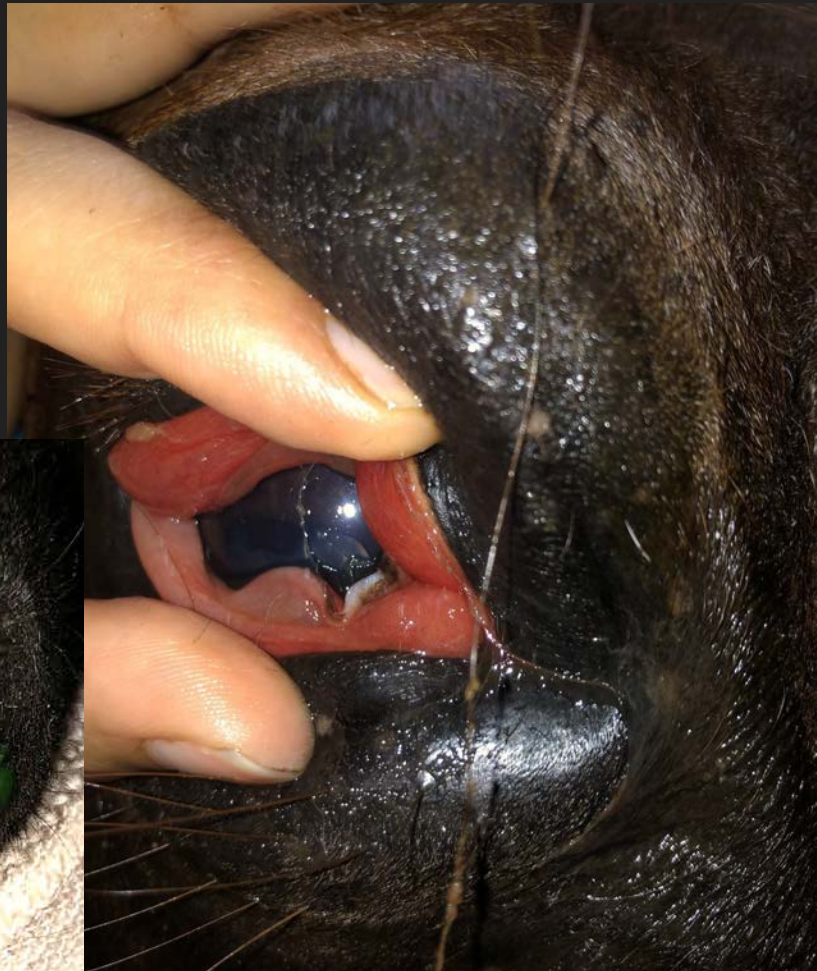
Corneal Ulcers and Abrasions

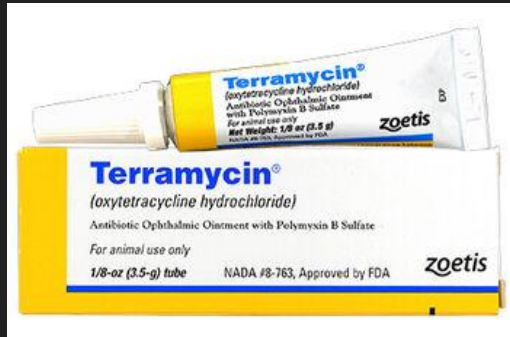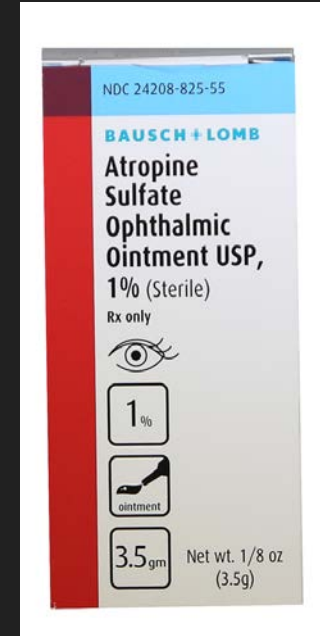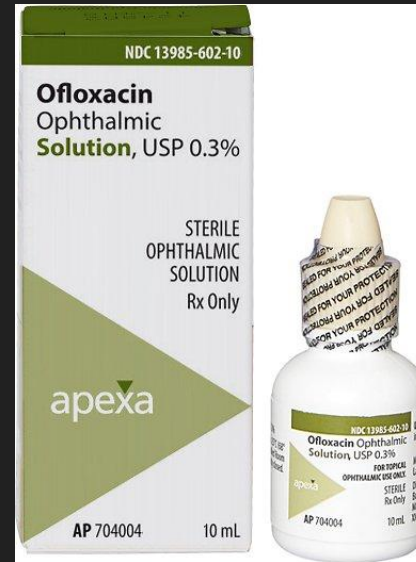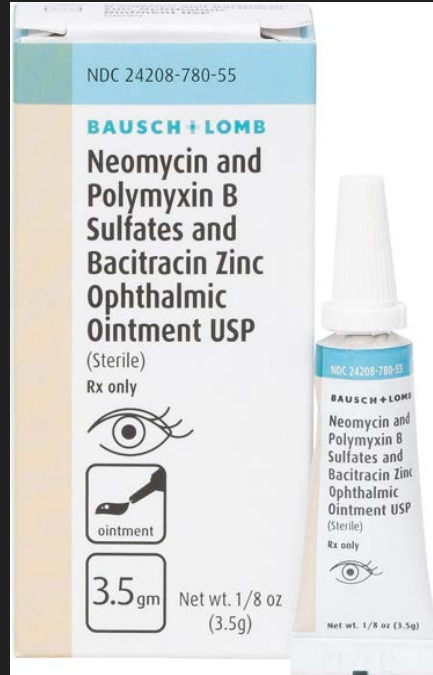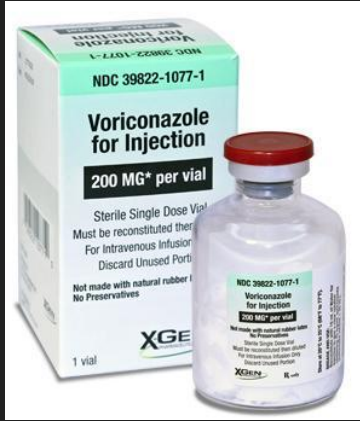- Damage to the corneal tissue
 - Fluorescein Stain
- Bacterial
- Fungal
- Pseudomonas

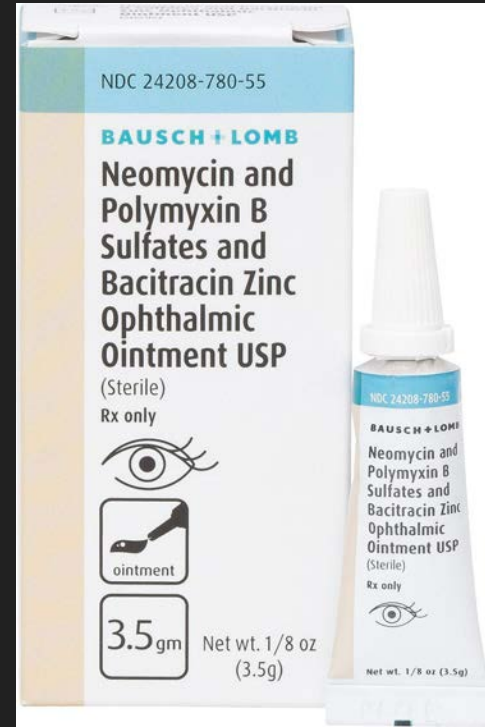
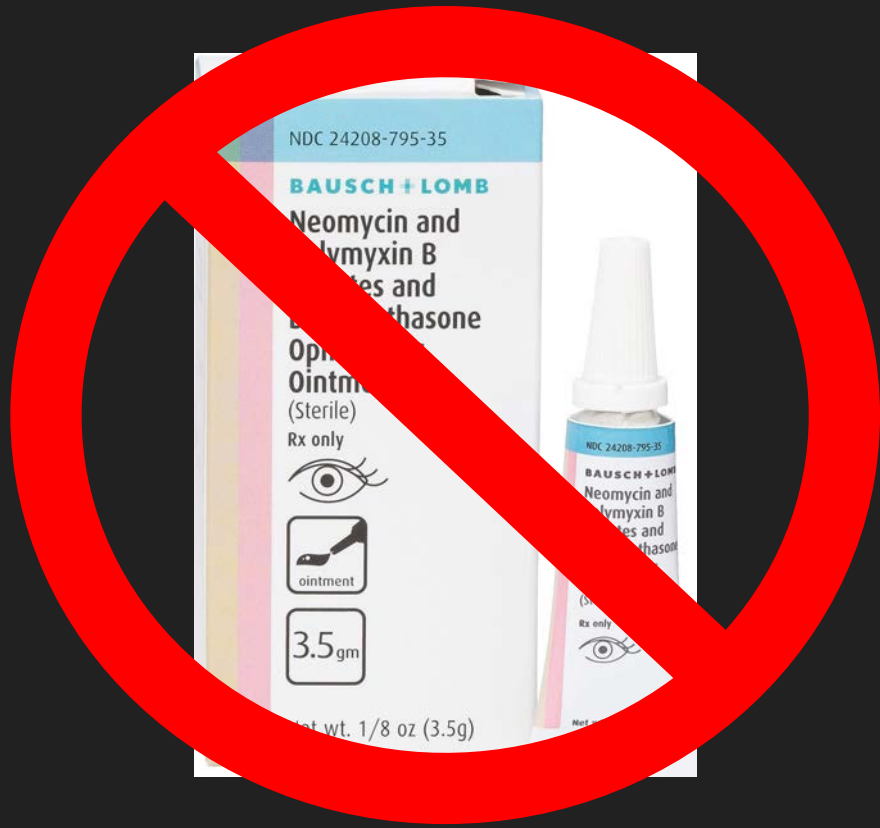
ALWAYS AN EMERGENCY



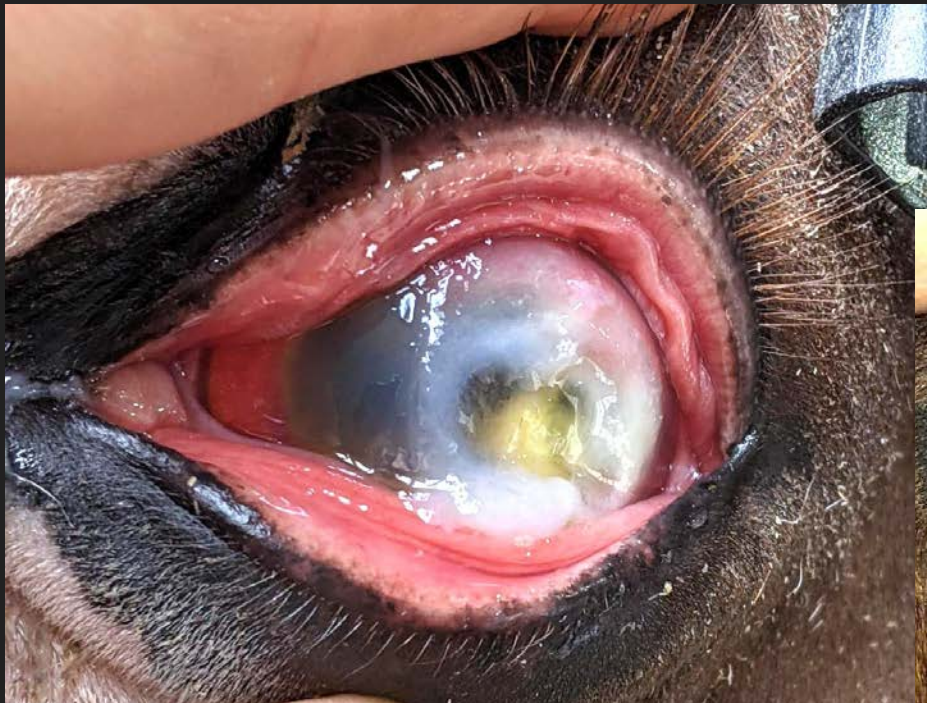Treatment Options



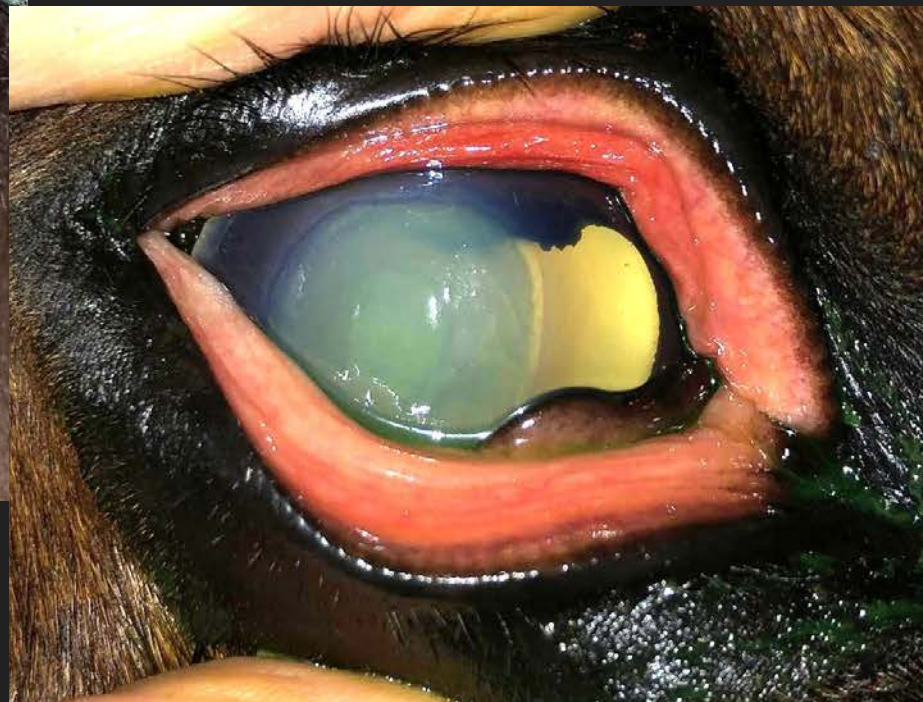

Any product containing dexamethasone or other steroid IS NOT safe for corneal ulcers!

Uh Oh!



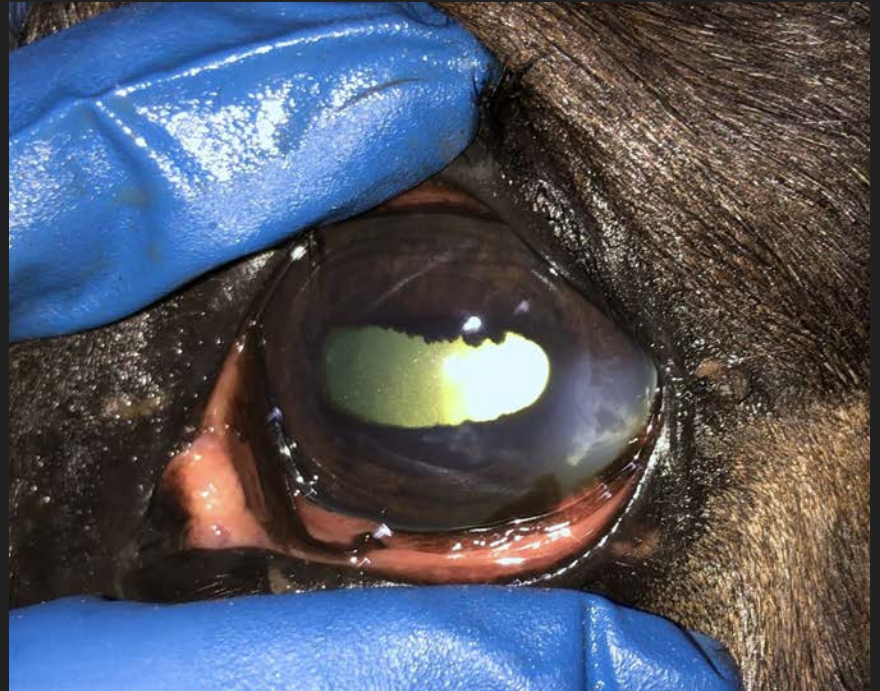ALWAYS AN EMERGENCY





Descemetocoeles

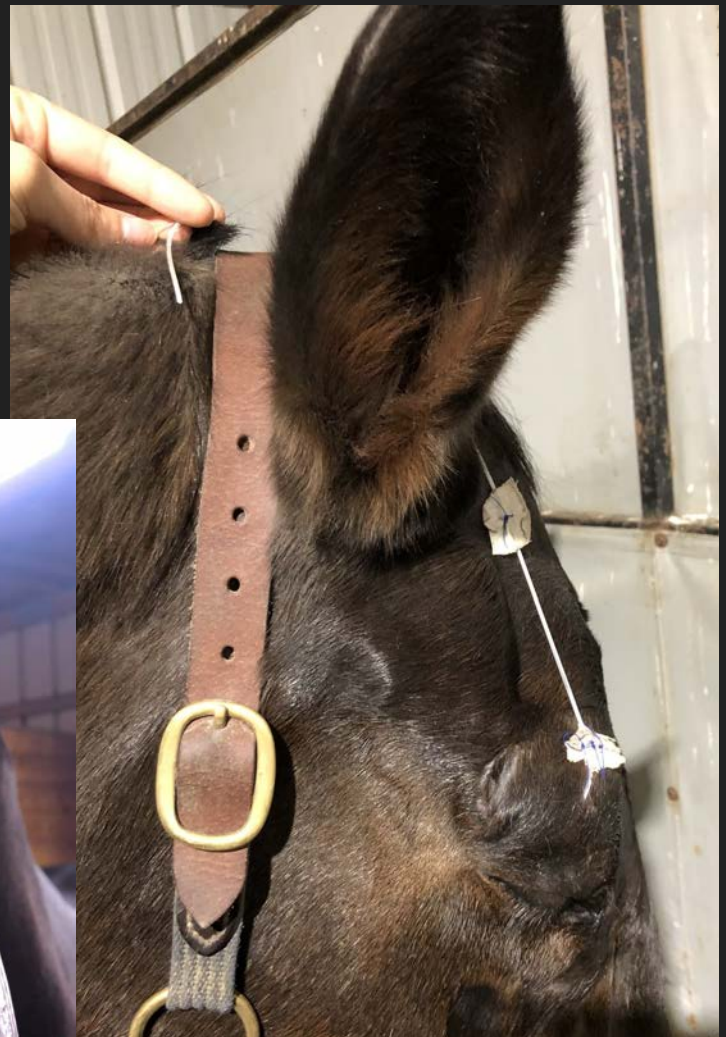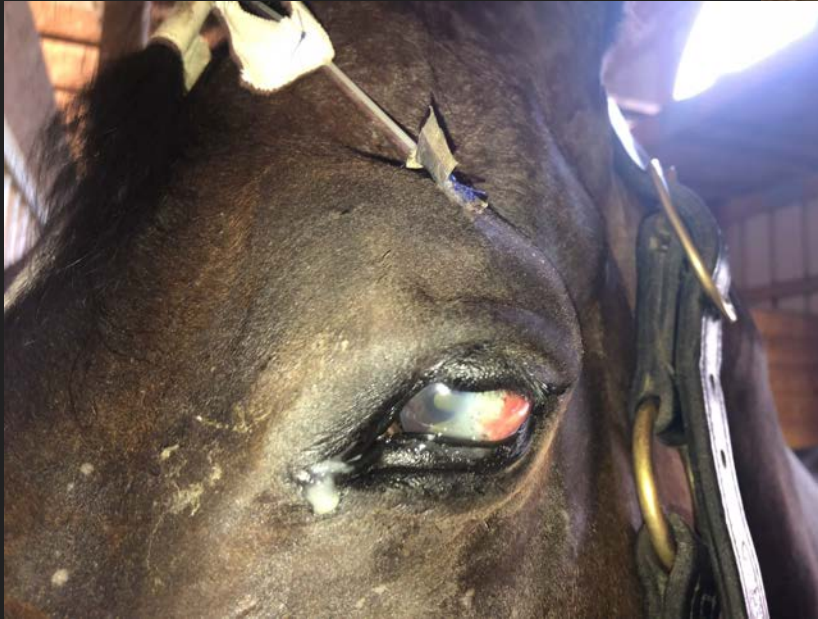Deep ulcerations that are full thickness of the cornea.
Can result in perforation of the eyeball itself



SPL

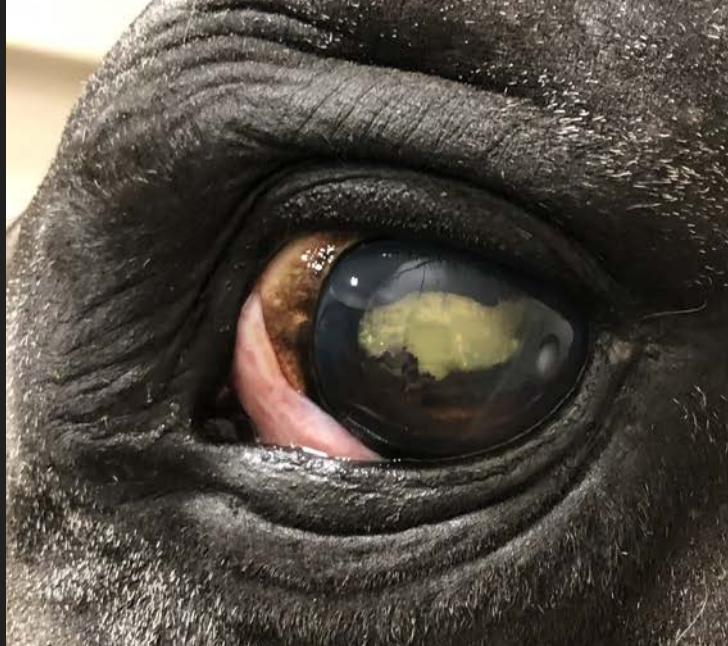Subpalpebral Lavage

- Less hassle/discomfort to the horse
- More frequent medication administration



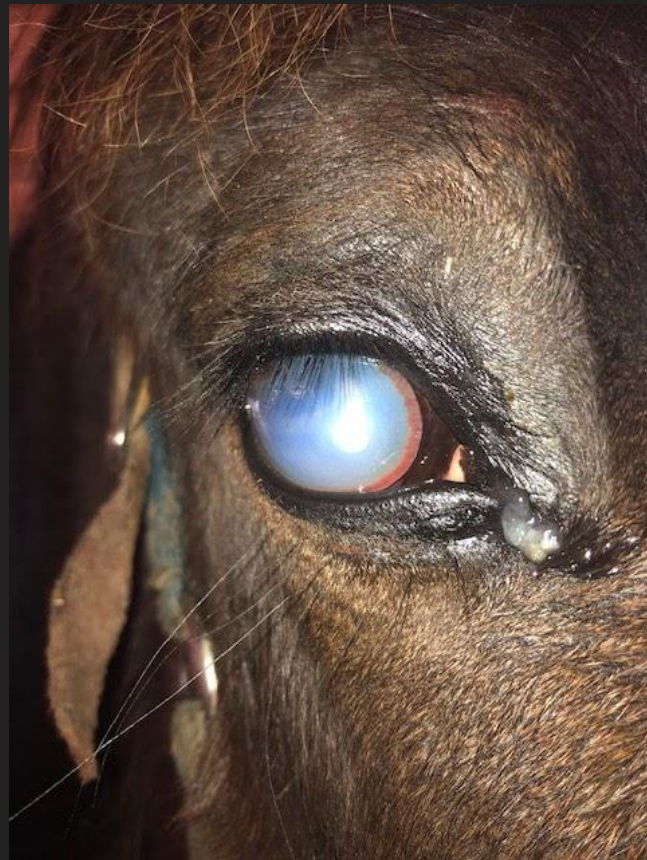Cataracts and Nuclear Sclerosis

- Results from chronic inflammation in the eye vs aging
- Can affect vision
- Irreversible
- Suddenly spooky

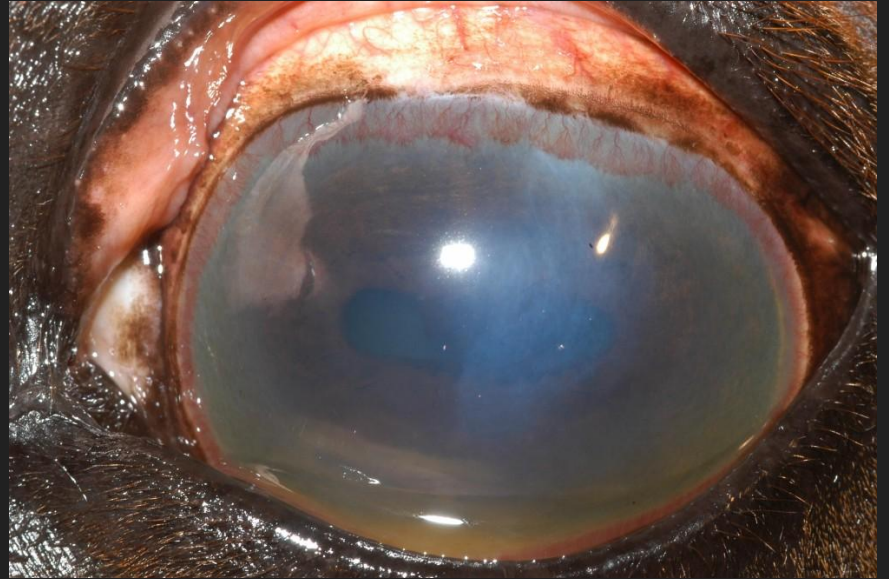
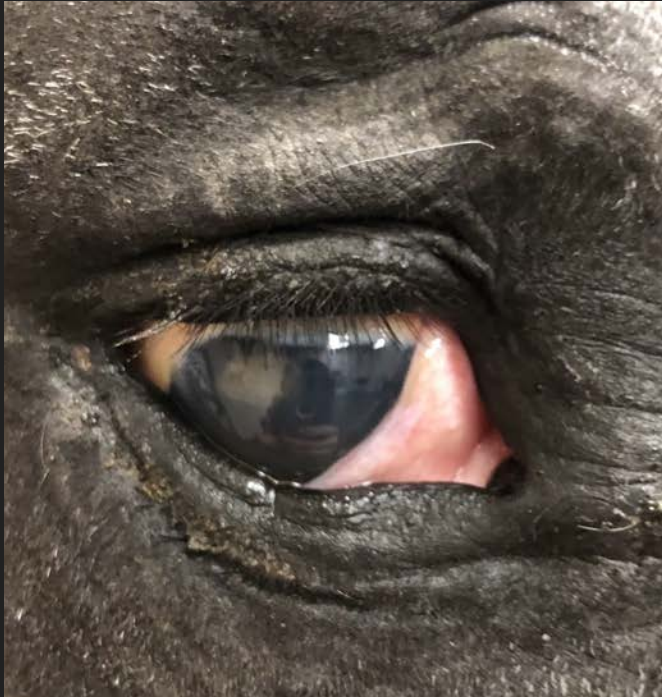
Equine Recurrent Uveitis

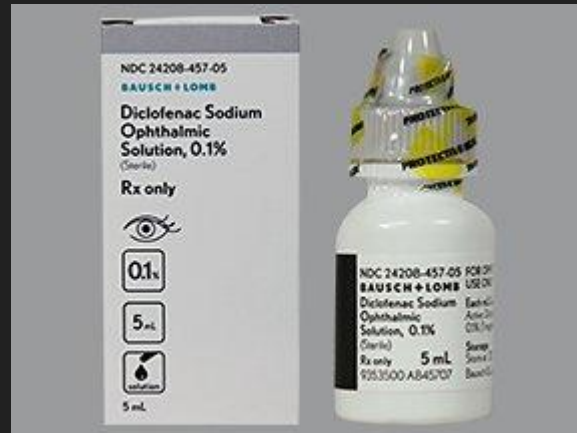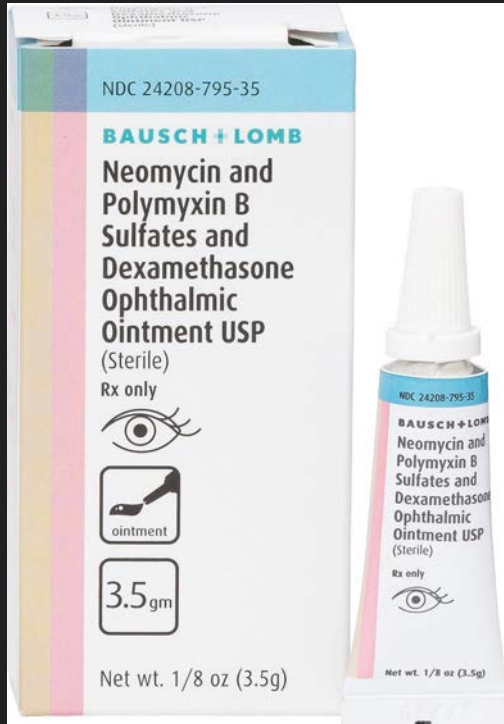- Persistent or recurrent inflammation of the eye
- Many potential causes
 - infection
 - immune mediated
 - hereditary
- Painful
 - tearing, conjunctivitis, chemosis, redness, corneal edema, secondary glaucoma
- May result in blindness due to chronic inflammation and degeneration of normal eye structures.



Chronic Equine Recurrent Uveitis



Chronic Equine Recurrent Uveitis - Treatment



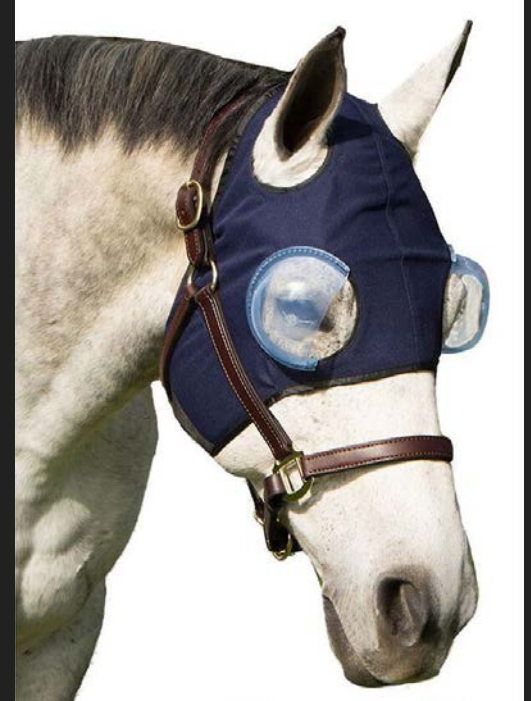Eye Protection!



(Nag Horse Ranch, 2021)

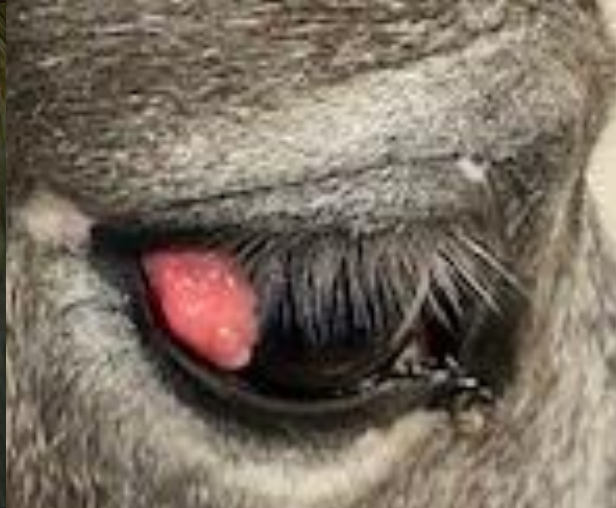
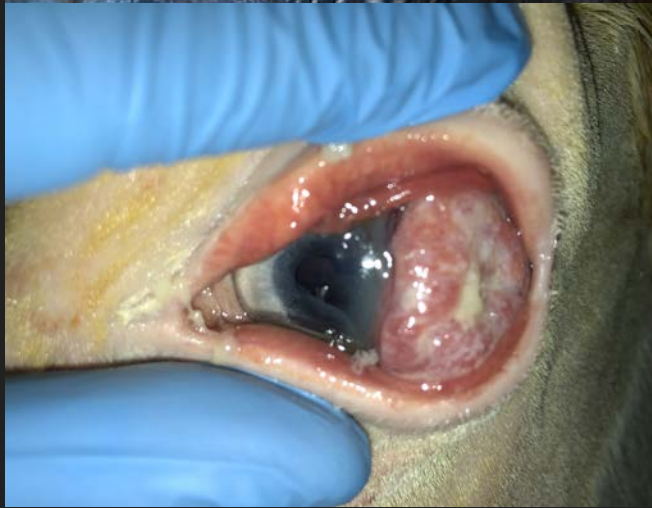
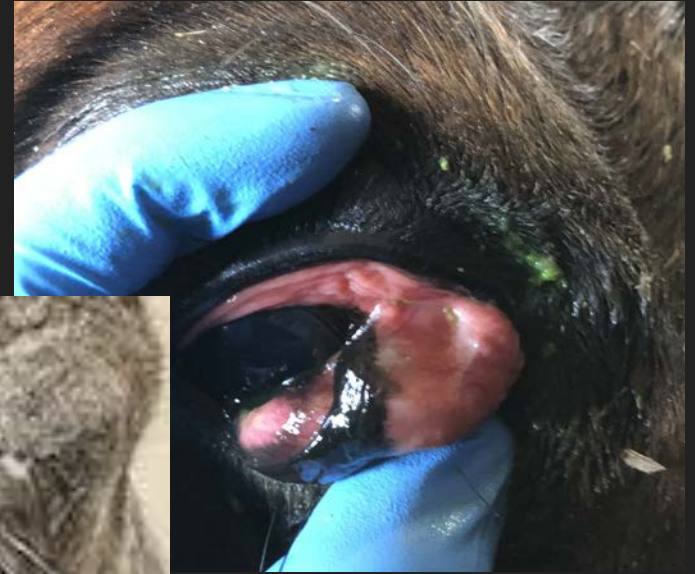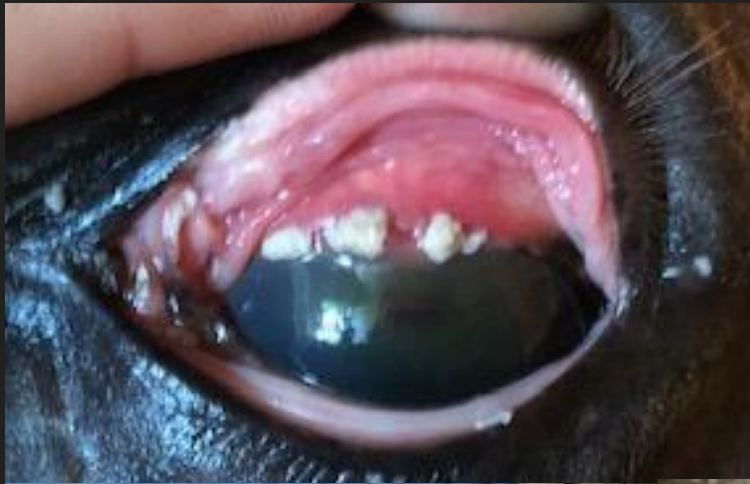(Big Dee's Tack & Vet Supplies, 2021)

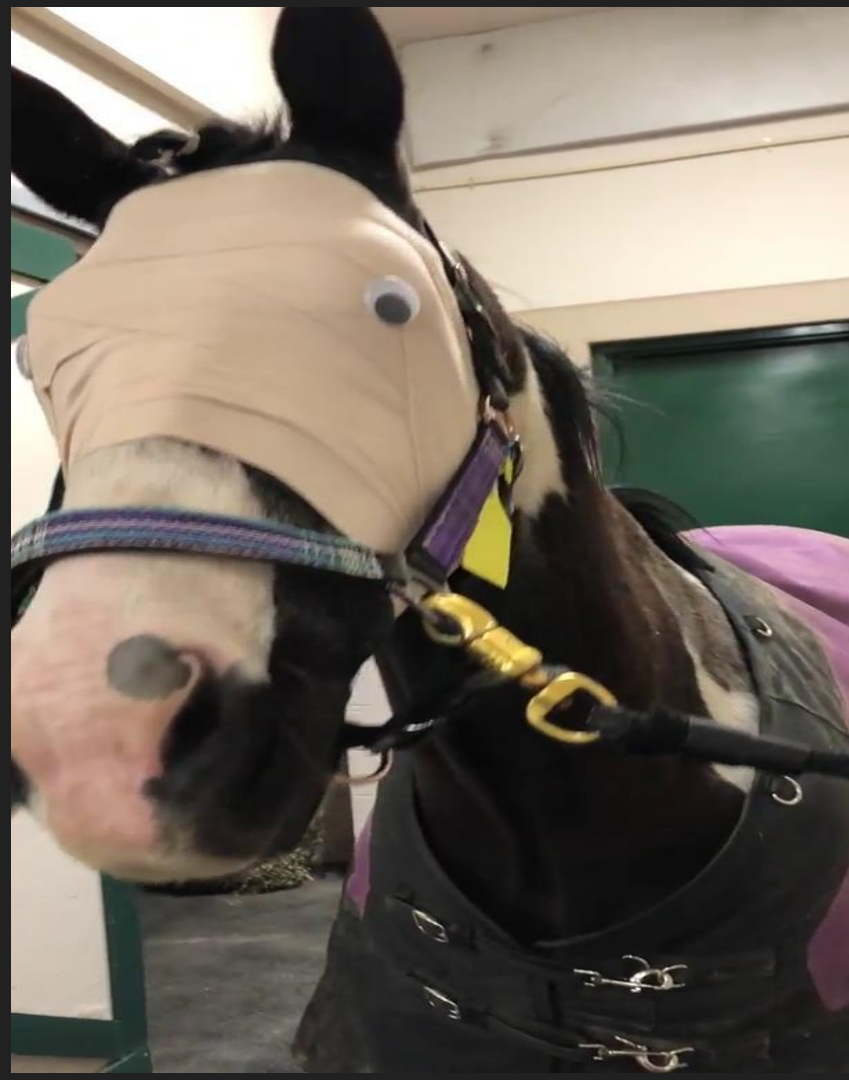

(Big Dee's Tack & Vet Supplies, 2021)

Masses and Neoplasia

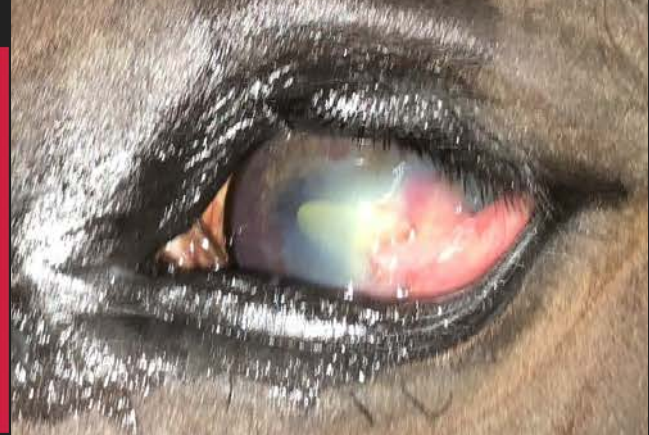
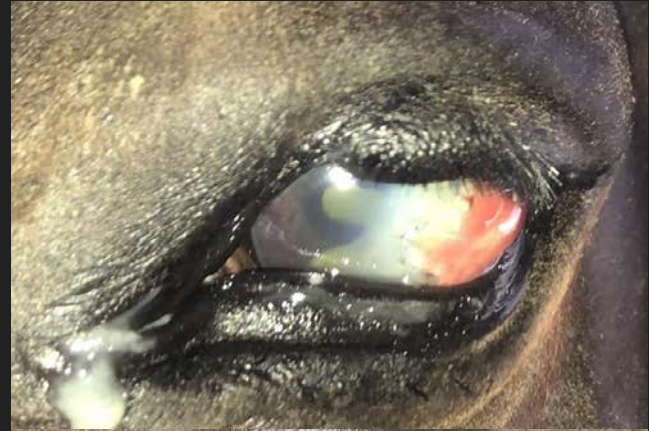

Enucleation



Referral

- Advanced Ulceration
 - Advanced Debridement
 - Conjunctival Graft
 - Therapeutic Contact Lens
 - Keratotomy/Keratectomy
- Uveitis
- Foreign Bodies
- Mass Removals
- Immune Mediated Keratitis





Questions?

References

Alex43223. (2007). *text logo for Ohio State University*. [Image]. WikiCommons.
https://commons.wikimedia.org/wiki/File:Ohio_State_University_text_logo.svg

Big Dee's Tack & Vet Supplies. (2021, March 7). Equine-Medi Eye Lens. Retrieved from:
https://www.bigdweb.com/product/code/155095H.do?gclid=Cj0KCQiAs5eCBhCBARIsAEhk4r7Qg6d62S8g9oGtKvBtMvOsaZseLXnYwDmmM0wvjg80mcNxtu-QR_MaApxQEALw_wcB

Big Dee's Tack & Vet Supplies. (2021, March 7). Jacks Equivizor Recovery Vizor. Retrieved from:
https://www.bigdweb.com/product/code/2864J.do?gclid=Cj0KCQiAs5eCBhCBARIsAEhk4r4fyHy2cOod6Hwd1lge9CM7TSNuw4jUaksoKGXTJB4hKACNyNx1TKQaAt-PEALw_wcB

Gilger, B.C. (2011). *Equine Ophthalmology*. Saunder.

Nag Horse Ranch. (2021, March 7). Interchangeable Eye Saver System. Retrieved from:
<https://www.amazon.com/Interchangeable-Saver-System-Regular-Horse/dp/B07MKP66RX>

Thal Enterprises. (2018). HorseSideVetGuide (2018) [Mobile Application Software].
<https://horsesidevetguide.com/drv/Observation/467/swelling-around-one-eye-or-eyelid/?dialog=true&v=1>